



IPEG's 17th ANNUAL CONGRESS *for Endosurgery in Children*

JUNE 12-15, 2008 🌿 PALAIS STÉPHANIE 🌿 CANNES, FRANCE



Pictures are courtesy of Cannes CVB

Visit us online at www.ipeg.org

Final Program

2008 IPEG Corporate Supporters

IPEG gratefully acknowledges the following companies for their generous support.

DIAMOND LEVEL



PLATINUM LEVEL



IPEG's 17th ANNUAL CONGRESS

TABLE OF CONTENTS

GENERAL INFORMATION

Meeting Leaders & Faculty.....	1
Where, Who & Why.....	1-2
Member Benefits	2
2008 Meeting Goals	2
Accreditation	2
Best Basic Science Abstract Award	2
Scientific Session & Main Event.....	3

MEETING INFORMATION

Lecturers.....	4
Meeting-At-A-Glance.....	5-6
Detailed Program Schedule	7
Events Floorplan	21

FACULTY, MEMBER & GUEST INFORMATION

Faculty & Past Presidents	22
2008 IPEG Faculty.....	23-25
Faculty Disclosures	26
Presenter Disclosures	27

ABSTRACTS

Oral Presentation Abstracts.....	28
Video Presentation Abstracts	52
Poster Abstracts Listings	58-60
Poster Abstracts	61

GENERAL HOURS

EXHIBIT HOURS (Mediterranée/Level -1)

Thursday, June 12	
(IPEG Welcome Reception!)	6:30 pm – 8:00 pm
Friday, June 13	9:30 am – 3:30 pm
Saturday, June 14	9:30 am – 1:30 pm

REGISTRATION HOURS

Thursday, June 12	11:00 am – 8:00 pm
Friday, June 13	6:30 am – 4:00 pm
Saturday, June 14	6:30 am – 4:00 pm
Sunday, June 15	7:00 am – 12:00 pm

POSTER HOURS

Friday, June 13	11:00 am – 5:00 pm
Poster Tour	4:00 pm – 5:30 pm
Saturday, June 14	10:00 am – 5:00 pm
Poster Tour	5:00 pm – 6:30 pm

Don't forget!

Visit the IPEG Exhibit Hall!

The Hall opens at 9:30 am on Friday, June 13, 2008.

GENERAL INFORMATION



MEETING LEADERS & FACULTY

2008 PROGRAM CHAIRS

Program Chairman: Jürgen Schleef, MD

Program Co-Chair: Thomas H. Inge, MD

SESSION CHAIRS

Thursday, June 12, 2008

Bariatric Post Graduate Course

Carroll M. Harmon, MD & Holger Till, MD

Friday, June 13, 2008

Session: How to Set-Up an Endosurgery OR

Marc A. Levitt, MD & George W. Holcomb III, MD

Saturday, June 14, 2008

Urology Panel: UPJ Obstruction – Where Do We Stand?

Alaa El Ghonemi, MD & C.K. Yeung, MD

Panel: Quo Vadis MIS? Where Are We Going With MIS?

(Long-gap Esophageal Atresia, Duodenal Atresia)

Klaas (N) MA Bax, MD & Thom E. Lobe, MD

Panel: Interventional Radiology

Sanjeev Dutta, MD & John Meehan, MD

Sunday, June 15, 2008

Oncology Panel: Does Endosurgery Change

Paradigm in Oncology?

Tadashi Iwanaka, MD & Kathy Pritchard-Jones, MD

Scientific Session: Long Term Results – Is there a Benefit?

Jürgen Schleef, MD & Mark Davenport, MD

SESSION MODERATORS

Friday, June 13, 2008

Video Session: Pitfalls – What to do?

Ciro Esposito, MD & Behrouz Banieghbal, MD

Scientific Session: Advance Endosurgical Techniques

John Meehan, MD & Henri Steyaert, MD

Plenary Session: Gastrointestinal & Hepatobiliary

Benno M. Ure, MD & Philippe Montupet, MD

Scientific Session: All Short Papers

Hossein Allal, MD & David van der Zee, MD

Saturday, June 14, 2008

Video Session: “My Favorite Tricks”

Marcelo H. Martinez Ferro, MD & Gordon A. MacKinlay, MD

Scientific Session: Urology

Azad S. Najmaldin, MD & Jean-Stéphane Valla, MD

Scientific Session: Robotics & Emerging Technology

Douglas C. Barnhart, MD & Sanjeev Dutta, MD

Scientific Session: Basic Science

Thomas H. Inge, MD & Thom E. Lobe, MD

Sunday, June 15, 2008

Scientific Session: Thorax

Miguel A. Guelfand, MD & Steven S. Rothenberg, MD

POSTER LEADERS MODERATORS

Maria Marcela Bailez, MD Munther J. Haddad, MD

Ciro Esposito, MD Girolamo Mattioli, MD

Edward Esteves, MD Atsuyuki Yamataka, MD

EXECUTIVE COMMITTEE

President: Jean-Stéphane Valla, MD

President Elect: George W. Holcomb III, MD

1st Vice President: Behrouz Banieghbal, MD

2nd Vice President: Gordon A. MacKinlay, MD

Secretary: Marcelo H. Martinez Ferro, MD

Treasurer: Thomas H. Inge, MD

Journal Editor: Thom E. Lobe, MD

Asia/Africa Representative: Tadashi Iwanaka, MD

European Representative: Benno Ure, MD

Americas Representative: Marc A. Levitt, MD

Past President: Atsuyuki Yamataka, MD

PROGRAM COMMITTEE

Craig T. Albanese, MD

Hossein Allal, MD

Aayed Al Qahtani, MD

Maria Marcela Bailez, MD

Klaas (N) MA Bax, MD

Peter Borzi, MD

Sanjeev Dutta, MD

Keith E. Georgeson, MD

Munther J. Haddad, MD

Carroll M. Harmon, MD

George W. Holcomb III, MD

Thomas H. Inge, MD

Michael Irish, MD

Marc A. Levitt, MD

Girolamo Mattioli, MD

Azad Najmaldin, MD

Daniel J. Ostlie, MD

Olivier Reinberg, MD

Steven S. Rothenberg, MD

Jürgen Schleef, MD

Benno M. Ure, MD

Jean-Stéphane Valla, MD

David van der Zee, MD

John H.T. Waldhausen, MD

Mark L. Wulkan, MD

Atsuyuki Yamataka, MD

C.K. Yeung, MD

WHERE?

Palais Stéphanie

50 Boulevard de la Croisette BP 224 06414

Cannes Cedex, France

Phone: +33 4 92997000

Fax: +33 4 92997011

WHO?

International Pediatric Endosurgery Group (IPEG)

11300 West Olympic Blvd., Suite 600

Los Angeles, CA 90064 USA

Phone: +1 310-437-0553

Fax: +1 310-437-0585

Website: www.ipeg.org





GENERAL INFORMATION

WHY IPEG?

Now is an excellent time to become an IPEG member. Join IPEG now and receive a substantial discount on the meeting registration by being an IPEG member! Your dues also include a subscription to the *Journal of Laparoendoscopic & Advanced Surgical Techniques* (A \$900 value is yours for FREE).

MEMBER BENEFITS

IPEG exists to support excellence in Pediatric Minimal Access Surgery and endoscopy through education and research; to provide a forum for the exchange of ideas in Pediatric Minimal Access Surgery and endoscopy; and to encourage and support development of standards of training and practice in Pediatric Minimal Access Surgery and Endoscopy. Benefits of membership include:

- Subscription to our official journal: *Journal of Laparoendoscopic & Advanced Surgical Techniques*. (A \$900 savings! IPEG members receive the Journal free of charge.)
- Significant discounts on registration fees for the **Annual Congress for Endosurgery in Children**. (Note: registering for the IPEG Scientific Session, as a member, will save you the equivalent of one year's dues.)
- Affordable dues for surgeons and surgeons-in-training in any country.
- Opportunities to meet and discuss pediatric minimally invasive surgery with the leaders and innovators of the field.
- Access to the IPEG outcomes site on the web.

To apply online, please go to:

www.ipeg.org/memberapplication.php

WHO SHOULD ATTEND?

The **17th Annual Congress of the International Pediatric Endosurgery Group** (IPEG) has elements that have been specifically designed to meet the needs of practicing pediatric surgeons, urologists and other related specialties, physicians-in-training, GI assistants and nurses who are interested in minimally invasive surgery in children and adolescents. The IPEG Program Committee recommends that participants design their own attendance schedule based on their own personal educational objectives.

2008 MEETING GOALS

- To advance the use of minimal invasive endoscopic surgical procedures in children
- To explore the value of new minimally invasive surgical concepts and new endoscopic surgical techniques for use in children
- To discuss controversial topics in pediatric endosurgery and the future role of endosurgery in children
- To provide opportunity for younger surgeons to acquire a knowledge of endoscopic surgical procedures in children through exposure to experts in the field
- To describe emerging technologies in MIS

ACCREDITATION

This activity has been planned and implemented in accordance with the Essentials and Standards of the Accreditation Council for Continuing Medical Education through the joint sponsorship of the Society of American Gastrointestinal and Endoscopic Surgeons (SAGES) is accredited by the ACCME to provide continuing medical education for physicians. SAGES designates this Continuing Medical Education activity for:

- 3.0 Credits for Thursday Session
- 7.75 Credits for Friday Sessions
- 7.5 Credits for Saturday Sessions
- 4.0 Credits for Sunday Sessions

In Category 1 of the Physicians Recognition Award for the American Medical Association. *Note:* Each physician should claim only those hours of credit that he/she actually spent in the educational activity.

BEST BASIC SCIENCE ABSTRACT AWARD

The **Best Basic Science Abstract Award** will be a cash prize of US \$1000 to be presented during the Saturday session of the Abstract Presentations. The Program Committee will select the Award recipient. The IPEG Executive Committee is committed to education and feels this is a very concrete way to express that commitment.

EVALUATION & CME FORMS: Please complete the evaluation and CME forms and return to the IPEG Registration Desk. Please allow 60 days from the event date for all forms to be processed and CME certificates to be sent out.

GENERAL INFORMATION



SCIENTIFIC SESSION

DESCRIPTION

The theme of the 2008 IPEG Meeting will be a case oriented approach to challenges in clinical situations with expert panels and with invited faculty who will speak on specific topics. Included are sessions of oral and video presentations of abstracts selected by the Program Committee. The program also includes Video Abstract Presentations and Poster Presentation sessions. Panel information and information about the abstract and video presentation sessions will be available in the Final Program distributed on-site.

WHAT IS INCLUDED?

The registration fee includes entrance to the IPEG Scientific Session rooms on Friday, Saturday, and Sunday, entrance to the Exhibit Hall, General Session Breaks, entrance to the Main Event, and Welcome Reception. **Please note: Your hotel room rate at the Palais Stéphanie includes breakfast.**

OBJECTIVES

At the end of this session, participants will understand the current and emerging practices and procedures in minimal access surgery and other developing applications. Participants will acquire information, which relates to indications, contraindications, diagnosis, technique, prevention and management of complications, and results of minimal access surgery, endoscopic, and general surgical procedures. Participants will recognize the scientific and physiologic basis of minimal access surgery, endoscopy and emerging surgical technology (e.g. robotics).

MAIN EVENT



MAIN EVENT

Saturday, June 14, 2008

7:00 pm – 10:30 pm

Palais Stéphanie Roof Top

(Attire: French casual chic of course!)

Join IPEG for a cocktail dinner and dancing on the Palais Stéphanie Roof Top. Enjoy a taste of the Mediterranean, view the bay, and watch as the Boulevard La Croisette comes to life!

IPEG acknowledges our Diamond and Platinum Level Donors for their support of this event:

DIAMOND: Karl Storz Endoscopy-America and Stryker Endoscopy

PLATINUM: Ethicon Endo-Surgery, Inc.

2008 POSTER SESSION: Posters will be displayed, Friday, June 13th for Group A and Saturday, June 14th for Group B. If you are presenting a poster, please make sure to remove your poster immediately following your poster tour.

COPYRIGHT: The program and talks presented at the 2008 IPEG Annual Meeting are copyrighted products of the International Pediatric Endoscopic Group. Any reproduction or rebroadcasting without the express written consent of IPEG is strictly forbidden.



LECTURERS

GUEST LECTURERS



KARL STORZ LECTURE: “NATURAL ORIFICE TRANSLUMENAL ENDOSCOPIC SURGERY (NOTES™)”

Friday, June 13, 2008, 11:30 am – 12:00 pm

Location: Auditorium/Level -1

Guy-Bernard Cadriere, MD

Director, Department of Digestive Surgery,
Center University Hospital, St. Pierre, *Brussels, Belgium*



KEYNOTE LECTURE: “CLIMATE CHANGE & INCREASED LONGEVITY – TWO MAJOR DRIVERS CHALLENGING THE FUTURE OF THE INSURANCE INDUSTRY”

Saturday, June 14, 2008, 2:30 pm – 3:00 pm

Location: Auditorium/Level -1

Sergio Balbinot

Co-Chief Executive Officer, Assicurazioni General, *Triste, Italy*

PRESIDENT ADDRESS & LECTURE



PRESIDENT ADDRESS & LECTURE: “THE INFLUENCE OF SPORTS ON MY SURGICAL PRACTICE”

Friday, June 13, 2008, 1:00 pm – 1:30 pm

Location: Auditorium/Level -1

Jean-Stéphane Valla, MD

Professor of Pediatric Surgery, Head of the Surgical Department
Lenval Children's Hospital, *Nice, France*

MEETING-AT-A-GLANCE



THURSDAY, JUNE 12, 2008

TIME	EVENT	LOCATION
1:00 pm – 4:00 pm	IPEG Bariatric Post Graduate Course <i>Chairs:</i> Carroll M. Harmon, MD & Holger Till, MD <i>Panelists:</i> Aayed Al Qahtani, MD, Thomas H. Inge, MD, & Holger Till, MD	Suquet ABC Level -1
6:30 pm – 8:00 pm	Welcome Reception/Exhibit Hall	Mediterranée Level -1

FRIDAY, JUNE 13, 2008

TIME	EVENT	LOCATION
7:30 am – 8:30 am	Morning Video Session: Pitfalls – What To Do? <i>Moderators:</i> Ciro Esposito, MD & Behrouz Banieghbal, MD	Auditorium Level -1
8:30 am – 8:45 am	Welcome Address Jean- Stéphane Valla, MD <i>Introduction:</i> Jürgen Schleef, MD	Auditorium Level -1
8:45 am – 9:45 am	Scientific Session: Advance Endosurgical Techniques <i>Moderators:</i> John Meehan, MD & Henri Steyaert, MD	Auditorium Level -1
9:45 am – 10:15 am	BREAK	Exhibit Hall/ Mediterranée
10:15 am – 11:30 am	Scientific Session: Gastrointestinal & Hepatobiliary <i>Moderators:</i> Benno M. Ure, MD & Philippe Montupet, MD	Auditorium Level -1
11:30 am – 12:00 pm	Karl Storz Lecture: “Natural Orifice Translumenal Endoscopic Surgery (NOTES™)” Guy-Bernard Cadière, MD <i>Introduction:</i> Jean-Stéphane Valla, MD	Auditorium Level -1
12:00 pm – 1:00 pm	LUNCH BREAK <i>* Pre-purchased box lunch tickets can be redeemed in the Exhibit Hall</i>	Exhibit Hall/ Mediterranée
1:00 pm – 1:30 pm	Presidential Address & Lecture: “The Influence of Sports on My Surgical Practice” Jean-Stéphane Valla, MD <i>Introduction:</i> Jürgen Schleef, MD	Auditorium Level -1
1:30 pm – 2:45 pm	How to Set-up an Endosurgery OR <i>Chairs:</i> Marc A. Levitt, MD & George W. Holcomb, MD	Auditorium Level -1
2:45 pm – 3:45 pm	Scientific Session: All Short Papers <i>Moderators:</i> Hossein Allal, MD & David van der Zee, MD	Auditorium Level -1
4:00 pm – 5:30 pm	Poster Tours: Group A <i>Moderators:</i> Ciro Esposito, MD, PhD, Maria Marcela Bailez, MD & Munther J. Haddad, MD	Suquet ABC Level -1

Don't forget!

Visit the IPEG Exhibit Hall!

The Hall opens at 9:30 am on Friday, June 13, 2008.



MEETING-AT-A-GLANCE

SATURDAY, JUNE 14, 2008

TIME	EVENT	LOCATION
8:00 am – 9:10 am	Morning Video Sessions: “My Favorite Tricks” <i>Moderators:</i> Marcelo H. Martinez Ferro, MD & Gordon A. MacKinlay, MD	Auditorium Level -1
9:10 am – 10:15 am	Urology Panel: UPJ Obstruction – Where Do We Stand? <i>Chairs:</i> Alaa El Ghonemi, MD & C.K. Yeung, MD	Auditorium Level -1
10:15 am – 10:45 am	BREAK	Exhibit Hall/ Mediterranée
10:45 am – 11:45 am	Scientific Session: Urology <i>Moderators:</i> Azad S. Najmaldin, MD & Jean-Stéphane Valla, MD	Auditorium Level -1
11:45 am – 12:45 pm	Scientific Session: Robotics & Emerging Technology <i>Moderators:</i> Douglas C. Barnhart, MD & Sanjeev Dutta, MD	Auditorium Level -1
12:45 pm – 1:45 pm	Panel: Quo Vadis MIS? Where Are We Going With MIS? (Long-gap Esophageal Atresia, Duodenal Atresia) <i>Chairs:</i> Klaas (N) MA Bax, MD & Thom E. Lobe, MD	Mediterranée Level -1
1:45 pm – 2:30 pm	LUNCH BREAK <i>* Pre-purchased box lunch tickets can be redeemed in the Exhibit Hall</i>	Exhibit Hall/ Mediterranée
2:30 pm – 3:00 pm	Keynote Lecture: “Climate Change & Increased Longevity – Two Major Drivers Challenging the Future of the Insurance Industry” Sergio Balbinot, MD <i>Introduction:</i> Jürgen Schleef, MD	Auditorium Level -1
3:00 pm – 4:00 pm	Panel: Interventional Radiology <i>Chairs:</i> Sanjeev Dutta, MD & John Meehan, MD	Auditorium Level -1
4:00 pm – 5:00 pm	Basic Science Session <i>Moderators:</i> Thomas H. Inge, MD & Thom E. Lobe, MD	Auditorium Level -1
5:00 pm – 6:30 pm	Poster Tours: Group B <i>Moderators:</i> Girolamo Martioli, MD, Edward Esteves, MD & Atsuyuki Yamataka, MD	Suquet ABC Level -1
7:00 pm – 10:30 pm	MAIN EVENT (Cocktail Dinner & Dancing)	Hotel Rooftop

SUNDAY, JUNE 15, 2008

TIME	EVENT	LOCATION
8:00 am – 9:00 am	Oncology Panel: Does Endosurgery Change Paradigma in Oncology? <i>Chairs:</i> Tadashi Iwanaka, MD & Kathy Pritchard-Jones, MD	Auditorium Level -1
9:00 am – 10:00 am	Scientific Session: Thorax <i>Moderators:</i> Miguel A. Guelfand, MD & Steven S. Rothenberg, MD	Auditorium Level -1
10:00 am – 10:30 am	BREAK	On Your Own
10:30 am – 11:30 am	General Assembly <i>Moderators:</i> Jean-Stéphane Valla, MD	Auditorium Level -1
11:30 am – 12:30 pm	Scientific Session: Long Term Results – Is there a Benefit? (Lecture & Abstract Session) <i>Chairs:</i> Jürgen Schleef, MD & Mark Davenport, MD	Auditorium Level -1
12:30 pm – 1:00 pm	Closing Remarks & Presentation of 2009 President Jürgen Schleef, MD, Thomas H. Inge, MD, & Jean-Stéphane Valla, MD	Auditorium Level -1

PROGRAM SCHEDULE



THURSDAY, JUNE 12, 2008

BARIATRIC POST GRADUATE COURSE

1:00 PM – 4:00 PM

Chairs: Carroll M. Harmon, MD & Holger Till, MD

Faculty: Aayed Al Qahtani, Thomas H. Inge, MD & Holger Till, MD

DESCRIPTION

This course will provide the participant with an understanding of the rapidly evolving epidemiology of childhood severe obesity and the considerable health risks. The immediate, intermediate and long-term risks of adolescent severe obesity will be highlighted. The efficacy of medical and behavioral interventions for childhood severe obesity will be briefly reviewed, and indications and contraindications for adolescent bariatric surgery will be discussed in detail. An appreciation for the types of surgical intervention and the rationale for surgical therapy will be presented. The participant will be brought up to date with the current considerations for weight loss interventions, which may be appropriate for the adolescent. Finally, practical considerations for the pediatric surgeon who plans to implement a surgical weight loss program in a children's hospital setting will be reviewed.

OBJECTIVES

At the conclusion of this seminar, you will:

- Understand the scope of the problem and health risks associated with of pediatric severe obesity
- Understand the indications and contraindications for weight loss procedures in adolescents
- Be familiar with the pros and cons of various surgical weight loss options for adolescents
- Be familiar with facility/personnel issues which may impact implementation of a surgical weight loss program within a children's hospital

TIME	TOPIC	FACULTY
1:00 pm – 1:05 pm	Introduction	Carroll M. Harmon, MD
1:05 pm – 1:30 pm	Etiology, Epidemiology and World Impact of Pediatric Obesity	Holger Till, MD
1:30 pm – 1:35 pm	Questions/Discussion	
1:35 pm – 2:00 pm	Indications and Contraindications for Adolescent Bariatric Surgery	Carroll M. Harmon, MD
2:00 pm – 2:05 pm	Questions/Discussion	
2:05 pm – 2:30 pm	Present and Future Surgical Options for Pediatric Bariatric Surgery	Aayed Al Qahtani, MD
2:30 pm – 2:35 pm	Questions/Discussion	
2:35 pm – 2:44 pm	(*Not in secular order) S002: Technical Considerations for Laparoscopic Adjustable Gastric Banding in Adolescents <u>Amulya K. Saxena, MD</u> , Lutz Stroedter, MD, Michael E. Hoellwarth, MD, Department of Pediatric Surgery, Medical University of Graz, Austria	
2:44 pm – 2:49 pm	S004: Managing the Left Gastric Artery During Adolescent Laparoscopic Gastric Banding (LAGB) <u>Jeffrey L. Zitsman, MD</u> , Morgan Stanley Children's Hospital of New York Presbyterian, Columbia University Medical Center	
2:49 pm – 2:58 pm	S003: Laparoscopic Sleeve Gastrectomy as a Stand-Alone Technique for Children and Adolescents with Morbid Obesity <u>Holger K. Till, PhD</u> , Oliver J. Muensterer, PhD, Susanne Blueher, MD, Antje Koerner, MD, Wieland Kiess, Department of Pediatric Surgery	
2:58 pm – 3:03 pm	S001: Perioperative Safety of Laparoscopic Roux-en-Y Gastric Bypass: A Children's Hospital Experience <u>Go Miyano, MD</u> , Stavra Xanthakos, MD, Judy Bean, PhD, Victor F. Garcia, MD, Thomas H. Inge, MD, Cincinnati Children's Hospital Medical Center	
3:03 pm – 3:20 pm	BREAK	
3:20 pm – 3:45 pm	Implementing a Bariatric Surgery Program in a Children's Hospital	Thomas H. Inge, MD
3:45 pm – 3:50 pm	Questions/Discussion	
3:50 pm – 4:05 pm	Case Presentations	Faculty

*IPEG acknowledges the following companies for educational grants in support of this session:
Ethicon Endo-Surgery, Inc. and Karl Storz Endoscopy-America*

WELCOME RECEPTION (EXHIBIT HALL/MEDITERANÉE)

6:30 PM – 8:00 PM



PROGRAM SCHEDULE

FRIDAY, JUNE 13, 2008

MORNING VIDEO SESSION: PITFALLS – WHAT TO DO?

7:30 AM – 8:30 AM

Moderators: **Ciro Esposito, MD & Behrouz Banieghbal, MD**

DESCRIPTION

This is a new session! The topic is open and the objective is to have participants share their experience about the pitfalls that you can have in your MIS practice. For example: difficult cases, management of complications, anatomic anomalies, special maneuvers, unusual pathologies, etc. Participants will have 5 minutes to present their video and/or power point presentation. This session will also include audience participation. *An award for best trick will be provided a la Cannes Film Festival!

OBJECTIVES

1. To promote the exchange of new ideas and techniques, that facilitates the development of minimally invasive surgery (MIS).
2. Promote the advancement of minimally invasive surgery (MIS) in Pediatrics.
3. To stimulate the development of new ideas and techniques outside the habitual scientific framework.

TIME	TOPIC
7:30 am – 7:35 am	S005: Genitofemoral Nerve Injury After Laparoscopic Varicocelectomy in Adolescents <u>Oliver J. Muensterer, PhD</u> , Department of Pediatric Surgery, University of Leipzig
7:35 am – 7:40 am	S006: Scrotal Skin Necrosis After Methylene Blue Dye Injection for Lymphatic Sparing Laparoscopic Varicocelectomy <u>Berkutug Bahadir, MD</u> , <u>Gulnur Gollu, MD</u> , <u>Aydin Yagmurlu, MD</u> , Department of Pediatric Surgery, Ankara University Faculty of Medicine
7:40 am – 7:45 am	S007: Accidental Tracheal Wall Injury During Thoracoscopic Esophageal Atresia Repair – Complications and Management <u>Dariusz Patkowski, PhD</u> , <u>Marzena Zielinska, PhD</u> , <u>Magdalena Checinska, MD</u> , <u>Piotr Stepień, PhD</u> , <u>Malgorzata Szerla, MD</u> , <u>Jerzy Czernik, PhD</u> , Department of Paediatric Surgery and Urology, Medical University of Wrocław
7:45 am – 7:53 am	V001: Prone Retroperitoscropy <u>Lars J. Cisek, MD</u> , <u>Micheal H. Hsieh, MD</u> , <u>David R. Roth, MD</u> , <u>Edmond T. Gonzales, MD</u> , <u>Eric A. Jones, MD</u> , Texas Children's Hospital/Baylor College of Medicine
7:53 am – 8:01 am	V002: Laparoscopic Colovaginoplasty: An Alternative Technique for Vaginal Reconstruction in Children <u>Berkutug Bahadir, MD</u> , <u>Gulnur Gollu, MD</u> , <u>Esra Temeltas, MD</u> , <u>Aydin Yagmurlu, MD</u> , Department of Paediatric Surgery, Ankara University Faculty of Medicine
8:01 am – 8:09 am	V003: Laparoscopic Management of Persistent Müllerian Duct Syndrome <u>Aayed R. Alqahtani, MD</u> , King Saud University, Riyadh, Saudi Arabia
8:09 am – 8:17 am	V004: Minimally Invasive Opportunities for Patients with Imperforate Anus with Rectovestibular Fistula and Absent or Atretic Vagina <u>Sean J. Barnett, MD</u> , <u>Marc A. Levitt, MD</u> , <u>Lesley Breech, MD</u> , <u>Richard A. Falcone, MD</u> , <u>Alberto Pena, MD</u> , Cincinnati Children's Hospital Medical Center, Division of Pediatric and Thoracic Surgery
8:17 am – 8:25 am	V005: Sigmoid Vaginoplasty with Robotic Surgery <u>Sarah Marietti, MD</u> , <u>Brendan Campbell, MD</u> , <u>Fernando Ferrer, MD</u> , <u>Christina Kim, MD</u> , Connecticut Children's Medical Center
8:25 am – 8:33 am	V006: Laparoscopic Excision of a Familial Paraganglioma <u>Brendan T. Campbell, MD</u> , <u>Kristine M. Kelliher, MD</u> , <u>Angela H. Santiago, MD</u> , <u>D. Elizabeth Estrada, MD</u> , Connecticut Children's Medical Center

WELCOME ADDRESS

8:30 AM – 8:45 AM

Jean-Stéphane Valla, MD

Introduction: Jürgen Schleef, MD

PROGRAM SCHEDULE



SCIENTIFIC SESSION: ADVANCE ENDOSURGICAL TECHNIQUES 8:45 AM – 9:45 AM

Moderator: John Meehan, MD & Henri Steyaert, MD

TIME	TOPIC
8:45 am – 8:54 am	S008: Endoscopic Endonasal Transsphenoidal Surgery for Intra- and Extrasellar Lesions in Children Verena Gellner, BA, Senta Kurschel-Lackner, BA, Hans Georg Eder, BA, Hannes Braun, PhD, Georg Clarici, MD, Heinz Stammberger, PhD, Michael Mokry, Department of Neurosurgery, ORL Head & Neck Surgery, Medical University Graz, Austria
8:54 am – 9:03 am	S009: Endoscopic Endonasal Transsphenoidal Approach to Pituitary Lesions, Craniopharyngiomas, and Other Lesions of the Skull Base– The Graz Experience <u>Michael Mokry, PhD</u> , Verena Gellner, MD, Etienne Holl, MD, Georg Clarici, MD, Hannes Braun, PhD, Heinz Stammberger, Department of Neurosurgery, Department of ORL Head & Neck Surgery, Medical University, Graz, Austria
9:03 am – 9:11 am	V007: Trans-Axillary Totally Endoscopic Robot-Assisted Ansa Cervicalis to Recurrent Laryngeal Nerve Reinnervation for Repair of Unilateral Vocal Fold Paralysis <u>Simon K. Wright, MD</u> , Thom E. Lobe, MD, Blank Children's Hospital/ENT Clinic of Iowa
9:11 am – 9:16 am	S010: Laparoscopy-Assisted Surgery for Bowel Occlusion in Newborns: Two Cases <u>Maria Grazia Scuderi, MD</u> , Lucia Virardi, MD, Salvatore Arena, MD, Aurelio Di Benedetto, PhD, Vincenzo Di Benedetto, PhD, U.O.C. di Chirurgia Pediatrica – Azienda Ospedaliero-Universitaria "Vittorio Emanuele", Azienda Ospedaliero-Universitaria "Policlinico", Università degli Studi di Catania.
9:16 am – 9:21 am	S011: SETT – Subcutaneous Endoscopic Transaxillary Tenotomy for Congenital Muscular Torticollis <u>Yury Kozlov, MD</u> , Vladimir Novogilov, MD, Natalya Aleynikova, Pavel Yurkov, MD, Vitaly Kovalev, Andrey Yakovlev, Irina Weber, MD, Marina Kononenko, Svetlana Kuznecova, Department of Pediatric Surgery, Department of Pediatric Traumatology, Municipal Pediatric Hospital, Irkutsk, Russia
9:21 am – 9:26 am	S012: Laparoscopic Management of Ovarian Lesions in Children <u>Riccardo Guanà, MD</u> , Fabio Beretta, MD, Luciano Sangiorgio, MD, Henry Steyaert, MD, Jean-Stephane Valla, PhD, Division of Paediatric Surgery, Lenval Hospital, Nice, France
9:26 am – 9:31 am	S013: Inter-Observer Variation in the Assessment of Appendicitis <u>Todd A. Ponsky, MD</u> , Muhannad Hafi, MD, Kurt Heiss, MD, John Dinsmore, MD, Kurt D. Newman, MD, James Gilbert, MD, Rainbow Babies and Children's Hospital, Cleveland, OH, USA, Children's National Medical Center, Washington, D.C., USA, Children's Hospital of Central California, Madera, CA, USA
9:31 am – 9:36 am	S014: Trans Perineal Rectovesical Fistula Ligation in Laparoscopic Assisted Abdominoperineal Pull through for High Anorectal Malformations <u>Sameh M. Abdel Hay, MD</u> , Pediatric Surgery Unit, Ain Shams University, Cairo, Egypt
9:36 am – 9:41 am	S015: Inguinal Hernia Repair in Children with Percutaneous Internal Ring Suturing (PIRS): Analysis of 350 Operations <u>Dariusz Parkowski, PhD</u> , Rysiakiewicz Konrad, MD, Ladogórska Jolanta, MD, Zielinska Marzena, PhD, Apoznanski Wojciech, PhD, Czernik Jerzy, PhD, Department of Paediatric Surgery and Urology, Medical University of Wrocław
9:41 am – 9:46 am	S016: Peritoneal Carcinomatosis in Children: Role of Laparoscopy <u>Piolat Christian, MD</u> , Dyon Jean-François, MD, Robert Yohann, SibaiI Samir, MD, Nugues Frédérique, MD, Eitenschenk Laurence, MD, Pagnier Anne, MD, Pasquier Dominique, MD, Plantaz Dominique, PhD, Chu de Grenoble, France

BREAK (EXHIBIT HALL/MEDITERANÉE) 9:45 AM – 10:15 AM



PROGRAM SCHEDULE

SCIENTIFIC SESSION: GASTROINTESTINAL & HEPATOBILIARY 10:15 AM – 11:30 AM

Moderators: Benno M. Ure, MD & Philippe Montupet, MD

TIME	TOPIC
10:15 am – 10:20 am	S017: Complete Laparoscopic Cyst Excision and Hepatico- Duodenostomy: Early Results of 74 Cases <u>Liem NT, PhD</u> , Dung LA, MD, Son TN, PhD, National Hospital of Pediatrics
10:20 am – 10:28 am	V008: Laparoscopic Transduodenal Resection of a Duodenal Duplication Cyst <u>Steven S. Rothenberg, MD</u> , The Rocky Mountain Hospital for Children
10:28 am – 10:33 am	V009: Laparoscopic Splenic Preserving Distal Pancreatectomy For Trauma in a Child <u>Marcus M. Malek</u> , MD, Timothy D. Kane, MD, Children's Hospital of Pittsburgh of UPMC
10:33 am – 10:38 am	S018: Laparoscopic Treatment of Pancreatic Pseudocysts in Children <u>Suzanne Yoder, MD</u> , Steven S. Rothenberg, MD, Kuo Jen Tsao, MD, Mark L. Wulkan, MD, Todd Ponsky, MD, Shawn D. St. Peter, MD, Daniel J. Ostlie, MD, Timothy D. Kane, Rocky Mountain Hospital for Children, Denver, CO; University of Texas Medical Center, Houston, TX; Emory Children's Hospital, Atlanta, GA; Children's Mercy Hospital, Kansas City, MO; The Children's Hospital of Pittsburgh, Pittsburgh, PA
10:38 am – 10:43 am	S019: Laparoscopic Cholecystectomy in Pediatric Patients – Experience of 570 Procedures <u>Igor V. Poddoubnyi</u> , MD, Kirill N. Tolstov, MD, Andrei A. Isaev, MD, Mikhail Y. Kozlov, Moscow State University of Medicine and Dentistry, Department of Pediatric Surgery * S020 (Moved to Panel: Quo Vasdis MIS? – Where are we Going with MIS?)
10:43 am – 10:48 am	S021: Early Discharge Following Laparoscopic Appendectomy in Children Utilizing an Evidence Based Clinical Pathway <u>Denis D. Bensard</u> , MD, Richard J. Hendrickson, MD, Joshua M. Careskey, MD, Carla J. Fyffe, RN, The Peyton Manning Children's Hospital and Cincinnati Children's Hospital Medical Center
10:48 am – 10:53 am	S022: Division of the Mesoappendix with Electrocautery in Children Is Safe, Effective, and Cost-Efficient <u>Todd A. Ponsky, MD</u> , Steven S. Rothenberg, MD, Rocky Mountain Hospital for Children, Denver, CO, USA
10:53 am – 10:58 am	S023: Is There a Need of Open Surgical Experience for Laparoscopic Appendectomy Training? <u>Gulnur Gollu, MD</u> , Meltem Bingol-Kologlu, MD, Berkutug Bahadir, MD, Rahsan Vargun, MD, Huseyin Dindar, MD, Aydin Yagmurlu, MD, Department of Pediatric Surgery, Ankara University, School of Medicine, Ankara, Turkey
10:58 am – 11:03 am	S024: Utility of ERCP in Neonatal and Infant Cholestasis <u>K. Bjornland, PhD</u> , L. Aabakken, PhD, I. Aagaenæs, MD, T. Sanengen, PhD, S. Aasen, R. Emblem, PhD, Rikshospitalet University Hospital
11:03 am – 11:08 am	S025: Laparoscopic Antegrade Continence Enema Using the Umbilical Y-V Appendicoplasty Technique <u>Shawn J. Rangel, MD</u> , Andrea Bischoff, MD, Pena Alberto, MD, Levitt A. Marc, MD, Cincinnati Children's Hospital
11:08 am – 11:13 am	S026: Laparoscopic Assisted Transanal Pull-Through Versus Transanal Pull-Through for Hirschsprung's Disease <u>Mustafa Kucukaydin, MD</u> , Mahmut Guzel, MD, Ahmet N. Ciftler, MD, Mehmet Uysal, MD, Mustafa E. Dorterler, MD, Serkan Arslan, MD, Ahmet B. Dogan, MD, Kadri C Sulubulut, MD, Ali Aslan, MD, Erciyes University School of Medicine, Department of Pediatric Surgery
11:13 am – 11:18 am	S027: Minimally Invasive Surgery for Anorectal Malformation in Boys <u>Guillaume Podevin, PhD</u> , Thierry Petit, MD, Pierre Yves Mure, PhD, Martine Demarche, MD, Hossein Allal, MD, François Becmeur, MD, Stephan Geiss, MD, Paul Phillippe, MD, Yves Heloury, MD, Departments of Paediatric Surgery of Nantes, Caen, Lyon, Liège, Montpellier, Strasbourg, Colmar, Luxembourg.
11:18 am – 11:23 am	S028: Endoscopy-Assisted Laparoscopic Recto-Bulbar Urethral Fistula Excision in a Male with Imperforate Anus <u>Atsuyuki Yamataka, PhD</u> , Yoshifumi Kato, PhD, Kyeong Deok Lee, PhD, Junichi Kusafuka, PhD, Geoffrey J. Lane, Tadaharu Okazaki, Department of Pediatric General and Urogenital Surgery, Juntendo University School of Medicine

IPEG acknowledges the following company for an educational grant in support of this session: Karl Storz Endoscopy-America

PROGRAM SCHEDULE



KARL STORZ LECTURE: 11:30 AM – 12:00 PM
"NATURAL ORIFICE TRANSLUMENAL ENDOSCOPIC SURGERY (NOTES™)"



Introduction: Jean-Stéphane Valla, MD

Guest Speaker: Guy-Bernard Cadière, MD

Director, Department of Digestive Surgery, Center University Hospital, St. Pierre, Brussels, Belgium
Born in Berchem, St. Agathe, Belgium, Dr. Cadière is married with two children.

EDUCATION

- 1977** Certification in Physical Education, University Libre of Brussels (ULB)
1980 Diploma of Doctor of Medicine, Surgery and Childbirth (obtained with distinction), University Libre of Brussels (ULB) in 1980.
1986 Recognition of Gratitude INAMI in General Surgery

CAREER

- 1978** Trainee, 8th Hospital – Peking
1978 Trainee, Prince Regent Charles of Bujumbura Hospital
1980 Candidate Resident Service, Department of Surgery, (Prof. Bremer), Chu, Saint Pierre
1981-1982 Candidate Resident Service, Surgery Center, P. Brien
1983-1986 Candidate Resident Service, Department of Surgery, (Prof. Bremer), Chu, Saint Pierre
1986-1991 Executive, Center Hospital, University of A. Gailly
1986-1991 Service in Gastroenterology (Prof. Lambilliotte), Erasme Hospital
1995-1996 Professor, University of Toulouse
1992-2000 Joint Chief of Digestive Surgery, Chu, Saint Pierre
2001-present Chief of Digestive Surgery, Chu, Saint Pierre, Brussels

UNIVERSITY TITLES

- 1982-1984** Assistant in charge of 2nd and 3rd year candidates, Department of Medicine – Anatomy (Prof. Mulnard)
1991 Consultant at the Academic Hospital, University Libre of Brussels (ULB)
1991 Associate Professor: 3rd level doctorat course, University Libre of Brussels (ULB)
1991 Participation in University degrees:
– University of Paris XIII & Paris School of Medicine
– Paul Sabatier University of Toulouse (Prof. Fourtanier)
– University of Bordeaux (Prof. Perissat)
1995 Professor, Paul Sabatier University of Toulouse
1997 Aggregation of higher education (May 1997), University Libre of Brussels (ULB)

INVITED PROFESSOR

French Academy of Surgery (Paris – France), Paris Hospital School of Surgery, Paul Sabatier University (Toulouse – France), Rangueil University (Toulouse-France), University of Bordeaux (France), University of Fort-de-France (Martinique – France), European Institute of Telesurgery (Strasbourg – France), University of Barcelona (Spain), Cleveland State University (Cleveland, Ohio - USA), The Ohio State University (Columbus, Ohio - USA), Mount Sinai School of Medicine (New-York - USA), Cornell University (New-York, New York - USA), Emory (Atlanta - USA), Fukuoka University (Japan), University of Pittsburgh (Pittsburgh, Pennsylvania - USA), and the University of Sao Paulo (Brazil)

SCIENTIFIC ACTIVITIES

- Member, Editorial Committee for Surgical Endoscopy
- Member, Editorial Committee Obesity Surgery
- Chair, Educational Committee for the European Association of Endoscopic Surgeons (EAES)
- Faculty for the Society of American Gastrointestinal Endoscopic Surgeons (SAGES)
- Member, International Federation for the Surgery of Obesity (IFSO)
- Vice-Président for the Society of European Telemedicine
- Faculty, European Institute of Technology (EITS/IRCAD)
- Consultant for the Airbus Industry
- Consultant for the European Space Agency (ESA)
- Director, European School of Laparoscopic
- Doctors of the World - Viet Duc hospital, Hanoi, Vietnam
- Doctors without Borders - Sean Pear Hospital – Cambodia
- Volunteer, Education in Africa
- Premiered Laparoscopic Surgery in Obesity
- Premiered Robotic Digestive Surgery
- Premiered Transoral Fundoplication for gastroesophageal Reflux

INTERNATIONAL CONFERENCES

779 communications, conferences and lectures, 54 visioconferences

PUBLICATIONS

131 publications, 1 body of work, 5 chapters in different topics, 17 visual support materials

LUNCH BREAK (EXHIBIT HALL/MEDITERANÉE)

12:00 PM – 1:00 PM

**Pre-purchased box lunch tickets can be redeemed in the Exhibit Hall*



PROGRAM SCHEDULE

PRESIDENTIAL ADDRESS & LECTURE:
"THE INFLUENCE OF SPORTS ON MY SURGICAL PRACTICE"

1:00 PM – 1:30 PM



Introduction: Jürgen Schleef, MD

President: Jean-Stéphane Valla, MD

Professor of Pediatric Surgery, Head of the Surgical Department, Lenval Children's Hospital, Nice, France

UNIVERSITY TITLES

- 1972** Laureate of the Medical University of Lyon
Winner of the Concours de l'Internat (examination for residency)
- 1974** Instructor of Anatomy (University of Nice)
- 1975** Certificate (CES) of Anatomy and Embryology (Marseille)
- 1976** Certificate (CES) of Biomechanics (Montpellier)
- 1978** Certificate (CES) of Neuron-anatomy (Montpellier)
Medical Doctor of the University of Nice
Thesis price winner (Gold Medal)
- 1980** Certificate (CES) of General Surgery
Special Diploma (AEU) in Experimental Microsurgery (Lyon)
- 1981** Special Diploma (AEU) in Legal Compensation of Physical Damage (Lyon)
- 1982** Special licence in Pediatric Surgery
- 1990** Professor of Pediatric Surgery
- 2002** FRCS: Fellow of the Royal College Surgeons (London)

CAREER

- 1972-1978** Intern, Nice University Hospital
- 1978-1981** Resident in Pediatric Surgery at the University Hospital of Lyon (Prof. Jaubert De Beaujeu – Prof. Mollard)
- 1982-1989** Senior consultant, Lenval Foundation's Pediatric Hospital Nice, France
- 1990-1992** Chief of the Department of Pediatric Surgery, Nice University Hospital
- 1994** Chief of the Department of Pediatric Surgery, Lenval Foundation's Pediatric Hospital Nice.
- 1994-1998** President of the Medical Committee, Lenval Foundation

SCIENTIFIC ACTIVITIES

- Director of 15 medical thesis
- Contributor in 15 Medical books (6 French, 6 English, 2 Italian, 1 Brazilian)
- Contributor in 10 multi-center studies and initiator and director of 4 multi-center studies
- Co-Editor Endoscopic Surgery in Children (Springer Verlag 1999)
- Editor and Director of 40 videos on Pediatric Surgery
- Organized and Directed 4 medical congresses
- Chair, Pediatric Surgery Sessions (50 French and 38 International Congresses)
- Teacher and tutor of laparoscopic surgery at the following Universities: University of Strasbourg, Lille (France), Dundee (Scotland), Bologna (Italy), Turin (Italy), Siena (Italy), Tunis (Tunisia).
- Member of the Editorial Board of the *Journal for Pediatric Endosurgery and Innovative Techniques*.

PROFESSIONAL SOCIETIES

- Member of the French Association of Surgery (AFC)
- Member of the board of the French Society of Pediatric Surgery (SFCP)
- Founder member and President of the French Group of Pediatric Urology (GEUP)
- Founder member of a Southeast Group of Research and Bibliography in Pediatric Surgery (GRECPSE)
- Member of a Southeast Association of Foetal Medicine (SEMERA)
- Member of the European Association of Endoscopic Surgery (EAES)
- Member of the International Pediatric Endoscopic Group (IPEG)
- Member of the European Society of Pediatric Urology (ESPU)

PUBLICATIONS

140 publications in French, 40 publications in English

IPEG acknowledges our Diamond Level Donors for their support of this lecture: Karl Storz Endoscopy-America and Stryker Endoscopy

PANEL: HOW TO SET-UP AN ENDOSURGERY OR

1:30 PM – 2:45 PM

Chairs: Marc A. Levitt, MD & George W. Holcomb, MD

Panelists: George W. Holcomb, MD, Marc A. Levitt, MD, Steven S. Rothenberg, MD & Holger Till, MD

Advance Minimally Invasive Surgery (MIS): Set-up of the Case, Set-up of the Room, Set-up of the Staff, and Set-up of the Institution

IPEG acknowledges the following company for an educational grant in support of this panel: Karl Storz Endoscopy-America

PROGRAM SCHEDULE



SCIENTIFIC SESSION: ALL SHORT PAPERS

2:45 PM – 3:45 PM

Moderators: Hossein Allal, MD & David van der Zee, MD

TIME	TOPIC
2:45 pm – 2:50 pm	S029: Videothoroscopic Surgery for Vascular Rings in Children : Technical Considerations Piolat Christian, MD, Dyon Jean-François, MD, Teklali Youssef, MD, Durand Chantal, Llerena Catherine, Cartal Marielle, Wroblewski Isabelle, Pin Isabelle, Chu de Grenoble, France
2:50 pm – 2:55 pm	S030: Nuss Procedure in a Patient with Pectus Excavatum Associated with Accessory Diaphragm Manabu Okawada, MD, Tadaharu Okazaki, PhD, Akihiro Shimotakahara, MD, Geoffrey J. Lane, MD, Atsuyuki Yamataka, MD, Department of Pediatric General and Urogenital Surgery Juntendo University School of Medicine, Tokyo, Japan
2:55 pm – 3:00 pm	S031: How to Get a More Stable Bar in Pectus Repair. The Bilateral Endoclose Approach Michele Torre, MD, Patricio Varela, MD, Maria Victoria Romanini, MD, Vincenzo Jasonni, MD, Pediatric Surgery, G. Gaslini Institute, Genoa, Italy; Pediatric Surgery, Calvo Mackenna Hospital, Santiago, Chile
3:00 pm – 3:05 pm	S032: Laparoscopic Strategy for Inguinal Ovarian Hernias in Children: When to Operate Irreducible Ovary? Hiroo Takehara, MD, Jun Hanaoka, MD, Yusuke Arakawa, MD, Department of Pediatric Surgery & Pediatric Endosurgery, The Tokushima University Hospital
3:05 pm – 3:10 pm	S033: Comparative Study of Thoracoscopic Approach to Thoracotomy Approach in Oesophagus Atresia Allal Hossein, MD, Mailliet Olivier, MD, Kalfa Nicolas, MD, Forgues Dominique, MD, Galifer RB, PhD, Service de Chirurgie Viscerale Pédiatrique, CHU Lapeyronie, Montpellier
3:10 pm – 3:15 pm	S034: Laparoscopically Harvested Omental Flap for Recurrent Tracheo-Esophageal Fistula in Newborn Baby Arnaud A Bonnard, MD, Annabel A Paye-Jaouen, MD, Sophie S Aizenfisz, MD, Alaa A El Ghoneimi, PhD, Robert Debre Hospital and Paris VII University, APHP, Paris, France
3:15 pm – 3:20 pm	S035: Results and Complications of Thoracoscopy in Pleural Empyema : A Study of the GECEI (Groupe d'Etude en Coelioscopie Infantile) Jean Breaud, MD, Eric Fontas, MD, Carlos Giné-Prades, MD, M. Tambassa, MD, M. Demarche, MD, François Becmeur, MPH, F. Lefebvre, MD, F. Bastiani, MD, J.Y. Kurzenne, MD, University Hospital of Nice, Montpellier, Strasbourg, Liège (Belgium), Reims and GECEI
3:20 pm – 3:25 pm	V010: Combined Laparoscopic and Thoracoscopic Esophagectomy and Gastric Pull Up Nam Nguyen, MD, Fombe Ndiforchu, MD, Richard Mathis, MD, Michael Hayashi, MD, Cathy Shin, MD, Childrens Hospital of Los Angeles and Miller's Children Hospital, Long Beach CA
3:25 pm – 3:30 pm	V011: Thoracoscopic Patch Repair of a Right-Sided Congenital Diaphragmatic Hernia in a Neonate Sohail R. Shah, MD, George K. Gittes, MD, Katherine A. Barsness, MD, Timothy D. Kane, MD, Children's Hospital of Pittsburgh, University of Pittsburgh Medical Center
3:30 pm – 3:35 pm	V012 :Thoracoscopic Aortopexy – Case Presentation and Operative Technique Lena Perger, MD, Heung Bae Kim, MD, Bradley Linden, MD, Harvard Medical School, Children's Hospital Boston
3:35 pm – 3:40 pm	V013: Thoracoscopic Division of a Vascular Ring Ayed R. Alqahtani, MD, King Saud University, Riyadh, Saudi Arabia

POSTER TOURS – GROUP A (SUQUET ABC)

4:00 PM – 5:30 PM

Moderators: Ciro Esposito, MD, PhD, Maria Marcela Bailez, MD & Munther J. Haddad, MD

IPEG acknowledges our Platinum Level Donor for their support of the poster tour: Ethicon Endo-Surgery, Inc.



PROGRAM SCHEDULE

SATURDAY, JUNE 14, 2008

All Scientific Sessions take place in the Auditorium (Level: -1)

MORNING VIDEO SESSION: "MY FAVORITE TRICKS"

8:00 AM – 9:10 AM

Moderators: Marcelo H. Martinez Ferro, MD & Gordon A. MacKinlay, MD

DESCRIPTION

The topic is open and the objective is to have participants share their best "tricks" they use when performing minimal invasive surgery (MIS). For example: making knots, instrument use, trocar placement, special maneuvers, special positioning of the patient or of the surgeon, etc. Participants will have 3 minutes to present their video and/or power point presentation. This session will also include audience participation. *An award for best trick will be provided a la Cannes Film Festival!

OBJECTIVES

1. To promote the exchange of new ideas and techniques, that facilitates the development of minimally invasive surgery (MIS).
2. Promote the advancement of minimally invasive surgery (MIS) in Pediatrics.
3. To stimulate the development of new ideas and techniques outside the habitual scientific framework.

TIME	TOPIC
8:00 am – 8:08 am	V014: Thoracoscopic Repair of Neonatal Congenital Diaphragmatic Hernia <u>David Bliss, MD</u> , Sanjay Krishnaswami, MD, Oregon Health and Science University
8:08 am – 8:16 am	V015: Laparoscopic Repair of a Left Congenital Posterolateral Diaphragmatic Hernia in a 3 Week Old <u>David Bliss, MD</u> , Oregon Health and Science University
8:16 am – 8:24 am	V016: Endoscopically-guided, Thoracoscopic Esophagectomy for Stricture in a Child <u>Timothy D. Kane, MD</u> , Marcus Malek, MD, Aviva L. Katz, MD, Children's Hospital of Pittsburgh of UPMC
8:24 am – 8:32 am	V017: Laparoscopic Gastric Pull-up with Cervical Esophagogastric <u>Shawn D. St Peter, MD</u> , Daniel J. Ostlie, MD, Children's Mercy Hospital
8:32 am – 8:40 am	V018: Laparoscopically Assisted Gastric Transposition For Long-Gap Esophageal Atresia <u>Philipp O. Szavay, MD</u> , Hans Joachim Kirschner, MD, Tobias Luithle, MD, Joerg Fuchs, MD, Dept. of Pediatric Surgery, Children's Hospital, University of Tuebingen
8:40 am – 8:48 am	V019: Toracoscopic Management of Long-Term Complications After Repair of Congenital Tracheoesophageal Fistula in Children <u>Yuriy Sokolov, MD</u> , Sergei Yurkov, MD, Ildar Valiulov, MD, Russian Medical Academy of Postgraduate Education, Moscow, Children's Hospital № 15, Perm, Russia
8:48 am – 8:53 am	S036: Dual Localization Technique for Thoracoscopic Resection of Lung Lesions in Children <u>Abigail E. Martin, MD</u> , James Y. Chen, MD, Christopher S. Muratore, MD, William W. Mayo-Smith, MD, Francois I. Luks, MD, Alpert Medical School of Brown University and Hasbro Children's Hospital
8:53 am – 8:58 am	S037: Gastoscopic Assistant Surgical Management of Pyriform Snius Fistula in Children <u>LV Zhibao, MD</u> , Xiao Xianmin, MD, Zheng Shan, MD, Department of Surgery, Children's Hospital, Medical Center of Fudan University
8:58 am – 9:03 am	S038: Microlaparoscopic Assisted Gastrostomy in Children – our technique <u>Salmai Turial, MD</u> , <u>Martin Schwind, MD</u> , Veronika Engel, MD, Cordula Scherer, MD, Walid Treef, MD, Felix Schier, MD, Department of Pediatric Surgery, University Medical Center Mainz
9:03 am – 9:08 am	S039: Age + 10: A Simple and Reliable Formula for Proper JJ Stent length in the Pediatric Patient <u>Jeffrey S. Palmer, MD</u> , Lane S. Palmer, MD, Glickman Urological and Kidney Institute, Cleveland Clinic Children's Hospital, Cleveland, Ohio, USA; Schneider Children's Hospital, North Shore-Long Island Jewish Health System, New Hyde Park, New York, USA

PROGRAM SCHEDULE



UROLOGY PANEL: UPJ OBSTRUCTION – WHERE DO WE STAND? 9:10 AM – 10:15 AM

Chairs: Alaa El Ghonemi, MD & C.K. Yeung, MD

TIME	TOPIC	FACULTY
9:15 am – 9:55 am	Panel Discussion	Lars Henning Olsen & Marc-David Leclair, MD
9:55 am – 10:00 am	V020: Laparoscopic Dismembered Pyeloplasty in a Child with a Relatively Inaccessible Intrarenal Pelvis Hannu Lintula, MD, Hannu Kokki, MD, Kari Vanamo, MD, Kuopio University Hospital, Kuopio, Finland	
10:00 am – 10:05 am	V021: Primary Laparoscopic Ureterocalicostomy in a Pediatric Patient Alex W. Caillat, MD, Paul H. Noh, MD, Cincinnati Children's Hospital Medical Center, University of Cincinnati	
10:05 am – 10:15 am	Questions/Discussion	

BREAK (EXHIBIT HALL/MEDITERANÉE) 10:15 AM – 10:45 AM

SCIENTIFIC SESSION: UROLOGY 10:45 AM – 11:45 AM

Moderators: Azad S. Najmaldin, MD & Jean-Stéphane Valla, MD

TIME	TOPIC
10:45 am – 10:54 am	S040: Fast-Track Laparoscopic Surgery of the Kidney and Renal Pelvis Marc Reismann, MD, Jens Dingemann, MD, Mirja von Kampen, Mathias Wolters, Martin L. Metzelder, MD, Robert Suempelmann, PhD, Benno M. Ure, PhD, Department of Pediatric Surgery and Department of Anesthesiology, Hannover Medical School
10:54 am – 11:03 am	S041: Laparoscopic Procedures in Pediatric Gynecology Igor V. Poddoubnyi, MD, Tatiana M. Glybina, MD, Andrei A. Isaev, MD, Alexei B Okulov, MD, Elena V. Fedorova, MD, Moscow State University of Medicine and Dentistry, Department of Pediatric Surgery
11:03 am – 11:08 am	S042: Videocystoscopic Ureteral Reimplantation Using Regular Trocars A Prospective Comparative Study Edward Esteves, MD, Bernardina B. Modesto, MD, Jose Ferreira-Silva, MD, Claudia M. Salgado, PhD, Pediatric Surgery Division, University of Goias, Brazil
11:08 am – 11:13 am	S043: Laparoscopic Dismembered Pyeloplasty by a Transabdominal Approach in Infants Qiangsong Tong, MD, Shaotao Tang, MD, Yongzhong Mao, MD, Yong Wang, MD, Qinglan Ruan, MD, Department of Pediatric Surgery, Union Hospital of Tongji Medical College, China
11:13 am – 11:18 am	S044: Laparoscopic Insertion with Tip Suturing, Omentectomy and Ovariopexy Improves Lifespan of Peritoneal Dialysis Catheters in Children A. Numanoglu, MD, L. Rasche, MD, M. Roth, MD, M. I. McCulloch, MD, H. Rode, MD, Departments of Paediatric Surgery and Nephrology, Red Cross Children's Hospital and University of Cape Town, South Africa
11:18 am – 11:23 am	S045: Retroperitoneoscopic Upper-pole Nephroureterectomy in Young Children with Duplex Systems S. Alhindi, M. Asgar, Salmaniya
11:23 am – 11:31 am	V022: Technique of Laparoscopic Transperitoneal Lower Pole Hemi-Nephroureterectomy Anies Mahomed, MD, James Lewis, Department of Paediatric Surgery, Royal Alexandra Children's Hospital, & Department of Medical Illustrations, Brighton, UK
11:31 am – 11:36 am	S046: Surgery of Deferential Reflux in Pediatric Varicocele Based on Preoperative Color Doppler Ultrasound Assessment M. Cimador, MD, Maria R. Di Pace, MD, P. Catalano, MD, M. Sergio, MD, M. Castagnetti, MD, E. De Garzia, MD, Dept. of Mother & Child, University of Palermo, Italy
11:36 am – 11:41 am	S047: Pneumovesicoscopic Marsupialisation of Complicating Ectopic Ureterocele Causing Bladder Outlet Obstructions in Young Infants Jennifer Sihoe, MD, K.H. Lee, MD, Division of Paediatric Surgery and Paediatric Urology, Department of Surgery, Chinese University of Hong Kong, Prince of Wales Hospital, Hong Kong SAR, China



PROGRAM SCHEDULE

SCIENTIFIC SESSION: ROBOTICS & EMERGING TECHNOLOGY 11:45 AM – 12:45 PM

Moderators: Douglas C. Barnhart, MD & Sanjeev Dutta, MD

TIME	TOPIC
11:45 am – 11:50 am	S048: Multipolar, Water-Cooled, Radiofrequency Induced Thermotherapy with 3-D Impedance Feedback – Prospective Study to Optimize Laparoscopic Subtotal 90% Splenectomy for Spherocytosis and ITP <u>Klaus Schaarschmidt, PhD</u> , Andreas Kolberg-Schwerdt, MD, Michael Lempe, MD, Frank Schlesinger, MD, Martina Hüging, MD, Jan Patino Mayer, MD, Helios Center for Pediatric & Adolescent Surgery, Berlin-Buch, Germany
11:50 am – 11:55 am	S049: Initial Experience with Surgical Telementoring in Laparoscopic Surgery Using Remote Presence Technology Steven S. Rothenberg, MD, Suzanne Yoder, MD, Sandra Kay, BA, Todd Ponsky, Rocky Mountain Hospital for Children
11:55 am – 12:00 pm	S050: Workflow Analysis of Laparoscopic Nissen Fundoplication in Infant Pigs - A Model for Surgical Feedback and Training <u>Alexandra Krauss</u> , Oliver J. Muensterer, PhD, Thomas Neumuth, BS, Robin Wachowiak, MD, Bernd Donaubauer, MD, Werner Korb, PhD, Oliver Burgert, PhD, Departments of Pediatric Surgery and Anesthesiology/Intensive Care Medicine, University of Leipzig; ICCAS, Innovation Center Computer Assisted Surgery, Leipzig
12:00 pm – 12:05 pm	S051: Feasibility of Minimal Invasive Surgery in Neonates C. K. Sinha, MS, S. Paramalingam, MS, M. Davenport, MS, S. Patel, MS, N. Ade-Ajayi, King's College Hospital, London, UK
12:05 pm – 12:13 pm	V023: Robotic Repair of Congenital Paraesophageal Hiatal Hernia <u>Daniel A. DeUgarte, MD</u> , James B. Geiger, MD, Ronald Hirschl, University of Michigan, Ann Arbor; UCLA, Los Angeles
12:13 pm – 12:22 pm	S052: Robotic Surgery for Infants and Small Children: Is there room for this? <u>John J. Meehan, MD</u> , Laura A. Phearman, RN, Seattle Children's Hospital & Regional Medical Center, Children's Hospital of Iowa
12:22 pm – 12:30 pm	V024: Robotic Resection of a Mediastinal Teratoma <u>Bethany J. Slater, MD</u> , Laura Phearman, MD, John J Meehan, MD, Seattle Children's Hospital & Regional Medical Center, University of Iowa Children's Hospital, Lucille Packard Children's Hospital
12:30 pm – 12:35 pm	S053: Surgical Performance with Head-Mounted Displays in Laparoscopic Surgery <u>Christopher J. Prendergast, BS</u> , Beth A. Ryder, MD, Adam Abodeely, MD, Gregory P. Crawford, PhD, Francois I. Luks, MD, Alpert Medical School of Brown University and Hasbro Children's Hospital
12:35 pm – 12:40 pm	S054: Telesimulation: An Innovation in Teaching Laparoscopic Skills in Africa <u>Georges Azzie, MD</u> , Allan Okrainec, MD, Hospital for Sick Children, Toronto, Canada

PANEL: QUO VADIS MIS? "WHERE ARE WE GOING WITH MIS?" 12:45 PM – 1:45 PM (LONG-GAP ESOPHAGEAL ATRESIA, DUODENAL ATRESIA)

Chairs: Klaas (N) MA Bax, MD & Thom E. Lobe, MD

TIME	TOPIC	FACULTY
12:45 pm – 1:05 pm	Thoracoscopic Repair of Esophageal Atresia without Distal Fistula	Steven S. Rothenberg, MD
1:05 pm – 1:25 pm	Laparoscopic Repair of Duodenal Atresia, Web, and Stenosis.	George W. Holcomb, III, MD
1:25 pm – 1:40 pm	Survey Summary	Klaas (N) MA Bax, MD
1:40 pm – 1:45 pm	S020: Laparoscopic Gastric Pull-Up for Long Gap Esophageal Atresia Edward Esteves, MD, Bernardina B. Modesto, MD, Chagas C. Celio, MD, Kelly C. Paiva, MD, Marcelo Calcagno, MD, Pediatric Surgery Division, University of Goias, Brazil	

PROGRAM SCHEDULE



LUNCH BREAK (EXHIBIT HALL/MEDITERANÉE)

1:45 PM – 2:30 PM

**Pre-purchased box lunch tickets can be redeemed in the Exhibit Hall*

KEYNOTE LECTURE:

2:30 PM – 3:00 PM

"CLIMATE CHANGE AND INCREASED LONGEVITY: TWO MAJOR DRIVERS CHALLENGING THE FUTURE OF THE INSURANCE INDUSTRY"



Introduction: Jürgen Schleef, MD

Guest Speaker: Sergio Balbinot

Co-Chief Executive Officer, Assicurazioni Generali

EDUCATION

1982 Graduation in Economics, 6-month Scholarship at the European Community in Brussels, Belgium.

CAREER

1983-1989 Insurance-Operations Department

1989-1992 Head of the Swiss Branch

1992-1995 Head of the International Activity of Europe Assistance

1995-1996 Area Manager for the German-Speaking Countries and France

1996-1998 Assistant General Manager and Head of the Group-Insurance Operations

1998-2002 Deputy General Manager

2002-present Co-Chief Executive Officer, Assicurazioni Generali

DEPUTY CHAIRMAN OF THE BOARD OF DIRECTORS FOR THE FOLLOWING COMPANIES

- Generali España, Holding the Entidades de Seguros, S.A., Madrid
- Generali Holding Vienna AG, Vienna
- Generali France S.A., Paris
- Generali China Life Insurance Co. Ltd, Canton

MEMBER OF THE BOARD OF DIRECTORS FOR THE FOLLOWING COMPANIES

- Generali (Schweiz) Holding, Adliswil
- Europe Assistance Holding, Paris
- Generali Finance B.V., Diemen
- Graafschap Holland Participate Maatschappij N.V., Diemen
- Generali Asia N.V., Diemen
- AMB Generali Holding AG, Aachen
- Aachener und Münchener Versicherung AG, Aachen
- Commerzbank AG, Frankfurt
- Banco Vitalicio de España, Barcelona
- La Estrella S.A., Madrid
- Migdal Insurance Holding Ltd., Tel Aviv
- Migdal Insurance & Finance Holding, Tel Aviv
- Transocean Holding Corporation, New York

PANEL: INTERVENTIONAL RADIOLOGY

3:00 PM – 4:00 PM

Chairs: Sanjeev Dutta, MD & John Meehan, MD

TIME	TOPIC	FACULTY
3:00 pm – 3:20 pm	Lung sequestration: Embolisation vs. MIS	John Meehan, MD vs. Klaus Schaarschmidt
3:20 pm – 3:25 pm	Questions/Discussion	
3:25 pm – 3:45 pm	Biliary Diseases and Post Liver Transplant Complications	Danièle Pariente, MD vs. Philippe Montupet, MD
3:45 pm – 3:50 pm	Questions/Discussion	
3:50 pm – 3:55 pm	S055: Advanced CT and XperCT Guided Minimally Invasive Bone Interventional Procedures Neil D. Johnson, MD, John Racadio, MD, Cincinnati Children's Hospital	



PROGRAM SCHEDULE

BASIC SCIENCE SESSION

4:00 PM – 5:00 PM

Moderators: Thomas H. Inge, MD & Thom E. Lobe, MD

TIME	TOPIC
4:00 pm – 4:09 pm	S056: The Impact of Intraoperative Hypercapnea or Hypercarbia on Neonates Undergoing Thoracoscopic Repair of Diaphragmatic Hernia of Bochdalek <u>David Bliss, MD</u> , Julie McKee, RN, Sanjay Krishnaswami, MD, Legacy Emanuel Children's Hospital
4:09 pm – 4:14 pm	S057: The Inflammatory Response is No Different in Children Randomized to Laparoscopic or Open Appendectomy - But Laparoscopic Patients Go Home Earlier <u>Philipp Simon</u> , Oliver J. Muensterer, PhD, Ulrich Sack, PhD, Ullrich Burkhardt, PhD, Departments of Pediatric Surgery, Anesthesia, and Clinical Immunology, University of Leipzig
4:14 pm – 4:19 pm	S058: Anatomical Variations of Medial Umbilical Ligament: Does It Have Any Clinical Significance? <u>Baran Tokar, MD</u> , Ferruh Yucel, MD, Eskisehir Osmangazi University, School of Medicine, Department of Pediatric Surgery and Anatomy, Eskisehir, Turkey
4:19 pm – 4:28 pm	S059: Thoracoscopic Repair of Large Diaphragmatic Hernias: Direct Closure versus Surgisis-patch Interposition – A Prospective Experimental Study in Young Pigs <u>Klaus Schaarschmidt, PhD</u> , Andreas Kolberg-Schwerdt, MD, Michael Lempe, MD, Frank Schlesinger, MD, Jan Patino-Mayer, MD, Dennis Goldmann, MD, Helios Center for Pediatric & Adolescent Surgery, Berlin-Buch, Germany
4:28 pm – 4:33 pm	S060: Locking Sliding Knots for Neonatal Minimally Invasive Surgery: Experimental Studies <u>B. Banieghbal, MD</u> , Department of Pediatric Surgery, Johannesburg General Hospital, Johannesburg, South Africa
4:33 pm – 4:42 pm	S061: The Effects of CO2 Pneumoperitoneum on Livers with Biliary Atresia in an Animal Model <u>Pablo Laje, MD</u> , Fred H. Clark, PhD, Joshua R. Friedman, MD, Alan W. Flake, MD, The Children's Hospital of Philadelphia
4:42 pm – 4:47 pm	S062: The Use of LigeSure on Bile Duct in Rats. Experimental Study <u>Antonio Marte, MD</u> , Maria Domenica Sabatino, MD, Micaela Borrelli, MD, Biagio Del Balzo, MD, Fabiano Nino, MD, Maurizio Prezioso, MD, Pio Parmeggiani, PhD, Paediatric Surgery of Second University of Naples
4:47 pm – 4:52 pm	S063: Fetoscopic Surgery of Extremity Amniotic Bands: Limb Salvage by Intrauterine Band Release in Fetal <u>Carlos Giné, MD</u> , José Luis Peiró, MD, Francisco Soldado, MD, Mario Aguirre, MD, César G. García Fontecha, MD, Marieli Esteves, PhD, Vicente Martínez Ibáñez, MD, Fetal Surgery Research Group, Vall d'Hebron Hospital, Barcelona, Spain
4:52 pm – 5:01 pm	S064: Cardia Yield Pressure Before and After Laparoscopic Fundoplication in an Infant Pig Model <u>Robin Wachowiak, MD</u> , Alexandra Krauss, Bernd Donaubaue, MD, Oliver J. Muensterer, PhD, Departments of Pediatric Surgery and Anesthesia, University of Leipzig

POSTER TOUR: GROUP B (SUQUET ABC)

5:00 PM – 6:30 PM

Moderators: Girolamo Mattioli, MD, Edward Esteves, MD & Atsuyuki Yamataka, MD,

IPEG acknowledges our Platinum Level Donor for their support of this poster tour: Ethicon Endo-Surgery, Inc.

MAIN EVENT: COCKTAIL DINNER & DANCING (PALAIS STÉPHANIE/ROOF TOP)

7:00 PM – 10:30 PM

PROGRAM SCHEDULE



SUNDAY, JUNE 15, 2008

ONCOLOGY PANEL: 8:00 AM – 9:00 AM
DOES ENDOSURGERY CHANGE THE PARADIGMA IN ONCOLOGY?

Chairs: Tadashi Iwanaka, MD & Kathy Pritchard-Jones, MD

TIME	TOPIC	FACULTY
8:00 am – 8:09 am	S065: Resection of Neurogenic Tumors in Children Using Thoracoscopic Approach <u>Ramanath N. Haricharan, MD</u> , Jacqueline M. Saito, MD, Douglas C. Barnhart, MD, University of Alabama at Birmingham	
8:09 am – 8:14 am	S066: Thoracoscopic Resection of a Pulmonary Mestastasis Less Than 1 cm in Size Utilizing preoperative CT-Guided Wire Localization: A Case Report <u>Silvana Federici, MD</u> , Alberto Ratta, MD, Lorenzo De Biagi, MD, Ilvana Federici, MD, Maurizio Mordenti, MD, Vincenzo Domenichelli, MD, Gabriella Pelusi, MD, Francesco Italiano, MD, Pediatric Surgery Unit-Infermi Hospital, Rimini, Italy. * S067 – (Abstract withdrawal)	
8:14 am – 8:19 am	S068: CT Guided Needle-Wire Localization for Thoracoscopic Resection of Small Pulmonary Nodules <u>John M. Racadio, MD</u> , Kamlesh U. Kukreja, MD, Shane J. McGonegle, MD, Manish N. Patel, DO, Neil D. Johnson, MD, Cincinnati Children's Hospital Medical Center, Cincinnati Ohio, USA	
8:19 am – 8:29 am	Abdominal Neuroblastoma	Tadashi Iwanaka, MD
8:29 am – 8:39 am	Renal Tumors	François Varlet, MD
8:39 am – 8:49 am	Lung Mestasis	Dominique H. Grunenwald, MD
8:49 am – 9:00 am	Questions /Discussion	

SCIENTIFIC SESSION: THORAX 9:00 AM – 10:00 AM

Moderators: Miguel Guelfand, MD & Steven S. Rothenberg, MD

TIME	TOPIC
9:00 am – 9:09 am	S069: Prior Thoracic Surgery Has a Limited Impact on the Feasibility of Consecutive Thoracoscopy in Children: A Prospective Study <u>Martin L. Metzelder, MD</u> , Joachim F. Kuebler, MD, Marc Reismann, MD, Taiwo A. Lawal, MD, Sylvia Glueer, PhD, Benno M. Ure, PhD, Department of Pediatric Surgery, Hannover Medical School, Hannover, Germany
9:09 am – 9:18 am	S070: Early Thoracoscopic Surgery for Sequestration Associated with Cystic Adenomatoid Malformation <u>Smart Zeidan, MD</u> , Geraldine Hery, MD, Frederic Lacroix F, MD, Alain Potier, MD, Guillaume Gorincourt, MD, Jean Christophe Dubus, PhD, Jean Michel Guys, PhD, Pascal de Lagausie, PhD, Hôpital la Timone, Marseille, France
9:18 am – 9: 27 am	S071: Laparoscopic Esophagectomy in Esophageal Replacement Surgery <u>Olivier Reinbeg, MD</u> , Department of Pediatric Surgery, University Hospital Center and University of Lausanne, Switzerland
9:27 am – 9:32 am	S072: Minimal Invasive Management of Children with Caustic Ingestion: Less Pain for Patients <u>Burak Tander, MD</u> , Unal Bicakci, MD, Ender Ariturk, MD, Riza Rizalar, MD, Suat H. Ayyildiz, MD, Ferit Bernay, MD, Ondokuz Mayis University, Department of Pediatric Surgery
9:32 am – 9:41 am	S073: Thorascopic Foker Technique for Long gap Esophageal Atresia <u>H. Edward Esteves, MD</u> , Denny C Lima, MD, Bernardina B Carvalho, MD, Pediatric Surgery Division, University of Goias, Brazil
9:41 am – 9:46 am	S074: Thoracoscopic Repair of Tracheoesophageal Fistula and Esophageal Atresia <u>Dariusz Parkowski, PhD</u> , Konrad Rysiakiewicz, MD, Wojciech Jaworski, PhD, Marzena Zielinska, PhD, Grazyna Siejka, MD, Jerzy Czernik, PhD, Department of Paediatric Surgery and Urology, Medical University of Wroclaw



PROGRAM SCHEDULE

9:46 am – 9:51 am	S075: Thorascopy in Children: Is a Chest Tube Necessary? <u>Todd A. Ponsky, MD</u> , Shawn St. Peter, MD, Daniel Ostlie, MD, KuoJen Tsao, MD, George W. Holcomb, III, MD, Steven S. Rothenberg, MD, Rocky Mountain Hospital for Children, Denver, CO, USA, Children's Mercy Hospital, Kansas City, MO, USA
9:51 am – 9:56 am	S076: Extra-Pleura Nuss Procedure for the Correction of Pectus Excavatum in Children <u>Shu-li Liu, PhD</u> , Long Li, MD, Wen-Ying Hou, MD, Department of Pediatric Surgery, Peking University First Hospital

BREAK (AUDITORIUM)	10:00 AM – 10:30 AM
--------------------	---------------------

GENERAL ASSEMBLY	10:30 AM – 11:30 AM
------------------	---------------------

Moderator: Jean-Stéphane Valla, MD

SCIENTIFIC SESSION: LONG TERM RESULTS – IS THERE A BENEFIT?	11:30 AM – 12:30 PM
--	---------------------

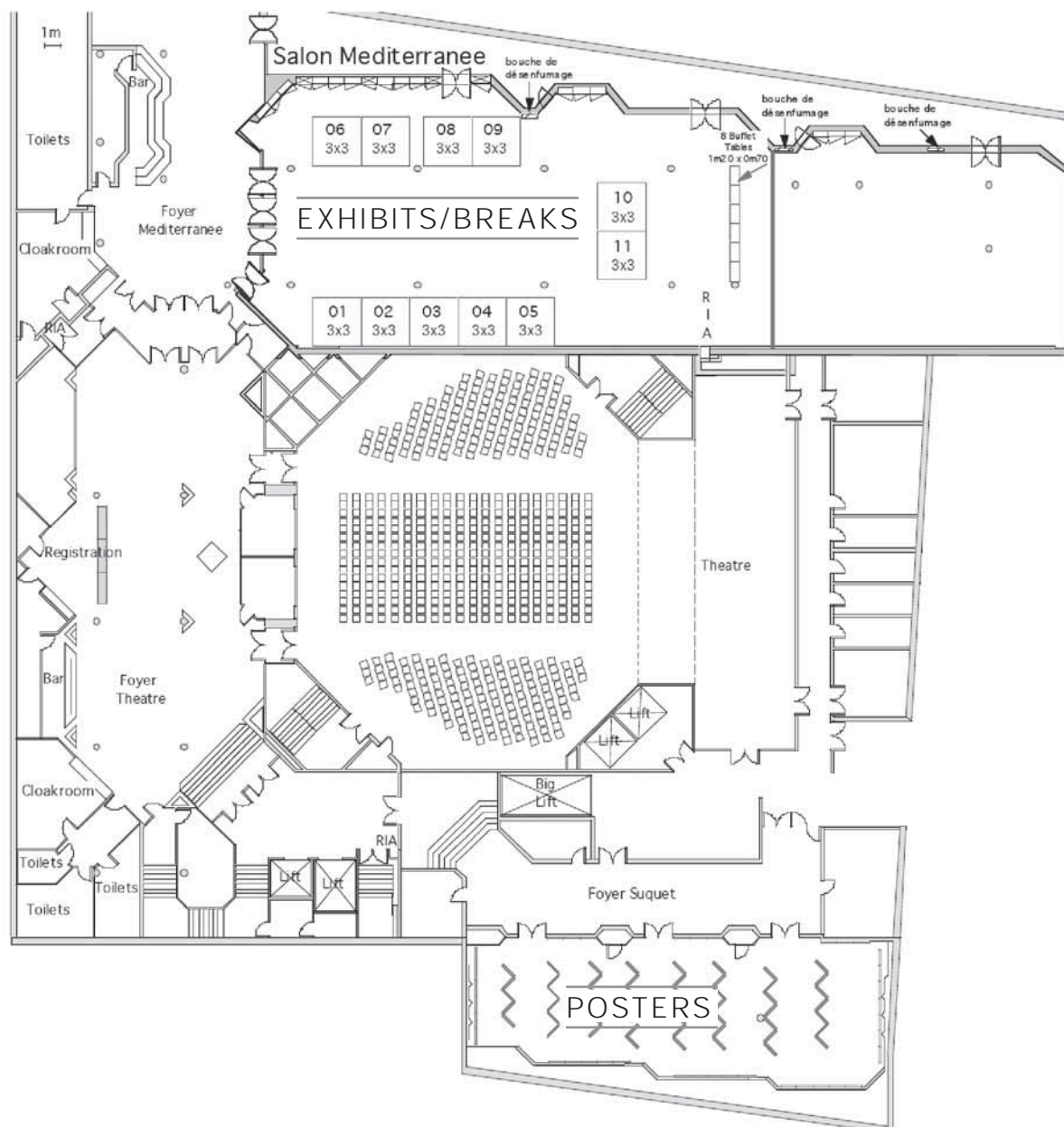
Chairs: Jürgen Schlee, MD & Mark Davenport, MD

TIME	TOPIC
11:30 am – 11:39 am	S077: Long Term Outcome of Fowler –Stephens Prchiopexy in Boys with Intra-Abdominal Testes <u>Ciro Esposito, MD</u> , Maria Rosaria Nugnes, MD, Francesca Alicchio, MD, Flavio Perricone, MD, Antonio Savanelli, MD, Gianfranco Vallone, MD, Alessandro Settini, Department of Pediatrics, Federico II University, Naples, Italy
11:39 am – 11:44 am	S078: Long Term Outcome of Endoscopic Approach Ureterocele in Children Antonio Savanelli, MD, Francesca Alicchio, MD, Ciro Esposito, MD, Flavio Perricone, MD, Alessandra Farina, MD, Alessandro Settini, MD, Dept of Pediatrics, Federico II University of Naples, Italy
11:44 am – 11:49 am	S079: Is There an Age Discrepancy for Utilization of Advanced Laparoscopy? A National Study of Fundoplication and Gastric Bypass Trends and Outcomes <u>John Morton, MD</u> , Sanjeev Dutta, MD, Tina Hernandez-Boussard, PhD, Craig Albanese, MD, Lucile Packard Children's Hospital and Stanford School of Medicine
11:49 am – 11:54 am	S080: Bowel Function After Laparoscopic Assisted Anorectoplasty for the Male Patients with High and Intermediate Type Imperforate Anus Makoto Yagi, PhD, Takeo Yonekura, PhD, Takuya Kosumi, RN, Hiroshi Yoshida, PhD, Takashi Nogami, PhD, Hideki Yoshida, MD, Division of Pediatric Surgery, Department of Surgery, Kinki University School of Medicine
11:54 am – 12:03 pm	S081: Long Term Functional Evaluation of Fecal Continence After Laparoscopic Assisted Pull Through for High Anorectal Malformations <u>Mohamed S El-Debeiky, MD</u> , H. A. Safan, MD, I. A. Shafei, MD, H. A. Kader, MD, Sameh A. Hay, MD, Pediatric Surgery Department, Ain Shams University, Cairo, Egypt
12:03 pm – 12:08 pm	S082: National Trends and Outcomes for Pediatric Laparoscopic and Open Appendectomy and Cholecystectomy: 1998-2005 <u>John Morton, MD</u> , Sanjeev Dutta, MD, Tina Hernandez-Boussard, PhD, Craig Albanese, MD, Lucile Packard Children's Hospital and Stanford School of Medicine
12:08 pm – 12:30 pm	Faculty Discussion

CLOSING REMARKS & PRESENTATION OF 2009 PRESIDENT	12:30 PM – 1:00 PM
--	--------------------

Jürgen Schlee MD (2008 IPEG Program Chair), Thomas H. Inge, MD (2008 IPEG Program Co-Chair)
& Jean-Stéphane Valla, MD (2008 IPEG President)

EVENTS FLOORPLAN





FACULTY & PAST PRESIDENTS

FACULTY

Hossein Allal, MD – <i>Montpellier, FRANCE</i>	Gordon A. MacKinlay, MD – <i>Edinburgh, Scotland, UK</i>
Aayad Al Qahtani, MD – <i>Riyadh, SAUDI ARABIA</i>	Marcelo H. Martinez Ferro, MD – <i>Olivos, Buenos Aires, ARGENTINA</i>
Maria Marcela Bailez, MD – <i>Buenos Aires, ARGENTINA</i>	Girolamo Mattioli, MD – <i>Genova, ITALY</i>
Behrouz Banieghbal, MD – <i>Johannesburg, SOUTH AFRICA</i>	John Meehan, MD – <i>Seattle, Washington, USA</i>
Douglas C. Barnhart – <i>Birmingham, Alabama, USA</i>	Philippe Montupet, MD – <i>Paris, FRANCE</i>
Klaas (N) MA Bax, MD – <i>Rotterdam, THE NETHERLANDS</i>	Azad S. Najmaldin, MD – <i>Leeds, England, UK</i>
Mark Davenport, MD – <i>London, England, UK</i>	Lars Henning Olsen, MD – <i>Aarhus, DENMARK</i>
Sanjeev Dutta, MD – <i>Stanford, California USA</i>	Danièle Pariente, MD – <i>Le Kremlin Bicêtre, FRANCE</i>
Alaa El-Ghonemi, MD – <i>Paris, FRANCE</i>	Kathy Pritchard-Jones, MD – <i>Sutton, England, UK</i>
Ciro Esposito, MD – <i>Naples, ITALY</i>	Steven S. Rothenberg, MD – <i>Denver, Colorado, USA</i>
Edward Esteves, MD – <i>Goiania, BRAZIL</i>	Klaus Schaarschmidt, MD – <i>Berlin, GERMANY</i>
Dominique H. Grunenwald, MD – <i>Paris, FRANCE</i>	Jürgen Schleef, MD – <i>Trieste, ITALY</i>
Miguel A. Guelfand, MD – <i>Santiago, CHILE</i>	Henri Steyaert, MD – <i>Nice, FRANCE</i>
Munther J. Haddad, MBBCH, FRCS – <i>London, England, UK</i>	Holger Till, MD – <i>Leipzig, GERMANY</i>
Carroll M. Harmon, MD – <i>Birmingham, Alabama, USA</i>	Benno M. Ure, MD – <i>Hannover, GERMANY</i>
George W. Holcomb III, MD – <i>Kansas City, Missouri, USA</i>	Jean-Stéphane Valla, MD – <i>Nice, FRANCE</i>
Thomas H. Inge, MD – <i>Cincinnati, Ohio, USA</i>	David C. van der Zee, MD – <i>Utrecht, THE NETHERLANDS</i>
Tadashi Iwanaka, MD – <i>Tokyo, JAPAN</i>	François Varlet, MD – <i>St. Etienne, FRANCE</i>
Marc-David LeClair, MD – <i>Nantes, FRANCE</i>	Atsuyuki Yamataka, MD – <i>Tokyo, JAPAN</i>
Marc A. Levitt, MD – <i>Cincinnati, Ohio, USA</i>	C.K. Yeung, MD – <i>Hong Kong, CHINA</i>
Thom E. Lobe, MD – <i>Des Moines, Iowa, USA</i>	

IPEG PAST PRESIDENTS

Atsuyuki Yamataka, MD (2007)	Peter Borzi, MD (2001)
Keith E. Georgeson, MD (2006)	Steven S. Rothenberg, MD (2000)
Klaas (N) MA Bax, MD (2005)	John HT. Waldschmidt, MD (1999)
C.K. Yeung, MD (2004)	Hock Lim Tan, MD (1998)
Craig T. Albanese, MD (2003)	Gunter-Heinrich Willital, MD (1995)
Vincenzo Jasonni, MD (2002)	

EXECUTIVE COMMITTEE

<i>President:</i> Jean-Stéphane Valla, MD	<i>Journal Editor:</i> Thom E. Lobe, MD
<i>President Elect:</i> George W. Holcomb III, MD	<i>Asia/Africa Representative:</i> Tadashi Iwanaka, MD
<i>1st Vice President:</i> Behrouz Banieghbal, MD	<i>European Representative:</i> Benno Ure, MD
<i>2nd Vice President:</i> Gordon A. MacKinlay, MD	<i>Americas Representative:</i> Marc A. Levitt, MD
<i>Secretary:</i> Marcelo H. Martinez Ferro, MD	<i>Past President:</i> Atsuyuki Yamataka, MD
<i>Treasurer:</i> Thomas H. Inge, MD	

2008 IPEG FACULTY



Hossein Allal, MD
Montpellier, France



Aayad Al Qahtani, MD
Riyadh, Saudi Arabia



Maria Marcela Bailez, MD
Buenos Aires, Argentina



Behrouz Banieghbal, MD
Johannesburg, South Africa



Douglas C. Barnhart
Birmingham, Alabama, USA



Klaas (N) MA Bax, MD
Rotterdam, The Netherlands



Mark Davenport, MD
London, England, UK



Sanjeev Dutta, MD
Stanford, California, USA




Alaa El-Ghonemi, MD
Paris, France



Ciro Esposito, MD
Naples, Italy



Edward Esteves, MD
Goiania, Brazil



Dominique H. Grunenwald, MD
Paris, France



Miguel A. Guelfand, MD
Santiago, Chile



Munther J. Haddad, MBBCH, FRCS
London, England, UK




Carroll M. Harmon, MD
Birmingham, Alabama, USA



George W. Holcomb III, MD
Kansas City, Missouri, USA



2008 IPEG FACULTY



Thomas H. Inge, MD
Cincinnati, Ohio, USA



Tadashi Iwanaka, MD
Tokyo, Japan



Marc-David LeClair, MD
Nantes, France



Marc A. Levitt, MD
Cincinnati, Ohio, USA



Thom E. Lobe, MD
Des Moines, Iowa, USA



Gordon A. MacKinlay, MD
Edinburgh, Scotland, UK



Marcelo H. Martinez Ferro, MD
Olivos, Buenos Aires, Argentina



Girolamo Mattioli, MD
Genova, Italy



John Meehan, MD
Seattle, Washington, USA




Philippe Montupet, MD
Paris, France



Azad S. Najmaldin, MD
Leeds, England, UK



Lars Henning Olsen, MD
Aarhus, Denmark



Danièle Pariente, MD
Le Kremlin Bicêtre, France



Kathy Pritchard-Jones, MD
Sutton, England, UK



Steven S. Rothenberg, MD
Denver, Colorado, USA



Klaus Schaarschmidt, MD
Berlin, Germany

2008 IPEG FACULTY



Jürgen Schleeß, MD
Trieste, Italy



Henri Steyaert, MD
Nice, France



Holger Till, MD
Leipzig, Germany



Benno M. Ure, MD
Hannover, Germany



Jean-Stéphane Valla, MD
Nice, France



David C. van der Zee, MD
Utrecht, The Netherlands



François Varlet, MD
St. Etienne, France



Atsuyuki Yamataka, MD
Tokyo, Japan




C.K. Yeung, MD
Hong Kong, China



FACULTY DISCLOSURES

NAME	DISCLOSURE	WHAT WAS RECEIVED	FOR WHAT ROLE(S)?
Hossein Allal, MD	Nothing to disclose		
Aayed Alqahtani, MD	Nothing to disclose		
Maria Marcela Bailez, MD	Nothing to disclose		
Sergio Balbinor, MD	Nothing to disclose		
Behrouz Banieghbal, MD	Neatstitch Netcare SA	Stock Interest Stock Interest	Ownership Independent Contractor
Douglas Barnhart	Nothing to disclose		
Klaas (N) MA Bax, MD	Nothing to disclose		
Guy-Bernard Cadiere, MD	Nothing to disclose		
Mark Davenport, MD	Nothing to disclose		
Sanjeev Dutta, MD	Nothing to disclose		
Alaa El-Ghoneimi, MD	Nothing to disclose		
Ciro Esposito, MD	Nothing to disclose		
Edward Esteves, MD	Nothing to disclose		
Dominique H. Grunenwald, MD	Nothing to disclose		
Miguel, A. Guelfand, MD	Nothing to disclose		
Munther, J. Haddad, MD	Nothing to disclose		
Carroll, M. Harmon, MD	Nothing to disclose		
George, W. Holcomb, MD	Nothing to disclose		
Thomas H. Inge, MD	Ethicon	Grant Support	Grant Support
Tadashi Iwanaka, MD	Nothing to disclose		
Marc-David Leclair, MD	Nothing to disclose		
Marc A. Levitt, MD	Nothing to disclose		
Thom E. Lobe, MD	Neatstitch UMS	Ownership Ownership	Stock Holder Partner
Gordon A. MacKinlay, MD	Nothing to disclose		
Marcelo H. Martinez Ferro, MD	Nothing to disclose		
Girolamo Mattioli, MD	Nothing to disclose		
John Meehan, MD	Nothing to disclose		
Philippe Montupet, MD	Nothing to disclose		
Azad S. Najmaldin, MD	Nothing to disclose		
Lars Henning Olsen, MD	Nothing to disclose		
Daniele Pariente, MD	Nothing to disclose		
Kathy Pritchard-Jones, MD	Roche	Honorarium	Attending Advisory Board
Steven S. Rothenberg, MD	Karl Storz Covidien	Consulting Fee Honorarium	Consulting Speaking and Teaching
Klaus Schaarschmidt, MD	Nothing to disclose		
Juergen Schleef, MD	Nothing to disclose		
Henri Steyaert, MD	Nothing to disclose		
Holger Till, MD	Nothing to disclose		
Benno M. Ure, MD	Aesculap	Honorarium	Teaching
Jean-Stephane Valla, MD	Nothing to disclose		
David van der Zee, MD	Nothing to disclose		
Francois Varlet, MD	Nothing to disclose		
Atsuyuki Yamataka, MD	Nothing to disclose		
C.K. Yeung, MD	Nothing to disclose		

PRESENTER DISCLOSURES



NAME	COMMERCIAL INTEREST	WHAT WAS RECEIVED	FOR WHAT ROLE(S)?
Todd A. Ponsky, MD	Valley Lab Storz	Consulting Fee Consulting Fee	Consulting Consulting
John M. Racadio, MD	Phillips Philips Medical <i>Other:</i> J. M. Racadio has had his travel expenses paid by Philips Medical for 2 Philipssponsored speaking engagements and 2 medical advisory boards	Honorarium Other Financial Benefit	Membership on Advisory Committees or Review Panels Speaking and/or Teaching
Steven S. Rothenberg, MD	Vallylab Covidien Karl Storz	Consulting Fee Consulting Fee Consulting Fee	Consulting Consulting Consulting

PRESENTERS WITH NO DISCLOSURES

Sameh M. Abdel Hay	Alexandra Krauss	Alberto Ratta
S. Alhindi	Mustafa Kucukaydin	Olivier Reinberg
Francesca Alicchio	Pablo Laje	Marc Reismann
Aayed R. Alqahtani	Marc A. Levitt	Amulya K. Saxena
Georges Azzie	Long Li	Klaus Schaarschmidt
B. Banieghbal	Hannu Lintula	Maria Grazia Scuderi
Denis D. Bensard	Francois I. Luks	Sohail R. Shah
Meltem Bingol-Kologlu	Anies Mahomed	Jennifer Sihoe
K. Bjornland	Marcus M. Malek	Philipp Simon
David Bliss	Antonio Marte	C. K. Sinha
Arnaud A. Bonnard	Abigail E. Martin	Yuriy Sokolov
Jean Breaud	John J. Meehan	Philipp O Szavay
Alex W. Caillat	Martin L. Metzelder	Hiroo Takehara
Pirolat Christian	Go Miyano	Burak Tander
Lars J. Cisek	Michael Mokry	Holger K. Till
Daniel A. DeUgarte	John Morton	Baran Tokar
Maria Rita Di Pace	Oliver J. Muensterer	Qiangsong Tong
Mohamed S. El-Debeiky	Nam Nguyen	Michele Torre
Ciro Esposito	Liem NT	Salmai Tural
Edward Esteves	A. Numanoglu	Robin Wachowiak
Verena Gellner	Manabu Okawada	Simon K. Wright
Carlos Giné	Daniel J. Ostlie	Makoto Yagi
Riccardo Guanà	Jeffrey S. Palmer	Aydin Yagmurlu
Ramanath N Haricharan	Dariusz Patkowski	Atsuyuki Yamataka
Allal Hossein	Lena Perger	Suzanne Yoder
Kristine M Kelliher	Igor V. Poddoubnyi	Smart Zeidan
Christina Kim	Guillaume Podevin	Lv Zhibao
Yury Kozlov	Shawn J. Rangel	Jeffrey L. Zitsman



ORAL PRESENTATION ABSTRACTS

S001 PERIOPERATIVE SAFETY OF LAPAROSCOPIC ROUX-EN-Y GASTRIC BYPASS: A CHILDREN'S HOSPITAL EXPERIENCE

Go Miyano MD, Stavra Xanthakos MD, Judy Bean PhD, Victor F. Garcia MD, Thomas H. Inge MD, Cincinnati Children's Hospital Medical Center

PURPOSE: To evaluate the perioperative safety of laparoscopic Roux-en-Y gastric bypass (LRYGB) in a free-standing children's hospital setting.

METHODS: Perioperative (<90 days) clinical outcomes of 67 consecutive patients (16.8±2.1 yrs, 13 to 23 years), who underwent LRYGB at Cincinnati Children's Hospital from 2002 to 2006 were examined. For this analysis, the patients were stratified by BMI < 60 kg/m² (Group A, n=40) or with BMI ≥ 60 kg/m² (Group B, n=27).

RESULTS: No mortality or conversion to open surgery was observed. Intraoperative complications were uncommon (2.9%), with 2 recognized perforation of hollow viscus requiring repair and no anesthetic complications or transfusion requirements. Median hospital stay was 3.3 and 4.0 days in Group A and B, respectively. Postoperative complications (≤30 days and 31-91 days) requiring re-intervention, transfusion, ICU transfer, or readmission were analyzed. No transfusions were required. Incidence of stenosis of gastrojejunostomy requiring dilation was 7.5% (≤30d) and 12.5% (31-90d) in Group A, and 7.4% (≤30d) and 22.2% (31-90d) in Group B (p=NS). Intestinal leakage occurred within 30 days in n=2 in Group A and in n=4 in Group B (p=NS); no leak was seen 31-90d. Reoperation was required for leak in 2 in Group A and in 4 (2 leak, 2 small bowel obstruction) in Group B. Other complications requiring readmission: 3 dehydration, 3 dysphagia, 4 gastrointestinal inflammation, and 2 wound infection. Initial mean BMI was reduced from 51 to 41 kg/m² (Group A) and 69 to 54 kg/m² (Group B) by day 90.

CONCLUSIONS: Perioperative outcomes demonstrate: 1) LRYGB is a safe procedure for extremely obese adolescents even at very high levels of BMI when performed in an experienced clinical setting. 2) differences by BMI category were not significant with this sample size. 3) LRYGB results in significant reduction in BMI.

S002 TECHNICAL CONSIDERATIONS FOR LAPAROSCOPIC ADJUSTABLE GASTRIC BANDING IN ADOLESCENTS

Amulya K. Saxena MD, Lutz Stroedter MD, Michael E. Hoellwarth MD, Department of Pediatric Surgery, Medical University of Graz, Austria

BACKGROUND: Morbid obesity has reached epidemic proportions in the adolescent population and presents with a major health problem in developed nations. Laparoscopic adjustable gastric banding (LAGB) is now being offered to adolescents that have met the criteria for this procedure, to minimize obesity related co-morbidities, avoid premature mortality, improve quality of life, and prevent obesity-related diseases as these patients mature into adulthood. Since LAGB is associated with a high-incidence of complications a review of our initial experience with this procedure was performed.

PATIENT SELECTION: Treatment of morbid obesity using LAGB was initiated at our center in 2006. After medical, psychologic, and nutritional screening of patients with a body mass index of 40 or more who failed medical attempts at weight loss, 5 patients were selected for LAGB. Patients and parents were informed about the procedure in details and the consent for surgery was obtained. The Swedish Adjustable Gastric Band (SAGB) (Ethicon Endosurgery) was placed using a 5 port technique.

SURGICAL PROCEDURE: Four technical considerations were evaluated and adopted in our approach. The open access method for placement of the initial (umbilical) port was preferred, though the Veress access technique for initial access has been favorable in adult LAGB surgery. An extra suture was additionally placed on the SAGB to facilitate easier locking after placement. The port site used for liver retraction was used as the exit point of the tubing from the abdomen. The reservoir was placed and secured on the caudal end of the sternum just above the level of the xiphoid.

CONCLUSION: There were no intraoperative complications and the procedures were completed with minimal loss of blood. Although open access for the placement of the initial port requires more time, it overcomes the complications of injuries that have been reported using the Veress needle. Placement of the extra suture on the locking end of the SAGB offers technical assistance during locking. Reservoir placement on the caudal end of the sternum offers stable fixation and easier filling of the reservoir.

S003 LAPAROSCOPIC SLEEVE GASTRECTOMY AS A STAND-ALONE TECHNIQUE FOR CHILDREN AND ADOLESCENTS WITH MORBID OBESITY

Holger K. Till PhD, Oliver J. Muensterer PhD, Susanne Blucher MD, Antje Koerner MD, Wieland Kiess, Department of Pediatric Surgery

BACKGROUND: The appropriate procedure for bariatric surgery in children and adolescents remains a matter of vivid discussions. To date gastric banding (GB) and Roux-Y gastric bypass (RYGB) represent the standards, but they require life-long tolerance of either an artificial device or significant intestinal malabsorption. Although laparoscopic sleeve gastrectomy (LSG) demands neither, it has not been advocated for this age-group as a stand alone technique yet. We report about the efficacy of LSG in a small series of children and adolescents.

MATERIAL/METHODS: Before surgery was considered, all patients (n=4) were subjected to a multi-modal weight loss program for several years without significant success. At referral the mean age was 14.5 years (range 8-17), mean body mass index (BMI in kg/m²) was of 48.4 (range 40.6 - 56.3). All suffered from co-morbidities consistent with a developing metabolic-vascular syndrome such as dyslipidemia and arterial hypertension. Moreover, in an 8-year old girl Prader-Willi-Syndrome had been confirmed genetically at the age of 2. The decision for bariatric surgery was taken unanimously by the patient, parents and the obesity team. LSG was performed in a 5-trocar technique. With a gastroscope protecting the lesser curvature, the stomach was resected from the antrum to the fundus using an ENDO-GIA stapler. That stapler line was oversewn to decrease the risk of leakage.

RESULTS: Mean operating time was 4.1 hours including 2 simultaneous cholecystectomies for cholelithiasis. There were no perioperative complications. An upper GI contrast study on postoperative day 4 showed a J-like tubular gastric remnant (with a volume of approximately 200 ml) and ruled out leakage. After discharge all patients were monitored in our special obesity outpatient clinic. After a mean follow-up time of presently 8.25 months (range 3-18 months) the mean BMI had decreased to 39.9. The girl with the longest follow-up had reduced her weight from 121 kg to 85.8 kg (BMI from 40.6 to 29.3) within 18 months. LSG failed in no child and laboratory studies ruled out malnutrition or vitamin deficiency.

CONCLUSION: LSG proved a safe and effective option for bariatric surgery in our small series of obese children and adolescents. Thus it may be considered as stand-alone restrictive operation. Before advocating this approach though, the long-term efficacy of LSG must be compared with established procedures like GB and RYGB.

S004 MANAGING THE LEFT GASTRIC ARTERY DURING ADOLESCENT LAPAROSCOPIC GASTRIC BANDING (LAGB)

Jeffrey L. Zitsman MD, Morgan Stanley Children's Hospital of New York Presbyterian, Columbia University Medical Center

The pars flaccida technique of perigastric dissection as described by Fielding et al has minimized the incidence of gastric prolapse ("slippage") in LAGB. Variability in the position of the left gastric artery (LGA) may present a challenge to the surgeon during this dissection. The author reviewed his experience with 34 adolescent patients (ages 14-18, BMI 35.7-76.0) who underwent LAGB.

Twenty-six patients presented no relevant vascular issues during dissection. One patient had multiple dilated veins but unremarkable arterial anatomy. Seven patients were found to have LGA that crossed the pars flaccida or protruded into the space so as to block the inferior exposure

ORAL PRESENTATION ABSTRACTS



of the right crus. In 2 patients the vessel was sufficiently low to allow for proper dissection with gentle traction. One patient had a high-lying vessel; placement of the band below the vessel resulted in gastric obstruction on POD 1 and required revision to place the band superiorly and around the LGA. In 3 additional patients the band was placed to include the artery within the band. One patient had sufficient space between the LGA and the stomach to create a medial window to exclude the artery after passing the band around the stomach. No patient has demonstrated any ill effect from including the LGA within the band (follow-up 2-14 months).

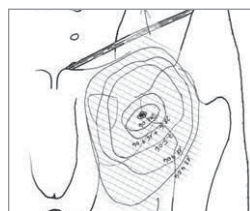
CONCLUSION: Variation in the position of the LGA must be noted to avoid injury during LAGB. Data from this limited series suggests the band can be placed around the vessel without untoward consequences.

S005 GENITOFEMORAL NERVE INJURY AFTER LAPAROSCOPIC VARICOCECTOMY IN ADOLESCENTS

Oliver J Muensterer PhD, Department of pediatric surgery, University of Leipzig

OBJECTIVES: Genitofemoral nerve injury (GNI) is an underappreciated complication after laparoscopic varicocele ligation (LVL). This study describes the incidence by ligation instrument, and the resolution pattern.

METHODS: Patients who underwent LVL from 2004-2007 were grouped by ligation modality (clips or ultrasound (US) shears). The incidence of GNI was assessed and compared.



RESULTS: LVL was performed using US shears in 12 and endoscopic clips/cold dissection in 15 boys. GNI occurred in 2 patients (17%) using US shears and none in the cold dissection group. In all patients, the paresthesias resolved after 8 months. One affected patient documented the decreasing area of paresthesia over time on a topographic map.

CONCLUSIONS: Genitofemoral nerve injury may be more frequent when dissection is performed using "hot" methods. Patients should be made aware of the incidence and the self-limiting nature of this complication.

S006 SCROTAL SKIN NECROSIS AFTER METHYLENE BLUE DYE INJECTION FOR LYMPHATIC SPARING LAPAROSCOPIC VARICOCECTOMY

Berkutug Bahadır MD, Gulnur Gollu MD, Aydin Yagmurlu MD, Department of Pediatric Surgery, Ankara University Faculty of Medicine

The most common long-term complication of varicocelectomy is the development of hydroceles, thought to be due to interruption in the lymphatic outflow from the subservient testis. Intrascrotal injection of methylene blue dye (MBD) for lymphatic preservation in laparoscopic varicocelectomy is a new method.

A fourteen year old boy was referred for bilateral varicoceles. He had previously operated for left side hydrocele and right side hernia. Bilateral lymphatic sparing laparoscopic varicocelectomy with MBD in-trascrotal injection was performed. Bilateral scrotal edema developed the following day. Patient developed bilateral scrotal skin necrosis two weeks after operation. After local antibiotic cream application, debridement was required.

In conclusion, the skin necrosis was found to be related with MBD usage. The use of MBD must be avoided due to its hazardous and catastrophic effects.

S007 ACCIDENTAL TRACHEAL WALL INJURY DURING THORACOSCOPIC ESOPHAGEAL ATRESIA REPAIR – COMPLICATIONS AND MANAGEMENT

Dariusz Patkowski PhD, Marzena Zielinska PhD, Magdalena Chęcinska MD, Piotr Stepień PhD, Małgorzata Szerla MD, Jerzy Czernik PhD, Department of Paediatric Surgery and Urology, Medical University of Wrocław

PURPOSE: To present different clinical course, complications and management of accidental tracheal wall injury during thoracoscopic esophageal atresia (EA) with distal fistula repair.

METHODS/PROCEDURE: From Aug 2005 to Dec 2007 19 consecutive cases of esophageal atresia with distal fistula were repaired using thoracoscopic technique. There were two cases of accidental tracheal wall injury. In one case the trachea wall was opened at the level of intubation tube end that resulted in sudden worsening of ventilation. There was a rise in end-tidal CO₂ and drop in saturation. The opening was closed with intracorporeal simple suture. Ten days later during extubation it became clear that intubation tube was sutured to the trachea. To remove the tube was twisted to exert traction on the suture and a day later removed without difficulty. In the second case the trachea was injured high at the level of neck that was not noticed until the end of procedure. During the postoperative course there was air leak from the chest drain and right pneumothorax was observed. As there was no sign



of improvement 2 days later the site of trachea injury was diagnosed by contrast study and the intubation tube was exchanged for cuffed tube and positioned under X-ray control. The air leak has stopped and resulted in healing the injury.

CONCLUSIONS: The trachea injury during thoracoscopic repair of esophageal atresia is a serious complication. The clinical signs and management vary depending on the level of injury.

S008 ENDOSCOPIC ENDONASAL TRANSSPHENOIDAL SURGERY FOR INTRA- AND EXTRASELLAR LESIONS IN CHILDREN

Verena Gellner BA, Senta Kurschel-Lackner BA, Hans Georg Eder BA, Hannes Braun PhD, Georg Clarici MD, Heinz Stammberger PhD, Michael Mokry, Department of Neurosurgery, ORL Head & Neck Surgery, Medical University Graz, Austria

PURPOSE: To evaluate the surgical results of endoscopic endonasal transsphenoidal approaches for intra- and extrasellar lesions in children.

METHODS: From 2003 to 2006, 12 children with intra- and/or extrasellar lesions were treated by 15 endoscopic transsphenoidal approaches. The mean age was 13.7 years (range 4-18), 58.3% were female. Visual field deficiency was present in 4 children.

RESULTS: Mean follow-up was 20.5 months (range 0-50); one patient was lost for follow-up. Histological diagnosis disclosed pituitary adenoma in 5 children, craniopharyngioma in 2, and Rathke cleft cyst, PNET, fibrillary astrocytoma, schwannoma and osteoma in 1, respectively. A total resection could be achieved in 6 cases, a subtotal resection in 3, a partial resection in 5, and a biopsy was the aim of surgery in 2 children. Postoperative transient complications comprising cerebrospinal fluid rhinorrhea and diabetes insipidus (DI) occurred in 33.3% (n=4), only one child showed persistent DI. Further treatment consisted of three endoscopic reoperations, two craniotomies, and three radiosurgical procedures due to residual or recurrent tumors. Visual field normalized in 3 children, in one it remained stable.

CONCLUSIONS: The endoscopic transsphenoidal approach has shown to be an excellent alternative for a wide variety of intra- and extrasellar lesions that especially in children would have been attacked via a transcranial approach. The procedure is minimally invasive and causes much less stress to the patients reducing the duration of hospital stay. Complications related to surgery in this series in general were transient and can be classified as minor.

S009 ENDOSCOPIC ENDONASAL TRANSSPHENOIDAL APPROACH TO PITUITARY LESIONS, CRANIOPHARYNGIOMAS, AND OTHER LESIONS OF THE SKULL BASE – THE GRAZ EXPERIENCE

Michael Mokry PhD, Verena Gellner MD, Etienne Holl MD, Georg Clarici MD, Hannes Braun PhD, Heinz Stammberger, Department of Neurosurgery, Department of ORL Head & Neck Surgery, Medical University, Graz, Austria

The microscopic transnasal transseptal transsphenoidal approach has been the standard approach for most of the pituitary lesions in adults as well as in children since many years. During the last years an increasing number



ORAL PRESENTATION ABSTRACTS

of publications appeared in the literature describing the endoscopic transsphenoidal approach to lesions of this region as a serious alternative to the traditional microscopic approach with the chance of improving surgical morbidity, outcome and shortening of hospital stay. Therefore, some four years ago, we started to use this approach in close cooperation between the neurosurgical and ENT departments.

Between August 2003 and December 2007 192 endoscopic transsphenoidal procedures were performed in 184 patients (mean age 47.9 + 15.1; range 4 - 76 years (12 patients age < 18). Most patients suffered from a pituitary adenoma. Other histological entities were 6 chordomas, 3 craniopharyngiomas, 5 Rathke cleft cysts, 3 meningiomas of the sellar tuberculum and various other rare lesions. All procedures were performed using CT- and MRI- based image fusion guidance.

With the endoscopic endonasal four handed technique we could not further reduce the already very low complication rate we observed in patients with pituitary adenomas. In most patients the duration of hospital stay was shorter because no nasal packing was necessary. The patients found it very pleasant that nasal breathing was nearly not obstructed after the operation.

Compared to the microscopical technique the use of the endoscope provides the following advantages in both children as well in adults: All the important anatomical landmarks like the protuberances of the optic nerves and carotid arteries can be identified. Direct view to the parasellar and suprasellar space is possible. Angled front lenses open the way to the suprasellar cisterns widening the indication for this approach to lesions that microscopically simply cannot be touched like the posterior part of the sphenoid plane, the suprasellar cisterns up to the third ventricle, intrapeduncular fossa and upper part of the clivus. The endoscopic view provides a far better differentiation of pathologic tissue and normal pituitary gland helping to preserve pituitary function. Even tough adenomas that could not be removed via a preceding microscopical approach could be removed radically via an endoscopic approach.

S010 LAPAROSCOPY-ASSISTED SURGERY FOR BOWEL OCCLUSION IN NEWBORNS: TWO CASES

Maria Grazia Scuderi MD, Lucia Virardi MD, Salvatore Arena MD, Aurelio Di Benedetto PhD, Vincenzo Di Benedetto PhD, U.O.C. di Chirurgia Pediatrica, Azienda Ospedaliero-Universitaria Vittorio Emanuele Azienda Ospedaliero, Universitaria Policlinico, Università degli Studi di Catania

Laparoscopy-assisted surgery for bowel occlusion in newborns: two cases

PURPOSE: Laparoscopic surgery has been applied even to newborns. To show the safety and the efficacy of minimally invasive techniques to correct neonatal congenital bowel obstruction, we present two cases of intestinal occlusion in newborns treated with minimally invasive approach.

MATERIALS/METHODS:

Case 1: Newborn girl (37 weeks), with prenatal diagnosis of bowel obstruction (32nd week) was treated with laparoscopy-assisted surgery. Under general anesthesia, a 10mm trocar was inserted using an open technique through an intraumbilical incision with an operative telescope. The proximal atretic bowel end was identified (jejunal atresia) and mobilized using laparoscopy. When the umbilical trocar was removed, the bowel was exteriorised to realise the anastomosis and then returned to the abdomen through the umbilical wound.

Case 2: Newborn girl (39th weeks), without antenatal diagnosis, during the second week of life presented biliary emesis and signs of bowel obstruction. At operation, intestinal partially volvulated malrotation became apparent. Through the same approach, the operation consisted of bowel exteriorisation and reduction of the volvulated bowel loops and division of obstructing bands.

RESULTS: Both of the got successfully results. No conversion needed, the operative time was 60 min for the first case and 40 min for the second one. Postoperatively, no complications occurred and there was minimal abdominal scarring, and the umbilicus was normal in appearance.

CONCLUSION: Although this experience is limited to 2 patients, the technique results easy, safe, and virtually scar free and for that reason could be applied for the treatment of newborns.

S011 SETT SUBCUTANEUS ENDOSCOPIC TRANSAXILLARY TENOTOMY FOR CONGENITAL MUSCULAR TORTICOLLIS

Yury Kozlov MD, Vladimir Novogilov MD, Natalya Aleynikova, Pavel Yurkov MD, Vitaly Kovalev, Andrey Yakovlev, Irina Weber MD, Marina Kononenko, Svetlana Kuznecova, Department of Pediatric Surgery, Department of Pediatric Traumatology, Municipal Pediatric Hospital, Irkutsk, Russia

BACKGROUND: Congenital muscular torticollis (CMT) is caused by fibromatosis within the sternocleidomastoid muscle. Surgical correction is recommended for patients with unsuccessful conservative treatment between the age of 1 and 4 years before formation of facial asymmetry and plagiocephaly. Many surgical procedures are advocated for release of the sternocleidomastoid muscle. Open operative techniques all leave noticeable scars and provide limited exposure. First subcutaneous tenotomy without endoscopy reported Kraft et al. Burstein F. described the first endoscopic experience for CMT. Transaxillary technique for the release of the sternocleidomastoid muscle is described by Swain, but he performed this procedure with 3 cm. incision on the anterior axillary fold. We proposed new full endoscopic two trocars approach without lift incision and with gas insufflation.

MATERIAL AND METHODS: We have applied a new technique of endoscopic release of the sternocleidomastoid muscle in 5 patients (3 female; 2 male) ages from 4 to 10. We described this operation. The surgery is performed under general anesthesia with endotracheal intubation. The child's head was turned toward the affected side. A two 3-mm. incision is made on the anterior surface of the axillary fold. We performed the tunnelization of the space over clavicular and sternal heads of the sternocleidomastoid muscle applied balloon inflation of Fogarty catheter (Fr.18). A CO₂-insufflation is made the excellent exposition of the operative field. The sternal and clavicular attachments were dissected and divided by electrocautery hook or scissors. The head of the patient is moved to the other side to check for undivided band. The wound was closed with Steri-Strip. Postoperatively, a program of physiotherapy was prescribed that included maintenance of passive and active motion of the neck. The patients wear a neck collar for 7 days.

RESULTS: An excellent result was found in all 5 patients. There were no severe complication to be seen. The neurovascular structures were preserved in all cases.

CONCLUSION: We believe that SETT procedure is a good method for treatment of congenital muscular torticollis. This endoscopic technique avoids injury to neurovascular structures and does not leave visible scars.

S012 LAPAROSCOPIC MANAGEMENT OF OVARIAN LESIONS IN CHILDREN

Riccardo Guanà MD, Fabio Beretta MD, Luciano Sangiorgio MD, Henry Steyaert MD, Jean-Stephane Valla PhD, Division of Paediatric Surgery, Lenval Hospital, Nice, France

INTRODUCTION: We have considered ovarian pathologies observed in a period of time of 24 years (1981-2005) in the Division of Paediatric Surgery of Lenval Hospital.

METHODS: We studied 223 patients, 36 between years 1981-1992 and 187 between years 1992-2005. The medium age at diagnosis was 11 years (+/- 5.4). Observed ovarian pathologies have been functional cysts (59% of cases), benign tumours (16.7%), malignant tumours (2.6%), ovarian torsions in normal ovary (7%), other adnexal pathologies (paraovarian cysts, tubaric cysts, etc) [14.5%]. Lesions were associated to torsion in 23.8% of the cases. We have observed the following ovarian tumors: benign teratoma (22 cases, 49% of tumoral pathologies), cystoadenomas (13 cases, 30%), adenophyllomas (2 cases, 5%), malignant teratoma (3 cases, 7%), seminomas



(2 cases, 5%) and 1 lymphoma (2%). The treatment for neoplastic lesions consisted in a laparotomy in 11% of patients and a laparoscopy in 89% of cases. The conversion rate has been of 20.5%, while a short inguinal laparotomy for the extraction of the piece has been practiced in 20.5% of cases. For benign lesions the treatment has been for 31% of cases surveillance alone with serial ultrasound examinations, obtaining the complete regression of the lesion in this group of patients. A laparoscopic treatment has been carried out in 57% of patients, while a laparotomy in 12% of cases.

RESULTS: As far as the tumours, the percentage of laparoscopic interventions has been of 20% in the period 1981-1991, and of 97% in the period 1992-2005, with 8 conversions and 7 mini-laparotomy for piece extraction (short Pfannenstiel or inguinal incision). As far as the cysts, 36% of the patients was operated with a laparoscopic approach before 1992, against 100% in the followed years. In the children younger than 1 year, has been necessary to perform a mini-laparotomy for the extraction of the lesion in 1 patient on 4 (laparo-assisted surgery). In the tumour group, we registered one late recurrence of a malignant teratoma approached by laparotomy.

CONCLUSIONS: Laparoscopic management of benign ovarian lesions is safe and effective; remains to clarify the risk of neoplastic cells' dissemination in laparoscopic procedures for malignant tumours.

S013 INTER-OBSERVER VARIATION IN THE ASSESSMENT OF APPENDICITIS

Todd A. Ponsky MD, Muhammad Hafi MD, Kurt Heiss MD, John Dinsmore MD, Kurt D. Newman MD, James Gilbert MD, Rainbow Babies and Children's Hospital, Cleveland, OH, USA, Children's National Medical Center, Washington, D.C., USA, Children's Hospital of Central California, Madera, CA, USA

BACKGROUND: Following appendectomy, surgeons define appendicitis, for treatment and billing purposes, into one of four categories: normal appendix, acute appendicitis, gangrenous appendicitis, and perforated appendicitis. Treatment of appendicitis is predicated upon classification at the time of visual inspection. Furthermore, this classification often plays a role in the assessment of hospital outcomes. The currently accepted classification system is based solely upon intraoperative surgeon opinion and not objective data. Inconsistent surgeon grading of the severity of appendicitis may have implications in both management and outcomes.

OBJECTIVE: To assess the inter-observer and intra-observer variation amongst surgeons in grading of the inflammatory severity of acute appendicitis as recognized on visual findings at operation.

METHODS: A cross-sectional study design. 110 surgeons and surgical residents were randomly selected. Surgeons were shown images of intraoperative appendicitis, and asked to evaluate the severity of the appendicitis (normal, inflamed, gangrenous, and perforated). Demographic information regarding the type of practice, hospital setting, and the number of encounters with patients with acute appendicitis were assessed.

RESULTS: The study group consisted of 100 surgeons, 62 practicing surgeons and 48 surgical trainees. 79% of the surgeons treated predominately adults with appendicitis, 18% treated primarily children, and 3% treated both children and adults. Overall there was poor agreement amongst surgeons in assessing the severity of appendicitis. The kappa score was used to assess agreement with $k=0.25$ being random chance. Specifically, when choosing to apply the descriptor "normal" the kappa score was ($k = 0.22$), less than random chance alone, inflamed ($k=0.30$), perforated ($k=0.27$); and gangrenous ($k = 0.20$).

CONCLUSION: There is poor agreement amongst surgeons in describing the severity of appendicitis. Treatment protocols based on more accurate assessment and categorization could potentially lead to more favorable and cost effective outcomes. Furthermore, studies determining efficacy in the diagnosis and treatment of appendicitis should consider observer variability. Future work must attempt to define critical objective assessment points, such as visible discontinuity of the appendix or fecal soilage, to assure better correlation of findings with prognosis.

S014 TRANS PERINEAL RECTOVESICAL FISTULA LIGATION IN LAPAROSCOPIC ASSISTED ABDOMINOPERINEAL PULLTHROUGH FOR HIGH ANORECTAL MALFORMATIONS

Sameh M. Abdel Hay MD, Pediatric Surgery Unit, Ain Shams University, Cairo, Egypt

BACKGROUND: Rectovesical fistula ligation after laparoscopic mobilization of the rectum needs either cutting of the fistula and application of endoloop or laparoscopic endoligation. These techniques need more time and well trained surgeon for performing the ligation laparoscopically. A simple technique for ligation of the fistula will be described.

MATERIAL/METHODS: Over the last 5 years laparoscopic assisted abdomino perineal pull through were performed in 12 cases with high anorectal malformation with rectovesical or rectoprostatic fistula. The rectovesical fistula was mobilized initially laparoscopically. The anal site was identified using muscle stimulator and incised at its center. A Hegar dilator was passed through the center of the anal sphincter to exit behind the fistula seen by laparoscopy. The tract is dilated with Hegar dilators till reaching a suitable size for rectal pull through. A straight clamp holding ligature was passed through the perineal site through the dilated tract to emerge on one side of the fistula, grasped through the abdomen and turned around the junction of the fistula forming a loop and re-grasped and brought outside with the clamp. The 2 ends of the ligature emerging from the perineal site were tied and the knot was pushed using the finger till it reaches the fistula and ligate it. The fistula was cut and the mobilized rectum was pulled through the perineal incision to be sutured at the site of the future anus.

RESULTS: Twelve patients with anorectal agenesis with rectovesical or recto prostatic fistula had fistula ligation with this technique. Their age ranged from 3 to 9 month. Ligation of the fistula was possible in all patients. Operative time ranged from 90-120 minutes (mean 110 mns). Ascending urethrogram showed no residual diverticulum in all but one showed residual diverticulum that was presented with difficulty in micturition and needed to be excised.

CONCLUSION: Trans perineal rectovesical fistula ligation in laparoscopic assisted abdominoperineal pullthrough for high anorectal malformations is an alternative technique for fistula ligation during laparoscopy. It is simple, easy to perform with acceptable post operative results.

S015 INGUINAL HERNIA REPAIR IN CHILDREN WITH PERCUTANEOUS INTERNAL RING SUTURING (PIRS): ANALYSIS OF 350 OPERATIONS

Dariusz Patkowski PhD, Rysiakiewicz Konrad MD, Ladogorska Jolanta MD, Zielinska Marzena PhD, Apoznanski Wojciech PhD, Czernik Jerzy PhD, Department of Paediatric Surgery and Urology, Medical University of Wrocław

PURPOSE: To review experience with laparoscopic hernia repair in children using our own technique – the percutaneous internal ring suturing (PIRS).

METHODS: From February 2004 to September 2007 350 children (257 male and 93 female) aged between 4 days and 14,5 years (mean 3,5year) with inguinal hernia were operated on by PIRS technique (previously described). The clinical results of retrospective analysis are reported.

RESULTS: In 350 patients 530 inguinal hernias were operated (bilateral in 32,7% male and 41,9% female). There were 2 male direct hernias and 1 female femoral hernia- all identified intraoperative. In 4 cases hernia was excluded by laparoscopy. In 37 patients other procedures were performed of which repair of umbilical hernia (32 cases) was most common. There was one conversion to open surgery because technical problems. The average operative time was 23 min. (20 min. for unilateral and 24 min. for bilateral hernias). The follow up was between 3 and 44 months. The cosmetic results are excellent with almost invisible scars in every case. There was no wound infection. The only intraoperative complication was



ORAL PRESENTATION ABSTRACTS

an incidental piercing of the vessels in inguinal region in 16 cases which required gentle pressing from outside for a short time. The most serious complication (1 case with direct hernia) was torsion of the ileum around adhesion which resulted in segmental necrosis and necessitated resection of the affected loop. There were eleven hernia recurrences (2,08%), only one noted in girl, eight were reoperated using PIRS technique. Most recurrences occurred in the group of first operated cases.

CONCLUSIONS: The PIRS method is a simple minimally invasive technique with excellent cosmetic outcome particularly advocated in bilateral pathology, coexisting umbilical hernia and in female patient. Use of laparoscopy in treatment of inguinal hernia affords opportunity of precise recognition of pathology and verification of initial diagnosis. PIRS method allows other diagnostic and curative procedures to be performed safely which should be considered as advantages. The complication rate is comparable to other laparoscopic techniques of inguinal hernias repairs in children.

S016 PERITONEAL CARCINOMATOSIS IN CHILDREN: ROLE OF LAPAROSCOPY

Piolat Christian MD, Dyon Jean-François MD, Robert Yohann, Sibai Samir MD, Nugues Frédérique MD, Eitenschenk Laurence MD, Pagnier Anne MD, Pasquier Dominique MD, Plantaz Dominique PhD, Chu De Grenoble, France

INTRODUCTION: Peritoneal carcinomatosis is rarely reported in children. Laparoscopic approach as never been described. We report two cases of peritoneal carcinomatosis with a useful role of laparoscopy.

PATIENTS/METHODS: Two boys (4 years-old, 13 years-old) were referred to our institution for abdominal tumor associated with peritoneal carcinomatosis discovered on sonography and tomodensitometry. In these 2 cases laparoscopic exploration was able to localize the tumor, evaluate its extirpability and confirm peritoneal metastases. Tumorectomy in the first case and peritoneal metastasis biopsy in the second case allowed histopathologic diagnosis: inflammatory myofibroblastic tumor (case 1), abdominal desmoplastic tumor (case 2). In the first case complete excision of peritoneal nodules (douglassectomy) was performed in the same time by short supra-pubic incision (used for tumor extraction). In the second case laparoscopic second look was realized after protocolized chemotherapy; in the same time laparotomy was performed for tumorectomy and extended peritonectomies.

DISCUSSION: There's no publication dealing with laparoscopic management of peritoneal carcinomatosis in children whereas its role is well known in adult's cancers (gastric cancer): peritoneal staging, feasibility for peritonectomies, biopsy, tumor's extirpability. Laparoscopy is more often used in children's tumors in selected indications. Laparoscopic approach of peritoneal carcinomatosis seems to be really advantageous: small incisions are helpful to permit a rapid beginning of chemotherapy, a second look is easily performed, tumorectomies and peritonectomies can be realized with respect of oncological rules. Development of intraperitoneal chemotherapy and hyperthermy could reinforce the role of laparoscopy in abdominal tumors with peritoneal diffuse metastatic involvement.

CONCLUSION: Laparoscopic approach is helpful for diagnosis of abdominal tumors with suspected peritoneal carcinomatosis. Laparoscopy is also useful to realise tumor's complete excision, second look and perhaps peritonectomies. Principles of surgical oncology must be respected. Long term evaluation and multicentric studies should be performed.

MOTS-CLÉS: peritoneal carcinomatosis, laparoscopy, minimal invasive surgery.

S017 COMPLETE LAPAROSCOPIC CYST EXCISION AND HEPATICO-DUODENOSTOMY: EARLY RESULTS OF 74 CASES

Liem NT PhD, Dung LA MD, Son TN PhD, National Hospital of Pediatrics

OBJECTIVE: To report technical details and early outcomes of laparoscopic cyst excision and hepatico-duodenostomy for choledochal cyst.

METHODS: The operation was performed using four ports. The cystic duct was identified and divided. The liver was suspended by two stay sutures: one on the round ligament, and the other on the proximal cystic duct. The choledochal cyst was dissected and removed completely. The duodenum was mobilized and opened at a junction between DI and DII. Hepatico-duodenostomy was established using two running sutures with PDS 5/0.

RESULTS: From January 2007 to November 2007, 74 patients were operated. Ages ranged from 2.5 months to 16 years. The diameter of the cyst varied from 10 mm to 84 mm. The operating time ranged from 90 minutes to 340 minutes (mean: 186 minutes). Blood loss was minimal in 68 cases. Intraoperative blood transfusion was required in 4 cases, and postoperative blood transfusion in 2 patients. Postoperative anastomotic leakage occurred in three patients and resolved spontaneously in two patients. One patient required a second operation. Postoperative hospital stay ranged from 4 days to 21 days (average 6.6 days). Follow up was obtained in 42 patients (57%), ranging from 1 to 11 months. One patient had cholangitis, and 4 patients had gastritis due to bilious reflux. Recovery was uncomplicated in the remaining 37 patients.

CONCLUSION: Laparoscopic complete cyst excision and hepatico-duodenostomy is a safe procedure and a good alternative for treatment of choledochal cysts.

S018 LAPAROSCOPIC TREATMENT OF PANCREATIC PSEUDOCYSTS IN CHILDREN

Suzanne Yoder MD, Steven S. Rothenberg MD, Kuo Jen Tsao MD, Mark L. Wulkan MD, Todd Ponsky MD, Shawn D. St. Peter MD, Daniel J. Ostlie MD, Timothy D. Kane, Rocky Mountain Hospital for Children, Denver, CO; University of Texas Medical Center, Houston, TX; Emory Children's Hospital, Atlanta, GA; Children's Mercy Hospital, Kansas City, MO; The Children's Hospital of Pittsburgh, Pittsburgh, PA

BACKGROUND/PURPOSE: Pancreatic pseudocysts are problematic sequelae of pancreatitis or pancreatic trauma causing persistent abdominal pain, nausea and gastric outlet obstruction. Due to the low volume of disease in children, there is scant information in the literature on the operative management of pseudocysts with minimally invasive techniques. Therefore, we conducted a multi-institutional review to illustrate several technical variations utilized in achieving laparoscopic cystgastrostomy in the pediatric population.

METHODS: A retrospective review was conducted of all patients who underwent laparoscopic cystgastrostomy from five institutions. Patient data, operative techniques and post-operative course were analyzed.

RESULTS: There were 13 patients with a mean age of 10.4 years and mean weight of 52.1 kg. The etiologies of pancreatitis included: trauma (4) gallstones (3), chemotherapy (2), hereditary (1) and idiopathic (3). Preoperative radiographic measurements of the maximal cyst diameter averaged 11.7cm with a range of 8 to 20 cm. Cystgastrostomy was approached using transgastric exposure in 4 cases, and intragastric ports were utilized in 9 cases. An average of 4 ports were used to complete these operations (range 3 to 6). Mean operative time was 113 minutes (range 45-180 minutes). There were no conversions in this series. Cystgastrostomy was performed using an endoscopic stapler (average 3.8 loads) in 6 cases, sutures in 6 cases and 1 was formed solely with the harmonic scalpel. Gastrostomy sites were closed using a stapler in 4 cases and suture techniques in 9. Mean time to initial and goal feeds was 3 and 4 days respectively. Postoperative imaging revealed persistent pseudocyst in one patient who was treated with a distal pancreatectomy. Therefore, 92% required no further operative intervention and remained asymptomatic upon recovery from their pancreatitis.

CONCLUSION: A laparoscopic approach to pancreatic cystgastrostomy for chronic pseudocyst proved to be safe and effective in this five-institutional survey. Techniques varied, but 92% had complete resolution with minimal morbidity and rapid recovery. Laparoscopic cystgastrostomy should be considered an appropriate first line treatment for chronic pseudocysts in children

ORAL PRESENTATION ABSTRACTS



S019 LAPAROSCOPIC CHOLECYSTECTOMY IN PEDIATRIC PATIENTS, EXPERIENCE OF 570 PROCEDURES

Igor V. Poddoubnyi MD, Kirill N. Tolstov MD, Andrei A. Isaev MD, Mikhail Y. Kozlov, Moscow State University of Medicine and Dentistry, Department of Pediatric Surgery

Despite the exponentially increasing number of laparoscopic cholecystectomies on adults to date, there is paucity of reports in the literature about this technique in pediatric patients.

All 570 children, who underwent laparoscopic cholecystectomy (LC) between 1994 and 2007, were reviewed.

The indications for the procedure were: calculous cholecystitis - 543 patients (among them 67 underwent concomitant laparoscopic splenectomy for hematological diseases); gallbladder polyps larger than 8 mm - 18 (adenoma- 5, papillary hyperplasia- 3, adenomatous hyperplasia- 3, inflammatory - 1, cholesterol polyps- 6); acalculous cholecystitis - 9.

The age of the patients with gallstone disease was: 6-12 months' 5 (0.9%); 1-3 years' 38 (7%); 4-12 years- 218 (40.2%); 12-17 years- 282 (51.9%). Female patients predominated- 345 (63.5%). The period of observation and conservative treatment lasted from 1 week to 12 years (less than 1 year- 271; 1-3 years- 178; 4-6 years- 67; more than 6 years- 27). Distinct clinical symptoms were recorded in 427 patients (78.6%), no symptoms in 116 (21.4%); acute cholecystitis in anamnesis took place in 98 (18%); common bile duct (CBD) obstruction was registered in 42 patients (7.7%); 78 children underwent previous "open" or laparoscopic abdominal surgery (from 1 to 5 procedures); in 12 patients previous laparoscopic cholecystotomy was performed in other clinics and relapse of cholelithiasis occurred.

The mean operating time was 35 min. (range, 20-180 min.). Two CBD injuries occurred (0.4%) and needed conversion; no other serious complications and indications for open procedure took place. Pigment and mixed stones predominated in prepubertal children (85%), the frequency of pure cholesterol gallstones significantly increased in adolescent patients (up to 75% in the patients from 15 to 17 years old). Obvious morphological inflammatory signs were recorded in 100% of removed gallbladders; dystrophic, sclerous and fibrous changes took place in 94-96%.

No late complications and no signs of postcholecystectomy syndrome were registered in our series during very long period of observation.

CONCLUSION: Chronic cholecystitis is present in all patients with gallbladder stones irrespective of age, presence and character of clinical symptoms; laparoscopic cholecystectomy nowadays is the only method of choice in the treatment of children with gallstone disease; we consider postcholecystectomy syndrome a myth in pediatric patients.

S020 LAPAROSCOPIC GASTRIC PULL-UP FOR LONG GAP ESOPHAGEAL ATRESIA

Edward Esteves MD, Bernardina B. Modesto MD, Chagas C. Celio MD, Kelly C. Paiva MD, Marcelo Calcagno MD, Pediatric Surgery Division, University of Goias, Brazil

Esophageal replacement is indicated in children presenting long gap esophageal atresia (LGEA) when anastomosis is not possible, specially those without distal fistula or failure of the different techniques for esophageal elongation. The authors show their novel techniques and analyse the preliminary results of the laparoscopic gastric transposition for esophageal replacement in esophageal atresia.

METHODS: In the year 2007, 4 children (2 males, 2 females) with LGEA were successfully treated by laparoscopic gastric pull-up for esophageal replacement. Three presented esophageal atresia type I (without distal fistula, admitted with gastrostomy and esophagostomy) and one type 3 (long gap, distal fistula complicated with anastomotic rupture elsewhere). The gastrostomy was carefully closed externally at its site. Using 3 ports - umbilicus, gastrostomy site, right quadrant - the stomach was released with harmonic scalpel keeping the right gastric and gastroduodenal arteries. Pyloromyoplasty was accomplished

in 2 cases where the vagus nerves had to be cut to allow pull-up. The stomach was pulled-up retromediastinally after blunt dissection with direct view with the laparoscope through an enlarged phrenic window and with finger dissection at the superior mediastinum. After freeing the esophagostomy, cervical anastomosis joined the proximal esophagus to the blind distal esophagus in 2 cases and the gastric fundus in the others, coupled with a transanastomotic silicone feeding tube. In 2 cases a concomitant thoracoscopy helped orientating the stomach at the posterior mediastinum.

RESULTS: All operations were performed without major complications, no transfusion, death or reoperation. No abdominal complications. Intraoperative expected pneumothorax occurred in 3 cases (two without distal fistula, whose both pleuras were joined in front of the supraphrenic aorta) and were simply aspirated at the end of the operation. Perioperative atelectasis in 2. Tube feeding began on the 2nd day, oral feeding on the 8th day. Light or moderate anastomotic stenosis (2) resolved with endoscopic dilations. After a follow up of 9-18 months all children have a functional graft, tolerating oral feeding in a satisfactory way, and have had a normal ponderal growth. Duodeno-gastric reflux was noticed in one patient. Cosmetics has been excellent, since the children keep the same scars they had before (umbilicus, gastrostomy and esophagostomy) plus a tiny 3mm scar near the right flank.

CONCLUSIONS: Esophageal replacement has limited indications nowadays for LGEA and can be safely performed with the stomach assisted by laparoscopy, maybe easier or safer than with the blind conventional mediastinal dissection, with less abdominal complications, which require larger and comparative series to be confirmed.

S021 EARLY DISCHARGE FOLLOWING LAPAROSCOPIC APPENDECTOMY IN CHILDREN UTILIZING AN EVIDENCE BASED CLINICAL PATHWAY

Denis D. Bensard MD, Richard J. Hendrickson MD, Joshua M. Careskey MD, Carla J. Fyffe RN, The Peyton Manning Children's Hospital and Cincinnati Children's Hospital Medical Center

BACKGROUND: The utility of laparoscopic appendectomy (LA) in children remains controversial. The determination of efficacy of LA in children is complicated by variable post-operative management, duration of antibiotics, and criteria for discharge. The purpose of this study was to examine the results of a commitment to LA and the concurrent implementation of an evidence based clinical pathway (CP) for management of acute and advanced appendicitis in a Children's Hospital.

METHODS: With IRB approval, all children presenting with appendicitis (n = 72; age = 10.6 +/- 0.1 yrs; male = 45, female = 27) were offered LA and management was directed by a CP: standardized postoperative management, antibiotic therapy, and criteria for discharge. Data was accrued prospectively for 12 consecutive months (5/1/2006-4/30/2007) and analysis performed at 18 months with completed follow-up in all patients. Criteria for discharge included completion of appropriate antibiotics, resolution of fever, adequate PO intake and pain control. Data reported as mean +/- SEM.

RESULTS: Children were stratified based on the operative findings: Group I: acute, n = 41; Group II: suppurative, n = 11; Group III: gangrenous or perforated, n = 20. Duration of hospital stay differed between the groups: Group I = 26 +/- 0.3 hrs; Group II = 48 +/- 3 hrs; Group III = 127 +/- 6 hrs (p<0.05). No patient in Group I or II suffered a complication or was re-admitted following discharge. Two patients in Group III (10%) were re-admitted and successfully treated with antibiotic therapy alone. 66% of children with acute appendicitis (27/41, age = 10 +/- 0.1 yrs) and 27% with suppurative appendicitis (3/11, age = 11 +/- 0.7 yrs) were discharged within 24 hours of admission. Discharge by 24 hours in Group I/II was not influenced by age, gender, or time of operation (< 6pm >). The most common reasons for delay included persistent symptoms (fever, pain), poor appetite, or parental anxiety.



ORAL PRESENTATION ABSTRACTS

SUMMARY: The commitment to LA and use of an evidence based clinical pathway resulted in discharge within 24 hours in 2/3 of children with acute appendicitis without re-admission or complications observed. Early discharge did not appear to be influenced by age, gender, or time of admission. For advanced appendicitis length of hospital stay determined by clinical parameters resulted in a low rate of complications or re-admission. Moreover, when peri-operative management is standardized, LA appears beneficial in children.

S022 DIVISION OF THE MESOAPPENDIX WITH ELECTROCAUTERY IN CHILDREN IS SAFE, EFFECTIVE, AND COST-EFFICIENT

Todd A. Ponsky MD, Steven S. Rothenberg MD, Rocky Mountain Hospital for Children, Denver, CO, USA

INTRODUCTION: Laparoscopic appendectomy is one of the most common procedures performed in children. There are several techniques available for dividing the mesoappendix including the using an endo-stapler, a ligasure (Valley Lab, Denver, CO), a harmonic scalpel (Ethicon Endosurgery, Cincinnati, OH), or electrocautery. Although it is the least expensive approach, many feel that electrocautery is an unsafe method of dividing the mesoappendix. Here we present our experience with the use of solely electrocautery to divide the mesoappendix.

METHODS: Over a period of 6 years, a total of 442 laparoscopic appendectomies were logged into our database. Each appendectomy was performed by coagulating and dividing the mesoappendix with a Maryland dissector or in some cases a hook electrocautery. Three 0-PDS Endoloops were then used to ligate the base of the appendix, 2 proximal and one distal. The total number of cases of post-operative bleeding and time of procedure were queried.

RESULTS: Of the 442 cases, 71 were perforated (16%). The mean time for non-perforated appendectomies was 26 min. and 38 min. for perforated. There was one case of post-operative bleeding managed non-operatively in a patient with previously undiagnosed Factor VIII deficiency. The cost of each Endoloop was \$22.

CONCLUSION: Although some have questioned the safety of using electrocautery alone to divide the mesoappendix for fear that it may not be adequate to seal the appendiceal artery, takes excessive time, or cause collateral tissue injury, this has not been our experience. Therefore the use of more costly instruments to divide the mesoappendix such as the endo-stapler, ligasure, or harmonic scalpel seems unwarranted. This study clearly show that electrocautery for the mesoappendix and Endoloops for the appendix is safe, effective, and cost efficient.

S023 IS THERE A NEED OF OPEN SURGICAL EXPERIENCE FOR LAPAROSCOPIC APPENDECTOMY TRAINING?

Gulnur Gollu MD, Meltem Bingol-Kologlu MD, Berkutug Bahadir MD, Rahsan Vargun MD, Huseyin Dindar MD, Aydin Yagmurlu MD, Department of Pediatric Surgery, Ankara University, School of Medicine, Ankara, Turkey

BACKGROUND: Resident experience in open appendectomy (OA) has diminished since laparoscopic appendectomy (LA) became gold standard in childhood appendicitis. For the last two years no OAs were performed in our department. With the concern of whether OA experience was needed for LA and pediatric surgical training, the factors influencing operative time, outcome in LA and the safety of LA performed by residents were investigated.

MATERIALS/METHODS: 272 LA procedures consecutively performed by two attending surgeons, 4 senior residents, and 3 junior residents were collected retrospectively in a computer database and analyzed prospectively. The number of LA procedures needed to decrease operating time under 40 minutes was determined by ROC curve analysis. Univariate analyses and multivariate analyses with

logistic regression were performed to identify factors influencing operating time. The investigated parameters were general surgical experience, laparoscopic surgical experience, OA experience and LA experience, institutional experience in LA, and the presence of complicated appendicitis. The complications and results of LA were also analyzed and compared between attending surgeons experienced in OA and residents unexperienced in OA.

RESULTS: There were only 9 complications which occurred during the first 70 cases performed by attending surgeons. Residents started to perform LA after the initial 73 cases and there were no complications recorded since then. Mean operating time decreased with increased institutional experience (61 ± 36 in initial 100 cases, 44.2 ± 26 in 101-200, 39 ± 21 in 201-272 cases). According to ROC curve analysis, the number of procedures needed to decrease operating time under 40 minute was 19. Residents needed less procedures than attendings to decrease operating time under 40 minutes. The univariate analysis demonstrated that laparoscopic surgical experience, LA experience, institutional LA experience and presence of complicated appendicitis effected operating time ($p < 0.05$). The multivariate analysis showed that the factors independently associated with operating time were the surgeons - LA experience, institutional LA experience and presence of complicated appendicitis. OA experience and general surgical experience did not correlate with operating time of LA.

CONCLUSION: Our findings certainly demonstrate that LA is a safe procedure in hands of residents. There is no need for OA experience prior to LA training as laparoscopic procedures require their own specific skills independent from open surgical experience. The decrease in the number of OA is not a drawback for resident training and it is possible to acquire an adequate knowledge of anatomy and surgery from LA training.

S024 UTILITY OF ERCP IN NEONATAL AND INFANT CHOLESTASIS

K. Bjornland PhD, L. Aabakken PhD, I. Aagaes MD, T. Sanengen PhD, S. Aasen, R. Emblem PhD, Rikshospitalet University Hospital

BACKGROUND/STUDY AIMS: In neonates and infants with biliary obstruction, the diagnosis of extrahepatic biliary atresia (BA) is important to establish early, to offer corrective surgery within 60 days of age. Abdominal ultrasound, hepatobiliary scintigraphy, CT and MRCP all offer partial imaging of the relevant structures, but still a definite diagnosis of BA may be difficult to ascertain. We report our experience with ERCP in the clinical situation of neonatal and infant jaundice.

PATIENTS/METHODS: Between 1999 and 2006, 23 ERCP procedures were performed in 22 neonates and infants with the provisional diagnosis of biliary obstruction where other imaging was inconclusive. The mean age and weight were 2.4 months and 4.8 kg respectively. A pediatric videoendoscope with an outer diameter of 7.5 mm was used in all patients.

RESULTS: ERCP was successful in 20/23 patients, suggesting or documenting biliary atresia in 6 patients, all subsequently verified by surgery. Of three failed cases, one patient subsequently was shown to have BA. The other two had a choledochal stone that was operated, and an inspissated bile plug that resolved spontaneously. The only complications were one asymptomatic case of hyperamylasemia and one of mild cholangitis successfully treated with antibiotics. When ERCP was suggestive of BA, the patient was referred to surgery the following day. Thus, no liver biopsy was taken.

CONCLUSIONS: ERCP is feasible and safe in the workup of neonatal cholestasis. When ERCP is suggestive of BA, patients are referred directly to surgery, and there is no delay due to waiting for results of evaluation of liver biopsies. Despite the expanding role of MRCP and ultrasound, ERCP may have a role in the multidisciplinary workup of these patients.

ORAL PRESENTATION ABSTRACTS



S025 LAPAROSCOPIC ANTEGRADE CONTINENCE ENEMA USING THE UMBILICAL Y-V APPENDICOPLASTY TECHNIQUE

Shawn J. Rangel MD, Andrea Bischoff MD, Pena Alberto MD, Levitt A. Marc MD, Cincinnati Children's Hospital

PURPOSE: The Laparoscopic Antegrade Continent Enema (LACE) procedure has been shown to be a safe and effective procedure to assist in the management of fecal incontinence. The purpose of this report is to present our experience using the LACE procedure with the umbilical Y-V appendicoplasty modification.

METHODS: We retrospectively reviewed the charts of all patients who underwent a LACE procedure using the umbilical Y-V appendicoplasty modification between 2005-2007. All procedures utilized a camera port at the umbilicus and two working ports for cecal mobilization. The appendiceal stoma was constructed at the umbilicus using a Y-V appendicoplasty technique. Laparoscopy-assisted cecoplication was performed in each case. All patients had achieved successful treatment of their incontinence through our bowel-management program prior to their procedure. Outcomes of interest included operative time, length of stay, peri-operative & stomal complications, and continence status at follow-up.

RESULTS: A total of 16 patients underwent a LACE procedure with the Y-V modification. Eighty-one percent (13/16) had an anorectal malformation (ARM), and the remainder included Hirschsprung's Disease (1), colonic pseudo-obstruction (1), and spinal cord injury (1). Median age was 8.6 years (range 4.5-34). Median number of previous abdominal operations was 4 (range 0-6). Median operative time and length of stay were 84 minutes (range 74-110) and 3 days (range 2-4), respectively. There were no perioperative complications and no procedures required an open conversion. Median follow-up was 10.5 months (range 1-25). No leakage was reported at the appendiceal stoma and successful control of fecal incontinence was observed in all patients. One patient required a revision due to stomal stenosis.

CONCLUSIONS: The LACE procedure provides a safe and effective means of managing incontinence in patients with a variety of underlying conditions. Our experience demonstrates this technique to be feasible and safe in patients with a history of complex ARM's, many of which have undergone multiple previous abdominal procedures. The umbilical Y-V appendicoplasty provides a convenient location for catheterization while at the same time providing the most cosmetic appearance for older children and adolescents. We therefore believe this technique to be the operative treatment of choice over cecostomy buttons and LACE procedures using traditional orthotopic positioning of the appendiceal stoma.

S026 LAPAROSCOPIC ASSISTED TRANSANAL PULL-THROUGH VERSUS TRANSANAL PULL-THROUGH FOR HIRSCHSPRUNG'S DISEASE

Mustafa Kucukaydin MD, Mahmut Guzel MD, Ahmet N Ciftler MD, Mehmet Uysal MD, Mustafa E. Dorterler MD, Serkan Arslan MD, Ahmet B. Dogan MD, Kadri C. Sulubulut MD, Ali Aslan MD, Erciyes University School of Medicine, Department of Pediatric Surgery

BACKGROUND/AIM: Transanal endorectal resection and pull-through technique (TERP) for Hirschsprung's disease (HD) was described in 1998. It offers the advantages of avoiding laparotomy, scars, and adhesions. In this study, we compared the results of TERP and laparoscopic assisted transanal endorectal resection and pull-through technique (LTERP).

MATERIAL/METHODS: Thirty five HD patients operated on by endorectal pull-through were divided in two groups according to operation technique and compared with each other. Group I had 25 patients (17 boys, 8 girls), age ranged from 12 days to 40 days (average of 24 days) and treated with TERP, between April 2000 and April 2005. Group II had 16 patients (11 boys, 5 girls), age ranged from 10 days to 90 days (average of 45 days) treated with LTERP between May 2005 and November 2007.

Age, operating time, bleeding, perianal excoriation, need of dilatations and functional results were analyzed. The groups were compared using the T-test, Mann-Whitney-U test and Chi-Square test. The differences were considered significant when P values were less than .05.

RESULTS: Age, sex and operating time were not statistically different ($P > .05$). Bleeding, perianal excoriations and need of anal dilatations was less in-group II ($P < .05$). There was no intestinal obstruction secondary to adhesions in the two groups. Good functional results were obtained in the two groups.

CONCLUSION: Although the functional results are similar in group I and group II, we think that LTERP has some advantages to the TERP minimizes blood loss, operating time, perianal excoriations and less need of anal dilatations.

S027 MINIMALLY INVASIVE SURGERY FOR ANORECTAL MALFORMATION IN BOYS

Guillaume Podevin PhD, Thierry Petit MD, Pierre Yves Mure PhD, Martine Demarche MD, Hossein Allal MD, François Becmeur MD, Stephan Geiss MD, Paul Philippe MD, Yves Heloury MD, Departments of Paediatric Surgery of Nantes, Caen, Lyon, Liège, Montpellier, Strasbourg, Colmar, Luxembourg.

INTRODUCTION: The laparoscopic pull-through for high imperforate anus in boys has recently been developed in France and Benelux, since the first description in 2000 by Georgeson et al. The purpose of this study was to evaluate technical difficulties and surgical complications of this approach.

PATIENTS/METHODS: This report was based on a retrospective study from January 2002 to November 2007, including 31 patients from 8 francophone paediatric surgery centres. The recto-urinary fistula found in 30/31 cases, was bulbar in 7, prostatic in 20 and cervical in 3. All patients were treated with colostomy in the newborn period.

RESULTS: Patients were 3.6 months old at surgery (1.6 - 10.4), with a median weight of 5.9 kg (4.2 - 7.8). Surgeons used 3 to 5 trocars, with a diameter from 3 to 12 mm. Fistula was cut without closure in 10 cases, and closed on the genitourinary side after section with a suture in 13, clips in 5 and linear stapler in 2. Median operative duration was 155 mm (80 - 410). One conversion for laparotomy through a pfannenstiell incision was performed in one of the first patients in order to secure the ligation of the fistula. The main per-operative complication, occurred in 5 cases, was linkage of stools from the rectum after the fistula section, requiring in one case a second laparoscopic procedure for washing and for all 5 cases intravenous antibiotics. Median hospital stay was 6 days (3 - 15). During the follow-up of 1.9 years (0.1 - 4.8), patients experienced 8 anal stenosis and 3 prolapses. Two stenosis and one prolapse required perineal redo-surgery.

CONCLUSION: We can consider the laparoscopic approach useful in the cure of anorectal malformation in male, firstly for the easiest control of a high fistula, and secondly because video enhancement help to determine the accurate passage through the levator ani without any injury of pelvic nerves. Nevertheless, technical points have to be improved, such as coprostasis before fistula section to avoid stools linkage, limitation of rectum dissection in order to not promote prolapse, and calibration of muscle channel to keep away from stenosis.

S028 ENDOSCOPY-ASSISTED LAPAROSCOPIC RECTO-BULBAR URETHRAL FISTULA EXCISION IN A MALE WITH IMPERFORATE ANUS

Atsuyuki Yamataka PhD, Yoshifumi Kato PhD, Kyeong Deok Lee PhD, Junichi Kusafuka PhD, Geoffrey J. Lane, Tadaharu Okazaki, Department of Pediatric General and Urogenital Surgery, Juntendo University School of Medicine

AIM: Complete excision of recto-urethral fistula in males with imperforate anus remains challenging, especially if it is recto-bulbar type. The aim of this study was to report a surgical technique to facilitate complete excision of recto-bulbar urethral fistula in males with imperforate anus.



ORAL PRESENTATION ABSTRACTS

CASE REPORT/SURGICAL TECHNIQUE: A male infant with high-type imperforate anus had a right transverse colostomy soon after birth. A distal loopogram demonstrated recto-bulbar urethral fistula. At the age of 6 months, he underwent a routine Georgeson's laparoscopy-assisted colon pull-through. During laparoscopic dissection of the fistula, a fine flexible endoscopy was inserted into the abdomen through a trocar placed in the left lower abdomen then inserted into the rectum through an opening made in the anterior rectal wall using hook diathermy. Endoscopy of the rectum allowed the level of laparoscopic dissection to be observed intra-luminally, allowing the recto-bulbar urethral fistula to be excised exactly at its distal end, so there was no chance of leaving any residual fistula; thus ensuring complete excision of the recto-bulbar urethral fistula. Post-operative recovery was uneventful, and there was no residual fistula on post-operative radiological investigations. He is well at follow-up of 6 months.

CONCLUSION: Our technique facilitates complete excision of recto-bulbar urethral fistula, and is likely to greatly reduce the risk for cyst formation due to residual fistula.

S029 VIDEOTHORACOSCOPIC SURGERY FOR VASCULAR RINGS IN CHILDREN: TECHNICAL CONSIDERATIONS

Piolat Christian MD, Dyon Jean-François MD, Teklali Youssef MD, Durand Chantal, Llerena Catherine, Cartal Marielle, Wroblewski Isabelle, Pin Isabelle, Chu de Grenoble, France

BACKGROUND: Thoracotomy is usually performed to treat symptomatic vascular ring anomalies in children. Recent development of video-thoroscopic surgery (VTS) allows videoendoscopic treatment of vascular ring anomalies (VRA) in children. There is no reported case in the European literature. We describe nine pediatric cases operated on by VTS. We emphasize to describe technical considerations.

METHODS: From November 2005 to October 2007, 9 patients underwent a left videothoracoscopy (3 or 4 trocars) for symptomatic VRA. Mean age of the patients was 5.5 years (range 7 months to 10 years). Vascular ring types included double aortic arch (n = 2), right aortic arch with left brachiocephalic arterial trunk and left ligamentum arteriosum (n = 1) and right aortic arch with left aberrant subclavian artery and left ligamentum arteriosum (n = 6). Diagnosis was suspected on thoracic radiography and confirmed on esophagogramme and MRI (8 cases). VTS allows complete surgical treatment in 8 cases. Compressive vasculofibrous structures were divided and esophagus was slightly dissected.

RESULTS: One patient was converted to thoracotomy because of operative bleeding. One patient developed a chylothorax treated by delayed conventional thoracotomy. There was no other complication and median length of postoperative hospital stay was 4 days (range, 3 to 5). All patients improved clinically at follow-up (3 to 26 months).

DISCUSSION: VTS for VRA is rarely reported in english literature. Feasibility has been demonstrated on few cases but technical details have never been published. Technologic improvement including new instruments (Harmonic scalpel®, Ligasure®) authorize safe division of compressive vascular or fibrous structures. Special attention should be paid to left vagus nerve and left recurrent nerve. Presence of left intercostal superior vein should be a sign of proximity of the thoracic duct. Dissection of the esophagus should be limited in order to prevent nervous or lymphatic damage.

CONCLUSION: Videothoracoscopic repair of VRA in children is feasible and safe in selected cases. Chest x-ray and esophagogram are advantageously completed by preoperative magnetic resonance arteriography allowing precised anatomic study of vascular anomalies and showing non-vascularized compressive remnants. Surgical steps should be the same than those described for conventional thoracotomy but technical specificities should be respected in order to prevent complications.

S030 NUSS PROCEDURE IN A PATIENT WITH PECTUS EXCAVUTUM ASSOCIATED WITH ACCESSORY DIAPHRAGM

Manabu Okawada MD, Tadaharu Okazaki PhD, Akihiro Shimotakahara MD, Geoffrey J. Lane MD, Atsuyuki Yamataka MD, Department of Pediatric General and Urogenital Surgery Juntendo University School of Medicine, Tokyo, Japan

AIM: To report a case of pectus excavatum (PE) associated with accessory diaphragm (AD) that was successfully treated by thoracoscopically-assisted Nuss procedure (NP).

CASE REPORT: A 6-year-old boy with PE was referred to our institute for recurrent bronchitis and pneumonia. Radiological investigations such as plain chest x-ray and computed tomography (CT) showed severe PE with CT index (Haller index) of 4.7, with no evidence of other anomalies. We considered that his clinical symptoms were due to PE, and proceeded to perform a thoracoscopically-assisted NP. However, on insertion of a 5mm thoracoscope into the right thoracic cavity through the 7th intercostal space, a thick, membranous structure arising from antero-lateral intrathoracic wall was identified and the procedure was abandoned. Postoperative thin slice CT scan and magnetic resonance imaging revealed right AD and review of initial radiological investigations (chest x-ray and CT) did in fact show some pathology in the right thoracic cavity. NP was re-scheduled for one month later and the AD was excised thoracoscopically using laparoscopic coagulating shears without difficulty and NP was completed successfully. Histology confirmed that the excised membrane was fibrotic diaphragmatic tissue. Postoperative recovery was uneventful. He is well at follow-up of 2 years with no respiratory symptoms.

CONCLUSION: AD is an extremely rare condition that can cause recurrent respiratory infection. This is the first report of NP being performed in a child with PE associated with AD.

S031 HOW TO GET A MORE STABLE BAR IN PECTUS REPAIR. THE BILATERAL ENDOCLOSE APPROACH

Michele Torre, Patricio Varela, Maria Victoria Romanini, Vincenzo Jasonni, Pediatric Surgery, G. Gaslini Institute, Genoa, Italy; Pediatric Surgery, Calvo Mackenna Hospital, Santiago, Chile

Mini-invasive repair of pectus excavatum with Nuss technique is the preferred technique in most Centers. One of the most important technical point for the final result is the stabilization of the bar, usually obtained by one or more stabilizers and few stitches fixing the bar to some ribs. Our aim is to show how to get the bar more stable by passing bilaterally some stitches around the bar and the ribs close to it. By a right thoracoscopy and a 30° optic we are able to pass the stitches bilaterally using an Endoclose needle. The left thorax is visualized from the right side, pushing the optic through the mediastinum following the bar and staying just below it. The maneuver takes only around 10 minutes.

We have operated 230 patients in two Centers. We have used only one stabilizer in more than 90% of the patients. In all patients we have passed 4 absorbable stitches on the right side using Endoclose. In the last 45 cases we have adopted bilateral fixation of the bar by Endoclose. We did not have complications related to that maneuver. We did not observe destabilization of the bar in those cases. The overall destabilization rate was 1.3%.

We suggest this technique to give the bar more stability on both side. We think the use of bilateral stabilizer is no required

S032 LAPAROSCOPIC STRATEGY FOR INGUINAL OVARIAN HERNIAS IN CHILDREN: WHEN TO OPERATE IRREDUCIBLE OVARY?

Hiroo Takehara MD, Jun Hanaoka MD, Yusuke Arakawa MD, Department of Pediatric Surgery & Pediatric Endosurgery, The Tokushima University Hospital

PURPOSE: Sliding indirect inguinal hernias containing the ovary and fallopian tube are not uncommon in younger girls. Although an irreducible

ORAL PRESENTATION ABSTRACTS



ovary is not at great risk of incarceration, this condition may develop to a significant risk factor of torsion or strangulation. This paper describes when irreducible ovaries should be operated.

MATERIALS/RESULTS: 611 children (388 boys and 223 girls) with inguinal hernia were treated with laparoscopic percutaneous extraperitoneal closure (LPEC) for 12 years. Of 223 girls with inguinal hernia, 40 had a diagnosis of containing ovary in hernial sac. Of them, 14 (ages ranged from 4 weeks to 2 years) were identified irreducible ovarian hernia. 12 were corrected laparoscopically and their hernial orifices were repaired by LPEC. Their ovaries revealed swelling with edema at surgery. One who was waiting for surgery developed to incarcerated ovarian hernia and she was done with oophorectomy. The remaining one was incised the external inguinal ring with small skin incision, and corrected laparoscopically.

DISCUSSION/CONCLUSION: Sliding indirect inguinal hernias containing the ovary and fallopian tube have a possibility to be irreducible ovarian hernia that maybe develops to incarcerated or strangulated ovarian hernia. Many of irreducible ovarian hernias can be corrected laparoscopically and their hernial orifices are repaired easily by LPEC. We suggest that irreducible ovarian hernia should be treated by LPEC, as soon as possible.

S033 COMPARATIVE STUDY OF THORACOSCOPIC APPROACH TO THORACOTOMY APPROACH IN OESOPAGHUS ATRESIA

Allal Hossein MD, Maillet Olivier MD, Kalfa Nicolas MD, Forgues Dominique MD, Galifer RB PhD, Service de Chirurgie Viscerale Pédiatrique, Chu Lapeyronie, Montpellier

BACKGROUND: Thoracoscopic treatment of Oesophageal Atresia (OA) type 3 has been previously reported to be feasible but no study clearly showed the benefits of thoracoscopy compared to open procedure. The aim of this study was to compare the outcome of OA type III treated by thoracoscopic or open procedure.

MATERIAL/METHOD: From January 2000 to December 2006, 31 children were operated, 17 by thoracotomy (weight range from 1750 gr to 4020 gr) and 14 by thoracoscopy (weight range from 2110 gr to 4160 gr). Neonatal deaths from an independent condition (3 cases in thoracotomy group) were excluded from the study and we analyzed 14 children in each group. Analyzed data included length of surgery, length of post operative assisted ventilation, length of pleural drainage, length of stay in ICU, delay before oral feeding, length of morphine analgesia, length of hospitalization and rate of complication.

RESULTS: Length of morphine analgesia was higher in thoracotomy group than in thoracoscopic group (mean 6, 6 days versus 5,3 days, $p=0,16$). Length of hospitalization was also higher in thoracotomy group (mean 22,6 days versus 19,1 days, $p=0,3$). Other studied parameters are presented in the table. The rate of complication with thoracoscopy was not higher need of oesophageal dilatation (21 % in thoracoscopic group versus 14 % in thoracotomy group), need of Nissen fundoplication (21 % in thoracoscopic group versus 28 % in thoracotomy group).

MEAN OF LENGHT		
	Thoracotomy	Thoracoscopy
Intervention	137,5	175
Intubation	4,6	3,8
Pleural Drain	6	5
Oral Feeding	7,5	6,5
Stay of ICU	7,8	7,5

CONCLUSION: Thoracoscopic treatment of OA type III reduces the need of morphine analgesia and the Length Of Stay without increasing the risk of postoperative complications.

S034 LAPAROSCOPICALLY HARVESTED OMENTAL FLAP FOR RECURRENT TRACHEO-ESOPHAGEAL FISTULA IN NEWBORN BABY

Arnaud A. Bonnard MD, Annabel A. Paye-Jaouen MD, Sophie S. Aizenfisz MD, Alaa A. El Ghoneimi PhD, Robert Debre Hospital and Paris VII University, APHP, Paris, France

OBJECTIVES: Recurrent tracheo-esophageal fistula (TEF) can occur in 10 to 15% of oesophagus atresia repair and remains quite challenging to treat. Several surgical solutions have been purposed like glue, diathermy and/or surgery. When the surgery is needed, some authors reported the use of natural flap tissue between the oesophageal anastomosis and the sutured trachea. We report an original technique using an omental flap as a natural tissue harvested previously to the TEF repair by laparoscopic approach.

PATIENTS/METHOD: We report the use of an omental flap tissue brought over the tracheal closure and sutured between the trachea and the oesophagus for 2 patients with recurrent TEF. The flap was dissected and taken down previously to the TEF repair by laparoscopic approach according to Kiricuta technique.

RESULTS: The procedure was done at day of life 110 and 52 respectively. For one, this was associated with a Nissen procedure. The duration of post operative mechanical ventilation did not exceed 4 days and time to first feed was 6 and 22 days post operatively. The average follow up is 20.5 months [17-24] without recurrence.

CONCLUSION: To our knowledge, this is the first report of using an omental flap in surgical treatment of recurrent TEF and laparoscopically harvested. This can be associated with another procedure such as gastrostomy or anti reflux surgery. Furthermore, the laparoscopic approach offers a less abdominal traumatism and better cosmetic result.

S035 RESULTS AND COMPLICATIONS OF THORACOSCOPY IN PLEURAL EMPYEMA: A STUDY OF THE GECI (GROUPE D'ETUDE EN COELIOSCOPIE INFANTILE)

Jean Breaud MD, Eric Fontas MD, Carlos Giné-Prades MD, M. Tambassa MD, M. Demarche MD, François Becmeur MPH, F. Lefebvre MD, F. Bastiani MD, JY kurzenne MD, University Hospital of Nice, Montpellier, Strasbourg, Liège (Belgium), Reims and GECI

Parapneumonic effusion and empyema seems to become more prevalent in the last years, with a 3.3 per 100.000 children's incidence, and may respond to various treatment. Thoracoscopy is efficient, but real surgical complication rate is not yet known.

OBJECTIVE: The aim of this study was to assess morbidity and results of thoracoscopy in pleural empyema.

METHOD: Thoracoscopic procedures performed in five paediatric surgical departments (Montpellier, Strasbourg, Liège, Nice and Reims), from 2001 through 2006, were retrospectively reviewed.

Pre, per and post-operative data were collected, including delay before surgery, aetiology, treatments before surgery, empyema stages, immediate efficiency, hospital stay, rate of complication and follow-up.

RESULTS: A total of 117 patients (71% men, median age 4.5 years) were analysed. In 61.3%, the surgical treatment was delayed over 7.8 days (range, 2 - 30 days) after the first symptoms. Microbial aetiology was similar to others studies. Before surgery, patient's treatments included antibiotics (94.4%), thoracocentesis (34.2%), and chest tube (11.7%). Intraoperatively, empyema stage I, II, and III were observed respectively in 5.1%, 39.4 %, and 55.6%. Thoracoscopy was efficient (>75% pleural space cleaned) in 94.9 %. Mean hospital stay was 11 days (+/- 3.27 days). The mean duration of antibiotic therapy was 15.2 days, mean time to apyrexia was 4.4 days, and mean time to drain removal was 4.7 days. Post-operative surgical complications occurred in 10 patients (8.5%) and resulted in second surgical treatment in 8 patients (7%) (5 thoracoscopy and 3 thoracotomy).

CONCLUSION: Our results suggest an 8.5% rate of surgical complication with thoracoscopy in pleural empyema of this technique



ORAL PRESENTATION ABSTRACTS

(with second surgical treatment in 7 % of cases), with 94.9% of immediate success and a median hospitalisation of 11 days. Concerning this morbidity, thoracoscopic approach, however it's an efficient procedure, has to be compared with other therapeutic strategies like fibrinolysis or antibiotherapy alone in a prospective study. Indications should be discussed according to the symptomatology of the patient rather than the presence of empyema alone.

S036 DUAL LOCALIZATION TECHNIQUE FOR THORACOSCOPIC RESECTION OF LUNG LESIONS IN CHILDREN

Abigail E. Martin MD, James Y. Chen MD, Christopher S. Muratore MD, William W. Mayo-Smith MD, Francois I. Luks MD, Alpert Medical School of Brown University and Hasbro Children's Hospital

BACKGROUND: Thoracoscopic wedge resection has gained widespread acceptance as a method of resecting pulmonary metastases in pediatric cancer patients. This is most successful for lesions on the pleural surface that can be identified without palpation. Deeper lesions can be marked by preoperative CT-guided techniques, but neither needle localization nor dye injection alone is fool-proof. We present our experience with a dual localization technique.

METHODS: Under CT guidance, a 22 G needle is advanced to within 1cm of the lesion and 0.1 mL of methylene blue is injected. A Kopans breast biopsy hook wire is then introduced through the needle and its tip placed within the lesion. Its tail is cut flush with the chest wall. The patient is transferred to the operating room and a wedge resection around the hook wire is performed thoracoscopically.

RESULTS: Six deep pulmonary metastatic lesions were preoperatively localized in four pediatric patients, ages 8-16. Median localization time was 30 min. All lesions were successfully marked and identified at operation. Margin-free resection of the lesion was successful in all cases.

CONCLUSION: Thoracoscopic resection of metastatic pulmonary lesions in children using preoperative localization with both wire localization and methylene blue injection is safe and effective. This method allows successful localization of lesions even in the event of either dislodgement of the wire or over-infusion of the methylene blue dye.

S037 GASTROSCOPIC ASSISTANT SURGICAL MANAGEMENT OF PYRIFORM SINUS FISTULA IN CHILDREN

LV Zhibao MD, Xiao Xianmin MD, Zheng Shan MD, Department of Surgery, Children's Hospital, Medical Center of Fudan University

PURPOSE: Third and fourth branchial remnants may result in cysts and abscesses that are in close contact with the thyroid. These anomalies are rare and often present diagnostic and therapeutic challenges. We present 43 cases of pyriform sinus fistula to highlight recent trends in diagnosis and management.

METHODS: The clinical data of 43 cases as pyriform sinus fistula at our pediatric hospital were reviewed for the period from January 1990~ to June 2007. the age at diagnosis ranged from 2.5 to 14 years with a mean of 7.5 years. The male to female ratio was 23:20. Presenting symptoms consisted of an asymptomatic cervical mass (n=4), twice or more episodes of infection (n=23, up to 6 previous episodes, mean 3.4), recurrence of primary fistulectomy (n=16). The diagnosis was identified by barium swallow, CT, ultrasonography, and scintigraphy. The left side was predominantly involved, with the left-to-right ratio being 41:2. Between 1990 and 1999, 8 patients operated by fistulectomy and ligation without endoscopic assistant identification (EAI). Between 1999 and 2007, 35 patients done by fistulectomy and ligation with EAI, the patients were subjected to endoscopy to identify the internal orifice intraoperatively, the fistula was showed by injection of methylene blue, resect and ligate the fistula at the level of the pharynx.

RESULTS: In EAI group, the mean operation time was 1 h and 35 min, all of 35 patients did well postoperatively and shown no recurrences during follow-up term. In without EAI group, the mean operation time was 2 h and 12 min, no evidence of a tract was found in 3 patients (37.5%), recurrent infection had been noted in 2 patients (25%).

CONCLUSIONS: The diagnosis and management of pyriform sinus anomalies are challenging. Gastroscopic assistant fistulectomy is a simple, quick and effective operation.

S038 MICROLAPAROSCOPIC ASSISTED GASTROSTOMY IN CHILDREN – OUR TECHNIQUE

Salmai Turial MD, Martin Schwind MD, Veronika Engel MD, Cordula Scherer MD, Walid Treef MD, Felix Schier MD, Department of Pediatric Surgery, University Medical Center Mainz

PURPOSE: The aim of this prospective study is to evaluate the feasibility and safety of the microlaparoscopic assisted gastrostomy (MAG) in children. We report our experiences with this method.

METHODS/PATIENTS: 12 children (aged 4 months to 4 years, median 1.2 years) underwent MAG. Under low-pressure insufflation a microlaparoscope (diameter from 1.7mm to 1.9mm) was inserted at umbilicus and a single 2mm miniport placed in the left lower abdominal wall in the first 8 cases. At the entrance site of the gastrostomy the stomach was lifted to the abdominal wall with a 1.9mm grasper. Under laparoscopic control the stomach wall was exteriorised through the 1cm incision for the gastrostomy tube. In the last 4 cases we just inserted a 5mm trocar at the prospected position of the gastrostomy tube, the stomach wall was grasped and exteriorised by simultaneous removal of the trocar. After a purse string suture the stomach was opened by electrocautery and a gastrostomy tube was placed in stomach. Similar to the open method the stomach serosa was fixed to the peritoneum with two additional stitches. After finishing the procedure the postoperative situs was controlled laparoscopically.

RESULTS: The mean operation time for MAG was 19 minutes (range 13 to 35 minutes), the mean time until feeding was 5 hours (range 4 to 12 hours). No intraoperative complications occurred. Follow up over six weeks has shown no early postoperative complications such as leakage, herniation of omentum or local wound infections. Nearly scarless healing of the 2mm port side and gastrostomy tube side was noted. We compared the results of microlaparoscopy group with the laparoscopic and to the "open" gastrostomies.

CONCLUSIONS: It is our suggestion that the microlaparoscopic assisted gastrostomy in children is a feasible and safe procedure with better results. Microlaparoscopic assisted gastrostomy is a simple method particularly in cases where percutaneous tube placement is not feasible. It combines the advantages of microlaparoscopic and open surgery. It is easy to perform in children and allows a primary gastrostomy tube or button placement. We have seen good parents- and nursing staff satisfaction.

S039 AGE + 10: A SIMPLE AND RELIABLE FORMULA FOR PROPER JJ STENT LENGTH IN THE PEDIATRIC PATIENT

Jeffrey S Palmer MD, Lane S Palmer MD, Glickman Urological and Kidney Institute, Cleveland Clinic Children's Hospital, Cleveland, Ohio, USA; Schneider Children's Hospital, North Shore-Long Island Jewish Health System, New Hyde Park, New York, USA

OBJECTIVES: The proper length of a double J (JJ) stent inserted in the pediatric population is determined empirically by the urologist. However, is there an accurate and easy to recall mathematical relationship between JJ stent length and another parameter, such as age? We evaluated if such a relationship exists between the age of the child and the appropriate JJ stent length.

METHODS: We reviewed the ages and JJ stent length inserted in all children over the past 6 years. The proper stent length was defined as a gentle curve of the distal coil within the bladder (direct vision) and the proximal coil within the renal pelvis (fluoroscopically or ultrasound). The

ORAL PRESENTATION ABSTRACTS



data were stratified according to laterality and gender. Regression analyses were then performed between stent length and patient age.

RESULTS: There were 228 patients, age range 2 months to 17.9 years, who were stented during this time period. The surgeries for which a stent was used included renal surgery, stone disease, and ureteral reimplantation. The regression analyses demonstrated consistent and reliable (r) relationships between patient age and JJ stent length irrespective of laterality or gender. The general relationship determined between stent length and age is: $\text{STENT LENGTH} = \text{PATIENT AGE (years)} + 10$.

CONCLUSIONS: This study demonstrates that simply adding 10 to the patient's age is an accurate and reliable "rule of thumb" to determine proper length of JJ stent in children irrespective of gender or laterality.

S040 FAST-TRACK LAPAROSCOPIC SURGERY OF THE KIDNEY AND RENAL PELVIS

Marc Reismann MD, Jens Dingemann MD, Mirja von Kampen, Mathias Wolters, Martin L Metzelder MD, Robert Suempelmann PhD, Benno M. Ure PhD, Department of Pediatric Surgery and Department of Anesthesiology, Hannover Medical School

BACKGROUND: Fast-track surgery is not well established for infants and children. We recently confirmed in 2 comprehensive studies an excellent feasibility of fast-track concepts and high patient/parent satisfaction in routine pediatric surgery. The aim of this study was to determine the applicability of fast-track concepts in pediatric surgery of the kidney and renal pelvis.

METHODS: Fast-track concepts were established for nephrectomy, heminephrectomy and pyeloplasty. The fast-track concepts included anxiolysis, avoidance of drains and catheters, laparoscopic techniques, immediate postoperative feeding and mobilization, and a specific pain control concept. All patients up to 17 years of age undergoing these procedures were studied prospectively up to 2 weeks after the operation between June 2004 to June 2005 and June 2006 to June 2007. Pain measurement, discharge criteria and follow-up methods were standardized. The length of hospital stay was compared with data derived from the German reimbursement system with German diagnosis-related groups (G-DRGs) for patients with similar diagnosis, a similar case mix index and hospitals with a similar structure.

RESULTS: Out of a total of 63 patients 59 (94%) were successfully treated according to fast-track concepts (25 nephrectomies, 34 pyeloplasties). The mean age was 3.3 ± 4 years. All fast-track procedures were performed laparoscopically. Reasons for exclusion from fast-track were concomitant diseases in 3 cases (nephrectomy) and former prematurity in an infant younger than 6 months (pyeloplasty). Compared to G-DRG data the mean hospital stay was reduced (3.6 ± 1.8 vs. 12.5 ± 1.8 , $p < 0.01$). At follow-up, no complications attributable to fast-track treatment were recorded. Complete convalescence was reached after a mean of 6.2 postoperative days. All parents and patients judged fast-track care as excellent.

CONCLUSION: Fast-track concepts including laparoscopic techniques are feasible in almost all pediatric patients undergoing (hemi-)nephrectomy and dismembered pyeloplasty. The feasibility is excellent with accelerated convalescence, minimal hospital stay and maximal patient satisfaction.

S041 LAPAROSCOPIC PROCEDURES IN PEDIATRIC GYNECOLOGY

Igor V. Poddoubnyi MD, Tatiana M. Glybina MD, Andrei A. Isaev MD, Alexei B. Okulov MD, Elena V. Fedorova MD, Moscow State University of Medicine and Dentistry, Department of Pediatric Surgery

The purpose of this study is to analyze our present experience of more than 800 laparoscopic gynecologic interventions in children:

I. 750 procedures for benign ovarian and paraovarian lesions. Among them: 220 urgent operations were required in complicated cases- torsion, rupture, acute inflammation etc.; Laparoscopic procedures for large and giant masses (more than 10-15 cm in diameter, occupying more than

25% of the peritoneal cavity, with maximal volume reaching 11.5 l) were performed in 62 girls. The character of removed masses was – teratomas (30), cystadenomas (14), paraovarian cysts (18); Laparoscopy was used in 29 newborns and infants (from 5 days to 6 months) with ovarian cystic lesions. In 17 cases the palpable cystic mass was detected; 6 patients presented distinct clinical symptoms, including three cases of partial bowel obstruction; 12 were asymptomatic. On laparoscopy: prenatal torsion and necrosis was confirmed in 20 patients; in 13 autoamputation of the fallopian tube had already occurred; 4 cysts were floating free in the peritoneal cavity; significant inflammatory or adhesive process was detected in 9, with partial bowel obstruction in 3. Laparoscopic adnexectomy was performed in 20 patients; in 9 ovary-sparing cyst excision was accomplished (teratoma- in 1).

II. Laparoscopic procedures for uterus and vaginal malformations were performed in 56 patients (from 6 months to 17 years). The typical indications were: different variants of duplication anomalies; high vaginal atresia; rudimentary uterus; congenital absence of the vagina; in 4 cases' concomitant laparoscopic nephrectomy was required.

In 17 patients with Mayer-Rokitansky-Kuster-Hauser syndrome (MRKHS) two variants of laparoscopic treatment were used: In 10 patients with existing 1-3 cm of distal vagina - laparoscopic vaginal elongation was elaborated. This simple method made it possible to elongate vagina up to 9-11 cm depth and to avoid more complex surgical operations; In 11 patients (7 with MRKHS and 4 with testicular feminization syndrome) laparoscopic sigmoid vaginoplasty was performed. Three trocars were used; the operating time varied from 95 to 160 min.; no complications and no cases of conversion occurred; cosmetic and functional results are excellent in all cases.

Our materials confirm nearly 100% effectiveness of laparoscopic technologies in the treatment of children with benign adnexal lesions and wide range of congenital uterus and vaginal malformations.

S042 VIDEOCYSTOSCOPIC URETERAL REIMPLANTATION USING REGULAR TROCARS. A PROSPECTIVE COMPARATIVE STUDY

Edward Esteves MD, Bernardina B. Modesto MD, Jose Ferreira-Silva MD, Claudia M. Salgado PhD, Pediatric Surgery Division, University of Goias, Brazil

INTRODUCTION: Among the surgical options for vesicoureteral (VUR) the transtrigonal reimplantation (bilateral -Cohen, unilateral-Glenn-Anderson) is the one that allows better results and less recurrences after late follow-up, being the gold standard for this disease. The traditional access has been achieved through open extraperitoneal Pfannenstiel laparotomy. Some authors have already described videocystoscopy using pneumobladder and special trocars with functional outcomes identical to open surgery, with the advantages of the videosurgery.

OBJECTIVE: The authors present their initial series analysing the ideal criteria for indication, describing the basic techniques using regular trocars and the ultimate outcome. Comparative data with a similar group of patients managed by conventional operation are presented

PATIENTS/METHODS: 32 consecutive children (4 to 16 years) presenting VUR grades 3-5 were randomly assigned for video or conventional treatment (transtrigonal techniques) according to the following criteria: children above 4 years, mild or severe obesity at the inferior abdomen, absence of serious vesical dysfunction. Seventeen (12 bilateral and 5 unilateral) were submitted to videocystoscopic transtrigonal ureteral reimplantation. One was a redo after open surgery. Other 6 submitted to Gregoire technique were not included. Basic technique for video-reimplantation: pneumobladder with CO2 infused through a urethral tube up to 6mmHg, 1 infraumbilical trocar for a 3.5 mm intravesical laparoscope, 2 trocars for 2.5 or 3mm instruments at the right and left hypogastrium; surgical team in position for pelvic surgery, videomonitor at the feet; intravesical ureteral dissection, manipulated by



ORAL PRESENTATION ABSTRACTS

a transperitoneal meatal suture; submucous transtrigonal tunnel for one or two ureters; reimplantation with PDS or Vicryl 5-0 or 6-0, without postoperative ureteral stents; silicone urethral tube for 48 hours. Fifteen were operated through conventional operations.

RESULTS: No complications in both series. No recurrences after a follow-up of 12-46 months. Video: mild pneumoretroperitoneum in case 3, Operating times 1-2.5 hours. Comparing both groups, the videogroup showed longer operating time, less hematuria, less pain-dysuria, better cosmesis.

CONCLUSION: Transvesical transtrigonal ureteral reimplantation can be accomplished successfully and safely in children through videocystoscopy with comparable functional outcome to open surgery and better recovery, better cosmesis.

S043 LAPAROSCOPIC DISMEMBERED PYELOPLASTY BY A TRANSABDOMINAL APPROACH IN INFANTS

Qiangsong Tong MD, Shaotao Tang MD, Yongzhong Mao MD, Yong Wang MD, Qinglan Ruan MD, Department of Pediatric Surgery, Union Hospital of Tongji Medical College, China

PURPOSE: To explore the feasibility of laparoscopic transabdominal dismembered pyeloplasty in infants.

MATERIALS/METHODS: A total of 23 consecutive infants (16 male and 7 female) underwent laparoscopic transabdominal dismembered pyeloplasty using a 3-trocar technique. All patients had confirmed unilateral deterioration of renal function on isotope renography and MRI. The 23 patients were divided into 3 age groups: 1 to 4 months (group 1, 6 patients), 5 to 8 months (group 2, 8 patients) and 9 to 12 months (group 3, 9 patients). Follow-up included clinical and ultrasound assessment, and isotope renography at 3 months.

RESULTS: Laparoscopic pyeloplasty was feasible in 22 of 23 patients (95.6%). Mean operative time was 185 minutes (range 110 to 260). The operation was converted due to bleeding in one patient. Mean operative time in 22 successful laparoscopic procedures was not significantly different among the 3 age groups (182 minutes in group 1, 174 minutes in group 2 and 178 minutes in group 3). Mean followup was 25 months (range 3 to 72). A total of 22 patients (95.6%) were asymptomatic and had improved PUJ drainage on isotope renography. One patient underwent redo pyeloplasty due to recurrent hydronephrosis at 2 years.

CONCLUSIONS: Laparoscopic dismembered pyeloplasty by a transabdominal approach is effective and safe in infants younger than 1 year. The transabdominal approach revealed good exposition without a disadvantage for the patient.

S044 LAPAROSCOPIC INSERTION WITH TIP SUTURING, OMENTECTOMY AND OVARIOPEXY IMPROVES LIFESPAN OF PERITONEAL DIALYSIS CATHETERS IN CHILDREN

A. Numanoglu MD, L. Rasche MD, M. Roth MD, M. I. McCulloch MD, H. Rode MD, Departments of Paediatric Surgery and Nephrology, Red Cross Children's Hospital and University of Cape Town, South Africa

Over the past two decades chronic peritoneal dialysis (PD) has emerged as the first choice pediatric dialysis modality. We previously published our results visually identifying the cause of malfunction of PD catheters. The reasons that could be found, lead to changed Tenckhoff insertion-techniques from open to laparoscopic. This included suturing of the tip, omentectomy and ovarian-pxy by laparoscopy. In the present paper we prospectively analyzed, if changed insertion technique lead to an improved outcome.

PATIENTS/METHODS: 26 Patients required 36 laparoscopic Tenckhoff insertions during the period August of 2003 and July of 2006. Overall a total number of 222.5 catheter-months have been observed. Laparoscopic insertion technique required 3 x 5mm port placements. The tip of the catheter was sutured to pelvic peritoneum, omentectomy performed through a port site and ovariopexy done when required.

RESULTS: The mean lifespan of all Tenckhoff's was 6.4 ± 6.3 months. The tip of the catheter was sutured 20 times; omentectomy done in 9 cases and 6 patients underwent ovarian pxy. In the group where the tip was sutured to the pelvic peritoneum catheter life was 8.4 months compared to the non-sutured group which was only 4.1. Omentectomy lead to an overall catheter survival of 8.0 months compared to the no omentectomy group, which had a survival of 5.8 months. The complication-rate concerning early problems and malfunctions in the sutured and omentectomy groups was also lower. Patients who underwent both, suturing of the tip and omentectomy had no malfunctions at all.

CONCLUSION: Omentectomy and suturing the tip can lower the complication-rate and prolong catheter survival. Using these procedures could decrease costs and morbidity and prevent patients from having further operations.

S045 RETROPERITONEOSCOPIC UPPER-POLE NEPHROURETERCTOMY IN YOUNG CHILDREN WITH DUPLEX SYSTEMS

Al Hindi S, Asgar M, from the Divisions of Pediatric Surgery Salmaniya Medical Complex, Manama, Kingdom of Bahrain

OBJECTIVE: To report the outcome of retroperitoneoscopic upper-pole nephroureterectomy in young children with Duplex Systems.

DESIGN: Young children with duplex system and dilated upper-pole were prospectively studied between January 2003 and November 2007.

RESULTS: Eight retroperitoneoscopic upper-pole nephroureterectomy (5 on the left and 3 on the right) were performed in 8 patients. Renal ultrasonography, DMSA, voiding cystourethrography done in all cases. the operative time ranging from 90 minutes to 120 minutes. There were no conversions to open surgery and no transfusions. Two cases developed seroma post operative which resolved by conservative treatment. Follow-up from 12 months to 36months resulted in preserving the lower moiety.

CONCLUSION: The initial outcome retroperitoneoscopic upper-pole nephroureterectomy in young children with Duplex Systems is feasible and safe.

S046 SURGERY OF DEFERENTIAL REFLUX IN PEDIATRIC VARICOCELE BASED ON PREOPERATIVE COLOR DOPPLER ULTRASOUND ASSESSMENT

M. Cimador MD, Maria R. Di Pace MD, P. Catalano MD, M. Sergio MD, M. Castagnetti MD, E. De Grazia MD, Dept. Of Mother & Child, University Of Palermo, Italy

BACKGROUND: This study aimed to assess whether laparoscopic treatment for any kind of varicocele is possible after preoperative identification of refluxing veins by color Doppler ultrasound (CDUS).

METHODS: At the authors' institution, 98 patients with a median age of 11.3 years (range, 7.1-16 years) were evaluated for a left varicocele. Preoperatively, all the patients underwent ultrasound scan assessment of testicular volume and CDUS to rule out reflux into the internal spermatic vein (ISV), deferential vein, or cremasteric vein. Boys presenting on CDUS with reflux in the ISV were treated via a transperitoneal Palomo procedure. A 5-mm, 0° umbilical telescope and two operating ports were placed. A peritoneal window was created, followed by careful dissection of the ISV and spermatic artery off the retroperitoneal fat. During this step, care was taken to avoid any injury to the fat, thus averting as much as possible any injury to the lymphatic vessels lying on it. Laparoscopic division of the spermatic artery and veins was performed. Patients presenting at surgery with dilated deferential vein(s) proved by preoperative CDUS to be refluxing were treated by a Palomo procedure, as described earlier but combined with coagulation and division of deferential vein(s) as follows. The retroperitoneal window was widened toward the internal inguinal ring. The deferential vein(s) running as satellites of the vas were gently dissected off the deferential artery, which

ORAL PRESENTATION ABSTRACTS



was spared because it could remain the almost unique blood supply of the testicle. The deferential vein(s) then was coagulated with bipolar diathermy and divided. Sometimes it is easier to approach the deferential vein(s) in the deep pelvis just beneath the iliac vessels. In these cases, a second retroperitoneal window is required..

RESULTS: Color Doppler ultrasound showed reflux only in the ISV in 87 cases (88.7%), but in both the ISV and the deferential in the remaining 11 cases (11.2%). During a median follow-up period of 18 months (range, 6-49 months), none of the authors' patients experienced varicocele recurrence either clinically or according to CDUS scanning. The median left testicular volume increased significantly postoperatively.

CONCLUSION: The proposed technique based on laparoscopic interruption of the ISV and testicular artery very close to the internal inguinal ring, meticulous CDUS assessment to rule out reflux in the deferential vein, and coagulation of refluxing deferential veins allows successful laparoscopic treatment of most varicoceles.

S047 PNEUMOVESICOSCOPIC MARSUPIALISATION OF COMPLICATING ECTOPIC URETEROCELES CAUSING BLADDER OUTLET OBSTRUCTION IN YOUNG INFANTS

Jennifer Sihoe MD, K.H. Lee MD, Division of Paediatric Surgery and Paediatric Urology, Department of Surgery, Chinese University of Hong Kong, Prince of Wales Hospital, Hong Kong SAR, China

BACKGROUND: Duplex kidneys with large complicating ectopic ureteroceles have always posed a clinical challenge to paediatric urologists and its management remains controversial. However, it is generally well accepted that endoscopic incision has a role in urgent interventions for young infants presenting with urosepsis or significant urinary obstruction. Despite this, incomplete decompression has been reported in 10-25% of cases necessitating further surgery. We herein review 2 cases of bladder outlet obstruction (BOO) following endoscopic incision and describe our initial experience with pneumovesicoscopic marsupialisation.

MATERIALS/METHODS: Two patients (both girls) with bilateral duplex kidneys and an obstructed unilateral upper moiety ectopic ureteroceles underwent urgent endoscopic incision at 3 and 7 months of age. Both showed evidence of incomplete decompression requiring a repeat procedure. One patient had persistent upper tract dilatation on post-operative imaging and the other was noted to have straining on micturition with decreased urine output despite complete decompression. Both subsequently underwent pneumovesicoscopic marsupialisation of ureteroceles. The procedure was performed in the supine position with legs apart. Pneumovesicum was achieved by carbon dioxide insufflation of the bladder up to 12mmHg. One camera port (5mm) was placed at the dome and another 2 working ports (5mm and 3mm) were placed at the left and right lower bladder. The ureterocoele was completely marsupialised using electrocautery.

RESULTS: Pneumovesicostomy confirmed adequate incision in both cases. However, significant BOO was caused by prolapse of the bulky flaps of the decompressed ureterocoele into the bladder neck. Complete marsupialisation was performed with a mean operating time of 80 minutes. A urethral catheter was left in-situ for 3 days and the patients were discharged following a course of antibiotics. Both patients have remained well and asymptomatic on follow-up (5 and 11 months). There were no procedure related complications.

CONCLUSION: Our initial experience in pneumovesicoscopic marsupialisation have demonstrated this to be a safe and effective procedure in children. Pneumovesicostomy provides a clear visualization of the anatomy helpful in the planning of subsequent definitive surgery. The approach allows complete marsupialisation of the ureterocoele including prolapsing remnants which may be pulled back into the bladder and excised. Long-term outcomes are eagerly anticipated.

S048 MULTIPOLAR, WATER-COOLED, RADIOFREQUENCY INDUCED THERMOTHERAPY WITH 3-D IMPEDANCE FEED-BACK - PROSPECTIVE STUDY TO OPTIMIZE LAPAROSCOPIC SUBTOTAL 90% SPLENECTOMY FOR SPHEROCYTOSIS AND ITP

Klaus Schaarschmidt PhD, Andreas Kolberg-Schwerdt MD, Michael Lempe MD, Frank Schlesinger MD, Martina Hüging MD, Jan Patino Mayer MD, Helios Center for Pediatric & Adolescent Surgery, Berlin-Buch, Germany

INTRODUCTION: Subtotal Splenectomy requires extensive reduction of splenic volume, which is often limited by anatomical variations of splenic vessels. Radiofrequency ablation (RF) assisted organ resection has been tried for hemihepatectomy and splenic cysts but traditional unipolar RF does not coagulate sufficient volumes for subtotal splenectomy. New improvements of radiofrequency induced thermotherapy (RFITT) by multipolar coagulation (2-3 bipolar probes, Celon, ProSurge), water-cooling and 3-D microprocessor impedance feed-back (3D-mRFITT) control larger volumes reliably, optimize hemostasis and/or tissue ablation during laparoscopic subtotal splenectomy and help to achieve target volumes of 10% residual spleen.

METHODS/PROCEDURES: From 2/2002 - 12/2007, 87 children aged 9.1 +/- 4.5 years (range 1.1 - 20.4 y) requiring 0:122 transfusions for symptomatic spherocytosis or ITP underwent laparoscopic subtotal splenectomy in Berlin-Buch. Following a series in mini-pig-spleens, 3D-mRFITT was applied by laparoscopy prospectively in 2007 in 11 laparoscopic subtotal splenectomies to facilitate bloodless resection and reduce target volumes in spleens with unfavourable vascular anatomy. Via 2 bipolar electrodes and 3-4 ports 28.7-43.6 W and energies of 65-71.5 KJ were applied to transection area and/or splenic rest and the spleens divided by ultrasonic scalpel.

RESULTS: Laparoscopic subtotal splenectomies with laparoscopic 3D-mRFITT were without complications except 1 left pleural effusion. Laparoscopic 3D-mRFITT allowed excellent hemostasis (Blood loss 60- 190ml, including a Jehovah's witness and portal hypertension) plus a reduction of splenic volume to $10.5 \pm 4\%$ of splenic volume. Late viability of splenic rests was proven by doppler and scintigraphy. Hemoglobin/Thrombocytes rose permanently and significantly ($p < 0.0001$, paired Student t-test) to Hgb from 4.9 ± 1.3 g/dl (lowest preop) to 13.1 ± 1.1 g/dl (lowest postop) with no postoperative transfusion required.

CONCLUSIONS: Bipolar or multipolar radiofrequency does not endanger small hilar vessels like monopolar radiofrequency ablation. Although preliminary experience is limited, 3D Multipolar Watercooled Radiofrequency Induced Thermotherapy (3D-mRFITT) is a major improvement in laparoscopic subtotal 90% splenectomy so far, which will allow further endoscopic indications like hypersplenism in cystic fibrosis, thalassemia, or hepatic/thoracic hemangiomas and lymphangiomas.

S049 INITIAL EXPERIENCE WITH SURGICAL TELEMENTORING IN LAPAROSCOPIC SURGERY USING REMOTE PRESENCE TECHNOLOGY

Steven S. Rothenberg MD, Suzanne Yoder MD, Sandra Kay BA, Todd Ponsky, Rocky Mountain Hospital for Children

PURPOSE: To evaluate the efficacy of remote presence technology in surgical mentoring

METHODS: A robot which is controlled from a wireless remote control station (Laptop computer), is self propelled, and provides two way audio and visual communication was used to allow a senior surgeon to provide mentoring during three unique laparoscopic cases. This first was a laparoscopic exploration in a 9 month old with clinical evidence of intermittent obstruction but non-diagnostic imaging studies. The second was a 4 day 3kg infant with a CDH, and the third was a one day old with duodenal atresia. The robot was used to visualize the patient and radiologic studies, telestrate suggestions for trocar placement, visualize the laparoscopic procedure, and provide advice during the procedure. In the



ORAL PRESENTATION ABSTRACTS

second case another surgeon at a remote site control station watched the surgery and asked questions.

RESULTS: The procedures were completed successfully in 90, 30, and 90 minutes. The first case included identification of the obstructing lesion (internal jejunal polyp) and intestinal resection and anastomosis. The second, resection of the hernia sac and repair, and the third identification of the site of atresia and identification of the site for the proximal and distal enterotomies. The robot allowed for excellent visualization of the procedures and direct communication between the surgeon and telementor uninterrupted throughout the case. Both surgeon and Mentor felt the tele-mentoring assisted in the case.

CONCLUSIONS: While this is a limited series the initial evaluation of this remote presence technology in the OR suggests that it may be extremely usefully in adding surgical experience and expertise in minimally invasive surgery.

S050 WORKFLOW ANALYSIS OF LAPAROSCOPIC NISSEN FUNDOPLICATION IN INFANT PIGS - A MODEL FOR SURGICAL FEEDBACK AND TRAINING

Alexandra Krauss, Oliver J. Muensterer PhD, Thomas Neumuth BS, Robin Wachowiak MD, Bernd Donaubauer MD, Werner Korb PhD, Oliver Burgert PhD, Departments of Pediatric Surgery and Anesthesiology/Intensive Care Medicine, University of Leipzig; ICCAS - Innovation Center Computer Assisted Surgery, Leipzig

BACKGROUND: Many nonmedical professions use workflow analysis to assess and improve performance of complex tasks. Advanced pediatric endosurgery requires efficient strategic planning of the procedure in general, and meticulous motor skills in detail. Workflow analysis may help optimize both these aspects by breaking down the operation into particular phases, evaluating these steps individually and thereby supplying appropriate feedback to the surgeon.

OBJECTIVE: To develop a module of computer-based surgical workflow analysis for Nissen fundoplication and to evaluate its applicability and usefulness in an infant pig model.

Materials and Methods: Laparoscopic Nissen fundoplication was performed in 12 young pigs (weight 7-10 kg) by a single surgeon who had previously performed over 70 such procedures in children. Based on synchronized intra- and extracorporeal movie recordings, the surgical workflow was segmented into temporal operative phases (preparation including positioning/handling/anesthesia, entry and dissection, hiatal reconstruction, placement of collar stitches, actual fundoplication, and closure). During each stage, all actions were recorded in a virtual timeline using a specially-developed workflow analysis computer program. Specific tasks evaluated in detail included tool-usage and knot-tying. The time necessary to perform these actions was compared for each operation throughout the study.

RESULTS: Exemplary times required to perform the specific phases (dissection/hiatal reconstruction/fundoplication/total OP-time) for the pigs in the beginning, midterm, and end of the experimental series were 13/10/10/42, 17/16/12/56, and 12/12/13/43 minutes, respectively. While time required for the preparation (premedication, anesthesia, intubation, positioning, set-up) decreased by more than half from 61 to 29 minutes, most other phases remained relatively stable. Median time to perform a 5-throw knot was 67 seconds in pig 2, 104 seconds in pig 7, and 94 seconds in pig 11. Over the course of the experiment, the number of complications and events requiring interruption of the standard workflow decreased from a total of 7 in the first to 3 in the last 6 pigs.

CONCLUSION: Our workflow analysis model allows the quantitative evaluation of dynamic actions related to laparoscopic fundoplication. This data can be used to define average benchmark criteria for the individual tasks that comprise the complex operation. It thereby permits task-oriented refinement of surgical technique as well as monitoring the efficacy of training. Although preoperative preparation time decreased substantially,

time required to perform all other operative phases remained relatively constant for a surgeon with moderate clinical experience. Likewise, knot-tying did not accelerate over the course of the experiment in this individual.

S051 FEASIBILITY OF MINIMALLY INVASIVE SURGERY IN NEONATES

C. K. Sinha MS, S. Paramalingam MS, M. Davenport MS, S. Patel MS, N. Ade-Ajayi, King's College Hospital, London, UK

INTRODUCTION: The use of Minimally Invasive Surgery (MIS) is still limited in neonates and young infants. We undertook a systemic review to quantify the feasibility of MIS in neonates (and infants < 5kg). **METHODS:** A systematic search of the databases was performed. Herniotomy and pyloromyotomy were excluded in view of substantial reports in the literature. From 49 papers, data of 1215 patients were included. Various operations were assessed in term of operative times, conversion rates and complications.

MAIN RESULTS: Commonly performed laparoscopic/robotic operations were fundoplication (n=473), operations for ovarian pathology (n=151), esophageal atresia [EA]/tracheoesophageal fistula [TEF] (n=123), diagnostic (n=90), lung biopsy (n=72), biliary atresia [BA] (n=61), Ladd's procedure (n=55), bowel atresia (n=45), congenital diaphragmatic hernia [CDH] (n=41) and others (n=204). One death was mentioned in the CDH series, where as mortality in TEF group was 3%. The results of a few common procedures have summarized in the table.

CONCLUSION: Fundoplication and operations for ovarian pathology were the most commonly performed procedures with minimal complications and low conversion rates. In experienced hands, most of the complex procedures were feasible with outcome comparable to conventional approach.

OPERATION	Mean time (min)	Conversion	Complication
Fundoplication	43	0.2%	4%
Ovarian surgery	54	4.4%	0%
EA / TEF	130	6.2%	Leak - 8%
BA	209	1.7%	3%
CDH	104	14.8%	11%

S052 ROBOTIC SURGERY FOR INFANTS AND SMALL CHILDREN: IS THERE ROOM FOR THIS?

John J. Meehan MD, Laura A. Phearman RN, Seattle Children's Hospital & Regional Medical Center, Children's Hospital of Iowa

PURPOSE: Pediatric surgeons have criticized robotic surgery because the only available surgical robot seems too large to use in smaller patients. However, the current robot can be used to accomplish a wide variety of procedures even in small children. A small number of these patients were presented at IPEG in an unpublished preliminary report in 2005. We now present a large series of patients in an IRB approved retrospective paper.

METHODS: We reviewed the first 180 consecutive pediatric patients who underwent robotic procedures by the lead author. Only patients less than or equal to 10.0 kg were selected. All procedures were performed using the 3 arm Da Vinci surgical robot (Intuitive Surgical; Sunnyvale CA) with one camera arm (5 or 12 mm) and two instrument arms (5 or 8 mm).

RESULTS: Forty-five patients (25.0%) met inclusion criteria. These 45 patients had 47 procedures with two patients having additional robotic procedures during the same operation. Average age was 8 months (1 day-27 months). Average weight was 6.8 kg (2.2-10.0). Thirteen patients had 14 thoracic procedures (29.8%). Thirty-two patients had 33 abdominal procedures (70.2%). Abdominal procedures attempted included fundoplication (25), neuroblastoma resection (2), Kasai (2), duodenal atresia (1), gastric duplication (1), pyloroplasty (1), and CDH from the abdomen (1). Thoracic

ORAL PRESENTATION ABSTRACTS



procedures included lobectomy/segmentectomy for intralobar sequestration (3) or CCAM (2), CDH repaired from the chest (3), bronchogenic cyst (2), eventration (2), TEF (1), and cystic hygroma (1). Overall procedure completion rate was 89%. Three patients (6.6%) were converted to open and two (4.4%) were converted to standard MIS. Two of the open conversions occurred for better understanding of the anatomy (gastric duplication, CCAM). One was opened because single lung ventilation was inadequate to proceed (cystic hygroma). Two thoracic patients (4.4%) were converted to thoracoscopic procedures because of poor initial trocar placement in regards to complete movement of the robotic instruments (CDH, eventration). Both of these procedures were successful on subsequent patients by selecting better trocar locations. Re-operations were required in 2 patients (4.4%). The only TEF patient re-fistulized and required a revision 2 weeks after repair. One fundoplication patient with a large congenital hiatal defect was re-explored robotically because the crural closure was too tight.

CONCLUSIONS: Robotic surgery is safe and effective for small children, infants, and neonates. A large variety of procedures can be accomplished. Careful planning of trocar locations is essential. Conversion rates to open are acceptable.

S053 SURGICAL PERFORMANCE WITH HEAD-MOUNTED DISPLAYS IN LAPAROSCOPIC SURGERY

Christopher J. Prendergast BS, Beth A. Ryder MD, Adam Aboodey MD, Gregory P. Crawford PhD, Francois I. Luks MD, Alpert Medical School of Brown University and Hasbro Children's Hospital

BACKGROUND: The difficulties of laparoscopic surgery include two-dimensional image projection and loss of alignment between the surgeon's hands and his visual field. Head-mounted displays (HMD) allow freedom from gazing at a stationary overhead monitor, thus improving ergonomics. Modern HMD offer greatly improved image quality and/or reduced bulk and weight. We compared two types of HMD with conventional overhead image display.

METHODS: Twelve pre-clinical medical students (laparoscopic novices) completed the standardized bead-passing task in a Fundamentals of Laparoscopic Surgery (FLS) box trainer using a wall-mounted monitor (WALL), a solid-state high resolution dual full-VGA HMD (HIGH HMD) or a lightweight commercial ¼ VGA HMD (LOW HMD). Participants performed each task using the three image displays. The order in which they performed each test was randomly assigned to minimize carry-over effect. Students were then asked to grade comfort and image quality on a scale from 1 (worst) to 5 (best). Statistical comparison was performed with analysis of variance (ANOVA).

RESULTS: Time per bead (total beads = 12/participant) was 14.2 ± 3.7 s for WALL, 12.5 ± 4.0 for HIGH HMD and 13.2 ± 5.2 s for LOW HMD ($p < 0.01$). Comfort rating was 3.67 ± 0.82 , 3.83 ± 0.75 and 3.50 ± 1.38 , respectively ($p = 0.7$) and image quality was rated as 3.00 ± 0.63 , 4.67 ± 0.52 and 2.83 ± 1.47 , respectively ($p < 0.001$).

DISCUSSION: High-resolution head-mounted displays offered a significantly better image quality and allowed faster task performance than a lower-resolution model of HMD, and both performed better than the overhead display. The high-resolution HMD was not significantly more comfortable than the low-resolution model, due to the added weight and bulk. Head-mounted displays alone may only be of incremental benefit in improving performance in laparoscopic surgery. However, their greatest promise is in combination with other advances in imaging and image manipulation technology, as they open the door to individualized image display.

S054 TELESIMULATION: AN INOVATION IN TEACHING LAPAROSCOPIC SKILLS IN AFRICA

Georges Azzie, Allan Okrainec, Hospital for Sick Children, Toronto, Canada

OBJECTIVE: Though telemedicine and simulation have existed as separate entities in surgical education, no one has combined these modalities

in the teaching and assessment of laparoscopic skills. "Telesimulation" is a novel concept based on internet linking of laparoscopic simulators. The feasibility of using telesimulation to teach and test the Fundamentals of Laparoscopic Surgery (FLS) course by surgeons in Canada to doctors in Botswana was assessed.

METHODS: Pre test FLS scores were obtained for each doctor during a minimally invasive surgery (MIS) workshop held in Botswana. A set-up for "telesimulation" was provided by using one FLS training box in Toronto, Canada and one in Gaborone, Botswana. At each site, the FLS camera was connected to a television using an S-video cable and to a laptop using a USB cable; the FLS camera thus functioned as a webcam. A second webcam was used to display the operator at the FLS training box. Skype software was used to establish a video connection between the FLS cameras and the external webcams. The instructor in Toronto and the trainee in Gaborone could see and speak to each other, as well as see inside each other's FLS training boxes. All this was in real time.

RESULTS: A total of 12 telesimulation sessions were held between 9 doctors in Gaborone and 2 instructors in Toronto. The instructors in Toronto were able to teach, demonstrate and provide feedback on all 5 FLS tasks performed by the doctors in Gaborone. Preliminary data suggest that all FLS tasks could be scored accurately from Canada and that trainees improved over the course of the study.

CONCLUSIONS: "Telesimulation" is not only a new concept, but a new word. It is a novel, practical and inexpensive method for teaching FLS in any country where the necessary internet access exists. Final data on post-test FLS scores is being analyzed and will determine the effectiveness of this novel teaching modality.

S055 ADVANCED CT AND XPERCT GUIDED MINIMALLY INVASIVE BONE INTERVENTIONAL PROCEDURES

Neil D. Johnson MD, John Racadio MD, Cincinnati Children's Hospital

PURPOSE: To report the use of CT and XperCT, Laser and 3 Dimensional guidance for advanced interventional radiology bone procedures.

METHODS/MATERIALS: Advanced Interventional Bone Procedures were defined as image guided procedures involving bone access greater than 8mm diameter, percutaneous bone substitute grafting, curettage, radiofrequency ablation, intraosseous pharmaceuticals or placement of metallic hardware. R.F. ablation of Osteoid Osteoma was excluded. Biopsies, aspirations and other simple or common procedures were excluded. A retrospective review was undertaken using the Radiology Information System, Hi-IQ and Radsearch wordsearch datasystems. All procedures were performed under general anesthesia using either Laser/CT guidance ($n = 52$) or XperCT ($n = 6$). Intraprocedural intravenous antibiotics were routinely administered. Standard procedure was to localize the lesion, place a guide pin under image and laser guidance, dilate the tract using custom designed serial metal dilators, and access the bone using the Corb (Zimmer medical) Trephine set. After access was obtained, procedures including curettage, bone substitute grafting (Pro-Osteon or Prodense bone substitute) or steroid administration were performed. Orthopedic screws were placed over guidepins and R.F. ablation was performed using Radionics equipment.

RESULTS: Over 7 years, a total of 58 procedures were performed on 43 patients (Age 2 - 20 years) Conditions Treated: Aneurysmal Bone Cyst (ABC): $n = 14$; Fracture / avulsion: $n = 6$; Infection: $n = 6$; Langerhans Cell Histiocytosis: $n = 4$; Enchondroma: $n = 2$; Physeal post traumatic growth arrest: $n = 1$; Other lesions: $n = 10$ There were no injuries to major vessels or nerves. One superficial wound infection was treated with oral antibiotics. One large pelvic ABC rapidly resorbed the bone graft material and required extensive surgical removal.

CONCLUSIONS: Advanced percutaneous CT and XperCT image guided interventional bone procedures can be safely and effectively performed by interventional radiologists in co-operation with Orthopedics and other specialties.



ORAL PRESENTATION ABSTRACTS

S056 THE IMPACT OF INTRAOPERATIVE HYPERCAPNEA OR HYPERCARBIA ON NEONATES UNDERGOING THORACOSCOPIC REPAIR OF DIAPHRAGMATIC HERNIA OF BOCHDALEK

David Bliss MD, Julie McKee RN, Sanjay Krishnaswami MD, Legacy Emanuel Children's Hospital

BACKGROUND: Better understanding of cardiopulmonary physiology in children with congenital diaphragmatic hernia of Bochdalek (CDH) has facilitated improved survival. It has also allowed surgeons to employ minimally invasive techniques to CDH repair under conditions that might result in hypercarbia and/or recurrent pulmonary hypertension.

MATERIALS/METHODS: Under institutional review board approval, the records of all neonates at a single institution who underwent thoracoscopic CDH repair (T-CDH) were reviewed with attention to the incidence of intraoperative hypercapnea (elevated end tidal CO₂) or hypercarbia (increased PCO₂ by blood gas measurement) and any associated complications.

RESULTS: From 2004 through 2007, 31 consecutive neonates, including those who had undergone ECMO, had T-CDH. CO₂ insufflation to 3 mm Hg was used until the viscera were reduced within the abdominal cavity. The remainder of the operative technique and outcomes are described elsewhere. Preoperative analyses revealed a mean arterial PCO₂ of 53 +/- 11 torr (range 29-83) and SaO₂ of 95 +/- 5% (range 80-100). The mean highest recorded intraoperative ET-CO₂ was 63 +/- 13 (range 29-88) and correlated poorly with the highest arterial PCO₂ (mean 86 +/- 33 torr, range 48-130). The mean lowest recorded intraoperative SaO₂ was 92 +/- 8% with all but one value above 88%. The average lowest intraoperative mean arterial blood pressure was 47 +/- 8 mm Hg (range 34-70 mm Hg). No neonate received vasoactive medications, inhaled nitric oxide, or intravenous buffer administration during the procedures nor did any experience recurrent pulmonary hypertension post-operatively.

SUMMARY: Hypercapnea and hypercarbia are common phenomena during T-CDH, but do not appear to result in clinically evident recurrent pulmonary hypertension, hypoxemia, hypotension, or the need for support with vasoactive medications, inhaled nitric oxide or buffering agents.

S057 THE INFLAMMATORY RESPONSE IS NO DIFFERENT IN CHILDREN RANDOMIZED TO LAPAROSCOPIC OR OPEN APPENDECTOMY - BUT LAPAROSCOPIC PATIENTS GO HOME EARLIER

Philipp Simon, Oliver J. Muensterer PhD, Ulrich Sack PhD, Ullrich Burkhardt PhD, Departments of Pediatric Surgery, Anesthesia, and Clinical Immunology, University of Leipzig

BACKGROUND: Previous nonrandomized studies suggest that the inflammatory response after laparoscopic appendectomy is less pronounced than after open surgery.

OBJECTIVE: To compare the clinical course and serum levels of a variety of inflammatory markers in children randomized to either laparoscopic or open appendectomy for nonperforated appendicitis.

MATERIALS/METHODS: Children with the diagnosis of appendicitis were randomized to either laparoscopic or open appendectomy after informed consent for participation in the study was obtained. Body temperature, leukocyte count, hematocrit, and blood levels of the inflammatory markers CRP, TNF-alpha, sTNF-R, IL-1Ra, sIL-2R, IL-6, and IL-8 were determined at 6 different times: Before anesthesia induction, at skin incision, after wound closure, as well as 12, 24 and 48 hours postoperatively. Length of stay was assessed as well. Parameters with normal distribution were compared by Student's t-test for independent samples, all others were compared by the Mann-Whitney U test. P < 0.05 was considered to be statistically significant.

RESULTS: A total of 47 patients with appendicitis were recruited and randomized. Retrospectively, 4 patients in the open group and 3 in the laparoscopic group were excluded from the analysis because perforated

appendicitis was described on their histopathologic report, leaving an equal number of patients in each study cohort (n=20 each). There was no significant difference in demographic variables including age, body weight, and duration of symptoms. There were also no significant differences in body temperature, hematocrit, leukocyte count or any of the inflammatory markers mentioned above at any time point. Average postoperative length of stay was 6.15 +/- 2.5 days in the open group and 4.3 +/- 1.1 days in the laparoscopic group (p < 0.01).

CONCLUSION: We found no differences in inflammatory parameters at any time point after open and laparoscopic appendectomy for nonperforated appendicitis. However, surgeons send their laparoscopically-operated patients home earlier.

S058 ANATOMICAL VARIATIONS OF MEDIAL UMBILICAL LIGAMENT: DOES IT HAVE ANY CLINICAL SIGNIFICANCE?

Baran Tokar MD, Ferruh Yucel MD, Eskisehir Osmangazi University, School of Medicine, Department of Pediatric Surgery and Anatomy, Eskisehir, Turkey

BACKGROUND: Obliterated umbilical arteries called as medial umbilical ligament (MUL) located in umbilicovesical fascia. As a cord of fibrous tissue, they reach to umbilicus while traversing between the median umbilical ligament (urachus) and lateral umbilical ligaments (inferior epigastric vessels). The pathologies of urachus are well known, but anatomy and clinical significance of MUL have not been documented well in literature. This prospective study combined with a retrospective video review and anatomy dissection on cadaver evaluated the anatomical variations of MUL and provided data for speculation on the clinical significance of this ligament.

METHODS: We had a patient with a tethered cord like MUL with a significant web. He had recurrent abdominal pains, retractile right testis and intraabdominal left testis. This case triggered the study, and the anatomy of MUL was investigated in total 62 patients including 41 retrospective cases. The patients having laparoscopic exploration were included into the study. The videos demonstrating both MUL and urachus with details were selected for retrospective evaluation. A dissection on cadaver was also performed to show the anatomic relation of MUL with the neighboring structures. A preliminary grading scale of anatomical appearance of MUL was obtained from the data.

RESULTS: In grade 0, patients had no visible ligament (n=10); in grade 1, MUL had a fibrous cord without a web (n= 28); in grade 2, MUL had a fibrous cord with a web (n=24). Seven patients in grade 0 had an urachus with a significant web. In our patient having tethered cord like MUL, the ligaments were excised, and left orchidopexy was performed. Pain relief was significant and he did well in the first year of follow up.

CONCLUSIONS: To know the anatomy and anatomical variations of anterior abdominal wall is highly important for surgeons performing laparoscopy. A MUL with a fibrous cord and significant web may cause technical difficulties in laparoscopic surgery. Anatomical variations may also affect the surgeon's preference on trocar locations. Although we have only one case with a significant tethering, it may also be speculated that a tethered cord like development of the ligament could be associated with abdominal pain and undescended testis.

S059 THORACOSCOPIC REPAIR OF LARGE DIAPHRAGMATIC HERNIAS: DIRECT CLOSURE VERSUS SURGISIS-PATCH INTERPOSITION - A PROSPECTIVE EXPERIMENTAL STUDY IN YOUNG PIGS

Klaus Schaarschmidt PhD, Andreas Kolberg-Schwerdt MD, Michael Lempe MD, Frank Schlesinger MD, Jan Patino-Mayer MD, Dennis Goldmann MD, Helios Center for Pediatric & Adolescent Surgery, Berlin-Buch, Germany

INTRODUCTION: Thoracoscopic repair of congenital diaphragmatic hernia is increasingly accepted, but repair of large defects, which are not

ORAL PRESENTATION ABSTRACTS



amenable to direct suture or diaphragmatic aplasia is still a challenge. Moreover right sided defects are so rare, that sufficient experience with different techniques is difficult to accumulate. Therefore this study aimed at establishing a reproducible training model for thoracoscopic repair of diaphragmatic hernia and to compare different techniques for right and left repairs.

METHODS/PROCEDURES: 16 young pigs of 15-20 kg were anaesthetized and intubated by endoscopic intubation. Venous access via an ear vein was established and continuous monitoring by ECG and pulse oximetry was established. From four accesses 50 % of the right and left diaphragm was excised using a template and alternately closed by direct suture or interposition of a Surgisis-patch. CO₂ insufflation of the thorax maintained a pressure of 2-4 mm of Mercury to minimize cardiovascular side effects. Operative details, operation times and blood loss were recorded prospectively, position of the accesses documented by digital photography. The animals were sacrificed at the end of the operation and the quality of the repair evaluated and documented from a posterolateral thoracotomy.

RESULTS: In one right hemithorax sufficient vision could not be gained due to massive previous purulent pleuritis and excessive adhesions. Thus 16 direct closures (8 right and 8 left) and 15 patch closures (8 right and 7 left) could be finished by thoracoscopy uneventfully. Operation times were not significantly different with 61.4 ± 37.3 minutes (range 32-141) for direct closure and 77.9 ± 16.8 minutes (range 56-131) for patch closure and comparing right and left repair. However the lower standard deviation for patch repair is striking.

CONCLUSIONS: The young pig model yields excellent experience and standardization for comparing different techniques of diaphragmatic hernia closure and for right sided defects. It is remarkable that after a certain learning curve patch repair is better reproducible and has a lower standard deviation than direct closure of large defects. Therefore, in difficult settings patch repair might be applied more readily than recorded in the literature.

S060 LOCKING SLIDING KNOTS FOR NEONATAL MINIMALLY INVASIVE SURGERY: EXPERIMENTAL STUDIES

B. Banieghbal MD, Department of Pediatric Surgery, Johannesburg General Hospital, Johannesburg, South Africa

INTRODUCTION: There is an increasing acceptance of minimal invasive surgery in neonatal conditions such as esophageal atresia (EA) repair. One of the biggest hurdles is the intra-corporeal suturing in the confined space of right hemi-thorax. Arthroscopic orthopedic surgeons for precisely the same issues use locking sliding knots. A series of tests are performed and presented utilizing locking sliding knots in an experimental model of EA.

MATERIAL/METHOD: 4 locking sliding knots were compared to standard square (tumble) knot in a thoracoscopic training module of EA. 5-0 suture material was used in all cases. The knots were performed by the author and timed with a digital timer. A total of 10 sutures were tied in each EA model. Overall tensile strength of 5 EA repaired models were tested with each type of knot. Tensile strength of the knots (in Newton) were measured by a motorized digital tension meter and plotted against time with a synchronised integrated computer software. Statistical analysis was performed using Anova or Student t-test by a commercial statistical software.

Type of Knot	Unraveling Rate	Tensile Strength	Time to Knot
Square	0/50	13.1 N	63.3 sec
Weston	8/50	8.0 N	42.9 sec
SMC	3/50	7.97 N	54.6 sec
Giant	1/50	12.9 N	37.7 sec
Field	0/50	13.6 N	57.9 sec

CONCLUSION: These experiments strongly suggest an important role for locking sliding knots, but only Giant knot and Field knot tensile strength compare favorably with standard intra-corporeal knot. Furthermore; Field knot's complexity renders it impractical. We conclude that Giant knot may have an important role in minimally invasive surgery in confined spaces, such as thoracoscopic EA repair.

S061 THE EFFECTS OF CO₂ PNEUMOPERITONEUM ON LIVERS WITH BILIARY ATRESIA IN AN ANIMAL MODEL

Pablo Laje MD, Fred H. Clark PhD, Joshua R. Friedman MD, Alan W. Flake MD, The Children's Hospital of Philadelphia

HYPOTHESIS: The CO₂ pneumoperitoneum (Pp) routinely used in laparoscopy produces changes in the blood flow of the portal vein and hepatic artery that alter the hepatic microenvironment, resulting in different degrees of cell damage and liver dysfunction. We hypothesized that livers with biliary atresia (BA) are more susceptible to the harmful effects of CO₂ Pp than healthy livers.

METHODS: Newborn Balb/c mice were inoculated intraperitoneally with wild-type rotavirus at 24 hours of life. Animals were divided in five groups: 1) Control mice, no rotavirus, not exposed to CO₂, 2) Control mice, no rotavirus, exposed to CO₂, 3) Control BA mice, 4) BA sham mice (anesthesia + catheter, no CO₂), and 5) BA mice exposed to CO₂. On day of life 16 to 18, mice in groups 2, 4 and 5 underwent general inhalatory anesthesia, and in those in groups 2 and 5, an 8mmHg CO₂ Pp was established for a total of 60 minutes through a percutaneous 16 gauge angiocath. CO₂ pressure and flow (2.5 L/min) were controlled by an electronic insufflator. Mice were euthanized 18 to 24 hours after the procedure, and liver samples collected for flow cytometry, enzymatic assays and histology. Markers of apoptosis (apoptotic bodies, active caspase-3, and Annexin V) were investigated.

RESULTS: We observed a higher rate of cell apoptosis in livers with BA that were exposed to a prolonged CO₂ Pp (group 5) compared to livers in all control groups. Histology: Livers in group 5 had a higher number of apoptotic bodies and piknotic nuclei in the periportal areas than groups 1, 2, 3 or 4. Samples were counterstained with Active Caspase 3-horseradish peroxidase / hematoxylin, and the presence of Active Caspase 3-positive cells was remarkably higher in group 5 than in groups 1, 2, 3 or 4. Flow cytometry: samples were stained with Annexin V, 7-AAD (dead cells), and anti-albumin antibodies. Group 5 had a significantly higher rate of Annexin V-positive 7AAD-negative cells than all control groups, and the difference was even higher within the albumin-positive population. Colorimetric assay: fresh cellular lysates from livers in group 5 showed a considerably higher activity rate of the active caspase-3 enzyme than lysates from groups 1, 2, 3 or 4.

CONCLUSION: The negative effects of a prolonged CO₂ Pp have been known for many years, but usually they have minimal clinical impact in patients with normal liver function. In the setting of BA, though, it has been noticed, in some surgical centers, that patients who had a laparoscopic portoenterostomy had a poorer outcome than those who had an open procedure. In this animal model we proved that livers with BA suffer the detrimental effects of prolonged CO₂ exposure more than healthy livers, evidenced by a significant raise in the rate of cell apoptosis. This event could trigger a more permanent increase in the cell death rate, hastening the progression to complete fibrosis and liver failure. This hypothesis remains to be addressed.

S062 THE USE OF LIGESURE ON BILE DUCT IN RATS. EXPERIMENTAL STUDY

Antonio Marte MD, Maria Domenica Sabatino MD, Micaela Borrelli MD, Biagio Del Balzo MD, Fabiano Nino MD, Maurizio Prezioso MD, Pio Parmeggiani PhD, Paediatric Surgery of Second University of Naples

AIM: The closure of the cystic duct during cholecistectomy using radiofrequency is still controversial. We report our preliminary experimental results on the use of LigeSure on common bile duct in rats.



ORAL PRESENTATION ABSTRACTS

MATERIALS/METHODS: Thirty Wistar rats weighing 70 to 120 gr were employed for this study. All rats were anaesthetized with intraperitoneal Ketamine. The rats were then divided into three groups. The first group (10 rats, Group C) underwent only laparotomy and isolation of the common bile duct. The second (10 rats, Group M) underwent laparotomy and closure of the common bile duct (CBD) with monopolar coagulation. The third group (10 rats, Group L) underwent laparotomy and sealing of the common bile duct with two application of LigaSure. Thereafter, all rats were kept in comfortable cages and were administered dibenzamine for five days. They were all sacrificed on day 20. Through a laparotomy, the liver and bile duct were removed for histological examination. Blood samples were obtained to dose bilirubin, amylase and transaminase.

RESULTS: Mortality rate was 0 in the control group (C), 3/10 rats in group M and 0 in group L. In group L, the macroscopic examination showed a large choledochocoele (3 - 3.5 cm x 1.5 cm) with few adhesions. Histology showed a good sealing of the common bile duct in 9/10 rats, without tissue necrosis. In group M, 2/10 rats had liver abscess, 3/10 rats had choledochocoele and 5/10 rats biliary peritonitis. There was intense tissue inflammation with partial necrosis of the bile duct and the dissection resulted difficult. Analyses of blood samples showed an increase in direct bilirubin and transaminase in groups M and L.

CONCLUSIONS: The preliminary results of our study confirm that radiofrequency can be safely used for the closure of the common bile duct. The choledochocoele obtained with this technique could represent a good experimental model.

S063 FETOSCOPIC SURGERY OF EXTREMITY AMNIOTIC BANDS: LIMB SALVAGE BY INTRAUTERINE BAND RELEASE IN FETAL LAMB

Carlos Giné MD, José Luis Peiró MD, Francisco Soldado MD, Mario Aguirre MD, César G García Fontecha MD, Marieli Esteves PhD, Vicente Martínez Ibáñez MD, Fetal surgery Research Group, Vall d'Hebron Hospital, Barcelona, Spain

INTRODUCTION: With the use of fetoscopy for minimally invasive surgery, the indications of fetal surgery have been expanded. Fetal limbs at risk of amputation by an extremity amniotic band (EAB) are amenable to fetal surgery. A previous model of in-utero repair of moderate EAB has been reported in the fetal lamb. The purpose of this study is to evaluate the feasibility of intrauterine fetal release of amputating EAB by fetoscopic means using a severe EAB lamb model.

MATERIAL/METHODS: Right limbs of fifteen 60-days gestational age pregnant sheep were tied with silk suture at the infracondylar level. Left limbs were used as normal controls for paired comparison. Fetuses were randomized in three groups: early repair group (n=5), late repair group (n=5) and no-repair group (n=5). The limbs of repaired groups underwent fetoscopic release of the constriction band. Fetoscopic repair was performed after intrauterine CO₂ insufflation by perpendicular section of the constrictive ring by means monopolar electrocoagulation. The limbs obtained from at-term fetuses were analyzed at morphological, functional, radiological, and histological level. Statistical analysis with paired test was used to compare data.

RESULTS: Constriction band release was attainable by fetoscopic access in all cases. Late repair group offered more difficulties at surgery due to greater distal oedema. Non-repaired limbs showed amputation or quasi-amputation. Repaired limbs did not show amputation. However, those late repaired had significantly reduced passive ankle range of motion, shorter limb length, and mild residual changes. Better results were obtained in early reparation group.


CONCLUSIONS: In-utero release of potentially severe EAB avoids limb amputation and permits its morpho-functional recovery. Early release shows better results. We consider this fetal surgery treatment useful for limb rescue in severe EAB using a fetoscopic approach.

S064 CARDIA YIELD PRESSURE BEFORE AND AFTER LAPAROSCOPIC FUNDOPLICATION IN AN INFANT PIG MODEL

Robin Wachowiak MD, Alexandra Krauss, Bernd Donaubauer MD, Oliver J. Muensterer PhD, Departments of Pediatric Surgery and Anesthesia, University of Leipzig

BACKGROUND: Cardia yield pressure (CYP) has been described as a measure of the combined effect of all antireflux mechanisms. We present a novel technique for measurement of the yield pressure before and after laparoscopic Nissen fundoplication (NF) in an experimental infant pig model.

MATERIALS/METHODS: Twelve 8-week-old female pigs with a mean weight of 8.7 +/- 0.7 kg underwent laparoscopic gastrostomy placement and NF. CYP was determined before and after NF by filling the stomach with water until reaching the pressure at which the cardia opened and became incompetent. Pre- and postoperative CYP was compared using the paired t-test.



RESULTS: Laparoscopic NF and gastrostomy was completed in all pigs. CYP increased in all subjects after fundoplication, from a mean of 20 +/- 8 to 63 +/- 13 cm H₂O (*p<0.001).

CONCLUSION: CYP increases consistently after laparoscopic NF in young pigs. This technique is a simple, reliable tool to determine antireflux efficacy and functional quality of laparoscopic NF.

S065 RESECTION OF NEUROGENIC TUMORS IN CHILDREN USING THORACOSCOPIC APPROACH

Ramanath N. Haricharan MD, Jacqueline M. Saito MD, Douglas C. Barnhart MD, University of Alabama at Birmingham

PURPOSE: Thoracoscopic resection of neurogenic tumors has been controversial, especially due to concerns of inadequate resection. The purpose of this study was to evaluate the feasibility, safety and determine the outcomes after thoracoscopic resection of neurogenic tumors in children.

METHODS: After IRB approval, all children with neurogenic tumors who underwent a thoracoscopic resection between September 2001 and August 2007 in a tertiary care children's hospital were reviewed. Demographic, clinical, operative, histopathological, and hospitalization data were collected.

RESULTS: Thoracoscopic resection was performed in nine children with a total of 10 neurogenic tumors during the study period. Seven children were boys and the overall median age at operation was 7.5 years (0.1-15) years. All procedures were completed thoracoscopically and thoracotomy was not required in any of these children. Typically, three ports were used for the procedure, which afforded excellent visualization of the tumor and possible lymph node involvement. Gross total tumor resection was possible in all children without any intraoperative complications or perioperative transfusion requirement. Histopathologically, there were 2 neuroblastomas, 2 ganglioneuroblastomas and 6 ganglioneuromas. All children had favorable histology except 1 child with ganglioneuroblastoma. None of the children had N-MYC amplification and none required postoperative chemotherapy. The median length of stay after thoracoscopic resection was 2 (range 1- 8) days. No recurrences were identified after a median follow up of 8 months (range 1 - 72 months). Three children had complications (1-mild ptosis and 2-chylothorax) in the follow-up period, however all complications resolved with conservative treatment. The child with ptosis had 2 tumors; apical tumor juxtaposed to the stellate ganglion and a mid-thoracic paraspinal tumor. Given the proximity of the apical tumor to the stellate ganglion, it is unlikely that an open resection would have prevented the ptosis. Chylothoraces resolved completely with in-hospital parenteral nutrition and drainage only. There was no mortality in the study group.

ORAL PRESENTATION ABSTRACTS



CONCLUSION: Thoracoscopic approach for neurogenic tumor allows for adequate gross total resection with excellent visualization of tumor and associated lymph nodes, and is feasible without significant additional morbidity.

S066 THORACOSCOPIC RESECTION OF A PULMONARY METASTASIS LESS THAN 1 CM IN SIZE UTILIZING PREOPERATIVE CT-GUIDED WIRE LOCALIZATION: A CASE REPORT

Silvana Federici MD, Alberto Ratta MD, Lorenzo De Biagi MD, Maurizio Mordenti MD, Vincenzo Domenichelli MD, Gabriella Pelusi MD, Francesco Italiano MD, Pediatric Surgery Unit- Infermi Hospital- Rimini-Italy

INTRODUCTION: Although thoracoscopic wedge resection for pulmonary metastasis in children is a well-established technique, there are some limitations to this approach. Lung nodules less than 1 cm in size or those not located on the pleural surface frequently require an open thoracotomy. To obviate the need of more invasive surgical procedure to obtain tissue diagnosis and resect these nodules, surgeon and radiologist developed preoperative needle localization techniques using CT guidance. Actually these procedures are effective and safe also in pediatric age and permit to complete thoracoscopic pulmonary biopsy and resection of small lesions.

PATIENT/RESULTS: A 5 years girl, submitted to a right nephrectomy for a Wilm's tumor, presented with a little subpleural pulmonary nodule (<1cm) located in the inferior left lobe. Patient underwent to localization of the metastasis under CT guidance by percutaneous positioning of a guide-wire. After transferring of the children in the OR a single lung ventilation was obtained using a bronchial blocker and the thoracoscopic procedure was performed with the use of two 10 mm and 12 mm ports positioned in the anterior and midaxillary line between the 6th and 8th intercostal space. The nodule was easily localized and the wedge resection made by the use of an operative optic and a 12 mm endo-GIA linear stapling device. A chest tube was positioned utilizing one of the port and left in place. The operating time was 45 minutes and the chest tube removed after 48 hours. The postoperative course was uneventful and the children was discharged in the 5th P.O. day. Pathologic evaluation confirmed that the lesion was completely removed.

CONCLUSION: Preoperative CT guidance localization utilizing a percutaneous guide wire is safe and beneficial in children with pulmonary nodules less than 1 cm in size or located deep to the pleural surface. This technique allows the surgeon to perform thoracoscopic resection of these lesions without submitting the patients to a conventional thoracotomy.

S067 Abstract Withdrawn

S068 CT GUIDED NEEDLE-WIRE LOCALIZATION FOR THORACOSCOPIC RESECTION OF SMALL PULMONARY NODULES

John M. Racadio MD, Kamlesh U. Kukreja MD, Shane J. McGonegle MD, Manish N. Patel DO, Neil D. Johnson MD, Cincinnati Children's Hospital Medical Center, Cincinnati Ohio, USA

PURPOSE: Children with malignancy and pulmonary nodules often need biopsies to guide therapy. Small lung nodules or those deep to the pleural surface usually require open thoracotomy. We describe a technique using preoperative CT guided needle localization, which allows for successful thoracoscopic resection, avoiding the morbidity of open thoracotomy.

MATERIALS/METHODS: From 1995 to 2007, 20 children (mean age 12 years; 8 mos-21 years) with malignancy underwent CT guided needle localization of pulmonary nodules with a standard breast biopsy needle and localization wire. All nodules were deemed by the surgeon too small or distant from the pleura to be directly visualized under thoracoscopy. Immediately following localization all patients underwent thoracoscopic

resection. In 11 cases a small amount of methylene blue dye combined with blood patch was also injected adjacent to the nodule and just beneath the visceral pleural surface.

RESULTS: Needle localization and thoracoscopic resection of pulmonary nodules was successful in all cases. Mean nodule size was 4mm. Five nodules were metastatic, 14 inflammatory/atelectasis, an one intraparenchymal lymph node. There were no complications.

CONCLUSIONS: CT guided needle localization of small pulmonary nodules allows for safe and successful thoracoscopic resection in children, who would otherwise need open thoracotomy.

S069 PRIOR THORACIC SURGERY HAS A LIMITED IMPACT ON THE FEASIBILITY OF CONSECUTIVE THORACOSCOPY IN CHILDREN: A PROSPECTIVE STUDY

Martin L. Metzelder MD, Joachim F. Kuebler MD, Marc Reismann MD, Taiwo A. Lawal MD, Sylvia Glueer PhD, Benno M. Ure PhD, Department of Pediatric Surgery, Hannover Medical School, Hannover, Germany

BACKGROUND: This study aimed to determine the impact of prior thoracic surgery on consecutive ipsilateral thoracoscopic surgery in children.

METHODS: We analyzed prospectively 228 thoracic procedures, which were performed in 190 children (99 male, 91 female, mean age 5.1 years; range: 1 day to 18 years) over a 7 year period (January, 2000, to August, 2007). Out of these, 133 were thorascopies and 95 conventional operations. The endpoints were conversion rate, intraoperative events and complications in subsequent thorascopies with regard to the type of prior thoracic surgery. In addition, the reasons for exclusion of those patients, who had previous thoracic operation from thoracoscopy should be identified.

RESULTS: Thirty-two patients (14%) had prior thoracic surgery, 20 of these underwent thoracoscopy, 12 after prior thoracotomy and 8 after prior thoracoscopy. The type of initial approach had no significant impact on the conversion rate of subsequent thoracoscopy (1/12 after thoracotomy versus 0/8 after thoracoscopy, n.s.). The conversion rate was not significantly different in patients with or without prior surgery (1/20 versus 19/101; n.s.). However, there was a higher number of reconstructive procedures in patients without prior surgery, which was reflected in conversions due to lack of overview (n=12), bleeding (n=3), tension during reconstruction of a diaphragmatic defect (n=2) and esophageal atresia (n=2), and intraoperative respiratory problems (n=1). Twelve patients with prior operation underwent thoracotomy due to limited respiratory capacity (n=5), advanced tumor stage, prior sternotomy (n=6), and limited visibility leading to conversion during initial thoracoscopy (n=1).

CONCLUSIONS: Prior thoracic operation has, independent of the initial approach, a limited impact on the feasibility of ipsilateral consecutive thoracoscopic surgery in children. The feasibility of thoracoscopy after prior operation is excellent.

S070 EARLY THORACOSCOPIC SURGERY FOR SEQUESTRATION ASSOCIATED WITH CYSTIC ADENOMATOID MALFORMATION

Smart Zeidan MD, Geraldine Hery MD, Frederic Lacroix F MD, Alain Potier MD, Guillaume Gorincourt MD, Jean Christophe Dubus PhD, Jean Michel Guys PhD, Pascal de Lagausie PhD, Hôpital la Timone, Marseille, France

OBJECTIVE: To establish the natural history of bronchopulmonary sequestration associated with congenital cystic adenomatoid malformation (CCAM) and to evaluate the management of these lesions, and to determine their outcome.

PATIENTS/METHODS: Over 23 fetal lung lesions diagnosed prenatally and managed in our institution, between May 2004 and September 2007, 7 patients present this hybrid form. We reviewed retrospectively their records, prenatal and postnatal radiological exploration, prenatal and



ORAL PRESENTATION ABSTRACTS

postnatal course, operative findings, and histopathology of these lesions.

RESULTS: In all seven fetus prenatal ultrasound diagnosed congenital lung abnormalities. Fetal MRI demonstrated the association of macrocystic lesion with aberrant vessel in three cases. The intrauterine evolution of the cysts remained uncomplicated. All patients were asymptomatic after birth. Chest CT performed in these patients during the first month of life showed the systemic aberrant vessel in five cases. A regression of the lesion in one and of the aberrant vessel in another patient were noted.

Elective lobectomy by thoracoscopy of the affected lobe based on the CT was performed in six cases at an average age of 5 months. One patient was under observation because of spontaneous resolution of the lesion. Operating time ranged from 80 to 160 min. Chest tubes were removed at day 3 after surgery. The average hospital stay was 4,5 days. One conversion to thoracotomy was required. All operated patients had an uneventful hospital course. Histopathological examination confirmed intra-lobe sequestration with associated Stocker type II CCAM in 5 cases, and CCAM type I in one case.

CONCLUSIONS: The incidence of the intralobar sequestration-CCAM association appears to be more common than reported in literature. It could be diagnosed prenatally. Outcome is usually excellent. The resolution of one or both component of this lesion is possible. Preoperative identification of the aberrant vessel should be done to prevent operative morbidity. An appropriate management allows early resection of these lesions, often by thoracoscopy, to promote lung growth.

S071 LAPAROSCOPIC ESOPHAGECTOMY IN ESOPHAGEAL REPLACEMENT SURGERY

Olivier Reinberg MD, Department of Pediatric Surgery, University Hospital Center and University of Lausanne, Switzerland

Before 1989 retrosternal transplants were used for esophageal replacements in children. We thereafter introduced the the one stage orthotopic transplant procedure following blind esophagectomy through a cervico-abdominal approach. Even after large experience in more than 200 cases, we still consider this step as the most dangerous part of the procedure, showing 20% of various complications. For this reason we have tried to achieve esophagectomy under visual control without opening the thorax for several years. Since 2006, we have used a standardized procedure through a laparoscopic approach.

We report our preliminary experience in 10 consecutive patients with caustic stenosis of the esophagus being replaced either by colonic transplants or gastric tubes. Through a laparoscopic approach, we dissected the esophagus in close contact with the latter under direct visual control. We were able to free the esophagus from the hiatus to far above the left bronchus, up to the subclavian artery, thus allowing its removal.

This technique reduces the hazards related to the blind esophagectomy in such procedures.

S072 MINIMAL INVASIVE MANAGEMENT OF CHILDREN WITH CAUSTIC INGESTION: LESS PAIN FOR PATIENTS

Burak Tander MD, Unal Bicakci MD, Ender Ariturk MD, Riza Rizalar MD, Suat H. Ayyildiz MD, Ferit Bernay MD, Ondokuz Mayıs University, Department of Pediatric Surgery

AIM: Management of caustic ingestion in children is still controversial. In this study, we present a minimal invasive management (flexible endoscopy, balloon dilatation, intralesional steroid injection) for those patients.

PATIENTS/METHODS: Between April 2002 and November 2007, 339 children with a history of caustic ingestion were admitted. Enteral feeding was discontinued for 24 hours and afterwards parenteral feeding was initiated when necessary. No patient underwent an early esophagoscopy or gastrostomy. A contrast study of upper gastrointestinal tract was performed in all patients with persistent dysphagia within 3 weeks after injury. Dilatation program of esophageal stricture was initiated in case of detection of esophageal stricture. Flexible esophagoscopy was performed

for dilatation. A guidewire was placed through the narrowed segment into the stomach and a balloon dilatator was inserted with assistance of the guidewire. Balloon dilatations were performed every 3 weeks. In intractable strictures, triamcinolone was injected into the stricture under guidance of flexible endoscopy.

RESULTS: Nineteen patients (10 male, 9 female, median 3 years old) required esophageal dilatation. 18 patients completed dilatation program with complete healing. One patient is still in dilatation program. None of the patients required stent application, esophageal replacement or gastrostomy. Seven patients underwent intralesional triamcinolone injection. No patient had esophageal perforation or any other complications. In 18 patients, the symptoms have been completely relieved and no further dilatation was necessary after a median of six dilatation sessions.

CONCLUSION: Minimal invasive management of caustic ingestion consisting of flexible endoscopy and guidewire assisted esophageal balloon dilatation, intralesional steroid injection is very effective and leads to a complete relief of dysphagia in almost all patients. We believe, in almost all patients, no gastrostomy or esophageal stent/ replacement are necessary. This method of dilatation is also safe and does not cause iatrogenic esophageal perforation.

S073 THORACOSCOPIC FOKER TECHNIQUE FOR LONG GAP ESOPHAGEAL ATRESIA

Edward Esteves MD, Denny C. Lima MD, Bernardina B. Carvalho MD, Pediatric Surgery Division, University of Goias, Brazil

Long gap esophageal atresia (LGEA) can be managed by many ways to provide elongation of the esophageal segments, specially the proximal esophagus, to allow a good non-tension anastomosis. Since the description of the elongation technique with transparietal stitches by Foker, using a 2-step thoracotomy, we have been using this technique thoracoscopically with good results, so the authors present the technical details and outcomes after these procedures.

METHODS: In the period January/2005 to January/2007, Six children presenting LGEA needed elongation in the neonatal period for type 1 (n=2, without fistula), type 4 (n=1 proximal fistula), type 3 (n=3, distal fistula). Another one was submitted for elongation after a failed Kimura elongation technique. Via a 3-port thoracoscopy at the posterior right hemithorax, both esophageal segments were dissected. 4 or 5 transparietal prolene 4-0 stitches are applied at each end, clipped with a metallic marker and fixed outside. The stitches are pulled about 2-3 mm a day until radiological confirmation of the "kissing clips" sign. In one case the proximal end ruptured, requiring anticipation of the second step, and the anastomosis was possible, helped by wide distal dissection of both esophageal ends. In all other cases, a second thoracoscopy with 6 to 8 5-0 PDS or prolene stitches allowed anastomosis after a "pulling time" of 21-40 days.

RESULTS: All anastomosis were accomplished in 60-130 minutes (mean 85 min). no deaths or conversions. Complications were :Fistula in case 3, resolved spontaneously after one week; pleural empyema (1), keloids (1).

CONCLUSIONS: the Foker technique allows anastomosis in most LGEA and can be achieved thoracoscopically, avoiding esophageal replacement and esophagostomy in most of these unfortunate children.

S074 THORACOSCOPIC REPAIR OF TRACHEOESOPHAGEAL FISTULA AND ESOPHAGEAL ATRESIA

Dariusz Patkowski PhD, Konrad Rysiakiewicz MD, Wojciech Jaworski PhD, Marzena Zielinska PhD, Grazyna Siejka MD, Jerzy Czernik PhD, Department of Paediatric Surgery and Urology, Medical University of Wrocław

PURPOSE: To evaluate the safety and efficacy of the thoracoscopic repair of esophageal atresia and tracheoesophageal fistula (EA/TEF).

METHODS: From August 2005 to December 2007 nineteen consecutive cases (14 male, 5 female) wt. 1,1 to 3,39 Kg underwent thoracoscopic

ORAL PRESENTATION ABSTRACTS



EA/TEF repair. 6 cases had additional severe malformations. Two 5mm and one 2,5mm trocars were placed. The 5mm 250 telescope was used. A pneumothorax was maintained with 5-6mmHg. The azygos vein was not divided in order to prevent recurrent fistula formation. The TEF was closed with 5mm titanic clips. The esophageal anastomosis was made over 6F nasogastric tube by 4-6 simple stitches of 5-0 Vicryl. The 8F chest tube was left without suction. The enteral feeding was usually started on 3-4th postoperative day. Barium swallow was performed on 5-6th postoperative day, then the chest tube was removed.

RESULTS: All procedures were successfully completed without conversion. The average operative time was 139min (range 55-245min) with significant improvement after gaining experience (mean 171min for first 10 cases and 104min for last 9 cases). There were 2 cases of accidental tracheal opening, one was closed intraoperative, one required cuff intubation tube placement. The anastomotic leak rate was 10,5% (2 cases) and all were healed on conservative treatment. 3 cases required 1-3 courses of anastomotic stricture dilatations. There were 3 deaths (15,8%) of causes not related with performed operation.

CONCLUSIONS: The thoracoscopic repair of EA/TEF is effective method and based on our experience it is the procedure of choice if performed by experienced endoscopic pediatric surgeon.

S075 THORACOSCOPY IN CHILDREN: IS A CHEST TUBE NECESSARY?

Todd A Ponsky MD, Shawn St. Peter MD, Daniel Ostlie MD, KuoJen Tsao MD, George W Holcomb, III MD, Steven S Rothenberg MD, Rocky Mountain Hospital for Children, Denver, CO, USA, Children's Mercy Hospital, Kansas City, MO, USA

PURPOSE: Historically, a chest tube or drain has been left following a thoracic operation to allow drainage of air or fluid in the postoperative period. However, in patients undergoing thoracoscopy, the tube is often the greatest source of postoperative pain. We began excluding chest tubes several years ago and therefore are reviewing our experience to evaluate the safety and efficacy of this approach.

METHODS: A retrospective review of the medical record was performed on patients undergoing thoracoscopy at two centers from 1993 to 2007. Patients who left the operating room without a chest tube (CT) were included in this series. Patient demographics, type of operation and outcome were recorded.

RESULTS: A total of 319 thoracoscopic procedures were performed at the two institutions without the use of a CT. Ages ranged from 1 week to 39 years. Weight ranged from 1.3 kg to 117 kg. The cases performed included aortopexy, congenital diaphragmatic repair, excision of a bronchogenic cyst, exploratory thoracoscopy, lung biopsy, resection extra-lobar sequestration, Nuss procedure, patent ductus arteriosus ligation, resection/biopsy of mediastinal lesions, resection of esophageal duplication, excision of parathyroid adenoma, hiatal hernia repair, esophagomyotomy, and thymectomy. Within this group of thoracic operations, 182 patients underwent either lung biopsy or resection of an extralobar sequestration. Pulmonary lobectomy or segmentectomy patients were excluded. All patients had a chest radiograph in the recovery room. Only one developed a postoperative pneumothorax which occurred on postoperative day 2 following reintubation for respiratory failure. A chest tube was then inserted.

CONCLUSIONS: The use of routine CTs following thoracoscopy in children appears to be unnecessary as the absence of a chest tube in our series resulted in an intervention in 1 patient (0.3%). Elimination of the CT will allow for a much more tolerable post-operative course in most children.

S076 EXTRA-PLEURA NUSS PROCEDURE FOR THE CORRECTION OF PECTUS EXCAVATUM IN CHILDREN

Shu-li Liu PhD, Long Li MD, Wen-Ying Hou MD, Department of Pediatric Surgery, Peking University First Hospital

INTRODUCTION: Nuss procedure has become a standard procedure for pectus excavatum in many institutions worldwide. But classical Nuss procedure has some drawbacks. Authors developed a new procedure which a bar was introduced through an extra-pleura tunnel between parietal pleura and bony thorax.

METHODS: sixteen cases underwent this operation. Under the assistance of thoracoscope, a extra-pleura tunnel was created using a blunt dissector via a right thoracic incision. Then a steel bar was inserted in the extra-pleura tunnel. After the bar was placed in position, it was turned over to elevate the deformed sternum and the anterior chestwall.

RESULTS: The operation was completed successfully in all the 16 cases. The operating time ranged 35-50 min (mean, 40 min). The intraoperative blood loss ranged 2-3 ml. The surgical outcomes were excellent in all 16 cases. No pneumothorax/hydrothorax and other complications occurred in our series. All patients were followed 2-6 months. No complications such as bar displacement, infection of pleural cavity, etc. occurred.

CONCLUSIONS: Extra-pleura Nuss procedure for pectus excavatum in children is a safe/reliable and minimally invasive technique.

S077 LONG TERM OUTCOME OF FOWLER-STEPHENS ORCHIOPEXY IN BOYS WITH INTRA-ABDOMINAL TESTES

Ciro Esposito MD, Maria Rosaria Nuges MD, Francesca Alicchio MD, Flavio Perricone MD, Antonio Savanelli MD, Gianfranco Vallone MD, Alessandro Settini, Department of Pediatrics, Federico II University, Naples, Italy

PURPOSE: We reviewed a series of pediatric patients operated between 1990 and 1997 for high intraabdominal testes (IAT) using 2 steps Fowler Stephens (FS) procedure via laparoscopy.

MATERIAL AND METHODS: A total of 36 patients were reviewed with a follow-up ranging between 10 and 17 years. Three patients were excluded from the study because they were operated in open surgery. Of the remaining 33 patients 18 have a right IAT and 15 a left IAT. All the patients received a telephonic interview and in the available patients a clinical control and a colour Doppler study of the testis was performed.

RESULTS: 8 of the 33 patients, were couldn't be contacted because they had changed their telephone numbers. Of the remaining 25, 13 didn't accept to be controlled because they had changed city (5/13) or because they were working or attending High School, however 12/13 patients confirmed that they had a viable testis in the scrotum. Twelve patients accepted to be controlled and our study will be focused on them. These 12 patients (7 right IAT; 5 left IAT) have a range of age varying between 13 and 16 years (14.7 years old on an average). Two of the 12 patients have an atrophic testis in the scrotum, while 10/12 patients (83.3%) have a viable testis in the scrotum. FS testis was always smaller than the normal one even if it had a good vascularisation at echo-colour Doppler. One patient presented at ultrasonography a bilateral micro-calcifications of both testes with a normal vascularisation. We have compared the results of volumetric difference between the FS and the normal testis using Manney Whithney tests and the results are statistically significant ($p > 0.001$).

CONCLUSIONS: It's extremely difficult to perform studies on long term outcome after surgical procedures because more than 50% of patients were not found or refused to be controlled. Our study shows that with an outcome of more than 10 yrs, patients operated using 2 step FS procedure have satisfactory results in over 80 % of cases. The FS testis is always significantly smaller compared to normal testis but it is always well vascularised. In this kind of patients it is important to perform also an ultrasonographic control because we can check the structure of the testis and discover other anomalies as in one case in our series that presented a microcalcification of the testes.



ORAL PRESENTATION ABSTRACTS

S078 LONG TERM OUTCOME OF ENDOSCOPIC APPROACH OF URETEROCELE IN CHILDREN

Antonio Savanelli MD, Francesca Alicchio MD, Ciro Esposito MD, Flavio Perricone MD, Alessandra Farina MD, Alessandro Settimi MD, Dept of Pediatrics, Federico II University of Naples, Italy

The treatment of ectopic ureteroceles remains a subject of discussion. We reviewed our experience to evaluate the long-term effectiveness of primary endoscopic-puncture of ureterocele to decrease the need for open surgical procedure.

We reviewed the medical records of 24 new patients of last 9 years (from 1998 to 2007) with diagnosis of ureterocele. Out of 24 we considered only 15 patients, with a median age of 3 months, underwent at endoscopic ureterocele puncture. Ureterocele presented as a part of a duplex system in 11 of patients (73,3%) and as part of a single system in 4 (26,6%). The follow-up ranged from 9 years to 6 months. 7 (46,5%) patients were cured by only one endoscopic puncture and 1 (6,6%) needed of a second look. In 8 patients we performed after endoscopic treatment an open surgical procedure: in 7 total reconstructive bladder surgery and in 1 nephrectomy. In 2 cases monolateral RVU (I degree and III degree) persisted after surgical procedures and they remain on the antibiotic-prophylaxis with no documented infections.

Primary endoscopic-puncture of ureterocele is a simple, long-term effective and safe with a minimal morbidity. In most cases the endoscopic technique eliminates the need for major open surgery and in others facilitates the open antireflux procedure by decreasing the need for ureteral tapering.

S079 IS THERE AN AGE DISCREPANCY FOR UTILIZATION OF ADVANCED LAPAROSCOPY? A NATIONAL STUDY OF FUNDOPLICATION AND GASTRIC BYPASS TRENDS AND OUTCOMES

John Morton MD, Sanjeev Dutta MD, Tina Hernandez-Boussard PhD, Craig Albanese MD, Lucile Packard Children's Hospital and Stanford School of Medicine

OBJECTIVES: Case series has previously identified laparoscopy as a technology that can reduce resource utilization and complications. Our study aims included population-based examination of laparoscopic vs. open outcomes for advanced laparoscopic procedures and comparison of adoption rates of laparoscopy between pediatric and adult populations.

METHODS: ICD9 codes for laparoscopic fundoplication and gastric bypass (4467 and 4438 respectively) and open fundoplication and gastric bypass (4466 and 4431/4439 respectively) were queried for 2004-5 from the Nationwide Inpatient Sample. Pediatric population was identified as being less than 18 years of age. Reported variables included age, sex, hospital type, comorbidities, complications, length of stay (LOS), total charges and death. Demographic and outcome variables were compared by either t-test or chi-square analysis as appropriate.

RESULTS: For both fundoplication and gastric bypass, laparoscopy was more frequently employed in the adult population than the pediatric group (72 vs. 32% and 67 vs. 33% respectively). In comparing pediatric outcomes for laparoscopic vs. open fundoplication, laparoscopic procedures were more often performed at teaching hospitals than open (92 vs. 83% respectively). Both LOS and total charges for laparoscopic fundoplication were less than open fundoplication (7 vs. 5 days and \$33,389 vs. \$36,792 respectively). Complications were also higher for the open fundoplication group than the laparoscopic procedures (19 vs. 9%). Similarly, laparoscopic gastric bypass in comparison to open gastric bypass had decreased LOS (4 vs 12), total charges (\$41,235 vs \$75,063), and complications (6 vs. 12%).

CONCLUSIONS: Surprisingly, the utilization of laparoscopy is significantly less in pediatric fundoplications and gastric bypass when compared to the adult procedures. This population-based study confirms that the laparoscopic approach provides superior outcomes when compared to open technique for both fundoplications and gastric bypass.

S080 BOWEL FUNCTION AFTER LAPAROSCOPIC ASSISTED ANORECTOPLASTY FOR THE MALE PATIENTS WITH HIGH AND INTERMEDIATE TYPE IMPERFORATE ANUS

Makoto Yagi PhD, Takeo Yonekura PhD, Takuya Kosumi RN, Hiroshi Yoshida PhD, Takashi Nogami PhD, Hideki Yoshida MD, Division of Pediatric Surgery, Department of Surgery, Kinki University School of Medicine

PURPOSE: The aim of this study was to evaluate the bowel function after the laparoscopic assisted anorectoplasty for the high- or intermediate type imperforate anus.

MATERIAL/METHODS: Subjects are six male patients who underwent laparoscopic assisted anorectoplasty. Type of the imperforate anus was rectobulbar fistula in one, rectourethral fistula in four, and rectovesical fistula in one. The age at present was 2 to 7 years. Bowel function was assessed by Kelly's clinical score, anorectal manometry (n=4), barium enema, and MRI imaging.

RESULTS: Postoperative complications were posterior urethral diverticulum in 1 (intermediate type) and anal prolapse in 4. Clinically, Kelly's score was 4.7+/-1.2 points. 4 cases were classified to "good" (score 5-6 points) 2 cases were to "fair" (score 3-4). Resting anal pressure was 29.4 +/- 12.4 mmHg and relaxation reflex was observed in 3 of 4 cases. Barium study demonstrated good anterior angulation in 4 of 6 cases. MRI imaging showed that the positioning of the rectum was at the center of the puborectal muscle.

CONCLUSION: The patients after laparoscopic assisted anorectoplasty showed a good defecation. Laparoscopic assisted anorectoplasty seemed to be an acceptable procedure for the high-type imperforate anus.

S081 LONG TERM FUNCTIONAL EVALUATION OF FECAL CONTINENCE AFTER LAPAROSCOPIC ASSISTED PULL THROUGH FOR HIGH ANORECTAL MALFORMATIONS

Mohamed S. El-Debeyky MD, H. A. Safan MD, I. A. Shafei MD, H. A. Kader MD, Sameh A. Hay MD, Pediatric Surgery Department, Ain Shams University, Cairo, Egypt

BACKGROUND: During PSARP for high anorectal malformations, rectal dissection and fistula ligation necessitate changing of patient position and laparotomy to complete the procedure. Using laparoscopy helped in performing this mobilization and fistula ligation in the same position with better visualization of the anorectal sling for positioning of the mobilized rectum in its proper location inside the muscle complex. Using this technique should have an impact on anorectal function as compared to the original PSARP where muscle complex was not cut and the rectum was pulled in a way similar to the old techniques for abdominoperineal pullthrough, this necessitates functional re-evaluation.

MATERIAL/METHOD: Out of 15 patients treated with laparoscopic assisted pullthrough for high anorectal malformation, 9 are now older than 3 years for fecal continence evaluation. They were subjected to full clinical history, barium enema, anorectal manometry, and MRI and their degree of continence were graded according to Kelly score.

RESULTS: 6 out of nine patients are clean without any attacks of fecal soiling or incontinence, they evacuate spontaneously but need application of rectal suppository for evacuation from time to time. The remaining 3 patients had variable degree of fecal incontinence. One of them had mucosal prolapse and was excised with good cleanliness post operative. The remaining two are managed by medical control and they are clean with minimal soiling when stools are loose. MRI showed centrally placed rectum within the muscle complex in all cases. Intact muscle complex despite variation in the degree of hypoplasia.

Barium enema showed no colonic dilatation in all with good evacuation with suppositories. Manometry showed high resting pressure that decrease on straining in the 7 clean patients and low in two, does not increase on squeezing and weak RAIR in all of the nine patients. One patient developed dysuria and constipation one year after surgery, VCUG showed huge residual fistula causing rectal and urethral obstruction treated by surgical excision with good functional result.

ORAL PRESENTATION ABSTRACTS



DISCUSSION: Despite the popularity and safety of PSARP a long learning curve is required to achieve good anatomical and functional results. Laparoscopic approach seems to present a considerable attraction as an alternative with the increasing skills due to the wide spectrum of practice with different surgical problems. The state of continence with laparoscopic technique in Imperforate Anus- High Anomaly needs to be subjected to wide and longer follow up to decide upon the chances of improving the outcome of this challenging anomaly

S082 NATIONAL TRENDS AND OUTCOMES FOR PEDIATRIC LAPAROSCOPIC AND OPEN APPENDECTOMY AND CHOLECYSTECTOMY: 1998-2005

John Morton MD, Sanjeev Dutta MD, Tina Hernandez-Boussard PhD, Craig Albanese MD, Lucile Packard Children's Hospital and Stanford School of Medicine

OBJECTIVES: Laparoscopy has emerged as a powerful technology which can lead to decreased cost and complications. Our study aims included population-based examination of laparoscopic vs. open outcomes for appendectomy and cholecystectomy and comparison of adoption rates of laparoscopy for these two procedures.

METHODS: ICD9 codes for laparoscopic appendectomy and cholecystectomy (4701, 4711 and 5123, 5124 respectively) and open appendectomy and cholecystectomy (4709, 4719 and 5121, 5122 respectively) were queried for 1998-2005 from the Nationwide Inpatient Sample. Pediatric population was identified as being less than 18 years of age. Reported variables included age, sex, hospital type, comorbidities, complications, length of stay (LOS), total charges and death. Demographic and outcome variables were compared by either t-test or chi-square analysis as appropriate.

RESULTS: From 1998 to 2005, the number of cholecystectomies grew 48% compared to an increase of 15% for appendectomies. The diffusion of laparoscopy was greater for cholecystectomy than appendectomy from 1998 to 2005 (67 to 84% vs. 19 to 43% respectively) Both LOS and total charges for laparoscopic appendectomy were less than open appendectomy (2.5 vs. 5 days and \$16,608 vs. \$22,658 respectively). Complications were also higher for the open appendectomy group than the laparoscopic procedures (10 vs. 7%). Similarly, laparoscopic cholecystectomy in comparison to open cholecystectomy had decreased LOS (2.5 vs. 11), total charges (\$18,845 vs. \$54,587) and complications (8 vs. 18%).

CONCLUSIONS: Of note, the utilization of laparoscopy is greater in pediatric cholecystectomy than pediatric appendectomy. Cholecystectomy rates have increased more rapidly than appendectomy perhaps reflecting rising pediatric obesity trends. This population-based study confirms that the laparoscopic approach provides superior outcomes when compared to open technique for both appendectomy and cholecystectomy.

EVALUATION & CME FORMS: Please complete the evaluation and CME forms and return to the IPEG Registration Desk. Please allow 60 days from the event date for all forms to be processed and CME certificates to be sent out.



VIDEO PRESENTATION ABSTRACTS

V001 PRONE RETROPERITOSCOPY

Lars J. Cisek MD, Micheal H. Hsieh MD, David R. Roth MD, Edmond T. Gonzales MD, Eric A. Jones MD, Texas Children's Hospital/Baylor College of Medicine

There are three potential approaches to retroperitoneal organs for surgical manipulation: transperitoneal laparoscopic, flank retroperitoneal, and prone retroperitoneal. The latter is likely to be the least familiar and most infrequently utilized method. This approach offers a number of advantages and in the pediatric population most of the technical challenges seen in adults are quite limited. We demonstrate this approach and applications in nephrectomy, heminephrectomy, nephroureterectomy, adrenalectomy, and retroperitoneal lymph node dissection (RPNLD).

METHOD: Patients are positioned prone, supported at the iliac crest and chest allowing the abdomen to fall free anteriorly. Access is gained below the 12th rib, just lateral to the sacrospinalis, using direct access with a Visiport. The retroperitoneal space is created under direct vision using a 10mm telescope and insufflation. Two 3-5 mm working ports are placed, one above the iliac crest and another in the midflank. The intermediate fascia of the retroperitoneum is opened to expose the operative field.

RESULTS: We have used this approach in over 250 cases. All of the cases were completed without repositioning. Two vascular injuries occurred: an adrenal vein was torn in during a nephrectomy and a lumbar vessel was torn during a RPLND repaired both were repaired intracorporally. No case required transfusion. A small bowel tear occurred during kidney morsillation with a nephrectomy, which was recognized and repaired though a 2cm extension of the primary portsite. The majority of patients were discharged in less than one day.

CONCLUSION: The prone retroperitoneal approach offers the surgeon direct access to organs of the retroperitoneum using only three ports with an unencumbered view of critical vascular structures.

V002 LAPAROSCOPIC COLOVAGINOPLASTY: AN ALTERNATIVE TECHNIQUE FOR VAGINAL RECONSTRUCTION IN CHILDREN

Berkutug Bahadır MD, Gulnur Gollu MD, Esra Temeltas MD, Aydin Yagmur MD, Department of Paediatric Surgery, Ankara University Faculty of Medicine

BACKGROUND: Vaginal reconstruction is necessary in children with gender differentiation problems. And it is a part of feminizing genitoplasty. Several surgical techniques have been described for the treatment of children who are in need of vaginal reconstruction. Technical details and results of laparoscopic colovaginoplasty is presented in three children.

PATIENTS/METHODS: Demographic data, diagnosis, operative techniques, length of hospital stay, early and late complications and all surgical videos were investigated.

RESULTS: Laparoscopic colovaginoplasty was performed in three children with complete (n=1) and partial (n=2) androgen insensitivity syndrome. All children had bilateral orchiectomy previously. Median age was 15 years (ranged to 12-17 years). Four trocar technique was used. A ten to twelve centimeter of sigmoid colon was isolated with preservation of the vascular supply. Colocolonic anastomosis was established with a circular stapler. The operative times were 2 to 4 hours. Mean hospital stay was four days. There was no postoperative complication on follow-up and no need of dilation.

CONCLUSIONS: Laparoscopic sigmoid colovaginoplasty is effective and reliable technique in children with vaginal agenesis. Neovagina created with colon has an adequate diameter and length, also has self-moistening property with no need of disturbing dilations.

V003 LAPAROSCOPIC MANAGEMENT OF PERSISTENT MÜLLERIAN DUCT SYNDROME

Aayed R. Alqahtani MD, King Saud University, Riyadh, Saudi Arabia

A 2-years-old boy presented with a nonpalpable left testis. On examination, the right testis was retractile and the left one was nonpalpable. Otherwise,

he has normal male external genitalia. Laparoscopic exploration revealed two testes, uterus and tubes, compatible with Persistent Mullerian duct syndrome (PMS). Laparoscopic division of the persistent mullerian structures was performed, keeping intact the vas deference on both side and bilateral orchidopexy. The video will demonstrate the intra-operative findings and the minimally invasive technique of dealing with this rare entity.

V004 MINIMALLY INVASIVE OPPORTUNITIES FOR PATIENTS WITH IMPERFORATE ANUS WITH RECTOVESTIBULAR FISTULA AND ABSENT OR ATRETIC VAGINA

Sean J. Barnett MD, Marc A. Levitt MD, Lesley Breech MD, Richard A. Falcone MD, Alberto Pena MD, Cincinnati Children's Hospital Medical Center, Division of Pediatric and Thoracic Surgery

INTRODUCTION: Imperforate anus with rectovestibular fistula and absent or atretic vagina is a rare anorectal malformation. Analysis of our series of patients has demonstrated several opportunities for minimally invasive applications (MIS) for the diagnosis and treatment of a wide spectrum of anatomic challenges.

METHODS: Of 1800 patients with anorectal malformations, twenty-three were cared for with this unique anatomy; what appears to be the vagina is actually the rectal orifice ending in the vestibule, and the vagina is absent. The potential applications of MIS techniques were evaluated.

RESULTS: In fifteen cases the distal rectum was utilized as neovagina. In eight cases the distal rectum was mobilized and used as rectum, and the vagina was replaced (In four cases using sigmoid, in two cases using small bowel, in one case by pulling through the upper vagina, and in one case splitting the rectum to be used for both the rectum and the vaginal replacement). In nineteen cases there was no uterus or upper vagina. In four cases there was a normal uterus and upper vagina, which was anastomosed to the neovagina in three cases, and pulled through in one. All patients had two normal ovaries. In a recent case, laparoscopy was utilized to identify and resect atretic intraabdominal Mullerian structures and to identify the lack of a vagina.

CONCLUSION: Imperforate anus with rectovestibular fistula and absent or atretic vagina is a unique anorectal malformation. Minimally invasive surgical techniques can be used to evaluate intraabdominal gynecologic structures and to resect atretic Mullerian structures if present. In appropriate cases, vaginal replacement can be done with a perineal (posterior sagittal) approach alone, with no intraabdominal component. Laparoscopy could also be used to mobilize an upper vagina if present, and for sigmoid resection for potential vaginal replacement, which we consider employing in future cases.

V005 SIGMOID VAGINOPLASTY WITH ROBOTIC SURGERY

Sarah Marietti MD, Brendan Campbell MD, Fernando Ferrer MD, Christina Kim MD, Connecticut Children's Medical Center

INTRODUCTION/OBJECTIVE: Surgery to construct a vagina is technically demanding with many challenges to produce functional and psychological satisfaction. The surgical methods used to create a vagina have advanced through the decades. One option to create a vagina is by using sigmoid colon. This operation requires a transperitoneal and perineal approach and originally was done with a separate laparotomy and perineal incision. To minimize the invasiveness of this operation, it has been reported to use standard laparoscopy to assist performing the intraabdominal portion of the case. We describe an innovative approach to sigmoid vaginoplasty using robotic assisted laparoscopy and one perineal incision.

METHODS: Our patient is a 17 year old 46 XY with androgen insensitivity syndrome. At birth, the family had extensive counseling and decided to rear this child as a female. Our patient was admitted preoperatively for a bowel preparation with Golytely and enemas. The

VIDEO PRESENTATION ABSTRACTS



patient was positioned in a modified lithotomy position with PAS stockings and secured to the bed with tape across the chest. We divided the bowel segment with a laparoscopic endovascular stapler and reapproximated the mesentery using a free hand technique with the robotic arms. We excised the stapled proximal end of the pouch and hand sewed it in two layers. The isolated sigmoid segment was positioned safely posterior to the bladder and anterior to the rectum.

RESULTS: The total time in the operating room was 10 hours and 15 minutes. The estimated blood loss was < 50cc. There were no intraoperative complications. Her incisions are shown one week postoperatively.

Four months postoperatively, the patient is doing well. She is dilating with a #15 anal dilator. She returned to normal activities two weeks postoperatively. She and her family are happy with her cosmetic result and postoperative recovery.

CONCLUSION: Creation of a vagina with bowel segment is a technically demanding case. Using robotically assisted laparoscopy, we can minimize the morbidity of the procedure with excellent results. The operative and cosmetic success of this case reiterates the importance of exploring the best utilization of robotic surgery in both adults and children.

V006 LAPAROSCOPIC EXCISION OF A FAMILIAL PARAGANGLIOMA

Brendan T. Campbell MD, Kristine M. Kelliher MD, Angela H. Santiago MD, D. Elizabeth Estrada MD, Connecticut Children's Medical Center

A 13-year-old male was referred to the Pediatric Endocrinology group at our institution with a 3-year history of intermittent headaches, palpitations, and flank pain. His vital signs were initially normal, but eventually, he became hypertensive and tachycardic. His mother had been diagnosed with a thoracic paraganglioma, and underwent a resection as a teenager. The patient's physical exam was unremarkable. Plasma and urine measurements showed elevated norepinephrine, normetanephrine, and dopamine.

Radiologic imaging studies showed a single 4 x 4cm mass in the abdomen. The mass was superior to the aortic bifurcation, adjacent to the inferior vena cava, duodenum and portal vein. Genetic testing revealed a mutation in the SDHB gene, thereby confirming the diagnosis of familial paraganglioma.

The patient was treated preoperatively with phenoxybenzamine, metyrosine, and prazosin. He was admitted 72 hours prior to surgery, and was given IV hydration. He received a dose of cefazolin prior to induction. Prior to the procedure, central venous and arterial catheters were inserted. The patient was placed in the lithotomy position.

A 12mm STEP trocar was placed periumbilically without difficulty. After insufflation, three 5mm STEP trocars were placed under direct vision. One was placed in the right upper quadrant, one in the left upper quadrant, and one in the epigastrium.

The liver and gall bladder were retracted superiorly, and the colon was retracted inferiorly. A combination of blunt dissection and Ligasure were used to Kocherize the duodenum. The duodenum and stomach were retracted medially and superiorly. The dissection was carried out layer by layer, circumferentially. The vena cava was identified laterally, and the tumor was dissected free successfully. A larger vessel to the vena cava was seen; this was ligated with a 5mm clip and the Ligasure was used on the specimen side. Some bleeding encountered on the anterior surface of the tumor was controlled with a suture ligature. The mass was dissected free, placed in an Endocatchbag and removed through the umbilical incision.

The area of dissection was inspected and found to be hemostatic. All instruments and ports were removed under direct vision and the incisions were closed. The patient was extubated and transferred to the Pediatric Intensive Care Unit on a low-dose epinephrine drip. The epinephrine was weaned over the ensuing 12 hours and the patient was discharged home on postoperative day number four.

V007 TRANS-AXILLARY TOTALLY ENDOSCOPIC ROBOT-ASSISTED ANSA CERVICALIS TO RECURRENT LARYNGEAL NERVE REINNERVATION FOR REPAIR OF UNILATERAL VOCAL FOLD PARALYSIS

Simon K. Wright MD, Thom E. Lobe MD, Blank Children's Hospital/ ENT Clinic of Iowa

Pediatric vocal fold paralysis is a common cause of hoarseness and is often a result of prior intrathoracic invasive procedures, such as PDA ligation or cardiac surgery. Quality of life studies reproducibly demonstrate significant handicap related to chronic hoarseness. Among children, no durable treatment exists: vocal fold injections are temporary and the developing larynx is not suited for thyroplasty. Intense interest in recurrent laryngeal nerve (RLN) reinnervation has emerged over the past decade for adults, and this has been shown to be effective for children, as well. The large neck incision, however, obviates the utility of this approach. Thus, many children are simply left with hoarseness until adulthood.

In this video, we present the novel use of advanced trans-axillary techniques along with robotic-assisted surgery to perform a trans-axillary totally endoscopic robot-assisted ansa cervicalis-to-RLN laryngeal reinnervation procedure. This eliminates the barrier of neck incision, is nearly painless, and provides permanent voice improvement through an outpatient procedure. Access to the ansa cervicalis and RLN was readily available and a zero-tension anastomosis was easily achieved. The surgical robot greatly enhanced the ability to perform the nerve anastomosis. Operative time was less than 3 hours. This very low morbidity procedure creates the option for early voice restoration among children who previously were not offered treatment. We anticipate great interest in this procedure given the treatment void it addresses in this population.

V008 LAPAROSCOPIC TRANSDUODENAL RESECTION OF A DUODENAL DUPLICATION CYST

Steven S. Rothenberg MD, The Rocky Mountain Hospital for Children

PURPOSE: To demonstrate a technique for Transduodenal resection of a duodenal duplication cyst

METHODS: A 17 year old girl presented to the emergency room with a history of right lower quadrant abdominal pain over the past year and a 5 pound weight loss. CT scan demonstrated a paraduodenal cystic mass that was better characterized as a duodenal duplication in the second portion of the duodenum by upper GI. The patient was referred for surgery. After 3 5mm trocars were inserted, the duodenum was Kocherized and examined. The mass was not evident extralumenally. Therefore, a duodenotomy was made between the second and third portion of the duodenum. A bulge was seen and the back wall of the duodenum was opened, entering the duplication cyst. The majority of the cyst wall was excised and the remaining was left to drain within the native duodenum. The duodenum was sutured closed

RESULTS: The patient tolerated the procedure well, was eating on POD 3. She is currently asymptomatic 3 months later

CONCLUSIONS: A laparoscopic approach to duodenal duplication cysts is a safe and effective technique.

V009 LAPAROSCOPIC SPLENIC PRESERVING DISTAL PANCREATECTOMY FOR TRAUMA IN A CHILD

Marcus M. Malek MD, Timothy D. Kane MD, Children's Hospital of Pittsburgh of UPMC

This is a 13-year-old boy with no past medical history who suffered a handlebar injury to the abdomen while riding a dirt bike. He did not report loss of consciousness, although he did complain of abdominal pain. He was evaluated at an outside hospital where a CT scan revealed a grade II splenic laceration and a transection of the distal pancreas. He was transported to our institution for definitive care. Upon transfer he was noted to be hemodynamically stable with a large contusion in the



VIDEO PRESENTATION ABSTRACTS

left upper quadrant. Laboratory evaluation was significant for elevated amylase and lipase which continued to rise after admission. He also developed significant abdominal distension and it was decided to take him to the operating room for definitive management of his pancreatic injury. In the operating room he received a central line to provide post-operative total parenteral nutrition. We performed a laparoscopic spleen preserving distal pancreatectomy. There was a fair amount of old blood seen in the left upper quadrant and behind the pancreas. There was no evidence of active bleeding. The operation was performed without complication and the patient resumed diet by post-operative day 4 and was sent home on post-operative day 7.

V010 COMBINED LAPAROSCOPIC AND THORACOSCOPIC ESOPHAGECTOMY AND GASTRIC PULL UP

Nam Nguyen MD, Fombe Ndiforchu MD, Richard Mathis MD, Michael Hayashi MD, Cathy Shin MD, Childrens Hospital of Los Angeles and Miller's Children Hospital, Long Beach CA

INTRODUCTION: The patient was a four year old male sustained a severe and long esophageal stricture from caustic ingestion. The patient was not a candidate for esophageal dilation. He underwent laparoscopic and thoracoscopic esophagectomy with esophageal replacement using the stomach.

METHOD: Using 5-trochar-technique, we began the operation by laparoscopically taking down the existing gastrostomy tube. The gastrocolic ligament was divided; care was taken not to damage the gastroepiploic vessels as they are the main blood supplies to the conduit. The gastrohepatic ligament was also divided along with the left gastric vessels. The esophagus was mobilized into the mediastinum. The gastric conduit was created by stapling the stomach along its greater curvature. The gastric conduit was attached to the proximal gastric stump so that it could be brought into the chest. A needle feeding jejunostomy was inserted. The patient was turned onto the right thoracotomy position. Four trochars were introduced. The intrathoracic esophagus was mobilized completely. The gastric conduit was pulled up into the chest. The esophagectomy was completed via a right cervical incision. The esophageal specimen was delivered through the cervical incision, pulling the esophageal conduit into the neck. A hand-sewn esophago-gastric anastomosis was performed.

RESULT: Esophagram at five days showed no leak. The patient tolerated PO

CONCLUSION: Thoracoscopic and laparoscopic esophagectomy is technically demanding but feasible and can be used as an alternative technique in some selective patients.

V011 THORACOSCOPIC PATCH REPAIR OF A RIGHT-SIDED CONGENITAL DIAPHRAGMATIC HERNIA IN A NEONATE

Sohail R. Shah MD, George K. Gittes MD, Katherine A. Barsness MD, Timothy D. Kane MD, Children's Hospital of Pittsburgh, University of Pittsburgh Medical Center

PURPOSE: Minimally invasive techniques continue to expand in pediatric surgery; however, there has been some debate over the appropriate operative technique for the management of congenital diaphragmatic hernias in neonates. We present a video of a thoracoscopic patch repair of a right-sided congenital diaphragmatic hernia (CDH) in a 3-day-old male.

METHODS: Our patient was noted to have a right-sided CDH on chest x-ray following respiratory distress at the time of birth. The patient's remaining neonatal workup also confirmed a hypoplastic transverse aortic arch with coarctation and ventricular septal defect (VSD), which were initially diagnosed by prenatal ultrasound. After monitoring the patient for hemodynamic stability and discussion with the family and involved pediatric cardiothoracic surgeons, the decision was made to proceed with a thoracoscopic repair of the CDH.

RESULTS: The large right-sided CDH was noted to involve herniated small bowel, colon, and liver. The diaphragmatic defect was successfully repaired thoracoscopically using a 5 X 5cm polytetrafluoroethylene (PTFE) patch. The patient was extubated on the second postoperative day and ultimately underwent aortic arch augmentation, VSD closure, and patent ductus arteriosus ligation and division at one month of age. There has been no evidence of CDH recurrence in follow-up.

CONCLUSIONS: As demonstrated by our video, large right-sided congenital diaphragmatic hernias requiring patch repair can be successfully repaired thoracoscopically with appropriate surgeon comfort and experience. This minimally invasive approach may also be used in neonates with associated cardiac defects with appropriate cardiothoracic surgical consultation and support.

V012 THORACOSCOPIC AORTOPEXY – CASE PRESENTATION AND OPERATIVE TECHNIQUE

Lena Perger MD, Heung Bae Kim MD, Bradley Linden MD, Harvard Medical School/Children's Hospital Boston

PURPOSE: In this video a case of severe tracheomalacia and our operative approach to thoracoscopic aortopexy is described.

METHODS: Thoracoscopic aortopexy was performed for treatment of severe tracheomalacia. Left sided approach with three ports was used. The aorta was sutured to sternum with series of transversely oriented simple interrupted Prolene sutures. Knots were tied subcutaneously. Pre- and post-procedure bronchoscopy was used to verify improvement in tracheal patency.

RESULTS: This operation was performed without complication. The blood loss was 10ml and the patient was extubated in the operating room. The chest tube was removed on post-operative day #4 and the patient was discharged to home on post-operative day nineteen.

CONCLUSIONS: Thoracoscopic aortopexy is an effective treatment for severe tracheomalacia not controlled by conservative measures. It can be safely performed even in small infants as long as equipment and skill for pediatric thoracoscopy are available. Authors believe that thoracoscopic exposure offers advantages over open technique and is cosmetically more pleasing to patients and their families. It may result in less pulmonary complications, shorter hospital stay, and less narcotic requirement compared to open thoracotomy.

V013 THORACOSCOPIC DIVISION OF A VASCULAR RING

Aayed R. Alqahtani MD, King Saud University, Riyadh, Saudi Arabia

A 4 months-old boy presented with respiratory distress. He was then intubated and transferred to our hospital. He had history of recurrent chest infections and dysphagia. A diagnosis of pneumonia was entertained and he was put on antibiotic for two weeks. Multiple attempts to extubate were not successful. CT-Angiogram with 3D reconstruction revealed a double aortic arch with dominant left. A thoracoscopic division of the right aortic arch was carried out successfully. The video will present the 3D reconstruction and the technique of thoracoscopic division of the right aortic arch for which we could not find any previous description in the literature.

V014 THORACOSCOPIC REPAIR OF NEONATAL CONGENITAL DIAPHRAGMATIC HERNIA

David Bliss MD, Sanjay Krishnaswami MD, Oregon Health and Science University

BACKGROUND: Continued innovations in minimally invasive operations have allowed their broader application. Until relatively recently, however, repair of Bochdalek type diaphragmatic hernias (CDH) in the neonatal period was considered both excessively technically challenging and risky due to hypercarbia and pulmonary hypertension.

METHODS: 31 consecutive neonates have undergone thoracoscopic repair of CDH (t-CDH). Once the child achieves physiologic stability, he or she is considered for repair. Using 3mm trocars and instruments

VIDEO PRESENTATION ABSTRACTS



combined with insufflation of a pressure of 3mm Hg, the abdominal viscera are reduced and a repair performed using interrupted, permanent suture tied extracorporeally. A chest tube is left through one of the trocar sites for 24 to 48 hours. Recovery is uneventful.

DISCUSSION: Thoracoscopic repair of posterolateral diaphragmatic hernias may be completed both safely and effectively in neonates.

V015 LAPAROSCOPIC REPAIR OF A LEFT CONGENITAL POSTEROLATERAL DIAPHRAGMATIC HERNIA IN A 3 WEEK OLD

David Bliss MD, Oregon Health and Science University

BACKGROUND: Minimally invasive surgical techniques are being applied to a greater breadth and depth of Pediatric Surgical diseases. However, application of this methodology to diaphragmatic hernia of Bochdalek (CDH) has been slowed by concerns about potential physiological risks such as hypercarbia and pulmonary hypertension as well as questions about best approach, thoracic or abdominal.

METHODS: Newborns who were admitted from home with either mild respiratory or gastrointestinal symptomatology and who appear to have adequate abdominal domain have been considered for laparoscopic repair. Here we present a representative video of a 3-week old infant who underwent successful laparoscopic primary repair of a left-sided CDH.

DISCUSSION: Congenital diaphragmatic hernia of Bochdalek is amenable to repair by minimally invasive techniques. Children without significant cardiopulmonary compromise may be considered for the laparoscopic approach.

V016 ENDOSCOPICALLY-GUIDED, THORACOSCOPIC ESOPHAGECTOMY FOR STRICTURE IN A CHILD

Timothy D. Kane MD, Marcus Malek MD, Aviva L. Katz MD, Children's Hospital of Pittsburgh of UPMC

A six year old boy developed a tight, short esophageal stricture from a lye ingestion injury at the age of four. He had a gastrostomy tube placed at the time for supplemental feedings and subsequently failed several attempts at ante grade and retrograde esophageal dilatation. This video demonstrates an endoscopically-guided (endoscopes simultaneously passed retrograde via the gastrostomy opening and ante grade through the oropharynx), thoracoscopic esophagectomy and primary anastomosis management of the stricture.

TECHNIQUE: In the left lateral decubitus position, 4 x 5 mm ports were placed in the right chest in the 5th intercostal space- anterior-axillary line; 6th intercostal space, mid-axillary line; 4th intercostal space- mid-axillary line; and 7th intercostal space-posterior axillary line. A 5 mm 30 degree telescope, 4.9 mm and 9.4mm esophagoscopes were used. The area of esophageal stricture was identified using the endoscopes and thoracoscopically dissected circumferentially. The vagus nerves were identified and freed from the esophageal segment. Primary resection and anastomosis was performed using intracorporeal sutures and then tested for leak using the endoscope via the gastrostomy site.

RESULTS: Esophagogram on post-operative day #7 revealed no leak and a widely patent anastomosis. He was discharged home on a soft diet on post-operative day #8 and continues to feed orally over 3 months following his operation.

CONCLUSION: Endoscopy is a useful adjunct in the performance of a thoracoscopic esophagectomy for short esophageal stricture.

V017 LAPAROSCOPIC GASTRIC PULL-UP WITH CERVICAL ESOPHAGOGASTRIC

Shawn D. St. Peter MD, Daniel J. Ostlie MD, Children's Mercy Hospital

PURPOSE: This video will show the technique of a complete laparoscopic approach for gastric pull-up with cervical esophagogastric anastomosis in an 8 month old patient with pure esophageal atresia.

METHODS: The patient is placed in the supine frog leg position at the foot of the operating table. One 10 mm, one 5 mm and three 3 mm cannulas were utilized to take down the existing gastrostomy, divide the

short gastric arteries, perform the esophageal hiatal dissection (including the distal esophageal remnant), divide the left gastric artery and mobilize the stomach. The esophageal remnant and portion of the lesser curve are resected using an Endo-GIA stapler. The posterior mediastinum is dissected under direct laparoscopic visualization to create a tunnel for the gastric pull-up. A right cervical collar incision is made and the cervical esophagus is dissected free. The superior mediastinal dissection is similarly performed under direct visualization through the incision and with the laparoscope. The fundus of the stomach is brought through the mediastinal tunnel and the esophagogastric anastomosis is performed through the cervical incision. A laparoscopic pyloromyotomy is performed.

RESULTS: The patient recovered uneventfully and underwent a contrast swallow one week postoperatively which revealed a no evidence of a leak at the site of the widely patent anastomosis.

V018 LAPAROSCOPICALLY ASSISTED GASTRIC TRANSPOSITION FOR LONG-GAP ESOPHAGEAL ATRESIA

Philipp O. Szavay MD, Hans Joachim Kirschner MD, Tobias Luithe MD, Joerg Fuchs MD, Dept. of Pediatric Surgery, Children's Hospital, University of Tuebingen

PURPOSE: The most common indication for esophageal replacement in children is long-gap esophageal atresia. Laparoscopically assisted gastric transposition for this purpose has been carried out in adults and in single cases in the pediatric population. Authors report with their video on the laparoscopically assisted procedure in an 5 months old boy with type I b long-gap esophageal atresia.

METHODS: Postnatally a cervical esophagostomy as well as a gastrostomy were performed. Surgery for gastric pull-up was undertaken including the closure of the gastrostomy site, exposure of the esophageal hiatus with transhiatal dissection, complete mobilization of the stomach, resection of the lower esophageal stump, the left-thoracic pull-up of the stomach with anastomosis to the upper esophageal stump and a laparoscopical feeding jejunostomy using laparoscopic techniques.

RESULTS: No intra- or perioperative complications occurred. Operation time was 3 hours 50 minutes. The child could be weaned and extubated on day after surgery, but had to be re-intubated due to respiratory problems. Further course was then uneventful, postoperative upper GI studies showed no obstruction and a good gastric clearance 6 weeks after surgery.

CONCLUSIONS: Gastric transposition seems to be the therapy of choice in children who require esophageal replacement. As indicated in the literature, the surgical procedure can be done laparoscopically assisted. As in minimally invasive surgery in general also in patients with need for esophageal replacement, the morbidity of a large laparotomy and/or thoracotomy can be avoided. Careful patient selection and monitoring is mandatory. The laparoscopic approach is technically demanding but offers excellent view on site visualization of the surgical site and exact preparation at the transhiatal dissection. Long-term results are pending.

V019 TORACOSCOPIC MANAGEMENT OF LONG-TERM COMPLICATIONS AFTER REPAIR OF CONGENITAL TRACHEOESOPHAGEAL FISTULA IN CHILDREN

Yuriy Sokolov MD, Sergei Yurkov MD, Ildar Valiulov MD, Russian Medical Academy of Postgraduate Education, Moscow, Children's Hospital E-#8470; 15, Perm, Russia

INTRODUCTION: The cause of respiratory symptoms that persist after division of congenital tracheoesophageal fistula (TEF) may be related to airway obstruction by the large redundant tracheal remnant or recurrence of the fistula itself. The aim of this study is to evaluate the role of a thoracoscopic approach for correction of such type disorders.

MATERIALS/METHODS: Two patients (3-year-old girl and 7-year-old boy) were referred to the hospital after neonatal repair of a Gross type C TEF. They suffered from recurrent episodes of respiratory infections



VIDEO PRESENTATION ABSTRACTS

and symptoms of recurrent airway obstruction. Bronchoscopy in both revealed a large diverticulum in the lower tracheal membranous portion. Esophagoscopy in one demonstrated a small fistulous opening at the right lateral aspect of the old anastomosis. Both patients were referred to surgery through a right thoracoscopic approach using 5 mm 30 degree camera, two 5 mm and one 3 mm ports. After dissection of the adherences around the upper lobe the pleura overlying the posterosuperior mediastinum was excised, exposing lower part of trachea and esophagus. Large tracheal pouch measuring 2.5 cm in length was doubly ligated with 4-0 Ethibond and excised in one and recurrent TEF was resected in another. The defects of tracheal and esophageal walls were closed using intracorporeal one-layer interrupted sutures of 5-0 Vicryl with interposition of "Tachocomb" to secure both suture lines.

RESULTS: Thoracoscopy was successful in both cases. Average duration of the operations was 140 min. Chest tubes were removed on day 4. Postoperative recovery was uneventful. Symptoms resolved after surgical procedures in both patients.

CONCLUSIONS: Thoracoscopic approach provides a safe and effective treatment in the cases of the tracheal remnants or recurrent TEF after neonatal surgery for esophageal atresia.

V020 LAPAROSCOPIC DISMEMBERED PYELOPLASTY IN A CHILD WITH A RELATIVELY INACCESSABLE INTRARENAL PELVIS

Hannu Lintula MD, Hannu Kokki MD, Kari Vanamo MD, Kuopio University Hospital, Kuopio, Finland

INTRODUCTION: Laparoscopic pyeloplasty is an accepted way of dealing with pelvi-ureteric junction obstruction in children with extrarenal pelvis. However, intrarenal pelvis has been considered a relative contraindication for laparoscopic pyeloplasty.

OBJECTIVE: Here we describe the technique of laparoscopic dismembered pyeloplasty in a child with intrarenal pelvis.

METHODS: Our patient was a 13-year old girl with a history of right-sided purulent pyelonephritis and a percutaneous nephrostomy due to pelvi-ureteric junction obstruction. The placement of the nephrostomy was complicated with intra- and extrarenal hemorrhage. To avoid recurrent acute pyelonephritis we decided to perform laparoscopic pyeloplasty one month after the removal of the nephrostomy. We used a 4-trocar-technique to expose the right kidney. The kidney was surrounded by intense scarring. The lower pole of the right kidney was mobilized to gain access to the right ureter.

The proximal ureter was manipulated meticulously and dissected free from surrounding fibrotic tissue. The renal pelvis was exposed and it was found to be completely intrarenal. Therefore, the stay sutures could not be used. By using a forceps the kidney was lifted in a vertical position. The poorly vascularized pelvi-ureteric junction was exposed. The patient did not have an aberrant crossing artery. A 2-cm segment of proximal ureter was resected. A 2-cm segment of ureter was spatulated. The re-anastomosis was made over a double pigtail ureteral stent using absorbable interrupted 4/0 polyglactin sutures. The peritoneum was not closed. The drain was left in the abdominal cavity.

RESULTS: The laparoscopic pyeloplasty was completed in 320 minutes. A caudal migration of the proximal double pigtail stent was observed on the second postoperative day and we were compelled to change the stent through cystoscope. Therefore, the patient was not discharged home until the eight postoperative day. The stent was removed one month after the operation. The patient after 12 months of follow-up was asymptomatic, and imaging with Tc-99m-Mercaptoacetyltryglycine (MAG 3) showed that the right kidney contributed 46% of renal function with no evidence of obstruction.

CONCLUSION: Laparoscopic transabdominal dismembered pyeloplasty appears to be safe and effective approach to the management of pelvi-ureteric junction obstruction in children with intrarenal pelvis.

V021 PRIMARY LAPAROSCOPIC URETEROCALICOSTOMY IN A PEDIATRIC PATIENT

Alex W. Caillat MD, Paul H. Noh MD, Cincinnati Children's Hospital Medical Center, University of Cincinnati

Pyeloplasty is the contemporary definitive surgical management of ureteropelvic junction (UPJ) obstruction. However, under certain circumstances such as a small intrarenal pelvis, extremely thinned parenchyma, and/or prior failed pyeloplasty, ureterocalicostomy may be utilized as an alternative.

There have been only a handful of reports of laparoscopic ureterocalicostomy in the adult population. To our knowledge, there are no reports in the pediatric population.

This video demonstrates the technique of primary laparoscopic ureterocalicostomy in a 13-year-old female. The patient had a high insertion of the UPJ as well as lower pole crossing vessels precluding a laparoscopic pyeloplasty with the transabdominal approach. Three ports were used as well as a percutaneous holding suture for intraoperative exposure.

The patient was discharged home in stable condition on POD#1 with a ureteral stent in place, tolerating a diet, ambulating, and pain free.

This case presentation is an example of how this procedure, if performed in the appropriate clinical situation, can be safely applied to the pediatric patient.

V022 TECHNIQUE OF LAPAROSCOPIC TRANSPERITONEAL LOWER POLE HEMI-NEPHROURETERECTOMY

Anies Mahomed MD, James Lewis, Department of Paediatric Surgery, Royal Alexandra Children's Hospital, & Department of Medical Illustrations, Brighton, UK

BACKGROUND: Laparoscopic transperitoneal nephrectomy is technically feasible in most cases of benign renal disease. To date there have been isolated reports of laparoscopic transperitoneal heminephroureterectomy of principally the upper moiety of a duplex system. Rarely reported are lower moiety nephroureterectomies.

AIM: To present a 3 minute video demonstrating the technical details of a transperitoneal laparoscopic, right, lower moiety, heminephroureterectomy in a 3 year old.

METHOD/TECHNIQUE: A child with marginally functioning (<5%) lower moiety of a right duplex system was subjected to a transperitoneal heminephroureterectomy. The patient was placed in a left lateral position and an umbilical camera and 2 working ports (right iliac fossa, epigastric) all 5mm, were utilised. The ascending colon was reflected to the left and the underlying lower moiety ureter identified and isolated. With traction on the ureter the pelvis was brought into view and control of blood supply to the lower moiety was achieved using a combination of ultrasonic scalpel and hook diathermy. A critical step at this stage was definition of the superior limit of the pelvis which corresponded to the level of vascular demarcation. The renal parenchyma was transected at this point using the ultrasonic scalpel which ensured reasonable hemostasis. Complete hemostasis was assured by approximating the divided kidney with a series of 3 interrupted intracorporeal sutures. The subtending ureter was dissected to close to the bladder base where it was ligated and divided. A drain was placed percutaneously in the renal bed and the specimen retrieved via an extended umbilical incision.

RESULT: The patient was started on fluids on recovery with oral feeds introduced the next morning. The drain was removed prior to discharge on day 2. At 6 months post resection the patient remains well.

CONCLUSION: Laparoscopic transperitoneal lower pole heminephroureterectomy is technically feasible for benign renal disease in children. The combination of ultrasonic scalpel and intracorporeal suturing is adequate to control bleeding of the transected kidney. Dissection of the ureter distally to bladder neck is easily achieved without change in port

VIDEO PRESENTATION ABSTRACTS



position. Recovery is robust with minimal requirement for analgesia. The wider space, better view and ability to access all of the urinary tract makes this a tenable alternative to other laparoscopic approaches.

V023 ROBOTIC REPAIR OF CONGENITAL PARAESOPHAGEAL HIATAL HERNIA

Daniel A. DeUgarte MD, James B. Geiger MD, Ronald Hirschl, University of Michigan - Ann Arbor; UCLA - Los Angeles

INTRODUCTION: Congenital paraesophageal hiatal hernias are rare and can be technically challenging to repair laparoscopically. We present a case in which the 5mm robotic platform was utilized to facilitate hernia sac dissection, hiatal repair, and fundoplication.

CASE: A three year old child presented with a history of intermittent bouts of severe abdominal pain and the sensation of needing to “burp.” An UGI contrast study demonstrated the presence of a paraesophageal hiatal hernia with partial gastric volvulus. A 5mm robotic platform was utilized to facilitate the repair. The stomach, which was not initially visible, was reduced and derotated. The hernia sac was densely adherent and required extensive careful dissection with the intent of preserving the blood supply to the stomach and preventing injury to the vagus nerve. Once the esophageal hiatus was clearly delineated, silk sutures were used to approximate the defect posteriorly. In order to prevent undue angulation of the esophagus, additional sutures were placed anteriorly to close the hiatal defect. A slightly foreshortened esophagus was sutured to the adjacent diaphragm. A floppy Nissen wrap was then fashioned. The patient was discharged home a couple of days post-operatively.

DISCUSSION: Surgical repair of congenital or primary paraesophageal hiatal hernia is advocated even in asymptomatic patients because of the risks of gastric volvulus, strangulation, mucosal ulceration, and anemia. Most surgeons recommend primary repair without a reinforcing patch. A fundoplication is advocated to prevent an otherwise high incidence of reflux. While not as “intuitive” as their 8mm counterparts, the 5mm snake-like articulating robotic instruments nonetheless greatly facilitated the extensive hernia sac dissection as well as precise suture closure of the hiatal defect.

V024 ROBOTIC RESECTION OF A MEDIASTINAL TERATOMA

Bethany J. Slater MD, Laura Phearman MD, John J. Meehan MD, Seattle Children's Hospital & Regional Medical Center, University of Iowa Children's Hospital, Lucille Packard Children's Hospital

VIDEO SUMMARY: Robotic surgery may be ideal for certain minimally invasive procedures when compared to laparoscopic and thoracoscopic instruments. Resection of solid chest tumors may fall into this group. We present a video demonstration of a robotic resection of a benign mediastinal teratoma.

2008 POSTER SESSION: Posters will be displayed, Friday, June 13th for Group A and Saturday, June 14th for Group B. If you are presenting a poster, please make sure to remove your poster immediately following your poster tour.

COPYRIGHT: The program and talks presented at the 2008 IPEG Annual Meeting are copyrighted products of the International Pediatric Endoscopic Group. Any reproduction or rebroadcasting without the express written consent of IPEG is strictly forbidden.



POSTER ABSTRACTS LISTINGS

POSTER GROUP A

GASTROINTESTINAL & HEPATOBILIARY

- P001 Laparoscopic Diagnosis and Treatment of Congenital Duodenal Obstruction
- P002 Primary Laparoscopic Pull-through in Hirschsprung's Disease
- P003 Laparoscopic Duodenoduodenostomy for Duodenal Atresia in Neonates
- P004 Is Prophylactic Fundoplication Necessary in Neurologically Impaired Children ?
- P005 Laparoscopic Surgery For Liver Hydatid Cysts In Children
- P006 Insufficiency of Laparoscopic Gastropexy For Treatment of Gastric Volvulus Associated With Dilatation Of Transverse Colon: A Case Report
- P007 Laparoscopic Treatment of Hiatal Hernia in Patients with Gastroesophageal Reflux Disease
- P008 Funduplasty Type Nissen en Pediatric, Laparoscopy VS Open
- P009 Thoracoscopic Surgery of Fistula Ligation and One-stage Esophageal Anastomosis for Congenital Esophageal Atresia
- P010 Three Trocar Approach for Laparoscopic Nissen Fundoplication
- P011 Laparoscopic Liver Biopsy in Children with Hepatic Coagulopathy
- P012 Laparoscopic Repair of Delayed Congenital Diaphragmatic Hernia In The Post-Neonatal Period.
- P013 Complications of Laparoscopic Pyloromyotomy: Does Size Make a Difference?
- P014 Clinical Usage of Laparoscopically Assisted Subtotal Colon Resection in Children
- P015 Trends in Pyloromyotomy at a Pediatric Teaching Institution
- P016 Gasless, Bladeless Access
- P017 Laparoscopic Gastropexy for the Treatment of Gastric Volvulus Associated with Wandering Spleen
- P018 Laparoscopic Appendectomy in Children – Alternative of Choice
- P019 Simple Marker for Intra-Operative Detection of Gastro-Duodenal Perforations During Pyloromyotomy
- P020 Laparoscopy for Recurrent Abdominal Pain in Children
- P021 Outcome of Laparoscopic Heller's Oesophagomyotomy to Treat Achalasia in 12 Children
- P022 Routine Preoperative ERCP Is Unnecessary in Children with Choledocholithiasis
- P023 Laparoscopic Hepatojejunostomy For Type ⅰ Orⅱ Biliary Atresia
- P024 Laparoscopic Total Cyst Excision With Roux-En-Y Hepatojejunostomy For Neonates With Choledochocyst
- P025 Effect of Elevated Intra-Abdominal Pressure (IAP) on Portal Vein (PV) and superior Mesenteric Artery (SMA) Blood Flow in a Rat
- P026 Laparoscopic Cholecystectomy in Paediatric Population: Is It Feasible as a Day-Surgery Procedure?
- P027 The Guidance ff Ultrasonography and Vessel Doppler Studies In Pediatric Laparoscopic Splenectomy
- P028 285 Laparoscopic Splenic Procedures In Children – Single Clinic Experience
- P029 Laparoscopic Near-Total Pancreatectomy for Persistent Hyperinsulinaemic Hypoglycaemia of Infancy: Report of Two Cases
- P030 Laparoscopic Transhiatal Gastric Transposition for Esophageal Atresia with Preservation of the Abdominal Esophagus
- P031 Interval Laparoscopic Appendectomy in a Child with G6PD Deficiency
- P032 Laparoscopic Approach for Esophagogastric Dissociation (Bianchi's Procedure): Is It a Good Way?
- P033 Laparoscopically Assisted Anorectal Pull-Through for High Imperforate Anus
- P034 Complications After Open and Laparoscopic Appendectomy for Perforated Appendicitis
- P035 Minimal Invasive Surgery for Benign and Malignant Pancreatic Lesions – Case Series
- P036 Fast-Track Surgery of the Colon In Children
- P037 Cecostomy Button Placement After Percutaneous Cecostomy or Sigmoidostomy Under Laparoscopic Control – Survey of 29 Patients
- P038 Pitfalls of laparoscopic Repair of Morgagni Hernia
- P039 Laparoscopic Management of Large Umbilical Hernia Using the Mesh – First in Pediatric Age
- P040 Treatment of Complicated Appendicitis in Children Using a Laparoscopic Approach. Is There Any Advantage In Its Use or It Is Unnecessary?
- P041 Laparoscopic Gastropexy for Gastric Volvulus in a Girl
- P042 Laparoscopic Endorectal Colon Pull-Through Leaving A Short Rectal Seromuscular Sleeve For Hirschsprung Disease: Personal Experience with 200 Cases
- P043 Laparoscopic Chait Cecostomy Tube Placement for the Management of Fecal Incontinence: Outcomes and Lessons Learned
- P044 Surgical and Anesthesiologic Pitfalls During Experimental Laparoscopic Fundoplication in Young Pigs
- P045 Laparoscopic Repair of High Imperforate Anus
- P046 An Unusual Journey of a Retained Fecalith
- P047 Pediatric Laparoscopic Cholecystectomy: Our experience in the Regional Hospital of Pucallpa, Ucayali – Perú
- P048 Effectiveness of Basic Endoscopic Surgical Skill Training for Pediatric Surgeons
- P049 Laparoscopic Cholecystectomy In Children: Lesson Learned From The First 109 Cases
- P050 An Alternative Method For Dilatation of a Persistent Segmental Caustic Esophageal Stricture
- P051 Intraoperative Upper GI Endoscopy Ensures An Adequate Laparoscopic Heller's Myotomy
- P052 Laparoscopic-assisted pneumatic Reduction of Intussusception
- P053 Laparoscopic adrenalectomy For Adrenal Tumors In Children
- P054 Minimal Invasive Surgery for Patients with Situs Inversus
- P055 Rectal prolaps: Rectopexy by Laparoscopy
- P056 The Laparoscopic Evaluation Of The Radiological Diagnosis of Intestinal Malrotation
- P057 Single Port Intracorporeal Laparoscopic Appendectomy (SPI-LA): A Unique Opportunity For Advancing Endoscopic Surgical Skills of Pediatric Surgery Residents
- P058 The Road To Paediatric Laparoscopic Fundoplication (LF)
- P059 Does Preexisting Gastrostomy Affect Laparoscopic Nissen Fundoplication?
- P060 Short-term Results of PEG and Laparoscopic Gastrostomy – Single Center Experience
- P061 Laparoscopic Cystojejunostomy In A Child With A Pancreatic Pseudocyst
- P062 Laparoscopic Treatment of Morgagni Hernia
- P063 Impact of Preoperative Weight Loss in Adolescents Undergoing Roux-en-Y Gastric Bypass
- P064 Isolated Torsion of Hydatid of Morgagni in Female: A Rare Possible Alternative Diagnosis in Acute Abdominal Pain

POSTER ABSTRACTS LISTINGS



- P065 Treatment of the liver abscess in children. Regional Hospital of Pucallpa, Ucayali – Peru
- P066 Laparoscopic Procedures For Choledochal Cysts
- P067 How Safe Is The Presence of PEG-related Postprocedural Pneumoperitoneum.
- P068 Modified Pyloric Traumatomyoplasty: An Alternative Surgical Procedure in Infantile Hypertrophic Pyloric Stenosis.
- P069 Laparoscopic Inguinal Hernia Repair in Children with Transperitoneal Division of the Hernia Sac
- P070 Laparoscopic Anterior Gastropexy For Gastric Volvulus
- P071 Laparoscopic Fundoplication After Previous Open Abdominal Operations
- P072 Laparoscopic Management Of Stomal Prolapse
- P073 Laparoscopic Total Intracorporeal Correction of Choledochal Cyst
- P074 Laparoscopic Appendectomy: Burden or Benefit; A Single Center Experience

INTERVENTIONAL RADIOLOGY

- P075 3D Imaging and Real Time Needle Guidance in the Interventional Radiology Suite

MISCELLANEOUS

- P076 Laparoscopic Ovary Sparing Surgery (LOSS) for the Treatment of Benign Ovarian Neoplasm (BON) in Pediatrics is Safe
- P077 Withdrawn
- P078 Paraovarian Microcyst Torsion Presenting with Acute Abdominal Findings
- P079 Laparoscopic Monolateral Adrenalectomy in Isolated Primary Pigmented Nodular Adrenocortical Disease (PPNAD).
- P080 Laparoscopic Resection of a Mature Cystic Ovarian Teratoma in a Premenarchal Patient
- P081 Can Morbidity Associated With A “Learning Curve” Be Avoided with a Proctorship System?

MY FAVORITE TRICKS

- P082 Reduction of Gastroduodenal Intussusception: A Combined Endoscopic and Laparoscopic Approach

THORAX

- P083 Lung Nodules In Pediatric Oncology: The Role of Thoracoscopy
- P084 Laparoscopic Repair of Late-Presenting Morgagni and Bochdalek Hernia in Children
- P085 Thoracoscopic Resection of Benign Intercostal Lipoma in a 9 Years Old Boy with Hemophilia
- P086 Bilateral Single Stage Thoracoscopic Sympathectomy for Palmar Hyperhidrosis (Supine Position)
- P087 Thoracoscopic Treatment of Lung Congenital Lesions: Report of Three Cases.
- P088 Conservative Thoracoscopic Treatment of Necrotizing Pneumonia

TRACHAEL (AIRWAY)

- P089 Endoscopic Diagnosis and Treatment of Recurrent Tracheoesophageal Fistula

UROLOGY

- P090 Laparoscopic Nephrectomy – Advantages of Technique in Infants And Newborns.

POSTER GROUP B

GASTROINTESTINAL & HEPATOBILIARY

- P091 Laparoscopic Colectomy in a Patient with Ulcerative Colitis and Cirrhosis
- P092 A Neonatal Laparoscopic Ladd’s Procedure Can Safely Be Performed Even if the Bowel Shows Signs of Ischaemia
- P093 Laparoscopic Duodenal Diverticulectomy for Diverticulitis in Adolescence: A Case Report
- P094 Laparoscopic Surgery of the Spleen
- P095 A Retrospective Audit of the Three Standard Procedures Used in the Surgical Treatment of Infantile Hypertrophic Pyloric Stenosis
- P096 Atypical Presentations of Meckel’s Diverticulum Determined by Laparoscopic Exploration
- P097 Withdrawn
- P098 Neonatal Isolated Gastric Polyp: A Rare Entity in Newborn
- P099 Peritoneal Inclusion Cyst: Diagnosis and Laparoscopic Management
- P100 Neonatal Laparoscopy in Newborn Affected by Nec: Case Report
- P101 Laparoscopic Management of Intussusception in Children
- P102 Roux-en-Y gastro-Jejunal Anastomosis in NIC
- P103 Percutaneous Endoscopic Gastrostomy (PEG) in Pediatric Patients: Our Experience and Proposal of Follow-Up Methodology
- P104 Incisional Hernia On A 5-mm Trocar Port Site After Laparoscopic Pancreatic Tail Biopsy
- P105 Laparoscopic Roux-En-Y Hepaticojejunostomy In Children With Pancreaticobiliary Maljunction
- P106 Minimal Invasive Surgery for Lower Esophageal Pathology, Congenital and Iatrogenic

INTERVENTIONAL RADIOLOGY

- P107 Varicocele Embolization with Boiling Contrast

MISCELLANEOUS

- P108 Why Do We Convert?
- P109 The Anatomical Pathology of the Processus Vaginalis In Childhood Hydroceles As Seen At Laparoscopy Differs From That Described In The Classic Pediatric Surgical Text Books
- P110 Efficacy Of Laparoscopy For Intra-Abdominal Large Cystic Mass In Children
- P111 Laparoscopic Insertion of an Abdominal Expander Before Radiotherapy of a Right Iliac Ewing Sarcoma To Prevent Small Bowel Enteritis
- P112 Laparoscopic Assisted Tenckhoff Catheter Implantation Vs Open Procedure: Advantages And Disadvantages
- P113 Pediatric Laparoscopic Surgery In Abidjan (Côte D’Ivoire)
- P114 A Mobile Cecum Predisposing To A Major Complication of Laparoscopic Assisted Ileostomy
- P115 Fetoscopic Surgery Of Extremity Amniotic Bands: Limb Salvage By Intrauterine Band Release In The Human Fetus.
- P116 Percutaneous Inguinal Herniorrhaphy With Endoclose Needle
- P117 Laparoscopic Femoral Hernia Repair
- P118 “Umbilicoplasty Like”(UPL) A Simple Technique For Training 1st Trocar Insertion
- P119 Withdrawn
- P120 Two Trocar Palomo Varicolectomy In Adolescents



POSTER ABSTRACTS LISTINGS

- P121 Emergency Laparoscopic Assisted Gastrotomy for the Treatment of an Iron Bezoar
- P122 Laparoscopic Inguinal Herniorrhaphy in Babies Weighing 5 Kilograms and Less
- P123 The Use of Animal Models (AM) for Training in Pediatric Endosurgery
- P124 Ovarian Cysts and Laparoscopic Unroofing: A Critical Revision
- P125 Resection of The Hernia Sac Using Laparoscopic Techniques: A New Method for Treating Inguinal Hernias On Children
- P126 Experience with the Exclusive Use of 5mm Instruments for Paediatric Laparoscopy
- P127 Randomized Controlled Trials in Paediatric Minimal Access Surgery
- P128 Laparoscopic Inguinal Hernia Repair in Children – No Ligation, Just Resection.
- P129 Laparoscopy in Pediatric Situs Inversus Totalis: Case Report and Literature Review
- P130 New Laparoscopic Flip Flap Technique Versus Conventional Inguinal Hernia Repair in Children. Is It Worth It?
- P131 Inguinal Hernia Repair Through a Minimal Skin Incision: Is Laparoscope an Indispensable Instrument for Inguinal Hernia Repair in Children?

MY FAVORITE TRICKS

- P132 Application of Laparoscopic Gangrenous Appendectomy with Perforation
- P133 Technical Aspects of the Laparoscopic Management of a Late Presenting Duodenal Web

ROBOTICS & EMERGING TECHNOLOGY

- P134 Experience With a New Energy Source for Tissue Fusion In Pediatric Patients
- P135 Stress Is Good? Performance Under Stress After Simulation Training.
- P136 Feasibility of Microlaparoscopy for Surgical Procedures of Advanced Complexity in Children
- P137 Robotic-Assisted Paediatric Laparoscopic Surgery: Preliminary Report
- P138 Robotic Repair of Congenital Diaphragmatic Anomalies
- P139 An Immersive Virtual Reality Environment for Patient Data Visualization and Endoscopic Surgery Planning

THORAX

- P140 Thoracoscopic Repair of Esophageal Atresia and Tracheoesophageal Fistula (EA-TEF) – A Single Surgeon Experience
- P141 Thoracoscopic Management of Complicated Parapneumonic Effusions In Young Children
- P142 MRI as an Alternative to CT in the Preoperative Evaluation of Pectus Excavatum
- P143 Thoracoscopic Treatment of Pulmonary Hydatid Cyst in Children
- P144 Thoracoscopic Treatment of Complicated Esophageal Atresia
- P145 Tube Thoracostomy Is Rarely Necessary Following Thoracoscopic Lung Biopsy
- P146 VATS Under Thoracic Epidural Anaesthesia in Children – Our Experience In 23 Cases

- P147 Video Assisted Toracoscopic (VAT) Removal of Mature Cystic Mediastinal Teratoma in A 4 Years Old Child
- P148 Treatment of Funnel Chest Following Previous Thoracotomy
- P149 Minimally Invasive Surgery in Ectopic Extralobar Pulmonary Sequestration: About Six Cases
- P150 Laparoscopic Mangement Of Foramen of Morgagni Hernia in Childhood
- P151 Thoracoscopic Surgery for Posterior Cervico-Mediastinal Tumors in Children

UROLOGY

- P152 Endoscopic Mic-Key Button Placement for Continent Vesicostomy
- P153 Laparoscopic Redo Pyeloplasty in Infants and Children
- P154 Laparoscopic Excision of Urachal Cyst in Pediatric Age: 3 Cases Report
- P155 Laparoscopic Nephrectomy for Wilms' Tumor After Chemotherapy: Our Initial Experience
- P156 Laparoscopic Surgery for Varicoceles in Children: A Single Centre Audit
- P157 Ureteroscopy in Young Children
- P158 Minimally Invasive Treatment of Bladder Calculi After Repair of Cloacal Anomaly: A Case Report
- P159 Unusual Presentation of Antenatal Ovarian Torsion: Free Floating Abdominal Cysts – Our Experience and Surgical Management
- P160 Ballistic Shock Wave Lithotripsy
- P161 Alternatives in Laparoscopic Approaches for Retroperitoneal Pathologies Presenting as an Adrenal Mass
- P162 Laparoscopic Pyeloplasty for Repair Of Ureteropelvic Junction Obstruction in Children
- P163 Endoscopic Treatment Of Moderate and High Grade Vesicoureteral Reflux in Children Using Dextranomer/ Hyaluronic Acid Injection
- P164 Laparoscopic Approach to Ovarian Mass in Children and Adolescents: Already a Standard in Therapy
- P165 Vesicoureteral Reflux Treatment of Neurogenic Bladder Children by Endoscopic Injection
- P166 Laparoscopic Managment of Non-Palpable Testes(Npt)
- P167 Endoscopic Treatment with Deflux for Refluxing Duplex Systems
- P168 Transperitoneal Mminimalinvasive Ureteroureterostomy for Duplex Kidney
- P169 Factors That Influence the Learning Curve in Retroperitoneal Laparoscopic Nephrectomy in Children
- P170 Our Transperitoneal Laparoscopic Dismembered Pyeloplasty Experience: The Importance of Reusable Laparoscopic Instruments
- P171 Laparoscopic Management of Nonpalpable Testes
- P172 Avagardtm In Pediatric Laparoendoscopic Surgery: Safe, Effective and Time Efficient
- P173 Passive Dilatation By Ureteral Stenting Prior to Ureteroscopy: Active Dilatation Eliminated
- P174 Safety and Efficacy of Retrograde Proximal Semirigid Ureteroscopy
- P175 Use of Kiss Catheter in Robotic-Assisted Laparoscopic Pyeloplasty In Children
- P176 Laparoscopic Procedures for Simple Renal Cysts in Children (79 Cases)

POSTER ABSTRACTS



P001 LAPAROSCOPIC DIAGNOSIS AND TREATMENT OF CONGENITAL DUODENAL OBSTRUCTION

Suolin LI BA, Zengwen YU, Zhendong LI, Department of Pediatric Surgery, 2nd Hospital of Hebei Medical University, Shijiazhuang, 050000, China.

OBJECTIVE: This clinical study was undertaken to evaluate the feasibility of a laparoscopic approach for the diagnosis and treatment of congenital duodenal obstruction.

METHODS: 22 children, aged 5 days to 16 years, were underwent laparoscopic surgery. The procedure was performed using 3 or 4 trocars of 3.5mm to 5.5mm diameter. The causes of duodenal obstruction were diagnosed and operated. A standard Ladd's procedure was performed in 15 cases with malrotation. 1 newborn and 2 infants with duodenal web encountered a partial excision of the diaphragm after ventral incision of the anterior part of duodenum followed by a transverse suture. 2 newborns with annular pancreas performed duodenal rhomb-anastomosis. 2 girls had superior mesenteric artery syndrome and underwent laparoscopic lysis of Treitz's ligament and Roux-en-Y duodenojejunostomy.

RESULTS: All procedures were completed successfully through the laparoscope. Of them, 1 case with Meckel's diverticulum, 1 case with jejunal ectopic pancreas and 2 case with paraduodenal hernia also had a concomitant procedure. Operative times ranged from 1 to 3.5 hours. Feedings were started on postoperative 1 to 3 days. Hospital stay ranged from 5 to 7 days. There were no complications.

CONCLUSIONS: Laparoscopy is a safe and excellent technique for the diagnosis and operative management of congenital duodenal obstruction. In addition, children are expected to benefit from the smaller incision, earlier feeding, shorter hospital stay, and fewer complications compared with traditional open procedures.

P002 PRIMARY LAPAROSCOPIC PULL-THROUGH IN HIRSCHSPRUNG'S DISEASE

Giovanna Riccipetitoni, Claudio Vella, Luciano Maestri, Giorgio Fava, Marco Gambino, Enrica Caponcelli, Department of Paediatric Surgery, Children's Hospital "V. Buzzi", Milan, Italy

INTRODUCTION: Laparoscopic-assisted endorectal pull-through (LAPT) could be considered the best choice for the treatment of Hirschsprung disease (HD). The aim of this study is to review our experience with this technique and perform a critical analysis of the outcome.

MATERIALS/METHODS: 40 HD patients were submitted to primary laparoscopic pull-through from January 2001 to December 2007. The age ranged between 20 days and 15 years; 22 patients were less than 6 months of age. The lowest patient's weight was 2.9 Kg. Each patient was investigated with rectal suction biopsy and barium enema. An ileal stoma was performed in 2 patients; a total colonic aganglionosis (TCA) and a long segment; the rest were managed with bowel nursing. All the operations were carried out by the same experienced surgeon requiring 3 operative ports. The colon was examined and several biopsies were taken at different levels to define the extension of the lesion. Surgery was postponed after the results of the intraoperative histochemical studies. The patients were definitively classified as: ultrashort (2 cases); rectosigmoid (29); long segment (7); TCA (1); NID type B (6). At the time of surgery the mesocolon was divided using Ligasure®, then the transanal dissection was completed, the videoassisted pull-through was carried out taking care of the pedicle placement and the seromuscular cuff. The operative time ranged from 160 and 240 minutes.

RESULTS: There were no conversions, no intraoperative or postoperative complications and no needs of blood transfusion. The patients had analgesia for 24 hours after the procedure. Bowel movements were observed at 24-48 hours, oral fluid intake was started after 48 hours, the median hospital stay was 7 days. The findings at follow-up were: 5 patients with grade I enterocolitis over the first months; 1 temporary anal stenosis because of omitted dilatation; the LS patients had about 4 toilets/day for 6 months.

CONCLUSION: we believe that laparoscopic pull-through is a safe operation for HD, even in patients with long segment and intestinal stoma; we had no conversions to open procedure in our series. The surgical and functional results are comparable to open surgery, moreover the recovery is significantly faster.

P003 LAPAROSCOPIC DUODENODUODENOSTOMY FOR DUODENAL ATRESIA IN NEONATES

Jeong-Meen Seo MD, Hea-Eun Kim MD, Suk-Koo Lee MD, Division of Pediatric Surgery, Department of Surgery, Sungkyunkwan University School of Medicine, Samsung Medical Center

BACKGROUND: Duodenal atresia is commonly corrected by laparotomy and duodenoduodenostomy. However, recently a few papers showed that the laparoscopic duodenoduodenostomy has been successfully done in neonates. We have experienced 4 patients (three neonates and one infant) of duodenal atresia corrected by laparoscopic procedure.

METHOD: All procedures were performed successfully with laparoscopy. One 5 mm 30 scope and three trocars for 3 mm instruments were used.

RESULTS: Ages at operation of 4 patients were 3 days, 3 days, 9 days and 2 months old. There were no intraoperative and postoperative complications. Feedings were started on postoperative day 6 in 2 patients and on day 9 in 2 patients. All 4 patients were on full feeding after 4 days and were discharged within postoperative day 14.

Comparison the Results of Open and Laparoscopy		
	Open	Laparoscopy
Number of pat	5	4
Feedin start	POD#9 day	POD#7.5 day
Full feeding	POD#4 day	POD#2.5 day
Hospital stay	16 days	13.5 days
Op time	85 min	224 min
POD#: postoperative day, Op: operation		

CONCLUSION: Laparoscopic duodenoduodenostomy for duodenal atresia in neonate is a safe and effective procedure.

P004 IS PROPHYLACTIC FUNDOPPLICATION NECESSARY IN NEUROLOGICALLY IMPAIRED CHILDREN?

Naveen Viswanath, Donny Wong, Askar Kukkady, Stuart Brown, Udaya Samarakkody, Department of Pediatric Surgery, Waikato Hospital, Hamilton-3206, New Zealand

AIM: To assess whether prophylactic fundoplication is necessary in children undergoing feeding gastrostomy

METHODS: During the period from 1996 to 2007, all the children who underwent gastrostomy with Fundoplication were compared with those in whom feeding gastrostomy alone was done. The clinical symptoms, investigations in relation to Gastro-esophageal Reflux and other motility disorders and the indications for gastrostomy were compared in the two groups. The complications directly related to the surgery in the two groups including subsequent need for fundoplication after gastrostomy were studied. Statistical analysis was done using Fishers exact test, taking p value of <0.05 as significant.

RESULTS: Prior to 1999, all the children who required a gastrostomy for feeding purpose underwent a prophylactic fundoplication. (n = 27). 23 out of 27 had neurologic abnormalities. From 1999, the Fundoplication was offered along with gastrostomy only if there was pH proven reflux disease. After 2001, only gastrostomy was done even if the pH was abnormal. A total of 141 children underwent gastrostomies for various indications out of which 60 underwent Fundoplication. Within this 60, 46 had undergone Fundoplication along with gastrostomy. There were 8 laparoscopic fundoplications. Of the 82 gastrostomies 65 were percutaneous endoscopic



POSTER ABSTRACTS

gastrostomies, 12 were laparoscopic and 5 were open procedures. The complication rate directly related to surgery was found to be higher in the gastrostomy with fundoplication group compared to the gastrostomy alone group (p value = 0.044). 14 / 82 neurologically impaired children with gastrostomy had to undergo subsequent fundoplication during follow up for severe gastro-oesophageal reflux.

CONCLUSION: Prophylactic Fundoplication is not essential in neurologically impaired children undergoing gastrostomy for feeding purposes. The authors recommend only gastrostomy for feeding purposes in neurologically impaired children and Fundoplication should be offered selectively to those children with clear surgical indications related to Gastro-oesophageal Reflux Disease.

P005 LAPAROSCOPIC SURGERY FOR LIVER HYDATID CYSTS IN CHILDREN

Mustafa Kucukaydin MD, Mahmut Guzel MD, Ahmet N. Ciftler MD, Mehmet Uysal MD, Serkan Arslan MD, Ahmet B. Dogan MD, Mustafa E. Dorterler MD, Ali Aslan MD, Kadri C. Sulubulut MD, Erciyes University School of Medicine, Department of Pediatric Surgery

BACKGROUND/AIM: Hydatid disease due to *Echinococcus granulosus* remains an important and challenging medical problem. Surgery is considered as an important option in the treatment of hydatid disease; however controversies still exist on the preferred operative technique. The purpose of this study is to define the efficacy of the laparoscopic management for liver hydatid cysts in children.

METHODS: Between April 2000 and August 2007, ten patients with liver hydatid cysts (six boys, four girls) were treated by laparoscopic procedure. The average age were 11 years ranging between six to 16. In three hydatid cysts, perforator-grinder aspirator was used. In seven patients, the cyst fluids were aspirated with a needle and then 20% saline solution injected in to the cyst cavity, and waited for 15 minutes. Following the aspiration, the cysts were excised partially and germinative membranes were taken out through the trocar in an endobag.

RESULTS: The average duration of postoperative hospitalization was 12 days (range 3-30 days). In these patients, there were three cysto-biliary fistulas. One of the fistulas was treated with hepatic segmentectomy by second laparoscopic procedure at 20th postoperative day. Other two fistulas healed spontaneously. The median follow-up period was 15 months (range five months to seven years). USG revealed that the cysts have disappeared between two and six months, leaving relatively small echogenic appearances at their original locations.

CONCLUSION: Although the number of patients in this series was small, our experience with laparoscopic procedures indicates that the same operation can be performed using this approach and the similar results can be achieved as with laparotomy with excellent cosmesis and potentially less morbidity.

P006 INSUFFICIENCY OF LAPAROSCOPIC GASTROPEXY FOR TREATMENT OF GASTRIC VOLVULUS ASSOCIATED WITH DILATATION OF TRANSVERSE COLON: A CASE REPORT

Jung-Tak Oh MD, Min Soo Cho MD, Yoon Joon Park MD, Seok Joo Han, Department of Pediatric Surgery, Severance Children's Hospital, Yonsei University College of Medicine

Gastric volvulus in children is a rare condition and most cases of this disease need surgical treatment. Laparoscopic gastropexy is known as a safe and effective treatment method for gastric volvulus. However, laparoscopic gastropexy alone sometimes result in unsatisfactory outcome. We report a case of insufficiency of laparoscopic gastropexy for treatment of gastric volvulus associated with dilatation of transverse colon.

A 2-year 2-month-old girl was admitted our hospital with intermittent abdominal distension. She was born at 36 weeks' gestation with birth weight of 3.3 kg. When she was 1-year 6-month old, she underwent

rectal full thickness biopsy for rule out Hirschsprung's disease because she had symptoms of abdominal distension and constipation. On admission, physical examination revealed a distended abdomen, and abdominal radiography showed marked distension of the stomach and colon. Barium enema showed a redundant and distended transverse colon, and upper gastrointestinal study showed mesenteroaxial gastric volvulus. A diagnosis of gastric volvulus was made and laparoscopic anterior gastropexy was performed by using one 10-mm camera port and two 5-mm working ports. Postoperatively, despite of normal position of stomach, the patient's symptoms were not completely disappeared and markedly distended transverse colon was still observed in Barium enema study. She underwent second operation on 1 month of postoperative day by laparotomy and distended transverse colon was resected. After second operation, the patient had an uneventful recovery, and her symptoms improved rapidly. There had been no recurrence of symptoms for follow-up period.

P007 LAPAROSCOPIC TREATMENT OF HIATAL HERNIA IN PATIENTS WITH GASTROESOPHAGEAL REFLUX DISEASE

Fernando Montes-Tapia MD, Ulises Garza-Luna MD, Guillermo Martínez-Flores MD, Idalia Cura-Esquivel PhD, Mario Menchaca-Menares MD, Maricela Zárate-Gómez MD, Valdemar Abrego-Moya PhD, Gerardo Muñoz-Maldonado MD, University Hospital "Dr. José E. González", Autonomus University of Nuevo León-México

INTRODUCTION: The presence of hiatal hernia in children is associated with prolonged exposure of the esophagus to acid and to a high rate of failure of medical treatment. The most frequent type is type I or sliding hiatal hernia in 90%, type II or paraesophageal hernia is the second most frequent, type III is a combination of type I and II.

MATERIALS/METHODS: In a period of 5 years 100 patients with gastroesophageal reflux disease have been operated on, of which 13 had a diagnosis of hiatal hernia (13%): type I:12 patients (92%), type II:1 patient. 6 Females and 7 males. The average age was 62 months (2-192) and weight 13 kg (3.5-22). The main symptoms were gastrointestinal in 8 patients (60%), pulmonary and gastrointestinal in 4 (31%) and only pulmonary in 1 (8%). Diagnosis was made by esophagealgastroduodenal x ray and/or endoscopy. There were associated pathologies in 6 patients (46%): neurological deficit in 4, post surgical esophageal atresia and congenital stenosis in 1, peptic esophageal stenosis in 1. All were corrected by laparoscopy using a 4 or 5 port technique: 3mm in patients less than 6 months and 5mm in older patients, 30° optics in all cases. A non-absorbable polyester suture was used (Ethibond) 4-0 or 3-0, according to the age of the patient. Posterior hiatal plasty in 12 patients with 1 to 3 sutures and the patient with the paraesophageal hernia required besides the posterior hiatal plasty an anterior suture. There were additional procedures in 5 patients (38%): 2 gastrostomies, 2 gastrostomies with pyloroplasty and 1 pyloroplasty. The average surgical time was 147 min. (70-200). Oral intake was started the same day in 2 patients, with gastrostomy on the 3rd day and with pyloroplasty on the 6th day postoperatively. There were no conversions. Immediate postoperative complications were leakage from the gastrostomy in one patient (7%). The average hospital stay was 5 days (3-13). Follow-up was 13 to 36 months, with a relapse (7%) in one patient with peptic esophageal stenosis and an acquired short esophagus.

CONCLUSIONS: Laparoscopic treatment for our patients with hiatal hernia and gastroesophageal reflux disease was effective and safe in the physiological restoration of the hiatus and control of gastroesophageal reflux. The patients with peptic esophageal stenosis require a wider mediastinal dissection to descend the acquired short esophagus and avoid relapses.

POSTER ABSTRACTS



P008 FUNDUPLASTY TYPE NISSEN EN PEDIATRIC, LAPAROSCOPY VS OPEN

Julian Alberto Saldaña Cortes MSC, Jorge Alberto Mujica Guevara MD, Antonio H. Chavez Aguilar MD, Instituto Mexicano Del Seguro Social, Umae Pediatric Hospital, Guadalajara-Jalisco

INTRODUCTION: Indications for antireflux surgery include GERD primary or coexisting with other states of comorbidity that are refractory to medical management. The technique described by Nissen and Rosetti in 1959 is the most widely surgical procedure. This is a safe procedure in hands experts both in technique as laparoscopy open.

GOAL: To demonstrate that the technique for laparoscopic Nissen funduplasty type works best for the open technique in pediatric patients.

MATERIALS/METHODS: A retrospective cohort March 2004 to February 2007. Were reviewed records and radiologic studies (SEGD) in pediatric patients, operated by funduplasty type Nissen open and laparoscopic technique, forming two groups of patients. We collected the following variables: age, gender, level of GERD (SEGD, pH and endoscopy with biopsy), neurological damage, response to medical treatment, surgical time according to the type of surgery, complications, time of onset of mouth, days of hospitalization and outpatient tracking.

RESULTS: In group laparoscopic Nissen are: 35 patients, 25 men and 10 women, with an average age of 8 years old, average operative time of 90 minutes without gastrostomy (7 patients), gastrostomy 120 minutes (28 patients). One complication in this group, the average time from onset of mouth in both groups was 24 hours; hospital stay for patients without gastrostomy was 2 days and with gastrostomy was 3 days. The group Nissen open are: 30 patients, 20 men and 10 women with an average age of 5 years, average operative time was without gastrostomy 70 minutes (7 patients), gastrostomy was 90 minutes (23 patients), the average time from onset of initiation of mouth was 5 days, and 4 days without gastrostomy, the average hospital stay for patients without gastrostomy was 7 days and gastrostomy was 8 days. No patient has so far required by reoperation recurrence in both groups with a mean follow-up of 24 months.

DISCUSSION: The learning curve teaching improved over time in laparoscopic surgery, reducing surgery time, comparing both study groups found less post-surgical recovery time, less time for the start of oral and fewer days hospitalization in the laparoscopic group vs. Open. ($P < 0.005$) as mentioned in literature, the technical by funduplasty laparoscopic surgery is the kind of gold standard, we expect improvement surgery time and increase the number of patients who underwent laparoscopic.

CONCLUSIONS: Laparoscopic technique is safe and provides an early recovery, and better results postsurgical, however, requires long-term monitoring to identify late complications and the need for reoperation by relapse.

P009 THORACOSCOPIC SURGERY OF FISTULA LIGATION AND ONE-STAGE ESOPHAGEAL ANASTOMOSIS FOR CONGENITAL ESOPHAGEAL ATRESIA

Wu Yeming MD, Shanghai Children's Medical Center, Shanghai Jiaotong University, China

PURPOSE: To introduce the development of the thoracoscopic surgery of one-stage esophageal anastomosis for neonatal esophageal atresia on Chinese mainland through a couple of successful cases in Shanghai Children's Medical Center (SCMC).

METHOD: Thoracoscopic surgeries of fistula ligation and one-stage esophageal anastomosis were performed on a couple of infants with congenital esophageal atresia successfully in SCMC in 2007. The two male infants, both of whom belonged to ϕ 6B type, weighted 2.9kg and 2.4kg, and were 4 days and 8 weeks old respectively. One baby also had severe inhalation pneumonia, so the operation was performed after the pneumonia was cured.

RESULT: We did two thoracoscopic operations successfully. One baby developed stomal leak on the third day after operation. But it was healed

one week later with conservative management. On the 11th day he could drink without anastomotic stenosis, and was discharged on the 15th day. The other baby was discharged 10 days after surgery. One month later, he was found to have anastomotic stenosis and was relieved after twice balloon dilations. Both of them grow well during the 6 and 9 months follow-up. After reviewing the Chinese medical literature, we find that there is only 1 article reporting 3 successful esophageal anastomosis surgeries under thoracoscope for congenital esophageal atresia.

CONCLUSION: On Chinese mainland, the initiation of children's thoracoscopic and laparoscopic surgery was quite late, but it advanced rapidly in recent years. There is some successful experience in the thoracoscopic surgery of one-stage esophageal anastomosis for neonatal esophageal atresia, and the effect is good.

P010 THREE TROCAR APPROACH FOR LAPAROSCOPIC NISSEN FUNDOPLICATION

Gulnur Gollu MD, Berkutug Bahadir MD, Aydin Yagmurlu MD, Department of Pediatric Surgery, Ankara University Faculty of Medicine

BACKGROUND: Laparoscopic Nissen fundoplication is becoming the preferred surgical approach in children with gastroesophageal reflux disease (GERD). With this study it was aimed to evaluate the results of three trocar approach for laparoscopic Nissen fundoplication in infants and children.

PATIENTS/METHODS: After insertion of an umbilical 4.5mm camera trocar, two working ports either 3 or 5mm were introduced, liver retraction was performed using a Cook retractor or a 3 to 5 mm port. No other trocars were placed in order to retract the stomach. Demographic data, indication of fundoplication, operative time, hospital stay, early and late complications were investigated.

RESULTS: Laparoscopic fundoplication was performed in 25 children with no conversion to open. Concomitant trocar site ($n=1$) and U-Stitch gastrostomy ($n=9$) were performed in ten children due to feeding disorders. There were no intraoperative complications. Mean operative time was 70 minutes. The mean oral or enteral feeding time was one day (0-3 days). The mean follow up period was eight months ranged from one to 23 months.

CONCLUSION: Using just two working ports and with no stomach retraction it is feasible to perform laparoscopic Nissen fundoplication in similar times with the traditional technique. No need for extra person for retraction made this technique useful in busy surgical centers with no increase in operative time and complications.

P011 LAPAROSCOPIC LIVER BIOPSY IN CHILDREN WITH HEPATIC COAGULOPATHY

Esra Temeltas MD, Ufuk Ates MD, Gulnur Gollu MD, Berkutug Bahadir MD, Aydin Yagmurlu MD, Department of Paediatric Surgery, Ankara University Faculty of Medicine

BACKGROUND: Liver biopsies are routine procedures for diagnosing liver pathology. There can be significant morbidity and mortality for children with uncorrectable coagulopathy during these procedures. Minimally invasive surgical techniques may favorably impact on the work-up of liver diseases in such cases.

PATIENTS/METHODS: A chart review was performed in children who underwent laparoscopic liver biopsy. Demographic data, indication of biopsy, length of hospital stay, early and late complications were investigated.

RESULTS: Six children had laparoscopic liver biopsy in eighteen months period. Median age was five years (20 days to 14 years). Indications of biopsies were searching the etiology of the chronic liver disease. After taking the biopsy specimens via laparoscopy, fibrin glue was used for hemostasis in three patients. Electric cautery was found to be adequate in the other three children for bleeding control. Sufficient tissue was obtained in all patients. The histopathological examination revealed;



POSTER ABSTRACTS

biliary cirrhosis (n=3), Alagille syndrome (n=1), biliary atresia (n=1), and glycogen storage disease (n=1). Mean length of hospital stay was one day. All children had experienced minimal postoperative discomfort and returned to normal activity on early postoperative period.

CONCLUSIONS: Laparoscopic liver biopsy is a safe, reliable and minimally invasive technique in cases where fine needle aspiration was avoided due to coagulopathy. The advantages of this particular procedure are 100% success rates in obtaining adequate tissue for histopathological evaluation, and early re-recovery to normal physical activity and good cosmetic outcomes.

P012 LAPAROSCOPIC REPAIR OF DELAYED CONGENITAL DIAPHRAGMATIC HERNIA IN THE POST-NEONATAL PERIOD

Mario Mendoza-Sagaon MD, Olivier Reinberg MD, Flurim Hamitaga MD, Rudolph Leuthardt MD, Department of Pediatric Surgery, Centre Hospitalier Universitaire Vaudois and Ospedale Regionale di Bellinzona e Valli, Switzerland.

INTRODUCTION: Congenital diaphragmatic hernias (CDH) diagnosed after the neonatal period are uncommon and usually associated with a better prognosis. Moreover, minimal invasive surgery have shown to be useful in their correction in children.

METHODS: The files of all children with the diagnosis of CDH established after the neonatal period and operated laparoscopically in two Swiss pediatric surgical institutions were analyzed.

RESULTS: Five patients, 2 with a right-side and 3 with a left-side CDH were included in the study. Age range was between 2 months and 3 years-old. All were operated through a laparoscopic approach. 4 patients have had a laparoscopic primary closure of the diaphragmatic defect. One conversion due to technical difficulties and a large diaphragmatic defect that required a Gore-tex patch was performed. Follow-up range was from 9 months to 7 years. To date all patients are doing well. No recurrences were observed and no re-intervention became necessary.

CONCLUSION: A laparoscopic surgical approach to treat children with a congenital diaphragmatic hernia diagnosed after the neonatal period is a safe and feasible option.

P013 COMPLICATIONS OF LAPAROSCOPIC PYLOROMYOTOMY: DOES SIZE MAKE A DIFFERENCE?

Claudia M. Mueller MD, Sathyaprasad Burjonrappa MD, Chad Wiesenauer MD, Zainab Al Balushi MD, Sarah Bouchard MD, Ste-Justine Hospital, University of Montreal

BACKGROUND: Pyloric stenosis is one of the most common surgical conditions encountered in infants. Diagnosis of pyloric stenosis, once resulting from the palpation of an abdominal "olive," is now most commonly made by ultrasound measurement of the length and width of the pyloric muscle. Minimally invasive pyloromyotomy has gained increasing acceptance as a surgical cure for pyloric stenosis. We consider whether an increase in size of the pylorus increases the difficulty and thereby increases the risk for conversion during laparoscopic pyloromyotomy.

METHODS: The charts of 252 patients who underwent pyloromyotomy from January, 2002 to March, 2005 were retrospectively reviewed. Pyloric length and width were measured in millimeters during ultrasonography of the abdomen performed by attending radiologists.

RESULTS: 107 patients underwent laparoscopic pyloromyotomy; the remaining 145 surgeries were performed open. Six of the laparoscopic procedures were converted to open during the course of the surgery. All conversions were performed because of perforation. In addition, two other patients underwent repeat surgery after an incomplete laparoscopic pyloromyotomy. No significant differences in pylorus size, as measured by length and thickness, were noted between the laparoscopic and conversion groups. In addition, there was no difference in pylorus size between patients who underwent a laparoscopic versus an open surgery.

CONCLUSIONS: We demonstrate that an increased pyloric size did not increase the rate of conversion from laparoscopic to open pyloromyotomy. In addition, it did not increase the likelihood of incomplete pyloromyotomy. Thus, we consider laparoscopic pyloromyotomy to be a safe, effective approach to the cure of pyloric stenosis of all sizes.

P014 CLINICAL USAGE OF LAPAROSCOPICALLY ASSISTED SUBTOTAL COLON RESECTION IN CHILDREN

Suolin LI BA, Yingchao LI, Zhichao WANG, Department of Pediatric Surgery, 2nd Hospital of Hebei Medical University, Shijiazhuang, 050000, China

OBJECTIVE: The aim of this study was to evaluate the clinical effect of laparoscopically assisted subtotal colectomy and transanal endorectal pull-through for Hirschsprung's disease (HD) and allied disease (HAD).

METHODS: From 2002 to 2007, 13 infants and children with HD or HAD were encountered with laparoscopic-assisted subtotal colon resection and ascending colon reversion (Deloyers' maneuver) for the pull-through. The age ranged from 4 months to 7 years. Of them was long-segmental HD in 6 cases, serious common type in 4 cases and HAD in 3 cases. The procedure was performed using three trocars of 5.5mm diameter. The trocars were placed on the superior margin of the umbilicus, left and right midabdomen respectively. The total colonic mesentery was dissected and the ileocecum was mobilized laparoscopically with ultrasonic shear by exchanging camera port and main working port. A modified Swenson's anastomosis was performed.

RESULTS: All cases obtained successful laparoscopic operations. The average time of procedure was 114 minutes. The length of ascend colon preserved was 12.3 cm. The mean period for discharge after surgery was 6.5 days. There were no perioperative complications. The fragmentary defecation was 5-20 times per day in postoperative 1 months and decreased gradually up to 3-5 times after 6 months. The incontinence and constipation were not appeared following up 6 months to 4 years.

CONCLUSIONS: Laparoscopic-assisted subtotal colectomy and transanal endorectal pull-through is a safe and effective technique for HD and HAD, which is highly superior than classical laparotomy in minimally invasive surgery features and should be advocated actively.

P015 TRENDS IN PYLOROMYOTOMY AT A PEDIATRIC TEACHING INSTITUTION

Lena Perger MD, Julie Fuchs MD, David Mooney MD, Children's Hospital Boston

PURPOSE: The purpose of this study is to compare the laparoscopic, umbilical and right upper quadrant approaches to pyloromyotomy and to reveal trends in operative approach over time at a single teaching institution.

METHODS: Study protocol was approved by Institutional Review Board. Chart review was performed on all isolated pyloromyotomies performed between January 1999 and December 2006. Perioperative care was by protocol for all patients and operative approach was determined by the on-call surgeon. Age, gender, weight, operative time, number of post-operative emeses, length of hospitalization and complications were noted for the three approaches: right upper quadrant (RUQ), umbilical (UMB) and laparoscopic (LAP). Operative times and lengths of hospitalization were compared using ANOVA and post-hoc analysis with Bonferroni adjustment for multiple comparisons. Post-operative emesis was analyzed with Mann-Whitney test.

RESULTS: 622 pyloromyotomies were performed: 243 RUQ, 246 UMB, and 133 LAP. Patient age, weight and gender did not differ significantly between groups. Mean operative times for LAP and RUQ groups were significantly shorter than UMB ($p < 0.01$). OR equipment costs were \$90 more for LAP. Post-operative stay did not differ significantly between groups. Number of post-operative emeses was significantly lower in LAP compared to UMB and RUQ ($p 0.02$ and 0.002 respectively). The incidence

POSTER ABSTRACTS



of wound infection was 3.3% (UMB), 1.2% (RUQ) and 0.8% (LAP). Four fascial dehiscences, two perforations, one incomplete pyloromyotomy and one incisional hernia occurred in UMB group. One incisional hernia occurred in RUQ group. Two perforations and four conversions to open occurred in LAP group. Laparoscopic pyloromyotomy was performed in 82% of patients in last six months of 2006 as compared to 2% of patients in first half of year 2002.

CONCLUSIONS: The UMB approach is associated with longer operative time than LAP and RUQ approaches. Number of post-operative emeses is lower in LAP than in UMB and RUQ. Umbilical approach is associated with trend toward higher complication rate. LAP is increasing in popularity and is supplanting both UMB and RUQ.

P016 GASLESS, BLADELESS ACCESS

Noemi Lerch MD, Christopher A. Gitzelmann MD, University Children's Hospital Zurich

BACKGROUND: Several access techniques are available for laparoscopic surgery. We demonstrate the safety and efficacy of the primary optical-access trocar in the non-insufflated pediatric abdomen. In addition, the technique used is elucidated.

METHODS: We retrospectively reviewed 531 laparoscopic cases in patients aged 3 months to 16 years of age. In 487 cases primary trocar placement was attempted using an optical-access trocar (Optiview/XCEL), Ethicon Endosurgery) with a zero degree laparoscope without prior insufflation.

RESULTS: There were no cases of inadvertent visceral or vascular injuries. In 480 cases quick and safe access was established. In 3 cases conversion to open trocar placement was necessary due to inadequate visualization. In 4 cases inadvertent preperitoneal insufflation was achieved which was easily corrected using the same technique following recognition of the problem.

CONCLUSIONS: The use of optical-access trocars in pediatric patients is a feasible, safe and rapid method for initial trocar placement in the non-insufflated abdominal cavity. To our knowledge this is the only study to show successful and safe use of this method.

P017 LAPAROSCOPIC GASTROPEXY FOR THE TREATMENT OF GASTRIC VOLVULUS ASSOCIATED WITH WANDERING SPLEEN

Caroline Francois-Fiquet MD, M. Belouadah MD, P. Chauvet MD, F. Lefebvre MD, G. Lefort MD, Ml Poli-Merol MD, American Hospital Reims (Pediatric Surgery, Pr Lefort) France

Gastric volvulus associated with wandering spleen is a rare entity resulting from a congenital absence or malformation of normal splenic suspensory ligaments. We report a case and discuss different managements already evoked in the literature.

CASE REPORT: A 2.5 years old boy was referred for brutal onset of diffuse abdominal and increasing pain, with lethargy, abdominal distension, and vomiting during less than 24 hours. It was the third episode over a 6-month period. Before this last one, symptoms resolved with gastric decompression and decubitus. Radiographic findings (sono, TDM) were negatives immediately after the two first crises. During the third admission, a plain abdominal X-ray showed gastric distension. Two litres of stasis were evacuated by suction. The ultrasound scan showed an unusual spleen position in left lower quadrant, without splenic ischemia. The diagnosis of gastric volvulus associated with wandering spleen was then evoked.

An open laparoscopic exploration of the abdominal cavity was then decided. Laparoscopic exploration revealed a non-ischemic spleen, absence of normal splenic suspensory ligaments, and gastric distension with flaccid gastric wall. Four additional working ports (5mm) were placed. The spleen could be cosily moved from its left iliac fossa situation to its normal sub diaphragmatic location. A parietal peritoneal postero-lateral incision was

made, opposite to the large gastric curve, up to the diaphragm (7 cm). This delimited a sharp zone between two edges of incised peritoneum. The anterior part of the lateral border of the stomach was fixed to the anterior edge of the peritoneal incision, and the posterior part to the posterior edge, the stomach covering and maintaining the spleen in good position. Recovery was uneventful and ultrasound realised after 4 years shows viable spleen in good place.

Scarcity of the gastric volvulus on wandering spleen and its fast clinical improvement with medical treatment often delays the diagnosis and the surgical treatment. Laparoscopy takes here all its interest: diagnosis and therapeutic (splenectomy, or gastropexy).

Laparoscopic gastropexy for the treatment of gastric volvulus associated with wandering spleen is an easy technique, and seems to combine advantages of all the techniques previously described.

P018 LAPAROSCOPIC APPENDECTOMY IN CHILDREN - ALTERNATIVE OF CHOICE

Kastriot N. Haxhirexha BA, Hysen N. Heta BA, Ferizat E. Dika BA, General Hospital, Tetove. R. Macedonia, University Hospital Center "Mother Teresa", Tirana

BACKGROUND/PURPOSE: The laparoscopic treatment of pediatric appendicitis remains controversial, because the advantages of laparoscopic appendectomy over the open appendectomies have not yet been clearly demonstrated. The intention of this study is to present our early experience with laparoscopic appendectomy in children.

METHODS: We reviewed our records for 23 children in which is performed laparoscopic appendectomy in a period between June 2004 and June 2007. We were evaluated this cases for age, sex, weight, type and length of intervention.

RESULTS: A total of 23 patients were operated on by laparoscopy in our department, and there were only one conversions (LA → OA). The middle age of LA patients in this study were 11.5 years, and more frequently occurred in girls (57.1% v 38.2%). LA took a little longer to perform than open appendectomy (approximately 50.5 v 45.5 minutes). The length of hospital stay varied between 2 and 4 days. In one patients is developed herniae umbilicalis and in one other patient trocar site infection. The histopathologic report was negative in only three patients (13%).

CONCLUSIONS: Laparoscopic appendectomy is a safe and effective procedure which does not increase the incidence of complications. The length of intervention is a little more longer than OA, but the length of hospitalization is shorter. Incidence of postoperative complications are equivalent to those of open appendectomy.

P019 SIMPLE MARKER FOR INTRA-OPERATIVE DETECTION OF GASTRO-DUODENAL PERFORATIONS DURING PYLOROMYOTOMY

Ravindra K. Vegunta MD, Arthur L. Rawlings MD, Paul M. Jeziorczak BS, University of Illinois College of Medicine at Peoria, Peoria, IL

BACKGROUND: Intragastric methylene blue dye is a potential marker for detection of mucosal perforation during laparoscopic pyloromyotomy. Methylene blue dye is inexpensive and has few reported serious reactions.

MATERIALS/METHODS: In-vitro model: Standardized perforations were made in fresh porcine stomachs using drill bits 0.8, 1.2, 1.6, 2.0, and 2.4 mm in diameter. One percent methylene blue was diluted and used as marker. Four tests were performed: 1) full thickness perforation; 2) mucosal perforation within a myotomy incision, no dye instilled prior to perforation; 3) mucosal perforation within a myotomy incision, dye instilled prior to perforation; 4) mucosal perforation within a myotomy incision, dye instilled in the stomach and removed prior to perforation. Perforations were monitored for the extravasation of dye for five minutes.

IN-VIVO MODEL: Laparoscopic myotomies were performed in the stomach and duodenum of anesthetized piglets (5-6 kg) with carbon dioxide pneumoperitoneum at 15 mm of Hg. Dilute and full strength 1%



POSTER ABSTRACTS

methylene blue was instilled into the stomach in turn. An oro-gastric tube was used to instill 35 ml of the dye in the stomach for two minutes and then most of the dye was suctioned out. Mucosal perforations were created within a myotomy incision. Perforations were made using standard size drill bits as described above. Perforations were monitored for two minutes for dye extravasation. The stomach was then distended with air to look for improvement in the detection of the perforations.

RESULTS: Methylene blue stained the mucosa blue and was seen through the myotomy. Dye extravasation was seen with mucosal perforations of 1.6 mm and greater in the absence of stomach insufflation and 1.2 mm or greater with insufflation. Air extravasation was seen with perforations of 2.0 mm and greater.

CONCLUSION: Full strength 1% methylene blue dye instilled into the gastric lumen can be used as a marker for detection of mucosal perforation. Despite the presence of pneumoperitoneum there was adequate extravasation of the dye. Diluted dye was not effective. Small volume (7 ml/kg) of the dye placed in the stomach and then aspirated to minimize aspiration risk was enough to stain the mucosa adequately. This required no additional instrumentation as the blue color was visible using standard laparoscopic equipment.

P020 LAPAROSCOPY FOR RECURRENT ABDOMINAL PAIN IN CHILDREN

Antonio Marte MD, Maria Domenica Sabatino MD, Micaela Borrelli MD, Biagio Del Balzo MD, Fabiano Nino MD, Maurizio Prezioso MD, Pio Parmeggiani PhD, Paediatric Surgery of Second University of Naples

PURPOSE: The use of laparoscopy to treat chronic recurrent abdominal pain (RAP) in children is still controversial. We reviewed our experience with laparoscopic treatment of RAP.

METHODS: The study sample comprised 33 out of the 80 patients referred to our institution for chronic RAP. Of these 20 were females and 13 males; their ages ranged from 7 to 17 years (mean 11.2). Nine patients had undergone previous abdominal surgery (inguinal herniotomy, appendectomy, ovarian cystectomy). The duration of the symptoms ranged from 1 to 6 years. Patients were excluded if an identified source of pain was discovered during preoperative workup. All patients underwent a typical three trocar laparoscopy: an open umbilical access and two 5 mm lateral operative trocars. The appendix was excised in all cases in whom it was present independently of its aspect. Each patient's outcome was classified into one of three categories, complete resolution, partial resolution of the pain, no response.

RESULTS: Twenty-one out of 33 patients presented the following findings: There were adhesions involving the ascending colon in 11 patients, omental adhesions in 2, sigmoid adhesions in 2; 5 patients had chronic appendicitis and 1 an appendicular MALT-Lymphoma; At a mean follow-up of 18 months 14 patients showed complete resolution of pain, 5 partial resolution and 2 no response; Of the 12 patients without adhesions, 5 achieved complete resolution of pain, 1 partial resolution, and 6 no response.

CONCLUSION: In our experience, laparoscopy seems to have an important role in the treatment of RAP in children. Adhesiolysis and appendectomy proved to be beneficial in most of our patients. No factor was identified that could help predict the outcome.

P021 OUTCOME OF LAPAROSCOPIC HELLER'S OESOPHAGOMYOTOMY TO TREAT ACHALASIA IN 12 CHILDREN

Michael Stanton, Faiz Shariff, Edward Kiely, David Drake, Agostino Pierrro, Joe Curry, Great Ormond Street Hospital, London, UK

INTRODUCTION: Achalasia is rare in children and controversy remains as to what is the optimal treatment. Previous reports of surgical treatment usually describe oesophagomyotomy with anterior fundoplication. We aimed to review our experience with laparoscopic Heller's myotomy without fundoplication to treat achalasia.

METHODS: Retrospective review of all laparoscopic Heller's procedures at single centre (1999-2007).

RESULTS (MEDIAN, RANGE): Twelve children age 14.0 years (7.6-17.6 years) who had been symptomatic for 15.3 months (3.5 months-7.9 years) were operated on. Pre-operative symptoms were dysphagia (100%), vomiting (92%), weight loss (58%) and odynophagia (25%). Achalasia was confirmed by oesophagogram in 100%, by manometry in 75% and by endoscopy in 33%. Prior to referral, balloon dilatation had been performed in 50%. All patients underwent Heller's myotomy without fundoplication. Operative time was 65 minutes (35-165 minutes). Opiate analgesia was required for 24 hours (9-52 hours), naso-gastric tube was used in 8 patients. Time to first oral intake was 22 hours (6-30 hours), time to full diet was 36 hours (18-96 hours) and length of stay was 49 hours (42-101 hours). There were no intra-operative or post-operative complications. Patients were followed up for 10.1 months (0.8 - 51 months) and time since surgery was 2.6 years (0.5 - 8.6 months). Symptom resolution occurred in 7/12 (58%). Symptoms continued in 5 patients (42%), these were dysphagia (33%), vomiting (33%), weight loss (8%). In one patient (8%), vomiting occurred post-operatively, but not prior to surgery. Post-operative balloon dilatation was carried out in 2 patients (17%). Re-do myotomy with fundoplication was undertaken in 2 patients again without symptom resolution. Re-do surgery is being considered in 2 more.

CONCLUSIONS: Laparoscopic Heller's myotomy can be performed safely in children with short hospital stay and low morbidity. Symptom resolution occurred rapidly in half of the patients. Reflux does not appear to be induced by myotomy alone in the majority (>90%). However, dysphagia is not eliminated in a significant proportion (despite re-do myotomy with fundoplication) and is likely to be related to underlying dysmotility.

P022 ROUTINE PREOPERATIVE ERCP IS UNNECESSARY IN CHILDREN WITH CHOLEDOCHOLITHIASIS

Wojciech J. Gorecki PhD, Mirosław M. Krysta PhD, Adam Bysiek PhD, Piotr K. Wojciechowski PhD, Joanna Palka MD, Department of Pediatric Surgery, University Children's Hospital

AIM: To confirm the safety of laparoscopic cholecystectomy (LC) without preoperative ERCP in children with choledocholithiasis.

METHOD: A retrospective review of 90 patients 72 girls and 18 boys (age 4-24 years, mean 14) who underwent LC between 1998 and 2007, for symptomatic gallstones under an institutional policy of avoiding routine preoperative ERCP, even when choledocholithiasis was suspected. Fourteen children underwent intraoperative cholangiography.

RESULTS: Thirty children (33%) had preoperative evidence of choledocholithiasis. All except 2 (with pancreatitis) were treated conservatively and then scheduled for a delayed LC. At the time of operation, 14 children still had clinical suspicion of possible common duct bile stones and therefore underwent intraoperative cholangiography. Of these, 9 were negative and 5 had a stone impacted in the common bile duct. The children with impacted stones required conversion (1), had the stones flushed out (2), or were scheduled to postoperative ERCP/papilotomy because of ineffective antegrade stones removal (2). ERCP/Papilotomy was performed within 24 and 48 hours. At the time of the procedure no stone had been found. The children meanwhile were free of symptoms of cholestasis with mild serum amylase elevation. Significant common duct stones were missed in 1 girl without clinical evidence of cholelithiasis, thus not subjected to cholangiography, leading to postoperative cystic stump leakage. The girl required relaparoscopy, drainage and ERCP/papilotomy. All patients remained asymptomatic and well at 30-day follow-up.

CONCLUSIONS: Cholelithiasis is common in children with symptomatic biliary stone disease, but more than 90% of these stones pass spontaneously. Routine preoperative ERCP is therefore unnecessary. This selective approach limits the use of ERCP and sphincterotomy to less than 10% of children with choledocholithiasis, who may need it postoperatively. Intraoperative cholangiography is an important adjunct in children in whom common duct stones are clinically suspected.

POSTER ABSTRACTS



P023 LAPAROSCOPIC HEPATOJEJUNOSTOMY FOR TYPE ⅰ OR ⅱ BILIARY ATRESIA

Shu-li Liu PhD, Long Li MD, Wen-Ying Hou MD, Liu-Ming Huang MD, Department of Pediatric Surgery, Peking University First Hospital

INTRODUCTION: Type ϕ_i and type $\phi\phi$ characterized with well-developed intrahepatic bile duct are minority in BA. For these patients, satisfactory bile flow and hepatic function may be recovered by applying biliary tract reconstruction. The conventional open procedure results in great injury to patients. These sick children suffering serious hepatic lesion caused by cholestasis was weakened in affording operative stress. The patient's conditions require a minimal invasive procedure. This study aimed to explore the feasibility and safety of laparoscopic Roux-en-Y hepatojejunostomy for curable biliary atresia (BA).

METHODS: The group enrolled 10 children suffering BA of type ϕ_i or $\phi\phi$ with symptoms of aggravating jaundice, white stools, and abnormal high level of AST and ALT, with 6 female cases and 4 male cases. Their ages ranged from 23 days to 160 days (with an average of 53 days). Six cases were type ϕ_i , while 4 were type $\phi\phi$. All cases characterized with cystiform dilated dead end of extrahepatic biliary tract. The average diameter of dilated dead end was 1.5 cm (range, from 1.0 to 1.8 cm). The 10 children underwent laparoscopic partial dilated dead end excision with Roux-en-Y hepatojejunostomy. Four trocars were utilized with 3 to 5 mm instrumentation. Under laparoscopic guidance intraoperative cholangiography was performed, and then the gallbladder was excised, followed by the partial resection of dilated dead end. The Roux-en-Y jejunal loop was fashioned extracorporeally by exteriorizing the jejunum through the umbilical incision (1.0-1.5 cm) and passed up retrocolically followed by an end-to-side hepaticojunctionostomy. All cases were followed up for a mean period of 26 months (ranging from 4 to 51 months).

RESULTS: Average duration of operation was 3.0 hours (ranging from 2.4 to 3.2 hours) without intraoperative problems. Intraoperative bleeding was 5 to 10 ml without necessity for blood transfusion. A mean passed flatus time postoperative was 18 hours (ranging from 16 to 28 hours). Return of oral food intake was 20 hours (range from 16 to 30 hours) postoperative. Bile stained stools were defecated on day 3 (range from 2 to 4 days) postoperative. Jaundice showed reduction at day 10 (ranging from day 7 to day 16) postoperative. In 6 cases, TBIL and DBIL decreased to normal on the 14th day postoperative, 3 to normal three weeks postoperative. Only 1 maintained high level after a reduction postoperative. The postoperative course was uneventful in 10 patients with hospital stay of 6.8 days (range from 5 to 9 days) after the operation. There was no postoperative complication during follow-up visits.

CONCLUSION: Laparoscopic cyst excision with Roux-en-Y hepatojejunostomy for children with type ϕ_i or $\phi\phi$ biliary atresia is feasible, safe, and effective.

P024 LAPAROSCOPIC TOTAL CYST EXCISION WITH ROUX-EN-Y HEPATOJEJUNOSTOMY FOR NEONATES WITH CHOLEDOCHOCYST

Long Li MD, Shu-li Liu PhD, Wen-Ying Hou MD, Liu-Ming Huang, Department of Pediatric Surgery, Capital Institute of Pediatrics

OBJECTIVE: The aim of this study is to explore the feasibility and safety of laparoscopic total cyst excision with Roux-en-Y hepatojejunostomy for choledochocyst in neonates.

METHODS: This study was carried out on 9 neonates with choledochal cyst. Their main symptoms were jaundice (8 cases), white stools (5 cases), abnormal high level of AST and ALT (9 cases). Their ages ranged from 13 days to 28 days (with an average of 24 days). The choledochal cysts were cyst type in all cases with the average diameter of 3.8 cm (range from 2.5 to 8.0 cm). On 3 patients, the diagnosis were confirmed prenatally. All patients underwent laparoscopic cyst excision with Roux-en-Y hepatojejunostomy. Four trocars were utilized with 3 to 5 mm instrumentation. Intraoperative cholangiography was performed.

The gallbladder and the dilated bile duct were completely excised. The Roux-en-Y hepatojejunostomy was divided into two stages: a Roux-en-Y jejunojunctional anastomosis was performed extracorporeally by exteriorizing the jejunum through the extending umbilical incision (range from 1.0 to 1.5 cm), and then an end-to-side anastomosis was carried out intracorporeally by the continuous hand suture methods between the stump of the hepatic duct and the Roux-en-Y limb. All cases were followed up for a mean period of 26 months (range from 3 to 45 months).

RESULTS: The average duration of operation was 3.6 hours (range from 3.3 to 4.0 hours) without intraoperative complications. Intraoperative bleeding was 5 to 10 ml without necessity for blood transfusion. Bowel movement postoperative was 18 hours (range from 16 to 28 hours). The patients tolerated oral feeding by 20 hours (range from 16 to 30 hours) postoperative. ALT, AST, TBIL, and DBIL decreased after operation. The postoperative course was uneventful in 9 patients with hospital stay of 6.3 days (range from 4 to 9 days) after the operation. No complication such as bile leakage, anastomosis stenosis, cholangitis occurred in these patients during follow-up.

CONCLUSIONS: Laparoscopic total cyst excision with Roux-en-Y hepatojejunostomy is feasible, safe, and effective for the treatment of choledochocyst in neonates.

P025 EFFECT OF ELEVATED INTRA-ABDOMINAL PRESSURE (IAP) ON PORTAL VEIN (PV) AND SUPERIOR MESENTERIC ARTERY (SMA) BLOOD FLOW IN A RAT

Jorge G. Mogilner MD, Igor Sukhotnik MD, Vera Brod PhD, Lili Hayari MD, Arnold G. Coran MD, Haim Bitterman MD, Dept of Pediatric Surgery, Bnai Zion Medical Center, Dept of Medicine, Carmel Medical Center, Rappaport Faculty of Medicine, Technion, Israel and University of Michigan, Section of Pediatric Surgery, Mott Children's Hospital, Ann Arbor, MI

AIM: Recent clinical experience suggests that minimal access portoenterostomy (Kasai procedure) for biliary atresia leads to transplantation sooner compared to the traditional open approach. It should be emphasized that elevated IAP may adversely affect the barrier and metabolic functions of the small intestine, may reduce hepatic and portal blood flow, and, thus cause histological liver damage. The purpose of the present study was to evaluate the effects of IAP on blood flow in the portal vein (PV) compared to the superior mesenteric artery (SMA) and on the systemic mean arterial blood pressure (MABP).

METHODS: Male Sprague-Dawley rats were anesthetized with intraperitoneal ketamine (90 mg per kg) and xylazine (13 mg per kg). Polyethylene catheters (PE-50) were introduced into the right carotid artery for measurement of MABP. After a midline laparotomy, SMA and PV were isolated. Ultrasonic blood flow probes were placed on the vessels for continuous measurement of regional blood flow. Two large-caliber percutaneous peripheral intravenous catheters were introduced into peritoneal cavity for inflation of air and for measurement of IAP. The time course of MABP and SMA and PV flow as well as the relationship between IAP and SMA and PV flow were determined.

RESULTS: Although all three hemodynamic parameters decreased with the increase in the IAP, the most significant changes were observed in PV blood flow. IAP at 3 mm Hg resulted in a 26% decrease in PV flow, 19% decrease in SMA flow and 11% decrease in MABP. IAP at 6 mm Hg caused a two-fold decrease in PV flow, a 30% decrease in SMA flow and a 19% decrease in MABP. There were no changes in the time course of MABP and PV and SMA flow. PV and SMA flow returned to normal values immediately after abdominal deflation.

CONCLUSIONS: Persistent IAP decreased MABP, SMA, and PV flow, but especially PV flow by 50%. We speculate that in biliary atresia patients with already present liver dysfunction decrease in SMA flow and a greater decrease in PV flow from increased IAP, which occurs during a laparoscopic Kasai procedure may further compromise liver function. This may be one of the explanations for the progression to earlier transplantation in infants undergoing a laparoscopic Kasai procedure.



POSTER ABSTRACTS

P026 LAPAROSCOPIC CHOLECYSTECTOMY IN PAEDIATRIC POPULATION: IS IT FEASIBLE AS A DAY-SURGERY PROCEDURE?

Giovanna Riccipettoni, Giovanni Di Iorio, Andrea Pansini, Milena Meroni, Claudio Vella, Marcello Napolitano, Department of Pediatric Surgery, Children's Hospital "V. Buzzi", Milan, Italy

INTRODUCTION: Cholecystectomy in paediatric patients is a debated field. Increasing diagnostic facilities may lead to incidental diagnosis and over extension of surgical indication. Nevertheless, in symptomatic children, laparoscopic cholecystectomy (LC) is the gold-standard technique.

MATERIALS/METHODS: Between January 2001 and December 2007 we have performed 42 LC (24 males, 18 females). All patients were symptomatic: 38 patients (90%) had abdominal pain, 2 (5%) had recurrent pancreatitis and 2 (5%) were jaundiced. Each patient had a preoperative ultrasound and blood test; 9 (21%) had a magnetic resonance cholangiopancreatography (MRCP); 1 (2%) had a preoperative endoscopic-retro-cholangio-pancreatography (ERCP). 34 children (81%) were affected by idiopathic cholelithiasis, 7 (17%) by spherocytosis and 1 (2%) had biliary sludge with dyskinesia of the gallbladder. LC was performed in 34 patients, LC and splenectomy was necessary in 7 patients affected by spherocytosis and an intraoperative cholangiogram was carried out in 1 child.

RESULTS: Each cholecystectomy was performed by an experienced surgeon, mean operative time was 85 minutes. No complications were observed. Oral clear fluids started on the first postoperative day. Mean hospital stay lasted 2,5 days.

CONCLUSION: LC represents a gold-standard technique in symptomatic children. It is characterized by reduced postoperative pain, shorter hospital stay and better esthetical results. An accurate preoperative investigation (like MRCP and ERCP for selected patients) is useful to reduce the need of intraoperative cholangiogram. We believe that LC could be performed in day-surgery regimen in paediatric patient with no associated hematologic disease or obstructive biliary symptoms, like most of the patients in our series (81%).

P027 THE GUIDANCE OF ULTRASONOGRAPHY AND VESSEL DOPPLER STUDIES IN PEDIATRIC LAPAROSCOPIC SPLENECTOMY

Suolin Li BA, Weili Xu, Meng Li, Department of Pediatric Surgery, The Second Hospital of Hebei Medical University, Shijiazhuang 050000, China

AIM: To evaluate the role of ultrasonography(US) and vascular Doppler studies in the applicable anatomy of spleen and demonstrate its instructive value in laparoscopic splenectomy(LS) with elective vessel endoligature.

METHODS: 42 children required LS for various hematologic and autoimmune disorders were examined with US between 2004 to 2007. The splenic vascular anatomic type, the volume of spleen and presence of accessory spleens were detected. The above-recorded parameters were compared with operative findings. We used the silk endoligature consisting in first elective arterial and second vascular ligature to perform LS.

RESULTS: There were no difference between the parameters by US and by intro-operative telerecording. According to the classification of Michels, splenic vascular course was divided into distributed and magistral type. In distributed pattern, multiple branches arised from the main trunk 2 to 3 cm from the hilum, each terminal branch was divided after ligation. In magistral pattern, the pedicle formed by the artery and vein entered the hilum as a compact bundle and was transected between ligating knots. There were no complications and no conversions to open.

Parameter	Detected by US	Recorded in LS	P
Distributed	27	26	>0.05
Magistral	15	16	>0.05
Splenomegaly	24	26	>0.05
Accessory	7	9	>0.05

CONCLUSIONS: The individual operative route and schedule is formulated on the basis of applicable anatomic type. With this technique, the blood splenic sequestration could be preserved and pancreatic trail lesion avoided. LS with elective vessel endoligature is the best procedure.

P028 285 LAPAROSCOPIC SPLENIC PROCEDURES IN CHILDREN – SINGLE CLINIC EXPERIENCE

Igor V. Poddoubnyi MD, Kirill N. Tolstov MD, Andrei A. Isaev MD, Artour G. Mannanov MD, Moscow State University of Medicine and Dentistry, Department of Pediatric Surgery

The purpose of this report is to analyze our 12 years experience in laparoscopic spleen surgery in children.

MATERIALS/METHODS: This study included 283 patients (age range, 11 months-17 years) who underwent 285 laparoscopic splenic operations during the period from 1995 to 2007:

Laparoscopic splenectomy (LS) was performed in 225 children with hematologic indications: hereditary spherocytosis (143), thalassemia (26), immune thrombocytopenic purpura (36), sickle cell disease (5), other variants of hemolytic anemias (15). In 67 cases simultaneous cholecystectomy was accomplished. Laparoscopic splenectomy was also performed in 8 patients with benign spleen tumors (hamartoma - 4; lymphangioma - 2; hemangioma - 2). 52 children underwent laparoscopic resection of benign non-parasitic splenic cysts (true epithelial - endothelial or mesothelial - 16 (30.8%), pseudocyst - 25 (48.1%), cystic lymphangioma - 11 (21.1 %). The growing cystic size more than 3 cm in diameter was the indication for laparoscopic treatment.

RESULTS: Laparoscopic splenectomy: the average operating time was 65 min. (range, 30-195 min.); one case of conversion in 1996 was caused by technical problems; no major complications needing relaparoscopy or relaparotomy occurred. Laparoscopic splenic cyst resection: no intraoperative or postoperative complications, no reasons for conversion occurred; there were 2 cases of recurrence in the patients with cystic lymphangiomas. Laparoscopic splenectomy was performed in these cases: in other 50 patients functional, anatomic and cosmetic results were excellent (including 9 other cases of cystic lymphangiomas).

CONCLUSION: Laparoscopic spleen operations in children are safe and effective and are associated with very low complication and conversion rates, excellent functional and cosmetic results. These methods can be considered the procedures of choice for most patients requiring splenectomy or treatment for benign splenic cysts.

P029 LAPAROSCOPIC NEAR-TOTAL PANCREATECTOMY FOR PERSISTENT HYPERINSULINAEMIC HYPOLYCAEMIA OF INFANCY: REPORT OF TWO CASES

Liem NT PhD, Son TN PhD, National Hospital of Pediatrics

AIM: To describe technical details and early results of laparoscopic near-total pancreatectomy for persistent hyperinsulinaemic hypoglycaemia in 2 infants.

PATIENT/TECHNIQUE: One boy (Patient A) and one girl (Patient B) underwent surgery at the age of 60 days and 54 days, and at bodyweight of 7700g and 5700g respectively. Four ports were used for Patient A and 3 ports for Patient B and fixation sutures to the abdominal wall were used for stomach traction. The pancreas was dissected free from the spleen and vessels and was mobilized beyond the right side of the superior mesenteric vein. The head of the pancreas was transected using the Harmonic Scalpel, leaving only one centimeter of the pancreas along the duodenal C-loop. The pancreatic stump was sutured to prevent leakage. Blood loss was minimal. The operative times were 180 and 160 minutes. There was neither intra- nor post-operative abdominal complication. Oral feeding was resumed on the first postoperative day. The blood glucose level increased immediately after the operation. Patient A restored his blood sugar level to the normal range while Patient

POSTER ABSTRACTS



B required insulin therapy because of hyperglycemia that occurred after 4 days of normoglycemia.

CONCLUSION: Laparoscopic near-total pancreatectomy can be performed safely in small infants with congenital hyperinsulinism.

P030 LAPAROSCOPIC TRANSHIATAL GASTRIC TRANSPOSITION FOR ESOPHAGEAL ATRESIA WITH PRESERVATION OF THE ABDOMINAL ESOPHAGUS

Liem NT PhD, Hau BD MD, Dung LA MD, National Hospital of Pediatrics

AIM: To report the technique of laparoscopic transhiatal gastric transposition for esophageal atresia, preserving the abdominal esophagus.

PATIENT/TECHNIQUE: A boy with Down syndrome and long gap (Type A) esophageal atresia underwent gastrostomy and cervical esophagostomy on February 27, 2007, four days after birth. Esophageal replacement was carried out at the age of 9 months. The laparoscopic operation included complete mobilization of the stomach and lower esophageal stump, pyloroplasty and transhiatal dissection. After loosening the cervical esophagostomy, the gastric pull-up was performed through the retropleural mediastinal route, and the esophago-esophageal anastomosis was completed. The 5-hour intraoperative course was uneventful. Feeding via gastric tube was started on day 2. Leakage at the esophago-esophageal anastomosis occurred on postoperative day 5 but resolved spontaneously. Postoperative esophagogram showed a wide anastomosis and good gastric emptying. The patient was discharged after 3 weeks.

CONCLUSION: Laparoscopic transhiatal transposition for esophageal atresia preserving the abdominal esophagus is a feasible, safe and physiologic procedure. It is a good option for the treatment of long gap esophageal atresia.

P031 INTERVAL LAPAROSCOPIC APPENDECTOMY IN A CHILD WITH G6PD DEFICIENCY

Gökhan Berkutug Bahadır MD, Ufuk Ates MD, Rahsan Vargun MD, Tanju Aktug MD, Department of Pediatric Surgery, Ankara University School of Medicine, Ankara, TURKEY

BACKGROUND: Glucose 6 phosphate dehydrogenase (G6PD) deficiency is the most frequent cause of hemolytic anemia due to enzyme abnormality. Hemolysis usually occurs after exposure to drugs and infections.

METHODS: An eight-year-old boy was admitted with an appendiceal mass with severe anemia. He had been diagnosed as having G6PD deficiency seven years ago. Conservative treatment followed by interval laparoscopic appendectomy was planned.

RESULTS: The length of hospital stay for conservative treatment was one week. The hemoglobin concentration was increased to 12 g/dl spontaneously. Interval laparoscopic appendectomy was performed after six weeks. He was discharged on postoperatively first day. There were no complications following interval laparoscopic appendectomy.

CONCLUSIONS: Conservative management of complicated appendicitis in children is becoming more common. Interval laparoscopic appendectomy can be safely performed in children with hemolytic anemia. Patient with G6PD deficiency requires special attention when admitted to hospital for operative procedures and minimally invasive approach must be preferred.

P032 LAPAROSCOPIC APPROACH FOR ESOPHAGOGASTRIC DISSOCIATION (BIANCHI'S PROCEDURE): IS IT A GOOD WAY?

Pascal de Lagausie PhD, Geraldine Hery MD, Stephane Le Bel MD, Arnaud Charpentier, Jean-Michel Guys, Hôpital la Timone, Marseille, France

BACKGROUND: Total esophagogastric dissociation (TED) was described in 1997 by Bianchi as a new surgical procedure to treat severe gastroesophageal reflux disease (GERD) in children with neurological

impairment. Recently, TED has been proposed in such conditions as oesophageal atresia, oesotracheal cleft or burn oesophageal lesions. Although the long term results in term of GERD control has been previously published, the risk of occlusion is not well documented. The aim of the study was to investigate the eventual place of laparoscopic approach for patients operated on for TED.

PATIENTS/METHODS: A single center retrospective study of all patients operated on for TED between 2004 and 2007 was performed. TED laparoscopic procedure included oesophago-gastric section by endo-GIA, confection of Roux en Y loop (40 cm from the treitz angle) by exteriorisation of the jejunum at the umbilicus (external anastomosis) and internal jejuno-oesophageal anastomosis (2 or 3 running sutures, protected by digestive clamps). All have had a gastrostomy during previous procedures.

RESULTS: Four children, mean age 5 years (6 months-17 years), underwent TED, of which two were severe GERD in neurological patients (failure of Nissen procedure in each case) and two were rescue procedure for severe respiratory disease after oesophageal atresia. Three procedures were completely performed by laparoscopic approach (one is excluded because of conversion). There was no operative mortality. The mean follow-up was 2 years (range 5 months to 3 years). Two children died, one 6 months after the procedure during encephalic convulsion (abnormal caryotype). The other one, a 17 years neurologic patient, needs redo of surgery by laparotomy 3 months after the laparoscopic procedure because of internal hernia. A large part of jejunum migrated upper the meso-colon. He died suddenly 2 months later (probably by intestinal occlusion). The third case is doing well, eating a third of its total feed ration.

CONCLUSIONS: TED is an effective procedure for treatment of GERD in neurologic patients and others surgical conditions such as esophageal atresia. It remains a life threatening procedure. Because intestinal adhesions is a strong risk in this type of patient, laparoscopic approach could be an help for this procedure. As in adult laparoscopic by-pass, a meticulous closing of the mesos is necessary to avoid an internal hernia.

P033 LAPAROSCOPICALLY ASSISTED ANORECTAL PULL-THROUGH FOR HIGH IMPERFORATE ANUS

Mustafa Kucukaydin MD, Ahmet N. Cifiler MD, Mahmut Guzel MD, Mehmet Uysal MD, Mustafa E. Dörterler MD, Serkan Arslan MD, Ahmet B. Dogan MD, Kadri C. Sulubulut MD, Ali Aslan MD, Erciyes University School of Medicine, Department of Pediatric Surgery

BACKGROUND/AIM: Laparoscopically assisted anorectal pull-through (LAARP) for high imperforate anus utilizes minimal perineal dissection, preservation of the distal rectum, and accurate placement of the rectum within the levator ani and external anal sphincter muscle complex. We describe our experience with LAARP for high imperforate anus.

MATERIAL/METHODS: From March 2000 to October 2007, 15 patients with a diagnosis of high anorectal malformation underwent LAARP. The patients, all males aged from 2.5 to 9 months (mean age, 6 months). Twelve patients (80%) had recto-urethral fistulae. The associated malformations were sacral and cardiac malformations, duodenal atresia, gall bladder malformation, proximal type hypospadias and renal agenesis. All patients were treated with a colostomy in the neonatal period by a delayed LAARP.

RESULTS: Laparoscopic mobilization has been possible on all cases attempted. All of the patients have a brisk and symmetric anal contraction with perineal electrostimulation.

CONCLUSION: Although longer follow-up to evaluate continence is to come, LAARP should be considered for the correction of the high imperforate anus and, according to our experience, it represents the preferable technique. It offers the advantage of good visualization of the fistula and the surrounding structures and minimally invasive abdominal and perineal wounds.



POSTER ABSTRACTS

KEY WORDS: Imperforate anus, laparoscopically assisted anorectal pull-through, laparoscopy

P034 COMPLICATIONS AFTER OPEN AND LAPAROSCOPIC APPENDECTOMY FOR PERFORATED APPENDICITIS

Mustafa Kucukaydin MD, Ahmet N. Ciftler MD, Ali Aslan MD, Mahmut Guzel MD, Mehmet Uysal MD, Ahmet B. Dogan MD, Serkan Arslan MD, Kadri C Sulubulut MD, Ozlem Yandim MD, Erciyes University School of Medicine, Department of Pediatric Surgery

BACKGROUND/AIM: The incidence of postoperative complications is not clear after laparoscopic compared with open appendectomy for perforated appendicitis. We want to compare the incidence of postoperative complications for each procedure.

METHODS: From April 2005 to November 2007, 73 patients (48 male, 25 female) age ranged 2-15 years were operated for perforated appendicitis at our institution. Open appendectomy (group I, 50 patients) was performed through a right lower quadrant (43 patients) or midline incision (7 patients) and laparoscopic appendectomy (group II, 23 patients) was performed through a 3-trocar approach. The incidence of postoperative intra-abdominal abscess, wound infections, adhesions and incisional hernia were compared between two groups. Statistical analysis was performed using Chi-Square test. Differences were considered significant when P values were less than .05.

RESULTS: The incidence of postoperative abscess was 2% in group I and 4% in group II. The incidence of wound infections was 4% in group I and 0% in group II. The incidence of postoperative adhesions was 12% in group I and 0% in group II. The incidence of incisional hernia was 6% in group I and 0% in group II. The complication rates were less in laparoscopic appendectomy clinically, but statistically these results were insignificant ($P>.05$).

CONCLUSION: In pediatric patients with perforated appendicitis, we found that less complications that including postoperative intraabdominal abscess, wound infections, adhesions and incisional hernia with laparoscopic appendectomy than open appendectomy.

P035 MINIMAL INVASIVE SURGERY FOR BENIGN AND MALIGNANT PANCREATIC LESIONS - CASE SERIES

Zakaria Habib MD, Mila Kolar MD, Saleh Al Nassar MD, King Faisal Specialist Hospital and Research Centre, Department of Surgery

BACKGROUND: Minimal invasive surgery for pancreatic pathologies is increasingly employed in pediatric population. The aim of this study is to present a single institution experience with this mode of intervention, feasibility and safety.

PATIENTS AND METHODS: This is a retrospective chart review study for patients who underwent laparoscopic procedures for pancreatic pathologies collecting demographic, clinical and outcome data.

RESULTS: A total of 12 patients has been managed laparoscopically in the period between 2003-2006, 5 females and 7 males. Pancreatic pathologies included 5 cases with nesidioblastosis, 3 blunt abdominal trauma with secondary pancreatic cyst, 2 pancreatitis secondary to choledochal cyst and 2 pancreatic tumors (malignant). Conversion rate was 16%. Postoperative complications included one with biliary leak healed spontaneously.

CONCLUSION: A cumulative data internationally and our experience demonstrate the feasibility, safety and easiness of performing this mode of approach to different type of pancreatic pathologies with adherence to basic surgical principles and advanced laparoscopic experience skills. It also provides an easy access to abdominal cavity if further surgical procedures are needed.

P036 FAST-TRACK SURGERY OF THE COLON IN CHILDREN

Girolamo Mattioli MD, Giovanni Rapuzzi MD, Edoardo Guida MD, Vincenzo Jasonni MD, Gaslini Institute, University of Genova, Italy

BACKGROUND: Fast-track surgery is based on a rapid return to normal activity in order to reduce the in-hospital-related problems. The reduced trauma to the viscera and abdominal wall, and the limited use of drugs are the base of the "fast track" organization.

Aim of this study is to present the "fast-track" experience on children who underwent colon resection.

PATIENTS/METHODS: 46 children who received laparoscopic colon resection were prospectively included in the study. Indication to surgery was: anomalies of colon innervation (38) and inflammatory bowel disease (8). Left colon/sigmoid resection was performed in 37, total colon resection was done in 5 and right colon resection in 4. Total colon resection was always associated to ileostomy. Anastomosis was done in 41. Patients were monitored for pain, return to normal activity, feeding, bowel movements and complications.

RESULTS: All the cases were regularly followed. Stool passage and feeding by mouth started on postoperative day one and discharge before post-operative day 4. One case was readmitted the day after discharge, on postoperative day 5 because of fever. Anastomotic leak was showed and temporary colostomy was performed without major problems. No other complications were recorded.

DISCUSSION: We ruled out appendectomies which are routinely performed in a fast-track surgery. Our experience showed that rapid discharge is feasible and safe also in major colon resection.

CONCLUSIONS: Minimal invasive access surgery is safe and effective in pediatric colon surgery. In absence of clinical signs of complications a rapid return to normal activity is suggested. A rigid follow up is mandatory in order to early detect and treat complications.

REFERENCES: Reismann M, von Kampen M, Laupichler B, Suempelmann R, Schmidt AI, Ure BM.: Fast-track surgery in infants and children. J Pediatr Surg. 2007 Jan;42(1):234-8.

P037 CECOSTOMY BUTTON PLACEMENT AFTER PERCUTANEOUS CECOSTOMY OR SIGMOIDOSTOMY UNDER LAPAROSCOPIC CONTROL - SURVEY OF 29 PATIENTS

Francois Becmeur PhD, Martine Demarche MD, Isabelle Lacreuse MD, Isabelle Kauffmann MD, Raphael Moog MD, Florence Donnars MD, Francesco Molinaro MD, Department of Paediatric Surgery University of Strasbourg

This study evaluates the Trap-doorâ button use (Cook Medical) for antegrade enemas in children.

METHODS: Since 2002, patients with faecal incontinence or encopresis and constipation underwent percutaneous cecostomy under laparoscopy using a button. Results: Twenty-nine patients age 3 to 21 (mean 8.5 years), 18 males and 11 females underwent laparoscopic Trap-doorâ button placement. The indications for all the patients was intractable faecal incontinence in 24 cases and constipation with encopresis in 5 cases.

Twenty-six cecostomy button placements and three sigmoidostomy button placements were successful with no intraoperative complication. The mean operative time was 25 minutes (10 to 40 min.) and the hospital stay was 2.5 days (1 to 4 days). Twenty-two patients answered the questionnaire. At the time of this survey, 2 patients had improved their fecal continence and had had the button removed. A mean of four weekly enemas was enough to improve faecal continence troubles (range 1 daily to 1 for 2 weeks). The volume for enemas was 250 mL to 1,000 mL (mean 700 mL). The time required for the irrigation of the bowel by gravity took from 5 min. to 60 min. (mean 25 min.) for 20 patients. Before surgery, 14 patients needed a diaper, day and night, and 6 needed a sanitary protection. Soiling was a very significant inconvenience for all the patients. After surgery, only 5

POSTER ABSTRACTS



patients needed a diaper due to moderate results or urinary incontinence and continued soiling. Patients were asked to give an assessment (null = 0, bad = 1, fair = 2, good = 3, very good = 4). The mean grade was 3.44.

CONCLUSION: Percutaneous placement of a cecostomy button under laparoscopic control is an easy and complication-free procedure. The use of the Trap-door device by the patients or with the help of the parents for antegrade enemas is effective and satisfactory. It improves the quality of life and is reversible.

P038 PITFALLS OF LAPAROSCOPIC REPAIR OF MORGAGNI HERNIA

Burak Tander MD, Mehmet Yazici MD, Ender Ariturk MD, Riza Rizalar MD, Suat H. Ayyildiz MD, Ferit Bernay MD, Ondokuz Mayıs University, Department of Pediatric Surgery

AIM: Four children with Morgagni hernia and laparoscopic repair were evaluated according to technical aspects and problems of repair, and causes of recurrence.

PATIENTS/METHODS: Between May 2005 and October 2006, four children with Morgagni hernia (Three males, one female, age: 3 months-2.5 years) were repaired laparoscopically. Three port technique was used (One for camera and two for instruments). In one patient, intracorporeal knotting technique was used for the repair of the defect, in the remaining patients, the sutures were placed through the full-thickness of the anterior abdominal wall, incorporating the posterior rim of the defect and turning back out through the anterior abdominal wall, with the sutures tied in the subcutaneous tissue. We analysed the causes of recurrences.

RESULTS: One male patient (1 year old) had an uneventful postoperative course with no recurrence of hernia. His defect had been repaired by intracorporeal sutures. The hernias of the patients, whose repairs were performed by sutures placed through the abdominal wall and tied extracorporeally, have recurred. One patient with recurrence (male, 1.5 years old) was found to have a connective tissue disorder and his open repair has failed as well. During the second patient's open repair for recurrence, we recognized that the suture material used at laparoscopy was defective. The cause of the recurrence of the last patient could not be found.

CONCLUSION: Laparoscopic repair of the Morgagni hernia in children might be not the best option for treatment. Placement and knotting of sutures for the closure of the defect extracorporeally may be too weak for a proper repair. Associated connective tissue disorder and the quality of suture material should also be considered.

P039 LAPAROSCOPIC MANAGEMENT OF LARGE UMBILICAL HERNIA USING THE MESH – FIRST IN PEDIATRIC AGE

Mila Kolar MD, Zakaria Habib MD, Saleh Al Nassar MD, Department of Surgery, King Faisal Specialist Hospital and Research Center, Riyadh

This is movie recording for a 4-year-old boy with glycogen storage disease who has an umbilical hernia which measures 12 cm in its maximum diameter. The selection for this approach was to reduce postoperative morbidity in this type of patients. The procedure was completed in 2 hours with smooth postoperative recovery and follow up in 4 months showed no morbidity so far.

P040 TREATMENT OF COMPLICATED APPENDICITIS IN CHILDREN USING A LAPAROSCOPIC APPROACH. IS THERE ANY ADVANTAGE IN ITS USE OR IT IS UNNECESSARY?

Carlos Garcia Hernandez PhD, Lourdes Carvajal MD, Juan Carlos Dueñas MD, Hospital Infantil Privado

BACKGROUND: Appendicitis is the main cause of acute abdomen and as well as emergency surgery in children. The laparoscopic approach is the preferred technique by a great number of surgeons, when it is necessary to

treat a patient with a non complicated acute appendicitis. However there are several reports that show a higher risk of infectious complications in patients that have a complicated appendicitis and are treated using the laparoscopic approach, this reports have created certain distrust on this technique, avoiding its use.

METHODS: Patients with diagnosis of complicated appendicitis were treated. These were divided in two groups. Group I, open traditional approach. And group II, laparoscopic approach.

RESULTS: In the period from January 2004 to January 2007, a total of 102 patients that were diagnosed with complicated appendicitis were included. Group I formed by 42 members and group II by 53 patients respectively. The evolution periods occurred as it is noted next, in group I with an X of 54.53, against an X of 53.58 hours of group II. (P= 0.20). The amount of purulent material in group I varied from 30 to 300 ml with an X of 68.82 ml, while in group II it varied from 30 to 600 ml with an X of 70.72. (P= 0.16). The surgical time of group I was of X=72.64 minutes and in group II X=32.12 minutes. (P=0.0007). The beginning of the oral alimentation of group I was X=114.27 hours and in group II of X=38.52 hours. (P=0.005). The hospital stay of group I was of X=7.31 days while in the second group of X= 3.50 days. (P=0.067). 31 patients of group I showed wall abscesses, in group II only 4 patients showed a wall abscess. (P=0.004). There were several residual abscesses in 4 patients of group I and in only one of group I without any statistic significance, 6 patients of group I and only I of group II showed any intestinal obstruction. (P=0.007).

CONCLUSION: The minimal invasion approach is the treatment that proves to be the optimal choice when treating children with acute complicated appendicitis, because it allows a faster recovery, an early alimentation, a shorter hospital period and a less frequency of infectious complications.

P041 LAPAROSCOPIC GASTROPEXY FOR GASTRIC VOLVULUS IN A GIRL

Burak Tander MD, Mehmet Yazici MD, Riza Rizalar MD, Ferit Bernay MD, Ondokuz Mayıs University, Department of Pediatric Surgery

AIM: We present an 11 year old girl with an organoaxial gastric volvulus treated by a laparoscopic gastropexy.

CASE REPORT: 11 year old girl had upper abdominal tenderness and distension for several months. She had no vomiting. Upper gastrointestinal series revealed an organoaxial gastric volvulus. We made a laparoscopy with three ports, a 30 degrees 5 mm telescope and two 5 mm instruments. We performed the procedure in three steps: Initially an esophagocardiopexy was made followed by a phrenofundopexy and an anterior gastropexy using intracorporeal and extracorporeal suturing techniques. The postoperative course was uneventful and she was discharged symptomless.

CONCLUSION: Laparoscopic gastropexy is a safe and effective procedure for chronic gastric volvulus in children.

P042 LAPAROSCOPIC ENDORECTAL COLON PULL-THROUGH LEAVING A SHORT RECTAL SEROMUSCULAR SLEEVE FOR HIRSCHSPRUNG DISEASE: PERSONAL EXPERIENCE WITH 200 CASES

Liem NT PhD, Hau BD MD, Quynh TA MD, Hong Anh NT MD, National Hospital of Pediatrics

OBJECTIVE: To report early and late outcomes after laparoscopic colon pull-through leaving a short rectal cuff for Hirschsprung disease (HD).

METHODS: Laparoscopic endorectal colon pull-through was performed using four ports. The ganglionic and aganglionic segments were initially identified by seromuscular biopsies obtained laparoscopically. The rest of the procedure was carried out according to Georgeson's technique. However we left a short rectal seromuscular sleeve around 2 cm from the dentate line.

RESULTS: From January 2001 to November 2007, 200 patients between 14 days and 36 months of age underwent laparoscopic surgery for HD. The aganglionic segment was located in the rectum in 112 patients, in the



POSTER ABSTRACTS

sigmoid colon in 80 children, and in the left colon in 8 patients. The mean operating time was 152 minutes. One stage operation was carried out in 161 patients. Excess colon was left at operation and removed 2 weeks later in 39 patients. There were no operative complications or deaths. Conversion to open operation was required in four patients. There was minimal blood loss during the surgery. Clear fluid was given 12 hours after surgery and milk was given on the second day. In one patient, a small intestinal perforation occurred 3 days after surgery, requiring ileostomy. Hospital stay varied from 4 days to 16 days (mean: 7.5 days). Follow-up was obtained in 105 patients (52.5%). Of these, 77 patients (73.3%) had 1-4 defecations /day, 15 children (14.3%) had 5-6 defecations /day, and 8 patients had more than 6 defecations/day. Fecal incontinence occurred in 3 patients (2.8 %), constipation in 2 children (1.9 %) and enterocolitis in 34 patients (14.8%).

CONCLUSION: Laparoscopic endorectal pull-through is a safe and effective procedure for HD.

P043 LAPAROSCOPIC CHAIT CECOSTOMY TUBE PLACEMENT FOR THE MANAGEMENT OF FECAL INCONTINENCE: OUTCOMES AND LESSONS LEARNED

Sani Z. Yamout MD, Philip L. Glick MD, Y-Horng Lee MD, Stanely T. Lau MD, Mauricio A. Escobar MD, Michael G. Caty MD, Women and Children's Hospital at Buffalo

Antegrade enemas administered through a percutaneously placed Chait cecostomy tube have resulted in a marked improvement in compliance and outcome of patients who suffer from fecal incontinence. The percutaneous technique; however, is a two step procedure that is not performed under direct vision. This report presents the results and lessons learned from our experience with laparoscopic placement of Chait cecostomy tubes.

This is a retrospective chart review of patients who underwent laparoscopic placement of Chait cecostomy tubes from 1999 to 2007. We recorded patient demographics, primary diagnosis, hospital stay, associated complications, follow up duration and outcome. The tubes were placed laparoscopically, with T fasteners used in the majority of cases.

Seventeen patients, ages 5 to 17 years (mean, 11.8 years), underwent laparoscopic Chait cecostomy tube placement over a period of 8 years. Follow up ranged from 4 to 67 months (mean, 46 months). The primary diagnosis was spina bifida in fourteen patients, and the rest had paraplegia, sacral agenesis and an anorectal malformation. Sixteen procedures were successfully completed laparoscopically. There was one intraoperative complication, which consisted of tangential needle placement into the cecum, and required conversion to an open procedure. Hospital stay ranged from 2 to 7 days (mean, 3.8 days). Emergency department visits related to Chait tube complications averaged 0.5 episodes per patient, and were mainly due to tube dislodgement and breakage. Long term complications included accidental dislodgement of the tube in 7 patients (41%), hypertrophic granulation tissue in 6 patients (35%), mechanical failure of tube (breaks/leaks) in 6 patients (35%), wound infections at the tube site in 3 patients (18%), complications related to the use of fasteners in 2 patients (12%), VP shunt infection in 2 patients (12%) and appendicitis in 1 patient (6%).

The laparoscopic approach to Chait cecostomy tube placement is a simple and safe procedure. The rate of long term complications such as tube dislodgement and mechanical failure, which are responsible for the majority of unplanned ED visits, may be decreased by routine yearly tube exchanges.

P044 SURGICAL AND ANESTHESIOLOGIC PITFALLS DURING EXPERIMENTAL LAPAROSCOPIC FUNDOPPLICATION IN YOUNG PIGS

Bernd Donaubauer MD, Alexandra Krauss, Robin Wachowiak MD, Oliver J Muensterer PhD, Departments of anesthesia and pediatric surgery, University of Leipzig

Objective: Laparoscopic Nissen fundoplication (LNF) can be performed on infant pigs for training or experimental purposes. However, young pigs are especially sensitive and porcine anatomical particularities may produce

problems which can be overcome by appropriate preparatory measures. We describe our experience with experimental LNF in infant pigs, analyze the complications encountered, and propose technical solutions.

MATERIALS/METHODS: LNF and gastrostomy placement was performed in 14 infant pigs (age 6-8 weeks, weight 7.0-9.8 kg) under general anesthesia. During the first 7 operations (group I), the liver was retracted by transabdominal liver sutures and a 5 mm endosurgical grasping forceps anchored in the diaphragm. The last 7 operations (group II) were performed without any retraction of the liver, and bilateral prophylactic chest tubes were placed after inducing anesthesia and before the actual procedure. Complications for these 2 groups were recorded and the rates were compared.

RESULTS: LNF was successfully completed in 12/14 subjects, 2 pigs died of hemorrhage from the liver and/or vena cava. Bleeding interrupting the operative workflow occurred in 5/7 in group I and 2/7 in group II. Tension pneumothorax developed in 4/7 pigs in group I and 1/7 in group II. All pneumothoraces in group I were treated with intraoperative chest tube placement. Less common complications were unsuccessful orotracheal intubation requiring tracheostomy (n=1) and injury of the bile duct during dissection of the gastrohepatic ligament (n=1).

CONCLUSION: Successful experimental LNF in infant pigs requires species-specific anatomical and physiologic knowledge. Retracting the liver increases the risk of bleeding and is unnecessary to obtain adequate exposure for LNF. Prophylactic bilateral chest tubes should be placed before the procedure to minimize the otherwise high risk of intraoperative tension pneumothorax. Differences in the airway may complicate orotracheal intubation. The surgeon must be aware of the proximity of the duodenohepatic and gastrohepatic ligament in small pigs.

P045 LAPAROSCOPIC REPAIR OF HIGH IMPERFORATE ANUS

Hamid Reza Foroutan MD, Abbas Banani MD, Namazi Hospital, Shiraz University of Medical Sciences

Laparoscopic repair for males with high type imperforate anus has recently been performed in our institute. Here we describe three patients with recto vesical fistula who had sigmoid colostomy at new born age and were repaired laparoscopically at age 3-5 month. They were followed for 6-24 months and they were evaluated clinically. All had distal loopography preoperatively. The fistulae were easily visualized, transected and ligated. Using a muscle stimulator to identify the location of the anus, a Veress needle was placed through the perineum in the middle of the muscle complex as visualized from the abdomen. The tract was then dilated up to a 12-mm port. Then the colon was pulled through and sutured to the anal dimple. They underwent every other day anal dilatation. All of them developed mild mucosal prolapse with mild anal stenosis. They had spontaneous bowel movement after closure colostomy which was performed 6-8 weeks after anoplasty. The results were acceptable but long term follow up is needed to evaluate the outcome.

P046 AN UNUSUAL JOURNEY OF A RETAINED FECALITH

Esra Temeltas MD, Rahsan Vargun MD, Suat Fitoz MD, Meltem Bingöl Kologlu MD, Ankara University School of Medicine

BACKGROUND: Retained fecalith after appendectomy is an uncommon complication and mostly presented as intra abdominal abscess. There are few cases of extra abdominal abscess developed due to retained fecalith. Herein we present a case complicated by a gluteal abscess with intra abdominal extension due to unusual journey of retained fecalith after appendectomy. As far as we know, this is the first case of gluteal abscess due to retained fecalith in children.

METHODS: A 14-year-old boy presented with fever, gluteal pain and difficulty to walk for three weeks. He had open appendectomy in outside hospital four years ago. There was no palpable mass or induration and tenderness from outside. Computed tomography revealed a gluteal abscess

POSTER ABSTRACTS



under muscle planes with intra abdominal component and a small round calcified mass encountered inside the abscess.

RESULTS: Child underwent laparoscopic exploration to find out if there is an intra abdominal relation with the abscess pouch. Laparoscopy revealed intra abdominal adhesions and after getting down the adhesions retroperitoneal extension of the soft tissue component of the abscess is found. Cecum was adherent to soft tissue component of the abscess. After releasing the cecum, drainage of the abscess and removal of the fecalith were performed from the gluteal region. The patient's symptoms relieved immediately and he is doing well.

CONCLUSIONS: Development of intra abdominal abscess due to retained fecalith is an uncommon complication and may develop because the stone acts as an infected foreign body. The number of both adult and child cases of intra abdominal abscess secondary to retained fecalith has been increasingly reported with more widespread use of laparoscopic appendectomy. Removal of fecalith is absolutely necessary for the treatment of abscess and laparoscopy has been successfully used in removal of retained fecalith. Extra abdominal abscess due to retained fecalith is very rare. However laparoscopic surgeons should become aware of this potential complication and possibility of migration of the fecalith.

P047 PEDIATRIC LAPAROSCOPIC CHOLECYSTECTOMY: OUR EXPERIENCE IN THE REGIONAL HOSPITAL OF PUCALLPA, UCAYALI – PERÚ

Armando Reque García MD, Luis Humberto Rengifo Navarrete MD, Regional Hospital of Pucallpa, Ucayali - Perú

SUMMARY/INTRODUCTION/OBJECTIVE: The laparoscopic cholecystectomy is the gold rule in treatment of the gallbladder pathology which is applied also in children since 90 decade. The objective is to show our experience in laparoscopic cholecystectomy in children.

MATERIALS/METHODS: This is a descriptive, retrospective and longitudinal study revising cases of 28 pediatric patients between 7 and 16 years old during January 1998 to December of 2007. A database of personal dates, diagnosis, intraoperative results, surgical time, intraoperative events, morbidity, complications, time of start for oral ingestion, time of postoperative hospitalization and follow-up was prepared. The American procedure was used in all the patients.

RESULTS: From the 28 patients 5 were male and 23 females. Six patients presented acute cholecystitis and 4 of them had lithiasis, 22 patients had chronic cholelithiasis and proved the presence of gallbladder stones. There were no intraoperative events, neither conversion to open procedure. The median operative time was 83 min (Std. D: 42.9). Postoperative morbidity presented in 3 patients (10.7%) and was due to abdominal pain, vomits and shoulder pain. The medium time for initial oral ingestion was 9 hours and hospitalization was 32.6 hours (Std. D: 12.2). Only 18 patients were followed up and they returned to their daily activities with a mean of 5 days (Std. D: 1.6). There were neither major postoperative complications and nor mortality.

CONCLUSIONS: The use of laparoscopic procedure in cholecystectomy in children is safe and gives a quick recovery.

Keys words: cholecystectomy, biliary lithiasis, laparoscopy, pediatry

P048 EFFECTIVENESS OF BASIC ENDOSCOPIC SURGICAL SKILL TRAINING FOR PEDIATRIC SURGEONS

Satoshi Ieiri MD, Kazuo Tanoue MD, Takanori Nakatsuji MD, Kozo Konishi MD, Junko Akiyoshi MD, Makoto Hashizume MD, Tomoaki Taguchi MD, Department of Pediatric Surgery, Graduate School of Medical Sciences, Kyushu University, Department of Advanced Medicine and Innovative Technology, Kyushu University Hospital

BACKGROUND/AIMS: Pediatric surgeons are required the highly advanced skills in endoscopic surgery for wide variety of operative procedures, but their experienced cases were limited in number comparing with general surgeons. The aim of this study was to evaluate the basic skill

training effects for the less experienced young pediatric surgeons and to compare with the general surgeons.

METHODS: 326 surgeons underwent a 2-days basic skill training program in Kyushu University Hospital Minimally Invasive Surgery Training Center. This program includes lecture, box training (mainly suturing), VR simulator training (MIST, LAP Sim, Lap Mentor), tissue training (porcine intestinal anastomosis) and live tissue training (25-30 kg pigs). These training were only basic skill trainings needed eye hand coordination and bi-hand coordination, not operative procedures. Trainees were divided into two groups. Group P (Pediatric surgeons, n=28) and Group G (General surgeons, n=298) received same training program and were evaluated their endoscopic surgical skills twice before and after training program. Evaluation task was suturing continuously along a circumference line. This task is also a test of non-dominant hand controls. The operator is required to continuously suture a circle 2.5 cm in diameter from the outside to internally. Cut off time is 7 min and errors (deviation from the line, loosened sutures and not completed sutures) were analyzed. To further analyze the spatial trace of the tips of the forceps, 3-dimensional position measurement instrument of electromagnetic tracking system (AURORA; Northern Digital Inc. CANADA) were used. Statistical analysis was used unpaired t-test.

RESULTS: All results were as follows; Experienced cases; P:16.7}16.2, G 64.2}91.2(p<0.05). Number of completed sutures before training; P:1.3}1.9, G2.3}2.1(p<0.01). Number of completed sutures after training; P:4.3}2.2, G4.4}2.0(p>0.05). Both group improved their skills in number of suturing comparing before and after training (P:p<0.001,G:p<0.001). Economy of the movement and speed in both hands were improved in both group from analysis of trajectory pattern of the forceps. But errors were increased in both groups.

CONCLUSIONS: Less experienced pediatric surgeons developed their endoscopic surgical skills up to same level of the more experienced general surgeons. However, manipulation of the forceps became roughly. Because rude handling is contraindicated for pediatric surgeons, our program must be modified to decrease the surgical errors and to acquire the safe and precise technique.

P049 LAPAROSCOPIC CHOLECYSTECTOMY IN CHILDREN: LESSON LEARNED FROM THE FIRST 109 CASES

Ciro Esposito MD, Francesca Alicchio MD, Antonella Centonze MD, Flavio Perricone MD, Giuseppe Ascione MD, Alessandro Settimi, Dept. Pediatrics, Federico II University of Naples and "Magna Graecia" University of Catanzaro, Italy

BACKGROUND: Laparoscopic cholecystectomy (LC) is a frequently performed operation in adult patients, but it is infrequently required in children. A retrospective review of 109 consecutive patients undergoing LC from 1996 to 2007 was performed to see what lessons have been learned from this series.

PATIENTS/METHODS: From January 1996 to January 2007, 109 consecutive patients required LC. Considering that 9 of them were adults, our attention will be focused only on the 100 pediatric patients. The 100 patients ranged from 60 to 204 months with an average age of 90 months. They were 58 girls and 42 boys; in 27 patients a concomitant splenectomy was performed (during the same anaesthesia). In all the patients we used 4 trocars and the cystic duct and the cystic artery were always closed using titanium clips. Only 2 surgeons performed all the operations. Only 1 patient that presented a main bile duct dilatation at pre-operative echography underwent a per-operative colangiography. In all the patients we left a drainage for the first 24 postoperative hours.

RESULTS: The operating time ranged between 27 and 90 minutes (45 minutes on an average). In all the patients the drainage was removed in the first post-op day and the child was discharged from hospital on post-operative day 2 or 3. We recorded 2 biliary and 1 vascular anomaly of the



POSTER ABSTRACTS

gallbladder (3%). We recorded 4 (4%) per-operative complications, in 1 case a technical problem with the tip of reusable scissors, in 3 cases a perforation of the gallbladder during the dissection step. We recorded 4(4%) postoperative complications. In 1 patient a dislocation of clips positioned on the cystic duct occurred; this patient was operated on the 2nd postoperative day and new clips were positioned. Two other patients had a lesion of the main bile duct, remained unknown during surgery, the first one received a choledo-jejunostomy on postoperative day 7, the second received a suture of the choleducus on post-operative day 5 on a stent positioned using ERCP. The follow-up was uneventful for all the 3 patients. The 4th complication was an umbilical granuloma.

The 2 biliary complications occurred in the patients n° 45 and 71 in patients over 14 yrs of age.

CONCLUSIONS: LC is a safe and effective procedure in children. Major complications can happen also in expert hands and are more frequent in teen-agers. Some complications can be resolved in laparoscopy, some others require a biliary derivation; for this reason it's important to have an expert of biliary surgery in the laparoscopic team. Biliary or vascular anomalies of the gallbladder are rare events that can be encountered in about 3% of patients. An accurate and delicate dissection together with a proper knowledge of the anatomy are key factors to reduce complication rate.

P050 AN ALTERNATIVE METHOD FOR DILATATION OF A PERSISTENT SEGMENTAL CAUSTIC ESOPHAGEAL STRICTURE

Baran Tokar MD, Huseyin Ilhan MD, Umut Alici MD, Dilsad Demet MD, Ozgur Aktas MD, Eskisehir Osmangazi University, School of Medicine, Department of Pediatric Surgery, Eskisehir, Turkey

BACKGROUND: Esophageal stricture in children may develop in corrosive injuries, inflammatory esophagitis and following an esophageal surgery such as esophageal atresia. We have a high number of patients admitting with esophageal stricture due to corrosive injuries and an algorithm was developed for diagnosis and treatment. In our management protocol, we continue to perform periodic dilatation with Moloney bougie or balloon until recovery of the esophageal passage. To prevent unnecessary esophageal surgery or replacement, we persist to dilate the stricture. In our cases, the longest duration needed for periodic dilatation was 3 years. In one of our cases, periodic dilatations continuing more than 3 years couldn't achieve a successful dilatation so that we applied a new dilatation method.

CASE REPORT: An eleven years old boy was admitted with a corrosive injury of the distal third of esophagus in September 1998. He needed periodic dilatations under general anesthesia (GA) with 3 to 4 weeks interval until November 2001. Since a significant progress couldn't be achieved, an alternative twice daily balloon dilatation program for long duration (7 days) was applied. The level of the stricture where the balloon had to be inflated was marked in the first day under fluoroscopy. Dilatation with 18-20 mm balloon dilators was performed twice daily at least 10 minutes for seven days. A complaint in difficulty of swallowing of solid vegetative matters occurred three months after the long term daily dilatation. The same procedure was repeated six times with 4 to 7 months intervals until October 2004. For the last three applications, Triamsinolon asetonid injection into the stricture under GA was performed just before the procedure. The patient is now in the follow up since the last 4 years with no complaint and with no need for dilatation.

CONCLUSION: Dilatation under GA has been recommended method for primary or secondary esophageal strictures. Surgery could be considered in persistent cases with no significant response to intermittent dilatations. Although it is not possible to make a conclusion with only one case, our long term daily dilatation method could be tried in persistent cases with a segmental stricture. Manuel pressure control by the physician and the patient's cooperation and guidance for where to inflate the balloon are the important factors for success of the procedure.

P051 INTRAOPERATIVE UPPER GI ENDOSCOPY ENSURES AN ADEQUATE LAPAROSCOPIC HELLER'S MYOTOMY

B.T. Adikibi MD, G.A. MacKinlay MD, F.D. Munro MD, L. Khan MD, P.M. Gillett MD, Royal Hospital for Sick Children, Edinburgh, UK

INTRODUCTION: We present our case series of Laparoscopic Heller's myotomies performed for achalasia between 2000 and 2007 in our institution. These were all performed with the aid of intra-operative endoscopy.

METHODS: During the seven year period, five patients underwent a Laparoscopic Heller's myotomy. There were four male patients and one female with an average age of 12.1 years at operation (age range 9.3-14.9 years). One 14 yr old boy had had a laparoscopic Heller's procedure performed elsewhere and presented with severe dysphagia whilst undergoing orthopaedic surgery in our hospital. His myotomy had been inadequate and intra-operative endoscopy had not been performed. All patients had pre-operative upper gastrointestinal contrasts performed to confirm the diagnosis of achalasia. Two patients had manometry in addition to the contrast study. One patient had been treated with balloon dilatation preoperatively and another with botox injections. All the patients had a three port (additional incision for liver retractor) technique laparoscopic Heller's myotomy with an anterior fundoplication. Endoscopy was performed pre and post myotomy to ensure adequacy. All patients had a water soluble contrast swallow on the second post operative day before commencing oral intake. Demographic, operative and post-operative outcomes were obtained.

RESULTS: The median operating time was 90 minutes (range 80- 150 minutes). The median time to oral feeding was 2 days. Median hospital stay was 3 days (range 3-6 days). There were no cases of intra-operative mucosal perforation or conversions to an open procedure. 60% of patients required extension of myotomy after intra-operative endoscopy. All patients had an uneventful post operative recovery with no post operative complications. After a follow up period that ranged from 1.5 months to 91 months (median 53 months) 4 patients were asymptomatic. One patient has had retro-sternal pain but normal swallowing. Investigations have suggested that this is due to oesophageal spasm and it has resolved with buccal nifedipine.

CONCLUSION: We feel that the addition of endoscopy during Laparoscopic Heller's myotomy confers a significant advantage in ensuring that the myotomy is adequate. In our experience the outcome has been excellent even after previous balloon dilatation or submucosal botox injections.

P052 LAPAROSCOPIC-ASSISTED PNEUMATIC REDUCTION OF INTUSSUSCEPTION

H. AbdElkader, Ehab ElShafi, H. Safaan, M. Sameh, S. Hay and A. Hamza, Pediatric Surgery Unit, Ain-Shams University, Cairo, Egypt

BACKGROUND: Intussusception is a common pediatric surgical emergency. When non-operative therapy fails, surgery becomes necessary. Minimal access surgery for reduction of ileocolic intussusception has been reported with success. But most of the literature described the use of laparoscopy for reduction after failure of pneumatic reduction without using concomitant air enema during laparoscopy. We herein reviewed our experience in using the laparoscopic -assisted pneumatic reduction in the management of childhood intussusception.

METHODS/RESULTS: During the period from January 2006 to March 2007, 89 patients were managed for intussusception at the Pediatric Surgery Unit, Ain-Shams University. All data were retrospectively collected and analyzed regarding the method of reduction, success rate and incidence of complication. 68 of them were successfully reduced using air enema reduction under fluoroscopic guidance. In fifteen patients the laparoscopic-assisted pneumatic reduction technique was used. Ten of them had the procedure completed; two patients had previous

POSTER ABSTRACTS



episodes of intussusception that were managed with previous pneumatic reduction. While conversion to open surgery was done in 5, all of them needed resection and anastomosis. In six patients the conventional open reduction was used instead of laparoscopy due to abdominal distension and bad general condition. In those patients, in whom laparoscopy was used there was no significant complication related to the procedure. All patients were discharged within 24 hours except those of course who needed conversion.

CONCLUSION: Laparoscopic-assisted pneumatic reduction of childhood intussusception is both safe and feasible. It allows for video monitor the reduction of the mass, it is also very helpful in recurrent cases and in those in whom the diagnosis was either difficult or doubtful.

P053 LAPAROSCOPIC ADRENALECTOMY FOR ADRENAL TUMORS IN CHILDREN

Pablo Laje MD, Peter A. Mattei MD, The Children's Hospital of Philadelphia

PURPOSE: The purpose of this study is to present our experience with children who underwent laparoscopic adrenalectomy for adrenal tumors over the last four years, discuss the technical aspects of the procedure, and review the current literature.

METHODS: We performed a retrospective review of all laparoscopic adrenalectomies performed at our institution between July 2003 and September 2007. Charts were reviewed and patient data compiled in accordance with all regulatory practices.

RESULTS: Eight patients underwent laparoscopic adrenalectomy. There were 6 girls and 2 boys. The median age was 14.5 years (range: 2 to 18 years). The median weight was 53.5 kilograms (range: 13 to 73 kg). There were 6 left adrenalectomies and 2 right adrenalectomies performed. In all cases, a lateral transperitoneal approach was used; the majority required only three ports while a fourth port was used in two patients. The tumor size ranged from 3 cm to 7 cm (maximum diameter). The mean operative time was 99 minutes (range: 58 to 140 minutes). There were no intra-operative or postoperative complications. None of the procedures required conversion to open, and blood loss was minimal in all cases. The mean hospital stay was 36 hours (range: 24 to 48 hours). The need for narcotics for pain management was minimal. Pathology results included: adrenal cortical adenoma (n=4), ganglioneuroma (n=2), pheochromocytoma (n=1) and neuroblastoma (n=1). All patients were started on diet advancement immediately after surgery.

CONCLUSIONS: Laparoscopic adrenalectomy is a safe and effective technique in children with small adrenal masses. The lateral transperitoneal approach offers optimal visualization and has excellent outcomes in terms of pain, post-operative recovery and cosmesis.

P054 MINIMAL INVASIVE SURGERY FOR PATIENTS WITH SITUS INVERSUS

Mila Kolar MD, Zakaria Habib MD, Saleh Al Nassar MD, Department of Surgery, King Faisal Specialist Hospital and Research Center, Riyadh

Situs inversus is a rare condition. It may possess technical difficulties in doing advanced minimal invasive procedures. Here is a report of three patients with situs inversus totalis who were managed laparoscopically for different pathological conditions. One patient had gastroesophageal reflux disease, one with duodenal atresia, and the third with neonatal jaundice (biliary atresia). All were completed laparoscopically except for the one with biliary atresia which is converted to open not for technical reasons but for the general consensus at recent IPEG meeting not recommending this approach for it.

P055 RECTAL PROLAPS: RECTOPEXY BY LAPAROSCOPY

Fouad F. Ettayebi MD, Children's Hospital of Rabat, Morocco

Prolaps of the rectum through the anus may involve only a small ring of mucosa or more common only all layers of the rectum. The most common form of rectal prolaps is idiopathic. Rectal prolaps is common

in patients with myelomeningocele, common extrophy of the bladder or similar conditions associated with deficiencies in the pelvic musculature or its innervation. Most patients with rectal prolaps do not require any specific treatment other than measures to prevent excessive straining and institution of stool softeners. Several surgical approaches to rectal prolaps have been reported. One of the most effective is linear injection of sclerosing solution into the rectal sub mucosa. In severe cases, operations via the transabdominal approach is used. The primary goal of most the procedures is to fix the rectum so that it can not prolaps. The fixation of the rectum can be done via laparoscopy. Between 1999 and 2007, 74 children with rectal prolaps have been admitted in the children hospital of Rabat Morocco. All the patients have benefited from injection of sclerosing solution in the submucosa. 11 of them had complete rectal prolaps and rectopexy via laparoscopy was required. Three trocars was used. The rectum was mobilised and fixed laterally to the fascia of left psoas muscle. The overage time of the procedure was 30 mn. Oral feeding was started on the same day. The patients was discharged in 24 h. Any recurrence has been seen until now. The follow up is about 6 years.

P056 THE LAPAROSCOPIC EVALUATION OF THE RADIOLOGICAL DIAGNOSIS OF INTESTINAL MALROTATION

Lucas E. Matthyssens MD, René M. Wijnen PhD, Ivo De Blaauw PhD, Marc H. Wijnen PhD, Dept of Paediatric Surgery, Radboud University Medical Center, Nijmegen, The Netherlands

INTRODUCTION: Intestinal malposition and malrotation (IM/M) are part of a spectrum of intestinal rotation anomalies and may be the cause of feeding problems and/or other intestinal symptoms, going from nausea up to intestinal volvulus. Intestinal rotation typically takes place at the duodenum and at the caecum. Malposition may occur at either localisation or at both (the so-called total intestinal malrotation). The ultimate diagnosis of IM/M remains surgical, but radiological contrast studies may be indicative. A positive Upper Gastrointestinal Contrast Study (UGICS) indicating malposition, especially in the presence of gastrointestinal symptoms, necessitates surgical exploration. The diagnosis and treatment (Ladd's procedure) can be performed laparoscopically.

AIM/METHODS: Since 2004 we operated all children presenting at our institution with a suspicion of IM/M on the radiological UGICS by laparoscopy. The aim of laparoscopy was: 1. diagnostic, to confirm or not the radiological diagnosis, by exploring the position of the caecum, of Treitz' Ligament, the position of the duodenal curvature, and to evaluate the mesentery, and 2. therapeutic, to perform an additional laparoscopic Ladd's procedure, whenever necessary. To study the operative findings in correlation with the radiological diagnosis, and the value and feasibility of laparoscopy as a diagnostic tool for IM/M, we reviewed all patients operated on since 2004.

RESULTS: 48 patients, with ages ranging from 6 days up to 16 years (mean 2.1), underwent diagnostic laparoscopy for the evaluation of a radiological diagnosis by UGICS of IM/M between January 2004 and June 2007. In 19 patients (39.6%), a duodenal malposition was found. 24 patients (50%) were found to have a caecal malposition. Total intestinal malrotation, a combination of both, was confirmed in 19 patients (39.6%) - exactly those with duodenal malposition (100%). However, of the 24 patients with a caecal malposition, only 16 had total intestinal malrotation (66.6%). All 19 malrotation patients underwent additional laparoscopic Ladd's procedure, of which 11 (57.8%) needed conversion for different reasons. With a 100% follow-up ranging between 1 and 4 years (mean 2.4), no complications or misdiagnosis have been noted up till now. These results will be compared with the literature and additional tips and remarks on the minimal invasive technique used and the lessons learned will be discussed.

CONCLUSION: Only 19 (39.6%) out of 48 patients with a radiological diagnosis of intestinal malposition on UGICS were found to have a true total intestinal malrotation, and underwent additional laparoscopic



POSTER ABSTRACTS

Ladd's procedure, with or without conversion. Laparoscopy is a safe and good tool for the minimal invasive diagnosis of IM/M in children and may prevent unnecessary explorative laparotomy in up to 75% of patients with UGICS suggestive for IM/M.

P057 SINGLE PORT INTRACORPOREAL LAPAROSCOPIC APPENDECTOMY (SPI-LA): A UNIQUE OPPORTUNITY FOR ADVANCING ENDOSCOPIC SURGICAL SKILLS OF PEDIATRIC SURGERY RESIDENTS

Gulce Hakguder MD, Oguz Ates MD, Mustafa Olguner MD, Feza M. Akgur MD, Dokuz Eylul University, Medical School, Department of Pediatric Surgery, Izmir Turkey

AIM: During postgraduate minimally invasive surgery training, residents traditionally acquire endoscopic surgical skills through on the job training. Explorative laparoscopy is usually the preferred procedure to start. For general surgery residents laparoscopic cholecystectomy is the best laparoscopic procedure to develop their endoscopy skills. For pediatric surgery residents SPI-LA would be a suitable laparoscopic procedure as it is more challenging than formal 3 port laparoscopic appendectomy.

MATERIALS/METHODS: Between April 2005-December 2007, 148 patients (80 boys, 68 girls), aging 5-17 years (mean 11.3 \pm 6.1) underwent SPI-LA. The residents were asked to fill out a questionnaire regarding developing endosurgical skills satisfaction.

RESULTS: Laparoscopic appendectomy was completed in 145 patients through a single port. A second port insertion was required in 3 patients. No perioperative complications were encountered. Residents were highly satisfied performing SPI-LA as they are developing their skills to control the camera and the instrument together at the same time. They stated that, SPI-LA was harder initially but it gets easier then as they gained experienced.

CONCLUSION: The unique method presented improves the manipulation of the camera and the instruments together by a single surgeon. SPI-LA elevates the self-confidence of the residents as it enables the surgeon to complete the appendectomy by her/himself.

P058 THE ROAD TO PAEDIATRIC LAPAROSCOPIC FUNDOPLICATION (LF)

T. Bradnock MD, P. Hammond MD, G. Haddock MD, A. Sabharwal MD, Royal Hospital for Sick Children, Yorkhill, Glasgow

INTRODUCTION: The way to introduce LF to a paediatric surgical unit has not been well described. We have taken a measured approach to LF and report our experience.

METHODS: All patients undergoing LF from January 2003 to December 2007 were reviewed retrospectively. Cases were identified from theatre and discharge databases.

RESULTS: 86 LFs were performed, 51 males; median age 48 months (2-218). 51 (59%) were neurologically impaired; a further 26 (30%) had significant co-morbidity. 82 (95%) cases were performed by or under supervision of the two senior authors. 11 of the first 13 cases were performed with mentorship of a visiting surgeon from an established paediatric laparoscopic centre. Thereafter, LF was conducted as a two consultant then one consultant operation and finally performed primarily by trainees under consultant supervision (see table). The total number of LF increased from 4 in 2003 to 31 in 2007. 38 patients underwent LF alone; 22 had a gastrostomy in situ. 38 underwent LF with gastrostomy and four underwent redo LF following previous antireflux surgery. The proportion of patients managed in HDU/PICU (68-78%) has not diminished with time. Major complications occurred in 8 (4 gastric perforations, 1 gastrostomy insertion into transverse colon, 1 NG tube sutured into wrap, 1 midgut and 1 gastric volvulus). 7 cases required conversion to open fundoplication. Post-operative stay (median 5 days) did not change. There was no 30 day mortality, 6 patients have died since surgery; in none was the LF implicated.

CONCLUSION: We recommend a planned, measured approach to the introduction of LF with transition from mentorship to local consultant practice and finally to a trainee procedure under consultant supervision.

Year	2 Consultant LF	1 Consultant LF	Trainee LF
2003	4	0	0
2004	11	1	0
2005	10	11	2
2006	2	9	6
2007	8	8	18

P059 DOES PREEXISTING GASTROSTOMY AFFECT LAPAROSCOPIC NISSEN FUNDOPLICATION?

F. Fascetti Leon MD, P. Betalli MD, P. Midrio MD, P.G. Gamba MD, Pediatric Surgery, Department of Pediatrics, University of Padua

BACKGROUND: Gastrostomy (GS) placement is commonly performed without antireflux procedure when gastroesophageal reflux (GER) is absent. Recently, the isolated GS has been advocated even in case of demonstrated GER. Nevertheless a laparoscopic Nissen fundoplication (LN) could be subsequently needed. The study aimed to evaluate the possibility that the presence of a preexisting gastrostomy (PG) could affect the LN procedure.

MATERIAL/METHODS: Data of patients who underwent LN at Pediatric Surgery Department of Padua between Jan 2006 and Dec 2007 have been retrospectively reviewed. Patients were split up in to three groups: LN in presence of PG (group A); LN alone (group B); LN coupled to GS (group C). Data were collected regarding operative time, number of ports needed and intra-operative complication. Statistical analysis was conducted using t-student test.

RESULTS: In the selected period 25 patients underwent LN (5 group A; 9 group B; 11 group C), 14 M, 11 F, average age 7 years. 21 up to 25 were neurologically impaired. Neither conversion to open procedure nor the need to separate the PG occurred. No intra-operative complications were recorded. Statistical analysis showed significant difference between group A and B in terms of operative times (means: A 3,5 h; B 2,38 h) and no difference A and C (mean C: 3,4h). No significant differences were found between each group in terms of numbers of ports needed (means: A 4,2; B 4,5; C 4,6). Average length of stay for patients who received only LN was 2 days.

CONCLUSIONS: LN is a standard and safe procedure in both patients with and without PG. The PG prolongs the operative time in our series. These results could be influenced by the higher percentage of patients with thoraco-abdominal deformity among those having or needing a GS compared with patients who received an isolated LN. The absence of difference in terms of intra-operative complications and conversions in all groups showed the safety of a staged approach when properly indicated.

P060 SHORT-TERM RESULTS OF PEG AND LAPAROSCOPIC GASTROSTOMY. SINGLE CENTER EXPERIENCE

P. Betalli MD, F. Fascetti Leon MD, C. Dalle Nogare MD, P. Gasparella MD, P.G. Gamba MD, Pediatric Surgery, Department of Pediatrics, University of Padua

BACKGROUND: Percutaneous endoscopic gastrostomy (PEG) represents the gold standard procedure when a gastrostomy is required in pediatric patients. However the need of a simultaneous antireflux procedure or technical difficulties can lead to a surgical procedure. Laparoscopic Gastrostomy (LG) has emerged as a viable alternative procedure to the open Gastrostomy. The study aimed to evaluate the short-term results of both PEG and LG in a single center experience.

POSTER ABSTRACTS



MATERIAL/METHODS: Data regarding operative techniques, intra and postoperative complications, device replacement, outpatients clinic follow-up (1, 3, and 6 months) of patients who underwent gastrostomy placement at Pediatric Surgery Department of Padua between Jan 2005 to Dec 2007 have been prospectively collected. Patients were split up in to two groups: PEG (group A) and LG (group B). Statistical analysis was conducted using the fisher exact test.

RESULTS: Thirty two patients have been operated in the study period, 18 M, 14 F, average age 4,2 years. Twenty-four underwent PEG and 8 LG. All patients in group B received LG because of the need of simultaneous antireflux procedure. No intraoperative complications or conversions were recorded. No significant differences between two groups were found in terms of local complications at the f-up (p values: 1 month 0.25; 3 months 0.29; 6 months 0.3). Two among Group A patients (8.3%) underwent surgical revision (1 laparoscopic, 1 laparotomic) for device displacement. Four bumper detachments occurred during the first tube replacement.

CONCLUSIONS: PEG and LG represent safe alternatives for pediatric patients requiring gastrostomy. In our experience no significant differences occurred between two techniques in terms of local complications at the follow-up. The incidence of device displacement was low but not negligible in the PEG group. We believe that these two procedures are complementary and should be both currently handled in a pediatric surgery center.

P061 LAPAROSCOPIC CYSTOJEJUNOSTOMY IN A CHILD WITH A PANCREATIC PSEUDOCYST

Florian Obermayr MD, Guido Seitz MD, Kirschner Hans Joachim MD, Joerg Fuchs MD, Department of Pediatric Surgery, University of Tuebingen, Tuebingen, Germany

Pancreatic pseudocyst is a rare entity in children for which many approaches have been described. We report on the case of a 5-year-old boy with a pancreatic pseudocyst after blunt abdominal trauma. The patient's clinical and laboratory examination also revealed acute pancreatitis. The diagnostic workup included ultrasound and magnetic resonance cholangiopancreatography. Two large cysts were found at the tail of the pancreas. No injury of the pancreatic or bile duct was found. The child underwent successful laparoscopic cystojejunostomy. The patient was free of complaints after more than 2 years of follow-up. Laparoscopic cystojejunostomy in children with pancreatic pseudocysts may represent an alternative treatment option for large pancreatic pseudocysts.

P062 LAPAROSCOPIC TREATMENT OF MORGAGNI HERNIA

R. Riis MD, K. Stensrud MD, H. Skari PhD, K. Bjornland PhD, Rikshospitalet University Hospital

We have treated two patients with Morgagni hernia laparoscopically. Medical history is summarized below, and a video will be presented.

CASE 1: Term baby boy, b.w. 2900g, Downs' syndrome and hypothyreosis. The baby had abdominal distension and screamed more than normal. Upper and lower GI studies at two weeks of age did not display any pathology. Chest x-ray at two months of age showed bowels in the ventral part of the thoracic cavity.

CASE 2: Three year old boy with Downs' syndrome diagnosed with diaphragmatic hernia accidentally when chest x-ray was taken because of pneumonia after a tonsillectomy.

SURGICAL TECHNIQUE: A transabdominal approach was chosen for both patients. In one patient parts of the liver and oment were found in the hernial sack. The second patient had small bowel located in the hernial sack. The contents of the hernia were easily repositioned into the abdominal cavity. In both the hernial sack was extirpated, and the defect was closed with interrupted extracorporeal sutures. A video presentation will high-lighten details of the operative procedure. Both patients were extubated immediately after the operation, but needed re-intubation the same day. The second patient developed postoperative pneumonia. Both

were extubated day after three days and discharged one week after the operation.

CONCLUSION: Treatment of Morgagni hernia can be successfully performed laparoscopically. The anatomical structures are well visualised. Closure of the hernia can be done in many ways, but a transabdominal approach is easy and gives little inconvenience postoperatively.

P063 IMPACT OF PREOPERATIVE WEIGHT LOSS IN ADOLESCENTS UNDERGOING ROUX-EN-Y GASTRIC BYPASS

Go Miyano MD, Shelley Kirk PhD, Kathy Hrovat PhD, Shelly P. Frank PhD, Richard A. Falcone MD, Renee Jeffreys MS, Stavra Xanthakos MD, Chris Bolling MD, Meg Zeller PhD, Jenny Sweeney RN, Victor F. Garcia MD, Thomas H. Inge MD, Cincinnati Children's Hospital Medical Center

PURPOSE: To determine the relationship between preoperative weight change and magnitude of postoperative weight loss in adolescents 12 months after Roux-en-Y gastric bypass (RYGB).

METHOD: A retrospective analysis was performed of 76 patents (53F, 23M) undergoing RYGB (laparoscopic in 74, open in 2) at a pediatric medical center between May 2001 and November 2007. A preoperative weight behavioral weight management intervention began for all patients after October 2005 (n=20), while before October 2005, no specific preoperative intervention was used. For this analysis, we grouped subjects by % change in excess weight achieved before surgery (group 1, >5% gain, n=20; group 2, 5-0% gain, n=18; group 3, 0-5% loss, n=19; group 4, >5% loss, n=11). Surgical weight loss outcome at 1 year was analyzed as a function of 1) preoperative weight loss Group and 2) before (Period A) and after (Period B) October 2005. Analysis of variance with the Bonferroni post-test correction was used for multiple comparisons of sample means. Statistical significance was set at <0.05 for all analysis.

RESULTS: The mean patient age was 16.8 years (range 13-23). Groups 1-4 were demographically similar in age and race, and had similar initial body weight and BMI. The BMI at initial consultation was 58.6 kg/m² (43.4-95.4). The mean interval from the initial consultation to surgery was 6.2 months. For the entire cohort we noted a preoperative increase in excess weight of 1.47±7.50% (mean ± SD). The preoperative change in excess weight in Period A (n=56) was a gain of 2.57±7.48, while in Period B (n=20) subjects lost 1.61±6.80 (p=0.03). Postoperatively, for the cohort overall we saw a % excess weight loss (%EWL) at 12 months of 61.5±13.4 (23.1-92.7). When postoperative %EWL was stratified by preoperative weight change group we found that %EWL in groups 1, 2, 3, and 4 was 54.6±9.8%, 62.4±11.3%, 64.4±17.5%, and 68.5±10.5%, respectively. The %EWL was significantly greater statistically for Group 4 than Group 1 (p=0.035).

CONCLUSION: A dedicated preoperative weight management program can be effective in extremely obese adolescents. Preoperative weight loss is associated with significantly greater postoperative weight loss and should be encouraged in adolescents undergoing bariatric surgery.

P064 ISOLATED TORSION OF HYDATID OF MORGAGNI IN FEMALE: A RARE POSSIBLE ALTERNATIVE DIAGNOSIS IN ACUTE ABDOMINAL PAIN

Federica D'Asta MD, Alessandra Martin MD, Roberto Mattei MD, Caterina Morelli MD, Antonio Messineo MD, Anna Meyer Children's Hospital, Florence, Italy

OBJECTIVE: Hydatid of Morgagni (HM) is a common embryonal remnant of the Mullerian duct. In female, this benign, peduncolated cystic structure arises from the fimbriated end of the fallopian tube. As in male, torsion of HM is a possible event also in female, but in girls diagnosis is complicated by the anatomical position: Therefore, its incidence is probably underestimated. Torsion of HM around its pedicle may produce severe, acute abdominal pain. We describe a case of a symptomatic torsion of HM in a 12 year-old girl, in which diagnosis was possible only at laparoscopy.



POSTER ABSTRACTS

CASE REPORT: A 12 year-old girl developed sudden and severe abdominal pain on the right lower quadrant, accompanied by tenderness and nausea; no fever or vomiting were reported. Labs tests were normal. Abdominal ultrasound showed a moderately enlarged right adnexa with small follicular cysts; the possibility of a partial ovarian torsion was not excluded. In view of such evidence, patient underwent diagnostic laparoscopy, which showed HM twisted around its pedicle. Hydatidectomy was laparoscopically performed; pathology confirmed the necrotic appearance of the hydatid. Postoperative follow-up was uneventful with patient discharged in the second day post-op.

DISCUSSION: HM seems to be a rare cause of acute abdominal pain. Its symptoms are so similar to those of ovarian torsion and appendicitis that it should be considered in the differential diagnosis of acute abdomen, especially in cases in which no clear ultrasound data are present. Therefore, when this pathology is suspected, laparoscopy is always mandatory.

P065 TREATMENT OF THE LIVER ABSCESS IN CHILDREN. REGIONAL HOSPITAL OF PUCALLPA, UCAYALI – PERÚ

Armando Reque García MD, Luis Humberto Rengifo Navarrete MD, Regional Hospital of Pucallpa, Ucayali National University, Ucayali - Perú

INTRODUCTION/OBJECTIVE: The liver abscess in children is little frequent but of high morbidity. We presented our experience in the treatment of this disease.

MATERIAL/METHODS: Retrospective revision of clinical records on 11 patients of 2 to 17 years of age between years 2002 to 2007 and, analysis by means of descriptive statistic.

RESULTS: There were 7 boys and 4 girls with an average of age of 9,3 years (St. D: 5.8); the frequent clinical manifestations were fever and right upper quadrant pain (n=11); ultrasonography diagnosis was made in 10 patients and in one the diagnoses was intraoperative; in 8 patients (73%), the location of the abscess was in right lobe and in 3 (27%) in the left lobe; single in four patients the etiologic diagnosis performed, in 3 was pyogenic liver abscess by *E. aureus* and in one was amoebic abscess. The surgical treatment in 7 patients was necessary, thus, 4 underwent percutaneous drainage and aspiration with catheter placed under ultrasound guidance, 2 underwent laparoscopic drainage and in one was necessary to open drainage. One complication displayed and consisted in bleeding at catheter site and required laparotomy. The antibiotic treatment included the metronidazol and amikacina association in the majority of patients. The average of hospital stay was 14 days (St. D: 4.2) and there was no mortality. The follow up was made in 9 patients between 1 to 40 weeks (average of 8 weeks) not being complications delayed.

CONCLUSIONS: The percutaneous and laparoscopic surgical drainage is safe and offers fast recovery in children with liver abscess who do not respond to the preservative treatment.

KEY WORDS: liver abscess, children, treatment

P066 LAPAROSCOPIC PROCEDURES FOR CHOLEDOCHAL CYSTS

Edward Esteves MD, Bernardina B. Modesto MD, Kelly C. Paiva MD, Marcelo Calcagno MD, Celio C. Chagas MD, Roneyara Santos MD, Denny C Lima MD, Pediatric Surgery Division, University of Goias, Brazil

INTRODUCTION: The conventional treatment for choledochal cysts or cystic dilatation of the hepatocholedocus (CDHC) has been accomplished through laparotomy. There are already some reports on the laparoscopic removal in adults and children. Since we first described using the umbilical site for easier extracorporeal anastomosis in CDHC, we have developed new technical improvements with excellent outcome.

OBJECTIVE: The authors present the largest brazilian series of laparoscopic treatment of CDHC in children, describing novel technical details and analysing surgical results. Patients and methods:

20 children with CDHC (18 Todani type 1 and 2 type 4), aging 2 months to 12 years, were operated on laparoscopically. Twelve had presented previous colangitis. Three had large intrapancreatic cysts. Five prenatal diagnosis. Using 3 trocars (5-10mm umbilical, 3-5mm left flank, 3-5mm right flank), transparietal sutures to expose the hepatic hilum, using fine instruments (5, 3 and 2.5mm), the extra-hepatic biliary tree was dissected, sometimes facilitated by transecting the cyst. The hepatocholedocus was cut proximally at or just above the bifurcation and distally close to the Wirsung duct. The Roux-en-Y jejunal anastomosis was performed extracorporeally with a stapler or manually through the umbilicus, and the hepatojejunal end-to-end anastomosis with extra or intracorporeal stitches.

RESULTS: Average operative time 170 minutes. One with cirrhosis required postoperative intensive care. One needed blood transfusion. Feeding started on 2-3rd days, one had transient postoperative pancreatitis. Hospital stay 4-15 days. One postop cholangitis. Fistula in 2 cases, one required revision. The cirrhotic died after 4 months. After a 6 month to 6 year follow-up, the other children are asymptomatic with excellent cosmesis.

CONCLUSION: The complete laparoscopic treatment of CDHC can be done delicately and safely by an experienced surgical team, using 3 trocars, with wide visibility of the structures, favored by the extracorporeal jejunal anastomosis, resulting in fast recovery of normal activities and low perioperative morbidity.

P067 HOW SAFE IS THE PRESENCE OF PEG-RELATED POSTPROCEDURAL PNEUMOPERITONEUM

Haluk B Guvenc MD, Kemal Rasa MD, Sabriye Guvenc MD, Kutlay Karaman MD, Anadolu Medical Center, Departments of Pediatric Surgery and Surgical ICU, Kocaeli, Turkey

AIM: Percutaneous endoscopic gastrostomy (PEG) is a widely used method for providing enteral feeding access in pediatric patients. The presence of pneumoperitoneum after PEG placement is reported as a common finding and regarded as insignificant in the absence of clinical symptoms. There is relatively little information concerning the feasibility and safety of PEG and its possible complications in very small infants. Diagnosis and treatment of complete transection of the esophagus during a PEG attempt in an infant is reported in this study.

METHODS: A three-months old, 3.7 kg male was consulted in the ICU with complaints of respiratory distress and hypoxia in short notice, following PEG placement. The patient was under ventilatory support in the ICU, had peripheral cyanosis, and exerted mild abdominal distention. A contrast study was obtained by the gastroenterologist in the theater, immediately after PEG insertion via gastrostomy catheter which, mimicked image of distal dilatation of the esophagus. Chest roentgenogram showed wide pneumoperitoneum and pneumothorax on the right side. History revealed that he was born at 34 weeks of gestation, weighing 1480 grams and, required ventilatory support for three weeks because of RSV infection after which he developed tracheomalasia in an other hospital. He suffered swallowing dysfunction and was continuously on nasogastric tube feeding for three months.

MAIN RESULTS: Exploratory laparotomy revealed complete transection of the esophagus. An approximately 3.5 cm long esophageal segment was found as lying, inverted and inserted in the stomach. The distal portion of the esophagus was closed, the gastrostomy was replenished and a cervical esophagostomy was fashioned. The patient was successfully weaned and recovered from respiratory treatment and was started on gastrostomy feeding within a week. He is well at present and awaiting esophageal replacement.

CONCLUSION: A wide range of reports regarding PEG insertion may be obtained from the English literature which, states low incidence and significance of postprocedural pneumoperitoneum. Our case represents an extremely rare but highly morbid PEG-related complication, which emphasizes careful intervention especially in the very small infant.

POSTER ABSTRACTS



P068 MODIFIED PYLORIC TRAUMAMYOPLASTY: AN ALTERNATIVE SURGICAL PROCEDURE IN INFANTILE HYPERTROPHIC PYLORIC STENOSIS

Gabriela Ambriz-Gonzalez MSc, Teodoro Gutierrez-Jimenez MD, Alejandro Ortiz Arriaga MD, Claudia-Guadalupe Maciel-Morones MD, Sergio Montero-Cruz PhD, Alejandro Gonzalez-Ojeda PhD, Hospital Civil Juan I. Menchaca., Universidad De Guadalajara, Universidad De Colima

INTRODUCTION: Pyloromyotomy (PM) as described by Ramstedt has been the treatment of choice in Hypertrophic pyloric stenosis (HPS). The operation can be performed through a transverse upper abdominal (TUA) incision, a semicircumbilical (SU) incision or by laparoscopy. In 1987 Castañon described pylorotraumamyoplasty (PT) as a new technique through traditional open or laparoscopy surgery. We report a retrospective study with a modified TP technique with SU incision as an alternative procedure for HPS.

METHODS: Included all patients who underwent modified PT through SU incision from 2001 to 2005. Variable were age, sex, weight, operation time, complications. All patient underwent surgery by sedation with sevoflourane and caudal block. PT technique: A Babcock clamp is applied to the hypertrophic muscle, until disruption of the muscle. The procedure is repeated above first grasp to complete 4 grooves to anterior and 2 on the posterior wall of pylorus. Modified PT: Through a SU incision a Babcock clamp is introduced to retract superiorly the stomach, A second Babcock is introduced and applied longitudinally to the hypertrophic muscle, disruption of the muscle is felt and seen. It is not necessary to exteriorize the pylorus.

RESULTS: We performed 32 modified PT. Mean age was 34.7days (17-65), 75% were boys and 25% were girls. Mean weight was 3.3Kg (1.8kg-4.9Kg), Palpation of pyloric olive was positive in 93.7% and confirming by ultrasonography in 21.8% and by upper gastrointestinal series in 9.3% of patients. Operation time was 20minutes (12-35minutes). Mean oral fluids were at 7.5 hours. In 29 patients mean post surgical hospitalization times were 30hours (16-72) and in 3 patients was longer but no related with surgery. Complication: Vomiting 10%, umbilical hernia presented in 1patient, 1patient with haematocele.

CONCLUSIONS: PT as described by Castañon has been applied in some hospital in Mexico. In modified PT is not necessary to rotate pylorus to complete 4 grooves then it is easier to realize through SU incision. In modified PT we have not observed major complication as duodenal injury or mucosal perforation as in PM. PM through SU incision is safe but there are reports of higher complications rate. PM by laparoscopy is associated with excellent cosmetic appearance, and less pain, but special equipment and general anesthesia are required. PT through SU incision is an excellent option at hospital where there is not available laparoscopic equipment.

P069 LAPAROSCOPIC INGUINAL HERNIA REPAIR IN CHILDREN WITH TRANSPERITONEAL DIVISION OF THE HERNIA SAC

Ashwin Pimpalwar MD, Childrens Hospital University of Missouri, Columbia, Missouri.

AIM: To reviews the results of our new modified laparoscopic technique for repair of inguinal hernias (IH) in children.

MATERIAL: This is a retrospective case series of one surgeon during the period of January to August 2007. A total of 33 IH were repaired laparoscopically in 29 patients (5 girls, 24 boys, median 3 yrs, R: 1 m - 14 yrs). 23 children had unilateral IH, 5 children had bilateral IH, and 1 child had no IH.

TECHNIQUE: One 3 mm incision was made at the umbilicus for a one step camera port, two 2 mm incisions were made on either side of the umbilicus for working instruments without ports. Peritoneum of the hernia sac was circumferentially divided around the deep ring and was dissected away from the vas and vessels. The peritoneum was then closed using a 4-0 vicryl intracorporeal purse string suture completing the herniotomy which compares exactly to the open technique.

RESULTS: Mean operating time for unilateral IH repairs was 46.5 minutes (SD +/- 11.9), and 3 of these repairs had an umbilical hernia repair at time of closure. Mean operating time for bilateral IH repairs was 70.6 minutes (SD +/- 14.8) one repair had an umbilical hernia repair, and another one had an orchiopexy. There were no intraoperative complications. Two patients (7%) with a preoperative diagnosis of a unilateral IH were found to have bilateral IH upon laparoscopic exam. Postoperative pain was minimal in 26 patients (94%) from operation up until discharge. All patients were discharged home the same day of surgery. All of them were back to normal activity in the next 24 hrs. Follow-up to date is 1-8 months. There were no IH recurrences till date. The cosmetic results and parent satisfaction were excellent.

CONCLUSION: Laparoscopic IH repair with circumferential division of the hernial sac and purse string closure of the peritoneum is an excellent approach to repair IH in children. The surgical time is comparable to historical controls in open surgery. Children tolerate the laparoscopic procedure well and have less pain than with an open approach. There have been no recurrences to date compared to other laparoscopic techniques who report recurrence rates as high as 4.1%. The cosmetic result and parent satisfaction is excellent. We recommend this approach for all children with IH.

P070 LAPAROSCOPIC ANTERIOR GASTROPEXY FOR GASTRIC VOLVULUS

Concepción Barceló MD, Claudia Marhuenda MD, Josep Lloret MD, Hospital Vall d'Hebrón

INTRODUCTION: Gastric volvulus is rare in newborns and infants. It is often associated a delayed diagnosis with a high morbidity for the patient. We would like to present a case of an infant who was subjected to laparoscopic anterior gastropexy with a satisfactory outcome.

CASE: A 2-months-old male infant has since birth a history of recurrent crying and irritability with vomiting. He also presented a lack of weight. A upper gastrointestinal contrast studies was performed and it showed horizontalness of the stomach, the greater curvature of the stomach folded upwards and to the right with the antrum and duodenal cap directed downwards and backwards suggestive of an organoaxial volvulus of the stomach. A laparoscopic approach using 3 ports with 3-mm instruments was used in this case, performing an anterior gastropexy to fix the stomach to the anterior wall of the abdomen with an extracorporeal sutures. Postoperative outcome was very satisfactory, disappearing the symptoms and gaining weight correctly.

COMMENTS: It is important to make an early diagnosis in gastric volvulus cases to avoid complications as gastric ischemia or perforation. Laparoscopic gastropexy is an excellent technique to fix the stomach and improve the symptomatology of these patients. The extracorporeal sutures were used due to the small working place.

P071 LAPAROSCOPIC FUNDOPLICATION AFTER PREVIOUS OPEN ABDOMINAL OPERATIONS

Shawn D. St. Peter MD, Katherine A Barsness MD, Daniel J. Ostlie MD, George W. Holcomb III MD, Timothy L. Kane MD, 1) The Children's Mercy Hospital 2) Children's Hospital of Pittsburgh

OBJECTIVE: There have been multiple reports in the adult literature stating that previous open operations should no longer be considered a contraindication to the laparoscopic approach. However, there is little data on this topic in the pediatric population, particularly in patients with neonatal abdominal pathology unique to the newborn population. Therefore, we reviewed our experience with laparoscopic fundoplication after a variety of previous abdominal conditions and operations in the pediatric population.

METHODS: A retrospective chart review was performed on all patients undergoing laparoscopic fundoplication after a previous open operation between October, 2000 and December, 2007. Data collected demographics,



POSTER ABSTRACTS

comorbid conditions, previous abdominal operations, gastrostomy tube placement, time interval between the initial operation and laparoscopic fundoplication, conversions, complications, and follow-up.

RESULTS: In the study timeframe, 45 patients underwent laparoscopic Nissen fundoplication after an open operation during the study interval. Mean age was 41.3 mos (range 1-233 mos) with a mean weight of 14.3 kg (range 2.9-63.6 kg), and 31 were (78.9%) male. A total of 61 previous abdominal operations were performed (range 1-4). Previous open operations included: fundoplication/hiatal hernia (14), gastroschisis (5), resection for necrotizing enterocolitis (NEC)(5), drainage for NEC (4), duodenal atresia repair (3), omphalocele (2), congenital diaphragmatic hernia (2), jejunoileal atresia (2), Ladd procedure (2), and 8 other types with 1 each. Mean time between last open operation and laparoscopic fundoplication was 27.3 mos (range 0.5-147 mos). Mean operative time was 161 mins (range 73-420 mins). There were no conversions and 3 in house complications occurred (splenic hematoma, clogged gastrostomy tube and liver bleed). Early reoperations were performed in 2 patients (4.4%), one for bleeding on day 2 and the other for leaking gastrostomy on day 12. No redo fundoplications have been required with a median follow up of 3.0 years (range 1 mo-7.2 years).

CONCLUSIONS: Our data demonstrate that laparoscopic fundoplication after previous open operations is feasible and safe.

P072 LAPAROSCOPIC MANAGEMENT OF STOMAL PROLAPSE

B. Banieghbal MD, Department of Pediatric Surgery, Johannesburg General Hospital, Johannesburg, South Africa

INTRODUCTION: Colostomy and ileostomy are common neonatal and pediatric procedures, they done mainly for ano-rectal malformation (ARM), Hirschsprung's disease (HD) and necrotizing enterocolitis (HD). Pediatric stomas are nearly all temporary and they rarely have major complications. One of the common parental complaints is that of stomal prolapse, although this is usually just a nuisance in applying the stomal bag, fatality has been seen by the author due to delayed presentation of massive prolapse and bowel infarction. Prompt attention is therefore should be given to any significant prolapse.

The most common re-fashioning techniques include fixation of the bowel serosa to the deep fascia either by local stomal surgery or laparotomy. In some instances excision of excessive protruding bowel is also sufficient. A laparoscopic approach has not been reported in children, although there a number of articles in adult literature. We would like to present our experience with this technique.

MATERIAL/METHOD: Over a 3-year period, 43 stomas were fashioned; most (39 cases) were performed for HD, ARM and NEC. In this period, 4 infants developed significant stomal prolapse, including one ileostomy. One case was treated with excision of the prolapsed bowel and the remaining 3 were managed by laparoscopy. A 3-port approach is used with the scope port just below the xiphosternum. A 0-degree 5mm scope is used. The prolapsed stoma is reduced by the assistant, and this reduced intra-abdominal bowel serosa is fixed onto to posterior aspect of the anterior abdominal wall with multiple locking sliding sutures or trans-abdominal buried sutures. The assistant then releases the external pressure to see whether additional sutures are required. Once no further prolapse is seen the operation is terminated. A video of the procedure will be shown.

RESULTS: All procedure were completed within 30 minutes; the bowel was fixed with 3-0 prolene for sliding sutures and 4-0 absorbable suture material for the trans-abdominal fixation. All 3 patients were discharged the next day. Minor recurrence of prolapsed occurred in 2 but neither required re-do surgery. Two have had their stomal closed later and the remaining 8 year old with recto-vaginal fistula secondary to AIDS is awaiting correction of the fistula once ant-retroviral treatment is deemed effective.

CONCLUSION: Simple laparoscopic fixation of the stomal prolapse is shown to be effective for temporary stomas in children. The procedure is quick with minimal discomfort to the child and rapid discharge home.

P073 LAPAROSCOPIC TOTAL INTRACORPOREAL CORRECTION OF CHOLEDOCHAL CYST

Soo Min Ahn MD, Jong Wan Kim MD, Dept. of Pediatric Surgery, Hallym University Sacred Heart Hospital, Hallym University College of Medicine

BACKGROUND/PURPOSE: The laparoscopic correction of choledochal cyst is an attractive treatment option. However, even the skilled surgeons did not prefer the intracorporeal jejunojunal anastomosis due to the technical difficulties. The authors present the feasibility of laparoscopic excision of the choledochal cyst with total intracorporeal retrocolic Roux-en-Y hepaticojejunostomy and jejunojejunostomy.

CASES: Four and 3-year old girls diagnosed with type 1a and 1c choledochal cyst respectively were operated laparoscopically. Five ports were utilized: one 11-mm telescope port at the umbilicus, one 5-mm left subcostal port for liver retraction, two 3-mm operating ports on both sides of the umbilicus, and one left lower quadrant 5-mm assistant port. Cholangiograms were not performed. Under the laparoscopic guidance, the gall bladder and the dilated bile duct were excised completely. The ligament of Treitz was identified and the Roux limb was developed and brought retrocolic to the porta hepatis. The jejunojejunostomy was made intracorporeally using an EndoGIA through the umbilical port with hand-sewn reinforcement. The hepaticojejunostomy was created using interrupted 4-0 absorbable suture. The operating time was 360 and 270 minutes respectively. The intracorporeally fashioned jejunojejunostomy took 35 and 25 minutes. At follow-up of 4 and 1 month each, two patients are anicteric and symptom-free.

CONCLUSION: Intracorporeal retrocolic jejunojejunostomy during the laparoscopic correction of choledochal cyst is feasible. This procedure is no longer exceedingly challenging and time-consuming.

P074 LAPAROSCOPIC APPENDICITOMY: BURDEN OR BENEFIT; A SINGLE CENTER EXPERIENCE

Saad I AlMulhim MD, Firas Shalak MD, Saleem Ghantous MD, Salam Yazbeck MD, Saudi Aramco hospital

Although laparoscopic appendectomy (LA) is now a common practice, it has not yet become the standard of care because it has no clear advantage when compared to open appendectomy (OA) especially in cases of complicated appendicitis. Moreover the literature reports an increased incidence of post operative infections with LA.

AIM: to review our center experience with LA and to compare it to the literature.

METHODS: All LA performed between January 2004 and October 2007 were retrospectively reviewed for age, gross operative findings, pathology reports, operating time, length of hospital stay (LOS) and the time to resume regular diet and reach afebrile status.

All patients who presented with phlegmonous appendicitis were treated medically and had a secondary appendectomy.

RESULTS: A total of 151 children underwent LA during this period (60 females, 91 males) the mean age was 10.4 y (4-16). Forty five patients (29.8%) presented with perforated appendicitis (PA). Nine patients had normal appendix on pathology. The mean operative time was 58.7 min (56.1 min for simple appendicitis (SA) and 64.8 min for (PA). The mean IV narcotic analgesia duration was 12.2 hours for SA and 15.1 hrs for PA. LOS was 2.82 days for SA and 3.8 days for PA. Regular diet was tolerated 1.47 days post operatively for SA and 2.4 days for PA. The latter patients remained febrile for an average of 1.9 days. None of the patients presented with intraabdominal infection postoperatively. Seven patients (4.6%) presented with trocar site infection. Since the introduction of a routine LA in 2004, the OR time decreased from 114 min to 51min.

POSTER ABSTRACTS



CONCLUSION: This series confirms the safety of LA in all cases. The absence of intraabdominal infections and the low rate of wound infection noted with LA compare favorably with the open approach. This approach is not only advantageous for cosmesis, but also allows satisfying parents' requests, helps developing surgeons' laparoscopic skills and is cost effective.

P075 3D IMAGING AND REAL TIME NEEDLE GUIDANCE IN THE INTERVENTIONAL RADIOLOGY SUITE

John M. Racadio MD, John W. Rampton MD, Manish N. Patel DO, Kamlesh U. Kukreja MD, Neil D. Johnson MD, Cincinnati Children's Hospital Medical Center, Cincinnati, OH, USA

PURPOSE: The interventional radiologist has traditionally had to choose between procedural guidance with CT or with fluoroscopy. New C-arm technology allows the acquisition of "CT-like" images; this provides the anatomic detail of CT along with real-time guidance of fluoroscopy. Recently, the fluoroscopy and 3D imaging from a cone-beam CT-flat-detector C-arm unit have been combined with an integrated tracking and navigation system. We evaluated the procedural capabilities and clinical efficacy of this new technology.

METHODS/MATERIALS: All interventional procedures in which 3D bony and/or soft tissue data sets were obtained through rotational image acquisition (Philips FD20 flat detector angio C-arm) and an integrated needle tracking and navigation system was used (Philips XperGuide) were reviewed.

RESULTS: 75 percutaneous procedures were performed in 45 patients: 56 spine injections (pars interarticularis, facet, SI joint, epidural, neuroforamen, discogram), 6 drainages (trans-gluteal abscess, nephrostomy, chest tube, neobladder), 6 bone biopsies (tibia, femur, iliac wing, disc), 5 bone percutaneous therapies (orthopedic pinning, bone grafting, growth plate bony bar excision, RF ablation), 4 miscellaneous (celiac plexus blocks, trans-lumbar IVC C-line, extra-theclal fibrin glue injection for CSF leak). Mean age: 17 years (range 5 mos-50 years), 48% male. All procedures were performed successfully with the exception of two L5-S1 discograms in which patient anatomy precluded needle advancement into the disc space. In all cases 3D imaging provided additional information beyond that of comparable 2D fluoroscopy. The integrated needle tracking and navigation system enhanced procedural planning and execution in all cases.

CONCLUSIONS: By combining the 3D spatial understanding of CT, real-time visualization of fluoroscopy, and a tracking and navigation system, this technology provides live 3D guidance and thereby increases the procedural capabilities in the interventional radiology suite.

P076 LAPAROSCOPIC OVARY SPARING SURGERY (LOSS) FOR THE TREATMENT OF BENIGN OVARIAN NEOPLASM (BON) IN PEDIATRICS IS SAFE

Marcela Bailez MD, Aixa Reusmann MD, Ivonne Lenz, General Pediatric Surgery. Garrahan Hospital. Buenos Aires. Argentina.

AIM: Present our results and surgical technical details of LOSS in BON, based in our experience with this technique in the last 14 years.

Introduction: LOSS for the treatment of BON is a well known procedure in adult gynecology. Still very few reports support its effectiveness in pediatrics. This is the first report of a long term follow up of LOSS in pediatric patients with BON

METHODS/MATERIALS: Starting 1993, 30 patients with a mean age of 11.09 years (4-17y) underwent LOSS for the treatment of BON. Laparoscopic assisted procedures are excluded of the analysis and only complete laparoscopic treatment was evaluated. Seven (23,3%) patients had bilateral neoplasms. Four patients had had a previous contralateral open oophorectomy because of a mature teratoma. Three patients had bilateral LOSS (1 synchronous and 2 metachronous) with a total of 32 procedures and 33 ovaries. Preoperative selection included negative germinal and epithelial markers and compatible ultrasound patterns. Three ports were used. A 10

mm umbilical port and 2.5 mm : 1 suprapubic midline and the other in the lower quadrant opposite to the side of the tumor. The procedure consisted in opening the ovarian capsule with monopolar cautery and the bipolar sealer without opening the tumor, enucleating the tumor and preserving the ovarian tissue. A controlled aspiration of the fluid component after entering the right plane was undertaken in oversized tumors. Tumors were resected in a bag avoiding spillage through the suprapubic port. Data was obtained from prospective records used in our surgical gynecology clinic. One of the authors participated in all the procedures and regularly followed the patients with an annual US.

RESULTS: Mean diameter of the tumor was 65.4 x 49.5 x 45.4 (range 30 x 20 x 20 to 150 x 80 x 60 mm). Mean operative time was 107.8 min (40 to 145 min). Histology showed a mature teratoma in 93,7 % and a cystadenoma in 6.2 % of patients. None of the patients required reoperation for malignancy in a mean follow up of 5.03 years (range 1 month to 14 years)

CONCLUSION: 1) This evidence supports the safety of preserving the ovary laparoscopically in carefully selected patients with benign neoplasm in an adequate surgical environment 2) The diameter of the tumor doesn't predict gonadal resection 3) This strategy may prevent castration in a considerable percentage of patients with bilateral gonadal neoplasms.

P077 Abstract Withdrawn

P078 PARA OVARIAN MICROCYST TORSION PRESENTING WITH ACUTE ABDOMINAL FINDINGS

Umut Alici MD, Dilsad Demet MD, Baran Tokar MD, Eskisehir Osmangazi University, School of Medicine, Department of Pediatric Surgery, Eskisehir, Turkey

BACKGROUND: Paraovarian cysts appear in the broad ligament. It is very uncommon in children. Preoperatively determined cysts are usually large enough to be detected with ultrasound. Torsion of the cyst may occur, but if the cyst is very small, torsion can not be detected preoperatively.

CASE REPORT: A 13-year-old girl was admitted with acute abdominal findings in the right lower quadrant. Ultrasound showed a cyst with a 5 cm diameter in the right ovary and no other intraabdominal pathologies were determined. Laparoscopic exploration showed the ovarian cyst determined previously and also 4 paraovarian microcysts on the same side. The diameter of the cysts ranged between 3 to 5 mm, and one of the cysts had torsion with necrosis. Excision of all paraovarian cysts including one with torsion, and fenestration and internal layer extirpation of the ovarian large cyst were performed by laparoscopy. She was discharged in postoperative day 2 and did well in early postoperative follow up period.

CONCLUSION: Since paraovarian cysts do not have a pedicle, and expand into the broad ligament, torsion is usually not expected. The incidence of torsion was reported between 2.1% to 16%. Although paraovarian cyst is very rare in children; with this case report, we would like to state that a physician should have a high index of suspicion for torsion of paraovarian cysts, even for microcystic ones.

P079 LAPAROSCOPIC MONOLATERAL ADRENALECTOMY IN ISOLATED PRIMARY PIGMENTED NODULAR ADRENOCORTICAL DISEASE (PPNAD)

Riccardo Guanà MD, Giulia Masi MD, Roberto Gesmundo MD, Elisa R Bianco MD, Valeria Bucci MD, Erasmo Maiullari MD, Patrizia Matarazzo MD, Angela Pucci MD, Mario Morino PhD, Ferdinando Canavese PhD, Regina Margherita Children's Hospital, Turin - Italy; S. Giovanni Battista Hospital, Turin - Italy

INTRODUCTION: Laparoscopic adrenalectomy (LA) has become standard therapy for benign adrenal masses in children.

Primary pigmented nodular adrenocortical disease (PPNAD), is a pituitary-independent, primary adrenal form of hypercortisolism, in 90% of the cases associated with Carney disease.



POSTER ABSTRACTS

We report the case of a patient that we treated the last year in our department for an isolated PPNAD.

METHODS: A 16 years-old female in November 2007 was admitted to our Service with diagnosis of primary hypercortisolism. The patient presented hypercortisolism, complicated by cerebral venous thrombosis and papilledema, due to an hypercoagulability status; truncular obesity and low stature. CT scan demonstrated the adrenal glands as normal-sized with discrete irregularity of the left adrenal gland outline. A transperitoneal approach was used in this patient to remove the left adrenal gland with curative purpose; the girl was placed in a right lateral decubitus position, with a flank lift to laterally flex the spine and maximally expose the space between the costal margin and iliac crest. The adrenal gland was mobilized and the exposed adrenal vein clipped closer to the gland than to the renal vein.

RESULTS: Operative time was 60 minutes; Not early or late complications were observed; Patient was discharged on the fourth day after surgery; Early follow-up demonstrated the reduction of serum and urinary cortisol level, but ACTH values were still low (probably due to delayed hypophysis compensation); The diagnosis of PPNAD was then confirmed anatomopathologically.

CONCLUSION: Laparoscopic adrenalectomy offers safe and effective surgical treatment for many paediatric adrenal lesions and may be the procedure of choice for benign lesions. In our patient a longer follow-up is necessary to precisely value the course of ACTH levels.

P080 LAPAROSCOPIC RESECTION OF A MATURE CYSTIC OVARIAN TERATOMA IN A PREMENARCHAL PATIENT

Sonia I. Guzman-Martinez MD, Alfonso Galvan MD, Francisco Flores MD, Beatriz Soto MD, Rodrigo Davila MD, Jordi Puente-Espel MD, Weimar Maldonado MD, Hospital General "Dr. Manuel Gea Gonzalez"

BACKGROUND: Malignant germ cell tumors account for approximately 3% of childhood malignancies. Teratomas represent the most common histologic type of pediatric germ cell tumors, being the ovary the second most frequent organ involved. Teratomas represent 35% of these tumors. Objectives. Describe a non invasive approach for resection of cystic tumors involving the ovary in a pediatric patient.

METHODS: An 8 year-old premenarchal girl presented with abdominal pain. The patient had no history of previous illness and complained of an oppressive, intermittent abdominal pain at the right lower quadrant. At physical exam, an abdominal mass was found located in the lower abdomen. Tumor markers were negative. Abdominal ultrasound and computed tomography showed an abdominal mass with multiple fluid levels and calcifications dependent of the ovary, suggesting a mature ovarian teratoma.

CASE: The informed consent was obtained. Under general anesthesia, a laparoscopic approach with three port insertions, umbilical-10 mm, and two lateral 5 mm at the flanks, was performed. A tumor dependent of the left ovary was found. The borders were dissected, dividing and the infundibulopelvic ligament, ipsilateral fallopian tube and utero-ovarian ligament, which were subsequently ligated with a non absorbable suture. A sterile plastic was introduced to the abdominal cavity. The tumor was introduced inside the sterile plastic, the plastic was folded and sutured in its openings in order to produce a closed-bag. The bag with the tumor inside was pulled and directed to the 10-mm port. The port was extracted and the incision was opened by 1 cm on each side. The bag was partially exposed on the outside and opened in order to suction the liquid contents of the neoplasm, taking care not to break the bag in order to avoid spilling its contents to the abdominal cavity or abdominal wall. The mass was extracted carefully by pulling it with Kelly clamps. The patient was discharged on day 2 after surgery. We followed the patient for 16 months. The tumor was histopathologically diagnosed as mature cystic teratoma of the left ovary.

DISCUSSION. Historically, ovarian tumors have been resected with open surgery. Nevertheless, the laparoscopic technique represents a safe approach to resect cystic ovarian tumors suspected to be benign. This technique shows a safe alternative to avoid spillage of the contents.

Conclusions. The laparoscopic approach represents a feasible alternative that can be safely performed for suspected benign ovarian tumors with a cystic component in the pediatric population.

P081 CAN MORBIDITY ASSOCIATED WITH A "LEARNING CURVE" BE AVOIDED WITH A PROCTORSHIP SYSTEM?

Girish Jawaheer MD, Fraser D Munro MD, Gordon A MacKinlay MD, Departments of Paediatric Surgery, Birmingham Children's Hospital & Royal Hospital for Sick Children, Edinburgh

BACKGROUND: There is a paucity of data on how proctorship influences the "learning curve" in Paediatric Laparoscopic and Thoracoscopic Surgery. One surgeon started offering a new service in a Paediatric Surgical Unit in 2002 with the help of two proctors based in a different centre.

Aims: Our aim is to report perioperative outcome for the first five years of the service.

METHODS: A prospective database was set up and demographic data, operative details, intra-operative complications, conversion rate to open and post-operative complications were recorded. The performance of "therapeutic" procedures was divided into two phases. In phase I, procedures were performed with the proctors. In phase II, procedures were performed independently.

RESULTS: 507 laparoscopic procedures were performed on 484 patients (298 boys and 186 girls; age 0-16 years) from June 02 to Dec 07 (203 diagnostic and 304 therapeutic). In phase I, 12 therapeutic procedures were performed: appendectomy (n=2), splenectomy (n=3), cholecystectomy (n=3), fundoplication (n=2), endorectal pull-through (n=1) & repair of diaphragmatic hernia (n=1). In phase II, 292 therapeutic procedures were undertaken: Palomo (n= 19), Fowler-Stephens (n=36), appendectomy (n=43), excision/marsupialisation of ovarian cysts (n=15), debridement of empyema (n=32), gastrostomy (n=35), cholecystectomy (n=40), splenectomy (n=32), partial splenectomy (n=3), fundoplication (n=13), endorectal pullthrough (n=4), repair of diaphragmatic hernia (n=2), removal of disconnected VP shunts (n=6) and miscellaneous procedures (n=12). Conversion to open was 1/12 (8%) in phase I and 7/292 (2%) in phase II. There were no complications in phase I and 15/292 (5%) complications in phase II. Complication rate did not differ significantly between years 1 and 5. There was no mortality.

CONCLUSIONS: A laparoscopic service can be successfully set up whilst avoiding morbidity associated with a "learning curve". This data provides support in favour of a proctorship system.

P082 REDUCTION OF GASTRODUODENAL INTUSSUSCEPTION: A COMBINED ENDOSCOPIC AND LAPAROSCOPIC APPROACH

Claudia M. Mueller MD, Sami Youssef MD, Francoise Rypens MD, Denise Herzog MD, Pierre Ruest MD, Sathya Burjonrappa MD, Ste-Justine Hospital, University of Montreal

Intussusception is a common cause of intestinal obstruction in the young child which, if not quickly reduced, may become a surgical emergency. Cases of gastro-duodenal intussusception are rare with fewer than five having been reported in the surgical literature. We describe the case of an eight-month-old girl who presented with gastric outlet obstruction caused by an intussusception of the first portion of the duodenum into the stomach. The child's intussusception occurred shortly after repositioning of her gastrotomy tube, whose balloon had migrated into her duodenum. Repeated attempts at radiologic reduction under fluoroscopy as well as endoscopic reduction in the operating room resulted in failure. Successful reduction was accomplished with the simultaneous use of upper

POSTER ABSTRACTS



endoscopy and three-port laparoscopy. This is the first reported case of gastro-duodenal intussusception amenable to successful reduction by the combined minimally-invasive approach of endoscopy and laparoscopy.

P083 LUNG NODULES IN PEDIATRIC ONCOLOGY: THE ROLE OF THORACOSCOPY

Belinda Dickie MD, Roshni Dasgupta MD, Cincinnati Childrens Hospital Medical Center

PURPOSE: Video-assisted thoracoscopic surgery (VATS) has come to be an important tool in the work-up of lung nodules in the pediatric oncology patient. The accurate identification of lung nodules has important prognostic value and helps guide chemotherapy and overall management of the patient. The aim of this study was to look at our institution's experience of VATS resection of lung nodules compared to thoractomy resection in children with cancer.

METHODS: A retrospective review of pediatric cancer patients in our institution that had either a thoractomy or video-assisted thoracoscopy for resection of lung nodules between 1998 and 2007.

RESULTS: 50 patients were identified who underwent either a thoractomy or thoracoscopy for removal of a lung nodule. Patients presented with lung nodules during work-up for metastasis or for during routine surveillance. Patients were excluded if the lesion was a chest wall lesion; mediastinal lesion; a lobectomy was performed; or random wedge lung biopsies were performed for no specific lesion. In total, 21 thoractomies (5 VATS converted to open - conversion to an open procedure was because of the inability to identify the lesion via thoracoscopy in all cases), and 48 VATS were performed for discrete masses seen on pre-operative CT scans. 9 of these required pre-op localization with CT (wire localization (8), methylene blue (1)). These lesions ranged from 1 to 3.8 mm (mean 2.35mm) with the mean size of non-localized lesions was 9.76 mm \pm 0.86 mm. All resected specimens contained the nodule of interest. 46/68 (67%) of the specimens were metastatic disease, the other diagnoses included bronchiolitis obliterans (9), granulomatous diseases (6), atelectasis (4), and pneumonia (4).

DISCUSSION: Pre-operative localization with CT guidance and thoracoscopy can accurately identify non-visible lesions, which previously would have required a thoractomy. The use of minimally invasive techniques to accurately biopsy lung nodules in pediatric oncology patients allows for accurate diagnosis and rapid recovery which are essential for the favorable outcome of these patients.

P084 LAPAROSCOPIC REPAIR OF LATE-PRESENTING MORGAGNI AND BOCHDALEK HERNIA IN CHILDREN

C. Marhuenda MD, G. Guillen MD, J.A. Molino MD, A. Moreno MD, C. Barcelo MD, J.L. Peiro MD, J. Lloret MD, Department of Paediatric Surgery, Vall d'Hebron University Hospital, Barcelona, Spain

BACKGROUND: Delayed presentation of congenital diaphragmatic hernia is not usual. Primary laparoscopic repair is becoming the standard surgery in many centres. Different techniques have been proposed.

PATIENTS AND METHODS: We report one case of Morgagni hernia (MH) and one case of Bochdalek hernia (BH), with ages 2 and 6 years respectively, operated in the last year in our hospital. A three port technique (MH) and a four port technique (BH) were performed. In both cases, the diaphragmatic defect was directly sutured with interrupted nonabsorbable sutures, passed through the full-thickness of the anterior abdominal wall with a Reberden needle.

RESULTS: Both patients were discharged 48 hours after surgery. There were no intraoperative or postoperative complications. Control chest x-ray films showed no recurrence after six months.

CONCLUSIONS: Laparoscopic repair of late-presenting diaphragmatic hernias is safe and effective, offers a short hospital stay, excellent recovery and cosmetic results.

P085 THORACOSCOPIC RESECTION OF BENIGN INTERCOSTAL LIPOMA IN A 9 YEARS OLD BOY WITH HEMOPHILIA

Hubert Lardy MPH, K Braik MD, X. Sauvagnac MD, I. Gibertini MPH, C. Guerois, Hopital Gatien De Clocheville Chru Tours

A nine years-old boy with hemophilia presented with an anterior intercostal tumor of the thoracic cavity existing since a few years and painless. US and tomodesitometry showed a well limited tumor with radiologic appearance corresponding to a benign lipoma. There were a major part of the tumor developed inside the thorax without any compression and a minor part outside the thoracic cavity at the level of the second intercostal space. Surgical indication was decided and patient prepared concerning hematologic conditions. The procedure consisted on a thoracoscopic approach in order to dissect the endothoracic part of the tumor with ultrasonic dissection and cutting and further direct dissection of the extrathoracic part of the tumor with complete excision. Post operative recovery was uneventful and histology confirmed the benign nature of the tumor which was a lipoma, completely excised. This mini-invasive approach for an hemophilic patient is recommendable, avoiding consequences of thoractomy.

P086 BILATERAL SINGLE STAGE THORACOSCOPIC SYMPATHECTOMY FOR PALMAR HYPERHIDROSIS (SUPINE POSITION)

Hamid Reza Foroutan BA, M. Hassan Shahi BA, Nemazee Hospital, Shiraz University of Medical Sciences

Bilateral thoracoscopic sympathectomy is the procedure of choice for patients with severe intractable palmar hyperhidrosis. This procedure is usually performed in two stages or by changing the position from right up to left up. Here we present bilateral thoracoscopic sympathectomy in supine position in one stage. Patient laying in supine position, under general anesthesia through 7th intercostal space in anterior axillary line, the camera port was inserted. The other port was again inserted in anterior axillary line through 5th intercostal space. This gave excellent view and T2 to T4 sympathectomy were easily performed. The same was performed for the other side. The patient well tolerated the operation with excellent results. So we recommend this simple method in supine position for bilateral thoracic sympathectomy

P087 THORACOSCOPIC TREATMENT OF LUNG CONGENITAL LESIONS: REPORT OF THREE CASES

Giovanna Riccipetitoni, Monguzzi Gian Luca, Leva Ernesto, Enrica Caponcelli, Marcello Napolitano, Department of Paediatric Surgery, Department of Radiology

INTRODUCTION: Thoracoscopic surgery in newborns is one of the most challenging mini-invasive approach. It requires experienced anaesthetists and surgeons. Nowadays few patients have been treated with this technique. We report 3 cases that underwent to surgery between June 2007 and December 2007: 2 pulmonary sequestration (PS) and a congenital cystic adenomatoid malformation (CCAM).

CASE 1: BS, female, antenatal diagnosis at 22 weeks of gestational age (WGA) for suspected high growth CCAM of the right lung with mediastinal shift. The mother had steroid therapy for 12 days. The infant was born at 38 WGA with spontaneous vaginal delivery (SVD), her birth weight was 3 Kg. Angiotomography scan showed a mass in the right low lobe sized 4,5 x 3,5 cm with systemic blood supply. No evidence of bronchial structures within the mass was detected. The patient was labelled as affected by PS. She underwent to surgery, under left lung selective ventilation on her 7th day of life: thoracoscopic excision of the lesion was carried out with 4 trocars 3mm and 5mm one. She was extubated on day 4 post-operation and discharged on day 7.

CASE 2: SS, male, antenatal diagnosis at 21 WGA for suspected right



POSTER ABSTRACTS

CCAM and mediastinal shift. He was born at 40 WGA with SVD, his birth weight was 4 Kg. Computer tomography scan showed cystic areas within the right low lobe. No systemic blood supply was detected. He underwent to surgery, under selective ventilation of the left lung, at the age of 1 month: 4 trocar were used (two 3mm ones, a 5mm and a 12mm). Recovery was fast and uneventful; the patient was discharged on day 7 post-operation. **CASE 3:** MF, male, antenatal diagnosis at 21 WGA for suspected PS of the left lung which was confirmed at the fetal MR. He was born at 40 WGA with SVD; his birth weight was 3,7 Kg. Computer tomography showed a mass compatible with PS (6,5 x 3,9 x 2,8 cm). The patient underwent to thoracoscopic excision at 1 month of age. No complication has occurred. The infant was discharged on day 4 post-operation.

CONCLUSION: CCAM and PS treatment can be planned as a multidisciplinary approach thanks to antenatal detection. The thoracoscopic approach requires a high level anatomical knowledge that should be obtained with modern sophisticated imaging. High specialized surgical and anaesthetic skills are mandatory to be able to successfully perform thoracoscopy in newborns. By using this technique thoracotomy could be avoided and the patients have a faster recovery. We believe that it could become the treatment of choice in third level centres.

P088 CONSERVATIVE THORACOSCOPIC TREATMENT OF NECROTIZING PNEUMONIA

Fernando Montes-Tapia MD, Ulises Garza-Luna MD, Guillermo Martinez-Flores MD, Jesus Treviño-Alvarado MD, Aquiles Quiroga-Rivera MD, Idalia Cura-Esquivel PhD, Gerardo Muñoz-Maldonado MD, Maricela Zarate-Gomez MD, Valdemar Abrego-Moya PhD, University Hospital "Dr. José E. González" -Autonomous University of Nuevo León-Mexico

INTRODUCTION: Necrotizing pneumonia is a severe complication of pneumonia and is characterized by centers of necrosis in areas with lung consolidation.

MATERIAL/METHODS: We present 4 patients with a diagnosis of necrotizing pneumonia treated in a period of two years. 3 females and 1 male with ages between 2 and 156 months, a weight of 6 to 87 kg with previous symptoms of 4 to 7 days and all with antibiotic treatment. On admittance all the patients with more than 20.000 leukocytes in the complete blood count. Diagnostic x-ray and tomographic studies were made. Thoracocentesis was performed in two patients with a diagnosis of exudate and in 1 patient managed previously with a chest tube. Surgical technique: 2 five mm ports in 2 patients, and 3 ports in 1 patient, 30° optics. The average surgical time was 98 minutes (80-120). All the patients presented a bronchopleural fistula and decortication, pleurodesis with iodopovidone and positioning of two chest tubes were performed. The first chest tube was removed in an average of 6 days (5-11) and the second in an average of 16 days (12-26). Lung resection was not done in any patient. S.aureus, S.viridans, S.haemoliticus and Prevotella veroralis were cultured. Hospital discharge occurred an average of 17 days post operatively (13-27). Follow-up with normal X-rays for 7 to 36 months. There was no mortality.

CONCLUSIONS: Necrotizing pneumonia is a pathology that has increased its incidence, mainly by resistant microorganisms. Surgical treatment oscillates around 66% in pediatric patients, usually requiring resection of lung parenchyma. All our patients were subjected to early thoracoscopy and we decided on conservative treatment of necrotic lesions, allowing recovery of the lung parenchyma without performing lung resections or fistula closure. Conservative treatment is based on the fact that lung parenchyma presents its maximum development around 2 years and persists for 8 years, so repair mechanisms are more accelerated allowing their integral restitution as is visible on follow-up x-rays.

P089 ENDOSCOPIC DIAGNOSIS AND TREATMENT OF RECURRENT TRACHEOESOPHAGEAL FISTULA

Burak Tander MD, Mehmet Yazici MD, Ender Ariturk MD, Ferit Bernay MD, Ondokuz Mayıs University, Department of Pediatric Surgery

AIM: We present the endoscopic repair of a recurrent tracheoesophageal fistula (TEF) in a 4 year old boy.

CASE REPORT: The patient had a primary repair of esophageal atresia (EA) and TEF. Several months after repair, he had recurrent cough and respiratory infections. Cineesophageal examination revealed a tiny TEF. To make the definitive diagnosis, simultaneous esophagoscopy and bronchoscopy were made. Bronchoscopically, methylene blue was injected through a catheter inserted into the fistula stump. Immediately thereafter, a flexible esophagoscopy was made and the methylene blue was seen on the esophageal mucosa. A re-bronchoscopy was performed and fibrin-glue was injected through the catheter to the fistula tract. The patient had an uneventful postoperative course. One year after surgery, he had no cough and no respiratory infection, and a normal growth and development.

CONCLUSION: Simultaneous esophagoscopy and bronchoscopic examination is a useful diagnostic tool for the recurrent TEF after EA repair. Application of fibrin glue may be beneficial especially in tiny recurrent fistula.

P090 LAPAROSCOPIC NEPHRECTOMY. ADVANTAGES OF TECHNIQUE IN INFANTS AND NEWBORNS

Svetlana Ionouchene MD, Nikolay Michaylov MD, Vladimir Novozhilov PhD, Scientific Center of Medical Ecology of East Siberian Research Center of Russian Academy of Medical Sciences. Irkutsk City Children's Hospital.

In spite of appearance of new instruments, equipments and new surgical techniques, the amount of laparoscopic procedures in infants remains limited. Some anatomic and physiologic features in those babies may complicate operations, and oblige us to give more attention to control and keep air exchange function during procedures. Moreover, it is necessary in addition to manual skills, to use some special instruments and equipment that takes infant laparoscopic procedures out of a routine category.

Nevertheless, some advantages of laparoscopic nephrectomy technique in infants which we present allow us to recommend this approach as the method of choice in some renal pathology in infants and newborns. During the last 2 years using laparoscopy we removed 9 multicystic dysplastic kidneys at our Center. All babies were full term. The mean age p was 5 weeks (3-9 weeks) at the time of the procedure, mean body weight - 4 130 gr. (3 750 - 5 230 gr.). 5 out of the 9 removed kidneys were located at left side. The average size of removed kidneys was: length from 30mm to 70 mm, width from 25mm to 40 mm. During the procedures we noted following technical advantages in infants in comparison with older children: Troacarlless approaches for instruments are easy to do and for exchange of instruments if necessary; We did not need more than 2 instruments at the same time; Wide mobilization and back fixation of colon are not necessary; Kidney mobilization is easy enough; We did not need clip application, just coagulation of vessels; Easy mobilization of the ureter without any additional peritoneum cutting; Possibility of extraction of nonfragmented kidney. Mean duration of the procedure was 47± 8 min including changing babies position. All babies needed postoperative analgesia just once and all of them were discharged on a next day after procedures. In all cases we observed good aesthetic result

P091 LAPAROSCOPIC COLECTOMY IN A PATIENT WITH ULCERATIVE COLITIS AND CIRRHOSIS

Richard G. Weiss MD, Sabino Zani MD, Connecticut Children's Medical Center and University of Connecticut School of Medicine, Hartford, CT, USA

Total proctocolectomy with ileoanal pouch reconstruction is the standard for pediatric patients with severe ulcerative colitis who fail to respond to maximal medical therapy. There are many reports of

POSTER ABSTRACTS



this procedure performed with a laparoscopic approach. Primary sclerosing cholangitis is an extraintestinal manifestation of ulcerative colitis which may progress to cirrhosis and the need for liver transplantation. Patients undergoing major operative procedures who have cirrhosis, portal hypertension, and coagulopathy are at increased risk for bleeding and progressive liver failure. A seven year old boy was admitted to the hospital with a flare of ulcerative colitis. He had previously failed maximal medical therapy, and had been scheduled for elective colectomy. His diagnosis had been made at age three, and he was also known to have sclerosing cholangitis. A recent endoscopy revealed esophageal varices. An ultrasound showed ascites. He was mild to moderately coagulopathic. This was able to be partially corrected, and he subsequently underwent a laparoscopic subtotal colectomy with ileostomy. Macronodular cirrhosis was noted at the time of operation. There were no intraoperative or postoperative complications. The patient's overall condition is now significantly improved. Successful major laparoscopic surgery is possible in pediatric patients with cirrhosis, portal hypertension, and coagulopathy.

P092 A NEONATAL LAPAROSCOPIC LADD'S PROCEDURE CAN SAFELY BE PERFORMED EVEN IF THE BOWEL SHOWS SIGNS OF ISCHAEMIA

B.T. Adikibi MD, C.L. Strachan MD, G.A. MacKinlay MD, Royal Hospital for Sick Children, Edinburgh, UK.

INTRODUCTION: We describe two cases of neonatal malrotation with volvulus treated laparoscopically in our institution.

CASE 1: A term baby girl was admitted from home on day three of life with malrotation and volvulus. On inspection laparoscopically the caecum was seen lying in a subhepatic position to the left of the midline. The small bowel was lying on the right and there was a 180 degree rotation of the bowel. The rotated bowel was viable and of good colour. The bowel was derotated and Ladd's bands divided together with broadening the root of the mesentery. She was up to full feeds by the second post-operative day and was discharged home on the third day post surgery. On review in clinic 3 months later, she was thriving and feeding well with no problems

CASE 2: A baby boy presented with malrotation and volvulus on day eleven of life. At laparoscopy there was free chyle in the peritoneal cavity and a mid-gut volvulus with ischaemic appearing bowel (with the exception of stomach duodenum and descending colon). The bowel was derotated, the ischaemic bowel returned to a healthy colour and Ladd's bands were divided and the root of the mesentery broadened. On day two post-operatively he was commenced on feeds (expressed breast milk) and by day four post-operation the baby was tolerating full feeds. On review 6 months later he was doing well and thriving.

CONCLUSION: The use of minimally invasive techniques in children is increasing. In our unit we have performed two laparoscopic Ladd's procedures, both by the same surgeon. Neither of these children have had any complications related to the operation, no need for reoperation and on follow up are thriving with excellent cosmetic results. We feel that laparoscopic treatment of malrotation with volvulus is a feasible procedure and should be performed where the expertise and equipment are available.

	CASE 1	CASE 2
Age at Operation	4 Days	12 Days
Operative Time	60 mins	60 mins
Feeds Started	Day 1	Day 1
Full Feeds	Day 1	Day 1
Discharge	Day 1	Day 1

P093 LAPAROSCOPIC DUODENAL DIVERTICULECTOMY FOR DIVERTICULITIS IN ADOLESCENCE: A CASE REPORT

G. Lisi PhD, M.T. Illiceto MD, N. Marino MD, D. Di Renzo MD, G. Lombardi MD, P. Lelli Chiesa MD, N. Pappalepore MD, Pediatric Surgery Unit, University "G. d'Annunzio" of Chieti-Pescara and Gastroenterologic Unit, "Spirito Santo" Hospital of Pescara, Italy

INTRODUCTION: The duodenum is the second most common site of intestinal diverticula, after the large bowel. Duodenal lesions are usually occasionally evidenced in adults during barium swallow (2-6%) or upper tract endoscopy (9-23% of ERCP). Nearby 10% of cases present with inflammatory onset (diverticulitis or diverticular abscess, depending on the diverticulum localization), duodenal perforation or bilio-pancreatic complications (juxta-papillary diverticula). In childhood, symptomatic diverticula are extremely rare and, to the best of our knowledge, this is the first report of a pediatric laparoscopic duodenal diverticulectomy.

MATERIALS/METHODS: The Authors describe the case of a 13 yrs old girl presenting recurrent epigastric pain and significant weight loss (10 Kg in 2 months), with radiologic and endoscopic evidence of a large extraluminal duodenal diverticulum, localized along the antero-lateral wall of the second duodenal portion, lined with inflamed mucosa; two smaller diverticula were immediately proximal to the previous lesion. A cycle of PPI therapy was performed, with recurrence of symptoms after a short period of pain relief.

RESULTS: Considering the clinical history and the position of the larger diverticulum, a laparoscopic diverticulectomy (linear 30 mm EndoGIA stapler) was performed, without any intraoperative complication. The remaining two smaller diverticula, asymptomatic and lined with normal appearing mucosa, were left untouched; the p.o. period was uneventful. After a follow up of 12 months, the girl is symptoms-free; an upper endoscopy will be planned in case of symptoms recurrence.

CONCLUSIONS: Extraluminal duodenal diverticula are rare lesions in childhood; when evidenced in asymptomatic patients they do not require any surgical treatment. In symptomatic cases, the more adequate surgical solution depends on their localization. When evidenced along the anterior duodenal wall, far from the papilla, laparoscopic diverticulectomy represents a simple and safe option; when this option is considered, multiple diverticula are present and the symptomatic ones are not clearly identified extraluminally, an intraoperative endoluminal endoscopic control would be advisable. Diverticula localized posteriorly or iuxtapapillary, are best treated with an open approach with duodenal mobilization, particularly when complicated with inflammation or perforation.

P094 LAPAROSCOPIC SURGERY OF THE SPLEEN

Giovanna Riccipetitoni, Marco Gambino, Monguzzi Gian Luca, Pansini Andrea, Salvatore Zirpoli, Department of Paediatric Surgery, Children's Hospital, V. Buzzi, Milan, Italy

INTRODUCTION: The advantages of laparoscopic toward open splenectomy are still debated. Limits seemed to be related to the spleen size and to the specific disease. Nevertheless the analysis of the recent data from the Italian Registry (IRLSS) says that laparoscopic splenectomy may represent the gold standard treatment. The aim of this study is to review our experience in 14 patients affected by massive splenomegaly.

MATERIALS/METHODS: A total of 14 patients (7 male, 7 female), aged between 6 to 18 year, underwent to laparoscopic splenectomy for massive splenomegaly. The indications for surgical treatment were: hematologic disease in 12 patients (5 beta-thalassaemia and 7 hereditary spherocytosis) and giant splenic cysts in the other 2 cases (1 affected by a retrohilar cyst and 1 by a multiple congenital cysts). The main spleen longitudinal diameter (SLD) ranged between 15,2 to 26 cm; the measures were taken with ultrasound examination. Complementary laparoscopic cholecystectomy was required in 6 patients affected by biliary stones. In our surgical approach a supine decubitus was preferred; we believe it is more indicated for large spleen because it assured a better view and a



POSTER ABSTRACTS

safer control of the hilar vessels. Moreover this procedure is particularly recommended when a complementary cholecystectomy is needed. Laparoscopic splenectomy was carried out using four trocars: two 10-12 mm (umbilicus and left midaxillary area) and two 5 mm (left subcostal and subxiphoid area). Spleen ligament and short gastric vessels were divided with harmonic scalpel or with Ligasure®; spleen vessels were sectioned with endovascular stapler. The whole spleen was extracted: in 10 patients through a small Pfannenstiel incision, in 2 using a lap disk and in 2 through a large umbilical endo-bag.

RESULTS: All the splenectomy were laparoscopically completed in a mean time of 180 minutes (160-260). Neither intraoperative or postoperative major bleeding occurred; nevertheless 2 patients required a postoperative transfusion of about 200 ml and 1 had a transient fever during the second day. Oral fluids were started the second day after the operation and the median hospital stay was 3 days.

CONCLUSIONS: We think that laparoscopic splenectomy is a safe procedure even in children with massive splenomegaly. Surgeon's experience and patient's position have a basic role in this procedure, the supine approach is preferred because it allows a better control of the splenic hilum.

P095 A RETROSPECTIVE AUDIT OF THE THREE STANDARD PROCEDURES USED IN THE SURGICAL TREATMENT OF INFANTILE HYPERTROPHIC PYLORIC STENOSIS

Julia R. Fishman MD, Simon Clarke MD, Nicholas Madden MD, Munther Haddad MD, Chelsea and Westminster NHS Foundation Trust, London

BACKGROUND: Congenital hypertrophic pyloric stenosis is surgically treated through either a minimal access (circumbilical or laparoscopic) or a right upper quadrant incision. Cosmesis is superior with the former. Published data suggest there is little significant difference in physiological outcome between all three.

AIMS: To audit the outcome of three surgical techniques currently performed in our unit for congenital hypertrophic pyloric stenosis: laparoscopic (LAP) open RUQ and circumbilical.

METHODS: We performed a retrospective case note review between November 1999 and December 2007 inclusive. All patients who underwent a pyloromyotomy were identified retrospectively from the electronic patient record & theatre log book. Ethical approval was obtained. Outcome measurements included: time to full feeds; time to discharge (days); Operative time (incision to dressing) (mins); Post operative emesis & complications.

RESULTS: 191 patients had an operation for Pyloromyotomy. Complete notes were obtained on only 76 patients due to fire damage (26 RUQ; 19 LAP with 2 converted to UMB; 30 UMB) Operative time (mins) revealed a significant shorter time for the RUQ than the UMB/LAP { $P=0.009$ [Mean OR: 31.2 (SD 10.6); UMB: 39.4 (SD 11.4); LAP 36.1 (SD 21.8) $P=0.52, 0.35, 0.009$]. There was no significant postop. difference in reaching full feeds between all 3 groups [Mean OR 2.5 (SD 1.48) UMB 2.79 (SD 1.52) LAP 2.46 (SD 0.97) $P=0.49, 0.93$]. There were 3 perforations (1 UMB & 2 LAP) and an increased number of wound infections in the UMB group with the latter showing no statistical significance.

CONCLUSION: The RUQ procedure had a significantly shorter operating time than the UMB & LAP approach but with no associated significant difference in length of stay or time to full feeds. Vomiting may be less in the LAP group. The RUQ had no perforations though has an inferior cosmetic result. There appears to be little difference in physiological outcome between the UMB and the LAP. We believe that despite the LAP having a steeper learning curve, subjectively is cosmetically superior. The LAP vs UMB long term follow up regarding satisfactory wound appearance is currently being investigated.

P096 ATYPICAL PRESENTATIONS OF MECKEL'S DIVERTICULUM DETERMINED BY LAPAROSCOPIC EXPLORATION

Ozgur Aktas MD, Dilsad Demet MD, Baran Tokar MD, Eskisehir Osmangazi University, School of Medicine, Department of Pediatric Surgery, Eskisehir, Turkey

PURPOSE: In this study, we present three cases having atypical presentation and unusual findings of Meckel's diverticulum (MD) during laparoscopic exploration.

CASE 1: A 2-year-old boy was admitted with a large lower abdominal mass. Ultrasound showed a large bilobular, thick-walled, fluid-filled anechoic cystic structure with internal echos. A round radiopacity located inside of the hypodense cyst was determined on CT scan. At laparoscopy, a MD and a preperitoneal cystic mass (9x7x5 cm) were found. The perforated tip of the diverticulum was found inside of the cystic cavity. Diverticulectomy, cyst decompression and partial cystectomy were performed. The microscopic examination confirmed the diagnosis of MD with a heterotopic pancreatic tissue and the benign pseudocyst formation of the abdominal wall.

CASE 2: A 3-year-old boy was admitted with acute abdominal findings. Ultrasound showed a very long and thick-walled, blind-ending tubular structure in the right lower quadrant. At laparoscopy, a 16 cm long, inflamed thick wall MD was determined in terminal ileum. A trans-umbilical diverticulectomy was performed.

CASE 3: A 10-year-old boy was admitted with intestinal perforation findings. He was autistic, and although the physical findings were very serious, he was not complaining. Ultrasound showed a free fluid in the abdominal cavity and intestinal dilatation. At laparoscopy, a free fluid with green color was aspirated in abdomen. An intestinal perforation and an intraluminal mass just under the perforation were determined in 10 cm proximal to ileocecal valve. Exploration of intestinal segments determined a MD in 30 cm proximal to the perforation. A trans-umbilical meckel's diverticulectomy and resection and anastomosis of the perforated intestinal segment with the intraluminal mass were performed. The mass was an ingested hard sponge-like foreign body with the diameter of 6x4x3 cm. It was obstructing the intestinal lumen.

CONCLUSION: Exploration of abdomen by laparoscopy provides a well demonstration of the pathology and associated findings. MD doesn't always present with typical findings. A rare presentation and unusual associated findings as in our cases could be observed.

P097 Abstract Withdrawn

P098 NEONATAL ISOLATED GASTRIC POLYP: A RARE ENTITY IN NEWBORN

Agostino Sergio MD, Donato Servedio MD, Beniamino Natale MD, Ospedale "Di Venere"-Sez di Chirurgia Neonatale-UTIN-Dip Materno-Infantile

Gastric polyposis is a rare condition in pediatric population, exceptionally observed in neonatal age. Sometime it's an incidentally feature, during endoscopic procedure performed for other causes. In the other cases can occasionally result for gastric outlet obstruction or gastric bleeding. The polyps can be multiple, situated on gastric fundus, and they can be associated at other polyposis like familial adenomatous polyposis, Peutz-Jeghers syndrome or diffuse juvenile polyposis. In this cases they have malignant potential and should be removed. In the other case they are solitary polyps, hyperplastic-inflammatory, localized in antral sites. In this case they haven't malignant potential and need not to be removed.

We present a case report of a newborn arrived at our attention in neonatal surgery division on 6th day of life for alimentary vomiting from possible pre/post-pyloric stenosis. The initial suspected condition causing alimentary vomiting (as hypertrophic pyloric stenosis or duodenal stenosis) was

POSTER ABSTRACTS



not confirmed at US and contrastographic exam. So he performed an endoscopic exam that showed an important gastritis and II° esofagitis. After one month of symptomatic successful anti-H2 therapy, we found an isolated antral polyp that was classified as hyperplastic-inflammatory on histologic assay. The last endoscopic control after two months of the same therapy, showed the total regression of polypoid lesion, with normalization of gastric and esophageal mucosa.

BIBLIOGRAPHY: The Clinical Spectrum of gastric polyps in pediatrics: an 18 year hospital based analysis. Attard TM, et al Gastroent 97:298-301,2002; Antral mucosal valve: a rare cause of gastric outlet obstruction in newborn. Prata A et Al. JPS 2006 Apr; 41(4):856-8; Gastric polyps and nodules in children receiving long-term omeprazole therapy. Pashankar DS et Al. JPGN 2002 Nov;35(5):658-62

P099 PERITONEAL INCLUSION CYST: DIAGNOSIS AND LAPAROSCOPIC MANAGEMENT

Amulya K. Saxena MD, Lutz Stroedter MD, Michael E. Hoellwarth MD, Department of Pediatric Surgery, Medical University of Graz, Austria

BACKGROUND: Peritoneal inclusion cysts are less well-recognized entities on imaging of the female pelvis. Peritoneal inclusion cysts or peritoneal pseudocysts and inflammatory cysts of the pelvic peritoneum present a wide range of variations during imaging and can be confused with various adnexal masses of the female pelvis. The correct diagnosis allows conservative treatment, however symptomatic cysts require a surgical approach.

PATIENT/DIAGNOSIS: A 17-year female patient presented with severe abdominal pain localized in the right lower pelvic area. After clinical examination, ultrasonography revealed a large cystic mass localized around the right ovary. MRI demonstrated the extension of the cyst from the right pelvis to the hepatic flexure along the paracolic gutter. A laparoscopic approach was considered for management of the cyst.

SURGICAL APPROACH: Resection of the cyst was commenced at the caudal end adjacent to the cecum using Ligasure(TM) and followed along the lateral edge of the ascending colon. The peritoneum was incised and the dorsal wall of the cyst was resected with care taken to avoid injury to the ureter. The dissection was completed with freeing of the cranial end of the cyst close to the caudal edge of liver. The cyst was punctured and cystic fluid was aspirated, after which the cyst wall was removed in a specimen retrieval bag.

CONCLUSION: Escherichia coli was diagnosed in the cyst aspirate and infection of the cyst was responsible for abdominal symptoms in the patient. Pathology also result showed chronic recurrent inflammatory reaction of the cyst wall. Recurrent infections of inclusion peritoneal cysts lead to inflammatory adhesions and a loss of border demarcation with neighboring tissue. Inflammatory adhesions warrant a cautious and meticulous laparoscopic approach during cyst resection in order to avoid injury to the neighboring structures and/or spillage of contaminated cystic fluid during dissection.

P100 NEONATAL LAPAROSCOPY IN NEWBORN AFFECTED BY NEC: CASE REPORT

Silvana Federici MD, Lorenzo De Biagi MD, Alberto Ratta MD, Maurizio Mordenti MD, Vincenzo Domenichelli MD, Gabriella Pelusi MD, Francesco Italiano, Pediatric Surgery Unit – Infermi Hospital, Rimini, Italy

BACKGROUND: Necrotizing enterocolitis is a pathology in which there is a lack of specific criteria to allow an early diagnosis that should be the best condition for the treatment. Sometimes laparotomy is not necessary but, some others, surgery is the treatment of choice that best fits with the clinical deterioration of the newborn. According with other authors, we describe a case in which the laparoscopic approach has given us the indication, by direct vision of the conditions of the bowel, for the need of mini-laparotomy.

CASE REPORT: We report the case of a preterm baby of 32 weeks of gestational age and 1,6 Kg of weight with a condition of important bowel distention, a tender abdomen, fecal vomiting and no sign of pneumatosis or

perforation on X-ray. The baby underwent laparoscopy on day 6 of life. The indication of laparoscopy was a presumed diagnosis of NEC with a clear degeneration of general conditions not responsive to medical treatment. A 5mm Scope was inserted through an umbilical incision under direct vision with 8 mmHg pressure and 0,5 ml/min flow rate of CO2. The abdominal distension reduced the working space that was anyway enough to visualize the whole bowel searching for (necrotic loops) zones of necrosis. The working space was enlarged by a gentle traction of the trocar ensured to the fascia by a purse string. Peritoneal fluid was collected. The laparoscopic exploration resulted in the decision of performing stomas with resection of a ileal loop of 15 centimeters. Through the stomas it was possible to perform a bowel toilette with several irrigations. The post-operative period was uneventful. Feeding was started after 72 hours. Recanalization of bowel was performed after 1 month.

CONCLUSIONS: Laparoscopy can provide, in our opinion, important indications regarding intestinal viability. A direct inspection of bowel allows to select to laparotomy or mini-laparotomies those cases in which a diagnosis of NEC is not clear. On the one hand this procedure avoids laparotomy whenever it isn't necessary, and on the other hand, thanks to a magnified vision, allows to indentify necrotic loops or covered perforations.

P101 LAPAROSCOPIC MANAGEMENT OF INTUSSUSCEPTION IN CHILDREN

Guibin Li MD, Qiu Yun MS, Long Li MD, The 5th Central Hospital of TianJin

OBJECTIVE: To evaluate the value of laparoscopic surgery application in treating children with intussusception. Methods The patients with intussusception received laparoscopic surgery and conventional surgery were analyzed retrospectively between January 2004 and December 2007. The operation was given on conditions that air enema failed or recurrence more than three times. The detail during operations and the incidence of complication were analyzed compared to the conventional laparotomy.

RESULTS: In five years, twelve patients were treated with laparoscopy and ten patients underwent an open reduction. Compared to conventional laparotomy (57;±23min), the operation time in laparoscopy group (53;±26min) was not longer than it. However, the bleeding was significantly decreased in laparoscopic group. As well, the complications after operation were significantly reduced in laparoscopic group. Moreover, the hospital stay was significantly shorter in the laparoscopic group (5.3d;±3.2d) than the conventional group (7.8d;±2.6d).

CONCLUSIONS: The laparoscopic approach, that is, minimally invasive, less bleeding, shorter hospital stay, few complications, and cosmetic results. so laparoscopic surgery can offer a safe, effective alternative to intussusception in children.

P102 ROUX-EN-Y GASTRO-JEJUNAL ANASTOMOSYS IN NIC

Girolamo Mattioli MD, Giovanni Rapuzzi MD, Edoardo Guida MD, Vincenzo Jasonni MD, Pediatric Surgery, Giannina Gaslini Research Institute, University of Genova, Italy.

BACKGROUND: Neurologically impaired children (NIC) have a high risk of recurrence of gastroesophageal reflux (GER) after fundoplication. The use of post-pyloric feeding tubes are suggested in case of gastric emptying disorders, however the dislocation of the tubes and the difficulty in feeding management suggested for more aggressive procedures. The total esophagogastric dissociation (Bianchi's TEGD) is an alternative to the simple fundoplication and the laparoscopic gastric bypass is a frequently performed procedure for morbidity obesity and its use is suggested to improve gastric outlet. Aim of this paper is to present a preliminary experience on the Roux-en-Y gastro-jejunal bypass, associated with Nissen fundoplication and gastrostomy, to treat and prevent GER in NIC and gastric emptying disorders.

PATIENTS/METHODS: We operated three neurologically impaired children with cerebral palsy, vomiting and aspiration due to



POSTER ABSTRACTS

gastroesophageal reflux. Surgical treatment was required because of feeding problems and pulmonary complications. Surgery, through a laparoscopic approach, included: 1) hiatoplasty, 2) Nissen fundoplication, 3) Jejunal-jejunal resection, 4) 20 cm distally Roux-en-Y jejunal anastomosis, 5) anastomosis between jejunum and stomach, 6) gastrostomy.

RESULTS: All the cases were fed on post operative day three without any complications. Outcome was checked using a contrast study on post-operative day 90 and 365.

DISCUSSION: Roux-en-Y gastro-jejunal bypass is a possible procedure to treat GER in NIC with gastric-emptying disorders. The laparoscopic approach is possible.

REFERENCES: Morabito A, Lall A, Lo Piccolo R, McCarthy H, Kauffmann L, Ahmed S, Bianchi A. Total esophagogastric dissociation: 10 years' review. *J Pediatr Surg.* 2006 May;41(5):919-22.

P103 PERCUTANEOUS ENDOSCOPIC GASTROSTOMY (PEG) IN PEDIATRIC PATIENTS: OUR EXPERIENCE AND PROPOSAL OF FOLLOW-UP METHODOLOGY

Raffaella Canali MD, Giada Sciascia Cannizzaro MD, Valentina Buonomo MD, Assunta Scaldaferrì MD, Giuseppe Retrosi MD, Claudio Pintus MD, U.O. Chirurgia Pediatrica - Policlinico Universitario "A. Gemelli", Roma, Italy

OBJECTIVE: To evaluate effectiveness and acceptability of percutaneous endoscopic gastrostomy in pediatric patients and to propose a data collection and follow-up methodology.

PATIENTS/METHODS: Observational retrospective and prospective study on 33 pediatric patients and 5 adults with metabolic, genetic or oncologic disease, who underwent PEG placement using Gauderer "push" technique, between 2000 and 2007. By means of an appropriate questionnaire, the following parameters were evaluated: complications, factors of further risk, nutritional status, management and acceptability of PEG.

RESULTS: No problems occurred during placement. Complications were few and easy to resolve. In 3 patients a stomal dehiscence occurred, strongly related to the tube gauge. During replacement, in 4 patients, bumper was not taken away because of difficult removal. 8 patients had pre-PEG gastroesophageal reflux: In 2 of them, during the PEG placement, fundoplication was realized. Subsequently PEG procedure, only 1 patient needed fundoplication for worsening of GER. All of them continued gastroprotective treatment. Respiratory tract infections decreased in our 13 patients carries of tracheostomy.

CONCLUSIONS: To prefer smaller gauge reduces risk of dehiscence. If the bumper's removal is hard, to leave it inside is acceptable and quite safe, on condition of a careful surveillance of gastrointestinal obstruction signs. GER is not a contraindication of PEG. A careful follow-up is important, by recording all the evaluated parameters and by questionnaire to the family, during every hospital admission. This study, even if on few patients, confirms PEG as the technique of choice for long-term enteral feeding, also in children. Training of family and caregivers is important to care.

P104 INCISIONAL HERNIA ON A 5-MM TROCAR PORT SITE AFTER LAPAROSCOPIC PANCREATIC TAIL BIOPSY

Winfried F. Barthlen MD, Manfred Scholz MD, Michael Singer MD, Harald Mau MD, Pediatric Surgery Charite University Medicine Berlin

A 2 month old infant presenting with the clinical signs of congenital hyperinsulinism underwent PET-CT to distinguish between the focal and diffuse form. The result has been equivocal and therefore laparoscopic pancreatic tail biopsy was performed. The specimen was removed by the 10mm umbilical incision. There was no drain left. The intermediate form of congenital hyperinsulinism was diagnosed histologically and medical therapy with octreotide was established. The initial course after surgery was uneventful. On day 10, however, the infant showed

feeding problems and a tender swelling was noted at a 5 mm trocar port site in the left lower abdomen. Ultrasound revealed incarcerated bowel subcutaneously. Surgical exploration showed a small bowel loop being trapped in the incisional hernia. The bowel was reduced and the hernia was closed. There were no further events. Although incisional hernias have been reported occasionally on 5-mm trocar port sites, to our knowledge our infant is the smallest one to experience this unusual complication. Because of the small bowel size all fascial defects should be closed surgically in infants.

P105 LAPAROSCOPIC ROUX-EN-Y HEPATICOJEJUNOSTOMY IN CHILDREN WITH PANCREATICOBILIARY MALJUNCTION

Hans Joachim Kirschner MD, Florian Obermayr MD, Philipp Szavay MD, Joerg Fuchs MD, Department of Pediatric Surgery, University of Tuebingen, Tuebingen, Germany

PURPOSE: Reports on minimally invasive bile duct surgery in infants are rare. We report on our experience with laparoscopic hepaticojejunostomy in four children with a long common channel.

PATIENTS/METHODS: Between 2004 and 2007 four patients were treated by laparoscopic hepaticojejunostomy for a long common channel. The median patient age was 3 years 6 months, the median follow up 3 years 5 months. Preoperative diagnostics consisted of MRCP and abdominal ultrasound in all patients. In two patients with a prepapillary concrement ERCP was performed additionally. Preoperative symptoms were recurrent pancreatitis and cholestasis in all patients. All children were treated by a laparoscopic Roux-en-Y hepaticojejunostomy.

RESULTS: Laparoscopic hepaticojejunostomy could be performed in all patients without intraoperative complications. The immediate postoperative recovery was uneventful in 3 patients, 1 patient needed re-operation due to bile leakage. Hepatobiliary 99mTc-iminodiacetic acid (HIDA) scan showed normal uptake and prompt passage into the bowel. One period of mild pancreatitis did occur in one child. All other children showed an uneventful long-term follow up.

CONCLUSION: Laparoscopic Roux-en-Y hepaticojejunostomy is a alternative approach in children with pancreaticobiliary anomalies.

P106 MINIMAL INVASIVE SURGERY FOR LOWER ESOPHAGEAL PATHOLOGY, CONGENITAL AND IATROGENIC

Mila Kolar MD, Zakaria Habib MD, Saleh Al Nassar MD, Department of Surgery, King Faisal Specialist Hospital and Research Centre, Riyadh

This is case report of 3 patients who were managed successfully by minimal invasive surgery. Two patients diagnosed to have congenital esophageal stenosis and one patient has surgical transection of gastroesophageal junction to control sepsis, secondary to a leaked repair for type C tracheoesophageal atresia/fistula. The esophageal continuity was established by the laparoscopic approach. Postoperative complication included esophageal anastomotic stricture which responded to dilatation sessions. This limited experience demonstrated the ease and feasibility of this approach in the presence of advanced laparoscopic skills.

P107 VARICOCELE EMBOLIZATION WITH BOILING CONTRAST

John M. Racadio MD, David M. McKinney BS, Manish N. Patel DO, Kamlesh U. Kukreja MD, Neil D. Johnson MD, Doan Vu MD, Cincinnati Children's Hospital Medical Center

PURPOSE: Transcatheter injection of boiling hot contrast into the gonadal vein has been used successfully for retrograde varicocele embolization in adults for many years; however, this technique has not been described in a series of adolescents. While other methods of transcatheter embolization have become popular recently in adults (including coil embolization and injecting sclerosing agents such as

POSTER ABSTRACTS



alcohol, doxycycline, and sodium tetradecyl sulfate), we felt that the well-established method of injecting hot contrast would be just as effective as these newer transcatheter techniques. We also felt that injection of gelfoam plegets would help promote immediate thrombosis. We retrospectively reviewed cases in which hot contrast and gelfoam were used for adolescent varicocele embolization.

MATERIALS/METHODS: A retrospective chart review was conducted on all patients in whom varicocele embolization was performed using transcatheter injection of hot contrast and gelfoam plegets.

Results: 7 patients were identified (all left sided varicoceles); 4 of the 7 had recurrent varicoceles after failed surgical varicocelectomy. Mean age was 16.3 years (range: 12.8-18.9 years). All embolizations were immediately technically successful, demonstrating venous occlusion of the left gonadal vein as well as any parallel collateral veins draining the varicocele. 4 of the 7 have returned for clinical follow-up after a mean follow-up period of 6.5 weeks. All four had a clinically evident decrease in varicocele size without any reported complications. 2 of the 7 underwent embolization recently and have not yet had clinical follow-up. Due to clinical improvement, no patients have had follow-up imaging to date.

CONCLUSION: Retrograde embolization with hot contrast and gelfoam is a precise, immediate, safe, and low-cost way to treat adolescent varicoceles. Longer follow-up, including any interval imaging, will be reported during the abstract presentation.

P108 WHY DO WE CONVERT?

B.T. Adikibi MD, G.A. MacKinlay MD, F.D. Munro MD, M.C. Clark MD, Royal Hospital for Sick Children, Edinburgh

INTRODUCTION: We review our laparoscopic and thoracoscopic experience and look specifically at the cases that resulted in conversion to an open procedure.

METHODS: Data was retrieved from surgical audit, our laparoscopic database and case note review of all minimally invasive surgical procedures performed in our institution.

RESULTS: There were 1775 cases performed between 1995 and 2007. Of these 1668 cases were laparoscopic and 107 performed thoracoscopically. There were, 505 appendectomies (34 interval), 223 funduplications (21 redo), 193 diagnostic laparoscopies, 136 pyloromyotomies, 35 cholecystectomies, 27 splenectomies, 97 fowler Stephen procedures, 76 nephrectomies (including heminephrectomies), 52 Palomo procedures, 75 assisted PEGS, 31 pull through procedures for Hirschsprung's disease, and 218 others. There were 50 conversions (2.8%) over the time period. The conversion rate fell from 6.3% in 1997 to 0.4% in 2007.

16% of the conversions were enforced due to bleeding or visceral injury noted at the time of surgery. 36% of the laparoscopic cases converted were in children who had previously had abdominal surgery. Looking specifically at the conversion for specific operations, this was 2% for appendectomies and pyloromyotomies and 1 % for funduplications. The rate was higher for thoracoscopic cases and nephrectomies at 10%. In the case of tumour resections parents were warned that the operation would only be completed endoscopically if this would not compromise safe surgery. Dividing the conversions for nephrectomies on the basis of benign or malignant disease, the rate was higher for malignant disease at 12.5 % compared with 10.2% for benign disorders. 80% of all conversions occurred during the first 1000 cases (56% of our experience)

CONCLUSION: Our conversion rate is 2.8%. There has been a 21 fold fall in our conversion rate over the thirteen years which we attribute to the learning curve of minimally invasive surgery and the increased number, breadth and complexity of our caseload. Conversion is more common with patients who have had previous surgery, thoracoscopic procedures and nephrectomies.

P109 THE ANATOMICAL PATHOLOGY OF THE PROCESSUS VAGINALIS IN CHILDHOOD HYDROCELES AS SEEN AT LAPAROSCOPY DIFFERS FROM THAT DESCRIBED IN THE CLASSIC PEDIATRIC SURGICAL TEXT BOOKS

Colin Lazarus, Milind Chitnis, Mie Elsen, Itayi Simango, Claire Purdue, East London Hospital Complex, East London, South Africa.

BACKGROUND: Standard pediatric surgical texts describe communicating hydroceles (CH) as occurring in association with a narrow patent processus vaginalis (PPV), while non-communicating hydroceles (NCH) follow the obliteration of the proximal PPV. With the experience gained in the laparoscopic correction of childhood inguinal hernias, we have begun to manage the PPV of childhood hydroceles in the same manner. In doing so, we have become aware of significant differences between our findings at laparoscopy and the descriptions of the pathology of childhood hydroceles as found in the standard pediatric surgical texts.

AIM: To document the anatomical pathology of the processus vaginalis of childhood hydroceles as seen laparoscopically at the time of repair.

PATIENTS/METHODS: 25 patients, aged between 10 months and 10 years (mean 4.5 years) were examined and photographs taken intra-operatively of their PPV. The diameter of the PPV, its length and calibre were estimated and recorded. The processus was then separated from the peritoneum by hook diathermy and the peritoneal defect thus created was closed with a single intracorporeal absorbable suture. When present, the NCH were then aspirated.

RESULTS: 1. CH were found in 15 patients and NCH in 10. 2. All 25 patients had a PPV. The PPV in CH extended down to the testis while in NCH the PPV extended some or all of the way down the inguinal canal to the outer wall of the tunica vaginalis of the closed hydrocele. 3. 3 patients thought clinically to have a NCH were found to have a pin hole opening between the hydrocele and the PPV. 4. 3 patients with NCH were shown to have early abdominoscrotal hydroceles. 5. The diameter of the PPV was assessed as being <5mm. in 6 patients, between 5mm. and 10mm. in 12 patients and >10mm. in 7 patients.

CONCLUSIONS: 1. Laparoscopy has augmented our understanding of childhood hydroceles and shown that standard pediatric surgical texts do not accurately describe their pathological anatomy. 2. Both CH and NCH have a PPV with the PPV in NCH ending at the hydrocele. 3. The presence of a proximal PPV in NCH and the variable diameter of the PPV raise questions about the subsequent development of inguinal hernias and the recommended non surgical approach to infant hydroceles.

P110 EFFICACY OF LAPAROSCOPY FOR INTRA-ABDOMINAL LARGE CYSTIC MASS IN CHILDREN

Mari Arai MD, Takako Nishina MD, Takatsugu Murakoshi MD, Sachiko Sakai MD, Department of Surgery, Tokyo Metropolitan Hachioji Children's Hospital

PURPOSE: Intra-abdominal large cystic mass in children is often difficult to diagnose before operation. We experienced three cases with large cystic mass, in which the efficacy of laparoscopy for their diagnosis and treatment is evaluated.

CASES: Case 1: Twelve-year-old girl was admitted for abdominal distention and pain. Computed tomography showed large cystic mass with a few septa, and preoperative diagnosis was suspected to be omental or ovarian cyst. Laparoscopic surgery revealed the omentum adhered so severely to parietal peritoneum and entire internal organs that we could put the laparoscope into the greater omentum. It showed multiple nodules on the surface of interior cyst wall, and they were nodules of tuberculosis of the omentum by the pathologic study. We did not resect the cysts, but drainage was effective. We started the treatment for tuberculosis. Case 2: Five-year-old boy was admitted for high fever, abdominal distention and pain. He had large cystic mass in his abdominal cavity. The transverse colon was dislocated to the anterior abdomen, and serum level of amylase



POSTER ABSTRACTS

was not increased. Because our preoperative diagnosis was infectious omental cyst based on radiological findings, medical treatment including administration of antibiotics was done. Delayed primary laparoscopic surgery showed the pancreatic cyst in omentum bursa. Case 3: Three-year-old girl was admitted for severe abdominal distention and pain. There were large multi-cystic masses in her abdomen by US and CT. We administered antibiotics, but the cyst did not become smaller. Preoperative diagnosis was omental or ovarian cyst. After drainage of the cyst under US, it was resected combined with omentum laparoscopically. The pathologic finding of the cyst was omental cyst surrounded by large vein wall.

DISCUSSION: Most of intraabdominal large cystic masses are omental or ovarian cyst. However, in these 3 cases, preoperative diagnosis using CT and US was quite difficult. At the time of acute abdomen with large cystic mass, we recommend to do conservative therapy including drainage of cystic fluid and to perform delayed laparoscopy after the cyst becomes smaller and the infection is controlled. We conclude that laparoscopic surgery is very useful to diagnose the origin of the large cyst and to excise it under beautiful cosmesis.

P111 LAPAROSCOPIC INSERTION OF AN ABDOMINAL EXPANDER BEFORE RADIOTHERAPY OF A RIGHT ILIAC EWING SARCOMA TO PREVENT SMALL BOWEL ENTERITIS

Arnauld Delarue MD, Angélique Rome MD, Laetitia Padovani MD, Smart Zeidan MD, Xavier Murraciale MD, Hôpital Timone-Enfants, Marseille, France

Bowel radiation injury is the main adverse effect of pelvic and abdominal radiotherapy. A 14-y-old girl presented an Ewing sarcoma of the right iliac crest that responded well to primary chemotherapy but remained non resectable. Local irradiation at full dose (54 Gy) was subsequently considered as part of the EuroEwing 2001 protocol. To move small bowel out of the radiation field and decrease the risk of acute and chronic radiation-induced enteritis, an inflatable expander was laparoscopically placed one week before irradiation. The expander was introduced through a 15-mm port, filled with 1000 mL of saline and secured in the right iliac fossa: the filling pipe was clipped and placed subcutaneously in the right flank and a silastic strap was fixed over the expander in the pelvis to prevent displacement. Because the girl had abdominal discomfort with such a volume, the expander was deflated to 600 mL 2 days later. CT-scann showed that the bowel was also appropriately displaced. The 6-week radiotherapy protocol was completed without emptying the expander between courses since it was well tolerated. The total dose delivered to small bowel volume was significantly reduced. 12 % of bowel volume would have received more than 40 Gy without expander versus 0% with expander and 20% versus 0% respectively for 20 Gy. The expander was removed laparoscopically 21 days after radiotherapy for patient's convenience. No adhesion or inflammation were found at surgery. The child never presented any abdominal symptom of enteritis.

Few cases of protective bowel displacement are reported in children. Various devices were used, but this expander is one of those commonly placed by plastic surgeons for skin expansion. Different sizes and shapes of expander are so easily available. Laparoscopic placement of an abdominal tissue expander could be recommended as an easy and safe procedure to prevent radiation-induced enteritis.

P112 LAPAROSCOPIC ASSISTED TENCKHOFF CATHETER IMPLANTATION VS OPEN PROCEDURE: ADVANTAGES AND DISADVANTAGES

C. van Tuil MD, M. Goeppl MD, P. Guenther MD, S. Holland-Cunz MD, Department of Pediatric Surgery, University of Heidelberg, Germany & Department of Pediatric Surgery, University of Mannheim, Germany

OBJECTIVE: Continuous Ambulatory Peritoneal dialysis (CAPD) is a common procedure in children with terminal renal failure. Laparoscopic assisted implantation of a peritoneal dialysis catheter is reported frequently

in adults; however few reports have emerged in the pediatric age group. Since catheter complications are common, a review of laparoscopic catheter placements with regards to infections, hernias, leakage, catheter tip migration and catheter dysfunction was done.

METHODS/PROCEDURES: The open surgical versus laparoscopic assisted procedure was reviewed over a period of 7 years. Data was collected in children over 3 months of age with regards to operation time, intraoperative, early and late postoperative complications. The groups were also divided into patients with minor and major abdominal surgeries prior to implantation of the peritoneal dialysis catheter.

RESULTS: In our series of 81 patients with a mean age of 6 8/12 years, we had 43 laparoscopic assisted catheter implantations and 34 open procedures. In 4 children with minimal invasive abdominal access conversion to the open approach was necessary in 2 cases because of strong adhesions, material defect (1 patient) and meteorism (1 patient). Due to catheter dislocation or dysfunction 17 patients needed a catheter revision. We found a noticeable increase in the number of cases with catheter dislocation and dysfunction, after the sourcing of the catheter was changed.

CONCLUSION: Laparoscopic assisted implantation of a peritoneal dialysis catheter is simple and safe even after abdominal surgeries. It is of important to implant a catheter which is adapted to the length of the child, especially in the very young age group. Most of the postoperative complications were found to be catheter dislocation and dysfunction due to omental incarceration. The minimal invasive technique is advantageous to reduce these incarcerations and other causes of abdominal catheter dysfunction and catheter revisions.

P113 PEDIATRIC LAPAROSCOPIC SURGERY IN ABIDJAN (CÔTE D'IVOIRE)

R. Bankole PhD, B. Kiroua MD, P. Guemaleu MD, Teaching Hospital of Treichville (Abidjan - Cote D'ivoire)

INTRODUCTION: Minimally invasive surgical approaches to various paediatric surgical disease processes are becoming the standard of care in developed countries, but it is not the case in developing countries. By reporting this series, we want to emphasize the obstacles of the promotion of laparoscopic surgery in Africa.

MATERIALS/METHODS: It's a retrospective study. We review over a 6 years period; the files of 118 children underwent laparoscopic surgery in Abidjan (Côte d'Ivoire).

RESULTS: They were aged 3 years to 15 years (median 12 years). In 77, 1% of cases, they were operated on in private health facilities, and 29, 9% of case in hospital teaching of treichville. Their pathologies were appendicitis in 79 cases, peritonitis in 10 cases, and cholelithiasis in 16 cases, exploration for genital ambiguous in 2 cases, no palpable testis in 9 cases, and 2 cases of ovarian cyst. Three patients required conversion to the open operation (1 appendicitis and 2 peritonitis) and we observed 1 postoperative umbilical infection as complication. Average duration of hospitalization was 2,2 days.

COMMENTS/CONCLUSION: Despite the advantage of laparoscopic procedure: shorter hospitalization, reduced discomfort, and cosmetic benefit. There were obstacles of its promotion: No formation of all paediatric surgeons to this approach; No laboratory of learning surgical procedure (only relatively routine laparoscopic procedures were done); No materials of laparoscopic surgery in emergency, in teaching hospital; Price of operation for laparoscopic is expensive for a majority of population. There is no insurance for all people in our country.

P114 A MOBILE CECUM PREDISPOSING TO A MAJOR COMPLICATION OF LAPAROSCOPIC ASSISTED ILEOSTOMY

Claudio De Carli MD, Juan Bass MD, Brian Sweeney MD, Department of General Surgery, Children's Hospital of Eastern Ontario, Ottawa, Ontario, Canada

Laparoscopic assisted stoma creation is becoming a more popular procedure in the adult population. Our institution has previously reported laparoscopic

POSTER ABSTRACTS



assisted colostomy in children. We report an important complication in a patient who underwent a laparoscopic assisted ileostomy (LAI). A four year old male with Down's syndrome and a histologically confirmed intestinal smooth muscle myopathy, resulting in chronic bowel distension and dysmotility, underwent an LAI. Ten days postoperatively, the patient developed severe abdominal pain, a dusky stoma, hypovolemia, metabolic acidosis and hypothermia. A plain abdominal X-ray showed a newly distended loop of bowel in the right abdomen compared to previous X-rays. Emergent laparotomy revealed that a volvulus of the cecum had occurred around the loop ileostomy compromising the blood supply of the terminal part of the ileostomy and the proximal right colon. The colon recovered after detorsion of the volvulus. The patient underwent a revision of the ileostomy with resection of the terminal necrotic portion. An end ileostomy was created, and a mucous fistula was fashioned at the ileocecal junction serving as a functional cecal fixation. To date, there is limited experience of laparoscopic stoma formation in children. In this case the ileostomy acted as a fulcrum for a volvulus of the cecum around a loop ileostomy. We now recommend that during the course of LAI, cecal mobility should be carefully evaluated. In the absence of adequate cecal peritoneal attachments, the addition of a cecopexy should be considered as part of the LAI.

KEY WORDS: volvulus; laparoscopy; ileostomy

P115 FETOSCOPIC SURGERY OF EXTREMITY AMNIOTIC BANDS: LIMB SALVAGE BY INTRAUTERINE BAND RELEASE IN THE HUMAN FETUS

Jose L. Peiró MD, Elena Carreras MD, Francisco Soldado MD, M-Angeles Sánchez-Duran MD, Marius Aguirre PhD, César G Fontecha PhD, Giné Carles MD, Vicen Martínez-Ibañez PhD, Fetal Surgery Program. Hospital Vall d'Hebron, Barcelona, Spain.

INTRODUCTION: Fetal limbs at risk of amputation by a constrictive extremity amniotic band (EAB) are amenable to fetal surgery. Experimental models of intrauterine repair of moderate or severe EAB in the fetal lamb has been reported. In front open fetal surgery, fetoscopic procedures offer a minimally invasive approach that could be applied for the treatment of the EAB.

PATIENTS/METHODS: Two human fetuses with prenatally detected extremity amniotic bands (EAB) at risk of limb amputation were treated in the last year by means fetoscopic surgery at 21 and 22 weeks of gestation (GA). EAB were detected by prenatal ultrasounds that showed a bulky edematous lower extremity distally to a constriction ring. A fold of amnios was detected in one case, that also trapped the umbilical cord. Both cases presented finger malformations in their hands. Power-doppler showed a clear decrease of the arterial flow beyond the constriction ring. Fetal MRI confirmed this findings. Fetal surgery was offered and programmed few days after EAB detection. Fetoscopy was performed with a percutaneous 10 Fr cannula inserted by Seldinger technique. A 3 mm. fetoscope with a 2 mm. telescope and a work channel was introduced in the amniotic cavity. Amnioinfusion was used to clear vision. Repair of EAB was achieved in both cases by perpendicular section of the constrictive ring by means a Nd:YAG laser fiber under direct vision and sonographic control.

RESULTS: Immediately after the procedure, a clear improvement in vascular flow of the affected area is detected with Doppler. Reduction of distal edema and normal blood flow were verified in the following weeks. One case presented a preterm rupture of membranes and was born at 28 weeks GA. The baby presented a mild mark at the constriction level that needed a little z-plasty, but she saved the leg with normal function and good results. The other fetus is still in the gestation period without complications in this moment.

CONCLUSIONS: In-utero release of potentially severe EAB avoids limb amputation and permits its morpho-functional recovery in the human fetus. Release of constrictive bands of the umbilical cord is lifesaving. Early antenatal detection and fetoscopic repair facilitates surgical procedure and offer better outcome for limb rescue in severe EAB.

P116 PERCUTANEOUS INGUINAL HERNIORRAPHY WITH ENDOCLOSE NEEDLE

Edward Esteves MD, Denny C. Lima MD, Eriberto Clemente-Neto MD, Pediatric Surgery Division, University of Goias, Brazil

There are some described techniques available for the percutaneous herniorrhaphy with needles. Helped by a thin laparoscope, the ligature can be achieved rapidly with the less possible method available, the percutaneous technique with needles. The authors present their first series with a new and safer technique for pediatric laparoscopic percutaneous herniorrhaphy with the endoclose needle, allowing blunt dissection, no trocar, only one puncture and no complications.

P117 LAPAROSCOPIC FEMORAL HERNIA REPAIR

Mustafa Kucukaydin MD, Ahmet N. Ciftler MD, Ahmet B. Dogan MD, Serkan Arslan MD, Mahmut Guzel MD, Kadri C Sulubulut MD, Erciyes University School of Medicine, Department of Pediatric Surgery

AIM: To present our experience with laparoscopic femoral hernia repair in two children.

PATIENTS/METHOD: Case-1: A three-year old boy presented with bilateral groin swelling. He was operated on bilateral indirect inguinal hernias by another surgeon before 6 months, but hernia's sac could not be found. Following the operation, the groin swelling insisted again bilaterally. On the examination, the bilateral femoral hernias were diagnosed. Under general anesthesia, bilateral femoral hernias were repaired by laparoscopic procedure using three trocars (one 5 mm, two 3 mm) on an outpatient basis. During the 4 months follow-up periods there was no recurrence and he did well. Case-2: A six-year old boy presented with left groin swelling. On examination, left femoral hernia was diagnosed. This patient also treated as a same manner like the first case with three trocars. During the 3 months follow-up periods there was no recurrence.

CONCLUSION: Our comment is that the laparoscopic femoral hernia repair is feasible, effective and safe method than indirect inguinal hernia in boys, because the internal orifice of femoral canal is away from the vas and testicular vessels.

KEYWORDS: children, femoral hernia, laparoscopic repair

P118 UMBILICOPLASTY LIKE (UPL) A SIMPLE TECHNIQUE FOR TRAINING 1ST TROCAR INSERTION

Aixa Reusmann MD, Catalina Salazar Sanin MD, Marcela Bailez MD, Garrahan Hospital Buenos Aires

AIM: Describe and analyze the safety and operative time of a technique used for training pediatric surgeons to insert the first trocar in laparoscopic procedures.

MATERIAL/METHOD: An open procedure to insert the first trocar resembling an umbilicoplasty was described by one of the authors 10 years ago. It consisted in a circumferencial incision under or over the umbilicus using a pursestring suture to fix the trocar and close the defect after the procedure. It has been used for training different residents since then. A prospective analysis of 100 consecutive procedures was undertaken. Data consisted in age of the patient, diameter of the trocar, timing of the procedure and level of the trainee (year of residency program)

RESULTS: The mean age of the patients was 9.8 years (range: 2 months to 19 years). The mean time of the procedure was 4.35 min (range 1 to 18 min); 4.31 min (from 1.5 to 7.16 min) for 4 mm trocar, 4.38 min (range: 1 to 10 min), for 5 mm trocar, 4.45 min (from 3.5 to 10 min), for 7 mm trocar, 4.31 min (from 1 to 18 min) for 10 mm trocar. There were 10 different operators. The mean time for first year residents was 4.5 min; for second year residents: 4.37 min; for third year residents: 4.3 min; for fourth year residents: 4.38 min and for the chief resident: 4.38 min. No intraoperative or immediate postoperative complications occurred.

CONCLUSION: UPL proved to be an easy, safe and fast open technique



POSTER ABSTRACTS

to train pediatric surgery residents in inserting the first laparoscopic trocar. Long term analysis is required for cosmetic results and incidence of incisional hernia.

P119 *Abstract Withdrawn*

P120 TWO TROCAR PALOMO VARICOCELECTOMY IN ADOLESCENTS

Antonio Marte MD, Maria Domenica Sabatino MD, Micaela Borrelli MD, Biagio Del Balzo MD, Fabiano Nino MD, Maurizio Prezioso MD, Pio Parmeggiani PhD, Paediatric Surgery of Second University of Naples

AIMS: The laparoscopic Palomo procedure for the treatment of varicocele in children and adolescents is accepted as one of the most effective and reliable techniques. This technique is classically based on the use of three trocars. We reviewed our experience from January 2005 to June 2007 utilizing a two trocar technique.

METHODS: Twenty patients aged 11 to 16 years underwent the laparoscopic Palomo procedure with Liga-Sure. These patients presented 2nd and 3rd grade varicocele, in some cases associated with ipsilateral testicular hypoplasia. An open 11 mm umbilical trocar was employed with a 10 mm operative optic and one right lateral 5 mm access in the lower right abdomen. Grasping forceps were utilized through the operative optic channel and the scissors and Liga-Sure probe through the lateral port. Once the vessels were isolated, the vascular sealant was applied three-four times to ensure the sealing of the spermatic vessels: the vessels were then divided with laparoscopic 5-mm scissors. In five cases that had considerable dilatation, the deferential veins were also sealed through another small peritoneal window, without dividing the vessels.

RESULTS: No perioperative or postoperative complications were recorded. At a mean follow-up 15 months one patient recurred and 1 presented hydrocele. No significant differences (Wilcoxon test) in terms of complications or operating time were found compared to our previous experience with the three trocar technique; there were instead better results in terms of cosmesis, recovery of the patients, optimal use of trocars, and postoperative pain. In our experience the technique resulted very easy and reliable even in treating sigmoidal adhesions. No significant difference was found between two-trocar and three-trocar laparoscopic varicocelectomy in terms of operating time (i.e., 18 ± 7 m?).

CONCLUSION: The two trocar laparoscopic Palomo varicocelectomy is a very safe and effective tool for the treatment of varicocele in adolescents, with the added value of a greater cost-effectiveness and improved cosmesis.

P121 EMERGENCY LAPAROSCOPIC ASSISTED GASTROTOMY FOR THE TREATMENT OF AN IRON BEZOAR

F. H. Haider MD, C. F. De Carli MD, S. Dhanani MD, B. Sweeney MD, Divisions of Pediatric Surgery and Pediatric Intensive Care, Children's Hospital of Eastern Ontario, Ottawa Ontario, Canada

Iron ingestion accounts for approximately 3 % of calls to poison centers and when retained in the gastrointestinal tract can cause significant bowel injury. The systemic absorption of ingested iron can result in hepatotoxicity, metabolic acidosis and coagulopathy with a mortality rate of 5%. Laparotomy and gastrotomy has been reported as a life saving maneuver to remove the retained iron aggregates that are notoriously resistant to conventional emesis or lavage techniques. We describe for the first time, the use of laparoscopic assisted gastrotomy in the treatment of an iron overdose. A 14 year old girl attempted suicide by means of a polydrug overdose which included ferrous fumarate at a calculated potentially lethal dose of 70 mg/kg. The patient was commenced on deferoxamine. An iron bezoar within the stomach was seen on plain abdominal X-ray. The poison control center recommended surgical removal of the retained iron tablets. At the time of initial evaluation the patient was hemodynamically stable with no evidence of coagulopathy and had a B.M.I. of 30. Upper endoscopy

confirmed the retention of iron medication that was densely adherent to the gastric mucosa. A 5 mm laparoscope was introduced at the umbilicus to identify the stomach which was grasped by an instrument introduced through a trocar in the left upper quadrant and the incision was then enlarged to allow the formation of a gastrotomy. The retained iron was then removed with the aid of digital disimpaction and copious saline irrigation. Postoperatively the patient's iron levels rapidly normalized and her liver function transiently deteriorated, but she made a full recovery prior to undergoing psychiatric treatment. Laparoscopic assisted gastrotomy is a simple and safe option in the acute management of a retained iron bezoar and may be particularly advantageous in patients with a high B.M.I.

P122 LAPAROSCOPIC INGUINAL HERNIORRHAPHY IN BABIES WEIGHING 5 KILOGRAMS AND LESS

Salmi Turial MD, Walid Treef MD, Krause Kathrin, Martin Schwind MD, Alexandra Weltzien MD, Felix Schier MD, Department of Pediatric Surgery, University Medical Center Mainz

PURPOSE: The aim of this study was to evaluate the feasibility, safety and to verify the incidence of complications during laparoscopic inguinal hernia repair in small babies weighing 5kg or less.

METHODS/PATIENTS: This study includes 183 laparoscopic hernia repairs in 110 children, 75 boys (68,2%) and 35 (31,8%) Girls. The age ranged from 14 to 164 days, median 56 days. The body weight at surgery ranged from 2120 to 5000grams, median 3904grams. 49 (44,5%) children were classified as premature (< 36 weeks gestation). In 20% the procedure was performed as an emergency case due to incarceration. All procedures were done under general anesthesia with endotracheal intubation. The internal inguinal ring was closed with a 4-0 nonabsorbable suture by intracorporeal knotting using 2mm instruments and 5mm scope or 1,9mm scope in 20 children respectively.

RESULTS: The operative time for the unilateral hernia performed by all surgeons including the residents was 25,4 minutes and for the bilateral hernia was 37,6 minutes. Intraoperative finding showed 26 right sided hernias, 11 left sided hernias and 73 bilateral hernias. No serious intraoperative surgical complications occurred. Anesthesiological complication during the intubation or extubation have been noticed in 10 cases. In three cases we converted to open procedure due to anesthesiologic concerns. Follow up results including clinical examination, testicular ultrasonography and blood-supply-measurements of the testicles by O2C-device will be presented.

CONCLUSIONS: Laparoscopic herniorrhaphy is a safe and feasible procedure for treatment of inguinal hernia in babies weighing 5 kg and less. In our opinion, the laparoscopic approach yields better results and it seems to be technically easier compared to the traditional "open" herniotomy in small babies. We perform laparoscopic herniorrhaphy as a routine procedure at our department.

P123 THE USE OF ANIMAL MODELS (AM) FOR TRAINING IN PEDIATRIC ENDOSURGERY

Aixa Reusmann MD, Martín Rubio MD, Mariano Bogleione MD, Marcela Bailez MD, J. P. Garrahan Hospital. Buenos Aires. Argentina

AIM: Evaluate the utility of the use of AM for training surgeons in endosurgery.

METHODS: Courses started in 1995. From 2005 we decided to fill a prospective file to evaluate different parameters related to their utility. Each course lasted 4 days. They included conferences and practice in trainers and live animals. Animals underwent general anesthesia. They received humanized treatment according to the "Guide for the Care and Use of Laboratory Animals" (Institute of Laboratory Animal Resources, National Research Council). Ergonomics, technical details regarding the use of both hands, the art of suturing and the safe use of haemostatic devices were the main topics. A systematic program of exercises run by the same instructors was used. Data collected consisted in: number of participants; type and weight of the animals; type, number and duration

POSTER ABSTRACTS



of procedures, number of operators per animal. An anonymous opinion survey was analyzed with these questions: Did you find the contents of the course interesting? Do you think you incorporate new knowledge? Was the course useful in your professional training? Are the concepts and procedures learnt useful in your everyday practice? Was time dedicated to practice enough? Did the course reach your expectations? Answers were rated as: in little, moderate or great measure.

RESULTS: We trained 32 participants in 6 courses from 2005 to 2007. We used Landrace pigs and rabbits. Mean weight was 10.4 kg for the pigs and 3.9 kg for the New Zealand rabbits. Procedures done were: salpingectomy, ooforectomy, cholecystectomy, nephrectomy, Nissen fundoplication, gastrostomy, diaphragmatic repair, esophageal anastomosis, tiectomy, lung biopsies, lobectomy, pleural effusion toilette, splenectomy, intestinal biopsies, rectal desvascularization, pelvic lymphadenectomy, dissection and ligation of vascular structures, dissection of the ureters. One hundred and thirty six procedures were performed. There were 2 participants and 1 instructor per animal in 89% of the procedures. A mean of 3.3 procedures in a mean period of 271 minutes were done in each pig and 2.6 in 259 minutes in each rabbit. Sixty-eight percent of the pigs and 88% of the rabbits died during a procedure. Ninety-three percent of the participants agreed that the contents of the course were interesting, they acquire new knowledge, the course was useful in their professional training and in their everyday practice, and their expectations were reached in great measure. Practical time was enough in great measure for 50% of participants.

Conclusion: According to these results, these courses seem to be helpful to train surgeons in endosurgery in pediatric patients. We need to analyze data regarding to level of training and cost.

P124 OVARIAN CYSTS AND LAPAROSCOPIC UNROOFING: A CRITICAL REVISION

G. Lisi PhD, N. Marino MD, V. Cascini MD, N. Pappalepore MD, P. Lelli Chiesa MD, Pediatric Surgery Unit - University "G. d'Annunzio" of Chieti-Pescara (Italy)

INTRODUCTION: Cystic ovarian masses in childhood represent an heterogeneous group of lesions of various etiology, the majority being of functional origin. The Authors re-evaluate their experience with laparoscopic approach to these lesions in perimenarchal adolescents.

MATERIALS/METHODS: From 2002 to 2006, 13 adolescents (range 11-15 yrs, mean 13.3 yrs) with ultrasonographic or MRI evidence of large persistent or symptomatic simple ovarian cysts (absence of solid area, internal septa and negative neoplastic markers), underwent laparoscopic radical cystectomy (5 cases) or large unroofing (8 cases).

RESULTS: 3 out of 8 unroofed cysts histologically resulted benign cystadenomas (2 mucinous, 1 sero-mucinous) with consequent laparotomic 2nd look (oophorectomy or salpyngo-oophorectomy); a further cystadenoma resulted in a girl who underwent radical cystectomy; the patient was then addressed to ultrasonographic follow up, without evidence of neoplastic recurrence.

DISCUSSION/ CONCLUSIONS: In adolescents with symptomatic or voluminous and persistent cystic ovarian masses, without laboratoristic, ultrasonographic and radiologic signs suggestive of neoplastic nature, a laparoscopic cystectomy, with maximal preservations of residual ovarian tissue, is indicated; a large unroofing is accepted as a valid alternative, still recently. For benign ovarian epithelial tumors (not always distinguishable from functional lesion at the pre-operative evaluation), radical cystectomy with ultrasonographic follow up is considered a valid therapeutic alternative to salpyngo-oophorectomy. Considering our relevant incidence of benign epithelial tumors (with consequent 2nd look surgery) in patients treated with unroofing and the not complete realibility of intraoperative frozen section reported in literature for this type of tumors, we suggest to debate whether the unroofing of the cystic wall should be yet considered a reliable option or if, in very large cysts (diameter >10 cm, possible cystadenoma), a more radical approach (open or laparoscopic cystectomy)

should be always offered to the patients, in order to minimize the need of a 2nd look procedure.

P125 RESECTION OF THE HERNIA SAC USING LAPAROSCOPIC TECHNIQUES: A NEW METHOD FOR TREATING INGUINAL HERNIAS ON CHILDREN

Carlos Garcia Hernandez PhD, Lourdes Carvajal MD, Juan Carlos Dueñas MD, Hospital Infantil Privado

BACKGROUND: The laparoscopic treatment of the inguinal hernias has the next advantages; since it allows examining of the counter lateral side, it has a lower probability of damaging the elements of the spermatic way, and in the complicated cases it allows intestinal recovery. However this technique has a mayor reoccurrence probability than the traditional open procedure. The physiopathology of the inguinal hernia in children as it is not an aponeurotic defect; therefore it can be treated when performing a resection of the hernia sac.

MATERIAL/METHODS: By performing a transperitoneal approach of three ports with 3mm instrumental, the peritoneovaginal process can be localized. The process on male subjects differs from the process in female subjects, as the process in males consists in a dissection of the spermatic way and it afterwards a total resection is performed. In the case of the female subjects the only resection occurs in the hernia sac, creating an area that unites together after removing the neumoperitoneum.

RESULTS: In the period that goes from January 2006 to January 2008, a number of 63 patients were treated, with ages that varied from 1 month to 14 years. In this period a number of 84 resections of the hernia sac were performed. After a period of 2 years of observation there haven't been any cases of recurrence as well as no elements of the spermatic cord were damaged.

CONCLUSION: The resection of the hernia sac is an easy technique that allows taking advantage of the minimal invasion in the treatment of the inguinal hernia on children, but without any recurrence.

P126 EXPERIENCE WITH THE EXCLUSIVE USE OF 5MM INSTRUMENTS FOR PAEDIATRIC LAPAROSCOPY

Anies Mahomed MD, Department of Paediatric Surgery, Royal Alexandra Children's Hospital, Brighton, UK

BACKGROUND: For a paediatric surgical unit offering minimally invasive surgery both 3 and 5mm instruments are essential. However, for a multitude of reasons a 3mm laparoscopic set was unavailable for use at the above institution, making surgeons entirely reliant on 5mm sets to deliver the service.

AIM: To report the experience of the exclusive use of 5mm instruments for paediatric laparoscopy over a 4 year period. To reflect on what is achievable and to assess the potential limitations and advantages to the use of exclusively 5mm instrumentation in paediatric practice.

METHOD: Presented is a single surgeons experience between 01/04 to 01/08. Details of all cases performed were recorded prospectively in a MS Excel database and analysed retrospective for basic demographic parameters, range of procedures performed and outcome measures including; operating time, conversion rate and complications.

Technique: Adaptation in technique was necessary in infants where port fixation to regulate intra-abdominal/thoracic extension was necessary to maximising view and manoeuvrability.

RESULT: A total of 157 laparoscopic cases were performed over the study period. These included 44 appendicectomies, 30 funduplications, 18 cholecystectomies, 11 transperitoneal nephrectomies. Miscellaneous cases totalled 54 and included 18 different procedures almost all therapeutic ranging from thoracoscopic to neonatal surgery. Ages ranged from 0.24 to 19.23 years, weight from <3 to >100kgs. and 8.3% of cases were less than 1 year of age. In the 2 largest groups (appendicectomy and funduplications) mean operating time were 45 mins (SD 17.23) and 124 mins (SD 48.43) respectively. There was no mortality or conversions and 2 cases, a 15 year



POSTER ABSTRACTS

old with 32 previous laparotomies with delayed ileal perforation following cholecystectomy and a 2 year old with an umbilical port hernia following fundoplication were taken back to theatre.

CONCLUSION: In experienced hands 5mm instruments pose no impediment to safely undertaking a near comprehensive range of laparoscopic procedures across all ages. A potential, but not insurmountable disadvantage is performing complex manoeuvres such as intracorporeal suturing within a confined place. However there are multiple advantages which include, standardisation and streamlining of laparoscopic sets, centralised consumables procurement process with adult services translating into cost saving, ease of passage of suture mounted needles into abdominal cavity, a wider choice of instrumentation and ease of manipulation and retrieval of excised internal structures.

P127 RANDOMIZED CONTROLLED TRIALS IN PAEDIATRIC MINIMAL ACCESS SURGERY

Clare Skerritt BA, Clare Rees BS, Simon Clarke BA, Munther Haddad MD, Chelsea and Westminster Hospital, London, UK

AIMS: 1) To determine the quantity of randomized controlled trials (RCTs) in Minimal Access Paediatric Surgery (MAPS) and evaluate the quality of reporting according to the CONSORT criteria and Jadad score for bias. 2) To compare the standards of reporting of RCTs in MAPS with those reported for adult general surgery RCTs.

METHODS: A Medline search was performed using search terms: laparoscop*, endoscop* and thoracoscop* and names of individual operations e.g. laparoscopic append*. Last search performed December 2007. Inclusion criteria were randomised controlled trials in human subjects, limited to children and comparing laparoscopic operations with open operations or other appropriate treatments. Papers were excluded if they were not general paediatric surgery operations (e.g. anaesthetic trials, ENT or neurosurgery). The trials were assessed independently by two reviewers and scored according to completeness of reporting of the modified CONSORT criteria (maximum score 90) and Jadad score (maximum score 5).

RESULTS: Of 200 papers identified, 19 RCTs met the predefined inclusion criteria, published between 1996 and 2007. Two trials were excluded from analysis due to duplicate reporting. 7 of 17 trials involved laparoscopic appendectomy (n=43-517), 2 papers compared laparoscopic pyloromyotomy with open (n=102, n= 200), 2 papers on laparoscopic hernia repair (n=18, n=83), and others included one each on fundoplication (n=40), orchidopexy (n=82) and varicocele repair (n=624). Two trials looked at VATS in the treatment of empyema (n=18, n=40) and one looked at fetoscopic surgery (n=24). 65% of the trials had been published in the last 5 years. The median CONSORT score for MAPS was 59 (interquartile range 54-68), which was significantly lower than previously reported CONSORT scores for adult general surgery RCTs. The median Jadad score was 1 (range 0-4), only 27% had a Jadad score of greater than 3. This is similar to findings in adult general surgery.

CONCLUSION: There is a paucity of RCTs in MAPS and although more are being published the quality of reporting of the evidence is still inadequate. There is evidence that the trials published are at risk of bias demonstrated by low Jadad scores. We welcome further RCTs of good quality which will add to the available evidence base for MAPS.

P128 LAPAROSCOPIC INGUINAL HERNIA REPAIR IN CHILDREN – NO LIGATION, JUST RESECTION

Mario Riquelme MD, Arturo Aranda MD, Mario Riquelme-Q, Christus-Muguerza Hospital, Monterrey, Mexico

BACKGROUND: There have been descriptions of several techniques for inguinal hernia repair in the pediatric population without a definitive advantage over the open procedure. High recurrence rates have been reported using minimally invasive techniques in which the patent processus vaginalis has been completely or partially left in place.

METHODS: First a proper informed consent is obtained. During July 2003 to July 2007, we performed an inguinal hernia repair on 91 patients using a laparoscopic technique in which we completely resect the patent processus vaginalis and the parietal peritoneum surrounding the internal inguinal ring. This allows the peritoneal scar tissue to close the area of the ring. Also, this scarring occurs in the extent of the inguinal canal where the dissection took place, therefore causing the same peritoneal scarring and sealing of the inguinal floor. We had 76 males whom we did a purse string stitch around the ring with polyester suture 3-0 RB1, and 15 females to whom no stitch was done. Age ranges are between 2 months to 11 years old (mean 3.5 y/o). All patients were operated using 3 trocars: one 5 mm trocar in the umbilical port, and two 3mm on the flanks.

RESULTS: There were no immediate surgical complications. Operative time was on the range of 35-72 minutes (average 40 minutes). Close follow-up in the clinic has been of 5 months to 4 years without a single recurrence. In 4 cases we have done a laparoscopic evaluation of the contralateral side due to associated cryptorchidism, in which we are able to confirm a complete closure of the interior inguinal ring. Other bilateral cases were done on a single operation.

CONCLUSION: No recurrences have been observed. We conclude that laparoscopic repair of inguinal hernia in the pediatric population is feasible using this technique. And, that the most important thing on a pediatric hernia is to resect the processus vaginalis and peritoneum parietalis surrounding the ring and by doing this, there is no need to close the inguinal ring.

P129 LAPAROSCOPY IN PEDIATRIC SITUS INVERSUS TOTALIS: CASE REPORT AND LITERATURE REVIEW

Belinda Dickey MD, Sean Barnett MD, Marc A Levitt MD, Cincinnati Children's Hospital Medical Center

PURPOSE: Appendicitis in the setting of situs inversus is a rare occurrence and can present both diagnostic dilemmas as well as surgical challenges. A recent case allowed us the opportunity to highlight the potential challenges and laparoscopic modifications when operating on pediatric patients with situs inversus.

METHODS: We present a case of acute appendicitis in an 8 year old boy with a known history of complete situs inversus. We took this opportunity to review the literature of laparoscopic surgery in the setting of situs inversus.

RESULTS: An uncomplicated laparoscopic appendectomy was performed on our patient with modification of our port sites to adapt to the situs inversus.

CONCLUSIONS: We believe the laparoscopic approach to the pediatric patient with situs inversus is ideal in managing acute appendicitis. There are however, important modifications and considerations that must be undertaken especially for advanced procedures. Pre-operative planning of the procedure is essential to anticipate any potential challenges. Laparoscopy can aid in the diagnosis if pre-operative workup is unclear in these patients. Table and patient positioning in relation to the primary surgeon and assistant will likely be opposite of the usual procedure. Moveable videoscreens should be available for ease of the operation. An initial diagnostic laparoscopy should be performed to help plan strategic port placement. Port placement can usually be anticipated to be the mirror image of the conventional procedure, however should be patient-tailored. Most "right-handed" surgeons need to be prepared for the reversed spatial relationships. If laparoscopy is being performed for another indication in a pediatric patient with situs inversus, the surgeon should consider also performing a prophylactic appendectomy. Laparoscopic procedures are feasible in the pediatric situs inversus patient and can be safe and effective if the potential challenges are first anticipated.

POSTER ABSTRACTS



P130 NEW LAPAROSCOPIC FLIP FLAP TECHNIQUE VERSUS CONVENTIONAL INGUINAL HERNIA REPAIR IN CHILDREN. IS IT WORTH IT?

Mohamed E. Hassan BA, AR Mustafawi BA, Alwasl Hospital, Ward 5, Dubai, UAE

BACKGROUND/OBJECTIVES: Inguinal hernia repair is one of the most frequently performed pediatric surgical operations. Several pediatric laparoscopic inguinal hernia repairs were introduced. Still there is unresolved debate regarding the feasibility of laparoscopy for treating pediatric inguinal hernia.

METHODS: A retrospective cohort study enrolled 33 patients who underwent congenital inguinal hernia repair by either new laparoscopic flip flap technique or conventional open repair. Patients were divided into two groups according to the type of surgery, Group A who underwent the new laparoscopic technique and group B who underwent conventional open repair.

RESULTS: Group A included 15 patient (mean age 39 months) while group B 18 patient (mean age 44 months). Mean operative time was 47.5 minutes for Group A versus 27.5 minutes for Group B. Intraoperative complications for group A included 1 case (7%) of vas deference injury, and 3 cases (20%) the flaps were teared during suturing while in Group B no intraoperative complications were encountered. In both groups the mean postoperative hospital stay was 5.5 hours. Postoperative follow up for 3 months revealed recurrence in 4 cases in Group A (27%), while no recurrences in Group B.

CONCLUSION: Our preliminary experience showed unsatisfactory outcome with the laparoscopic flip flap hernia repair in children. In spite the advancement in the application of laparoscopy in pediatric surgery, still conventional open hernia repair is the gold standard for children in our experience. Future studies with more numbers and long term follow up should be conducted.

P131 INGUINAL HERNIA REPAIR THROUGH A MINIMAL SKIN INCISION: IS LAPAROSCOPE AN INDISPENSABLE INSTRUMENT FOR INGUINAL HERNIA REPAIR IN CHILDREN?

Makoto Suzuki MD, Masahiro Hatanaka MD, Junko Fujino MD, Kazunori Tahara MD, Yuki Ishimaru MD, Hitoshi Ikeda MD, Department of Pediatric Surgery, Dokkyo Medical University, Koshigaya Hospital

BACKGROUND: Recent studies show that the laparoscopic inguinal hernia repair in pediatric surgery is feasible. Minimized invasiveness, no groin incision, and better cosmetic result are cited as the advantages over the traditional open procedure. The purpose of this study was to evaluate whether the open procedure could overcome this disadvantages.

METHODS: A retrospective study enrolled 162 patients who underwent inguinal hernia repair by our novel open technique with minimal skin incision (< 10 mm). Successful rate, length of incision, and the average hospital charge were evaluated.

RESULTS: This procedure was accomplished successfully in >90% patients except for patients with huge hernia sac. The length of skin incision was 7mm (5.5-9.5 mm). The cosmetic results were excellent with almost invisible scars in the inguinal region. There were no intra- /post-operative complication. For the evaluation of a secure repair offered by the traditional open procedure, we observe the inguinal ring laparoscopically. There are no recurrences to date. The average hospital charges were about \$580 for open method versus \$1080 for laparoscopic method and the cost of the materials for the open procedure is extremely lower than the laparoscopic procedure.

CONCLUSION: Open hernia repair through the minimal incision procedure can be accomplished good cosmetic result and the hospital charge is lower than the laparoscopic procedure. So the laparoscope might not be necessary for repairing hernia in pediatric surgery, and our novel open hernia repair with minimal skin incision is suitable in our

experience. Further study with more number and long term follow up should be conducted.

P132 APPLICATION OF LAPAROSCOPIC GANGRENOUS APPENDECTOMY WITH PERFORATION

Hongwei Xi MS, Qiangqiang Cui MS, Debing Meng MS, Depart. of Surgery, Shanxi Children Hospital, Taiyuan, Shanxi 030013

ABSTRACT OBJECTIVE: To explore the application of laparoscopic gangrenous appendectomy with perforation. Method 35 cases (22 boys, 13 girls, age 3-14 years) of gangrenous appendicitis with perforation having undergone laparoscopic appendectomies were reviewed. All of them received general anaesthesia with endotracheal intubation. Pneumoperitoneum was introduced. Appendix was extracted from trocar after silk ligation mesoappendix and electromy. Appendiceal stump endoligated. Results Laparoscopic gangrenous appendectomy with perforation was used in 35 cases. No severe adhesion and other complications were occurrence, but 6 cases had rectal tenesmus, and disappearance after 3 days. All of 35 cases were discharged after 6 to 8 days. Conclusion Laparoscopic gangrenous appendectomy with perforation has minimal complication rate, little wound and rapid recovery.

KEY WORDS: Appendicitis, Laparoscopy, Gangrenous perforative

P133 TECHNICAL ASPECTS OF THE LAPAROSCOPIC MANAGEMENT OF A LATE PRESENTING DUODENAL WEB

Anies Mahomed MD, Beelke Dhondt MD, Department of Paediatric Surgery, Royal Alexandra Children's Hospital, Brighton, UK.

BACKGROUND: Duodenal web is an uncommon congenital cause of intestinal obstruction, and in the majority of cases is surgically treated in the neonatal period. Late presenting webs are even rarer. Conventional management involves open web resection and duodenoduodenostomy with or without duodenoplasty. More recent experience with minimally invasive techniques support simple web resection as the exclusive management strategy.

AIM: To demonstrate the technical details of laparoscopic management of a late presenting duodenal web using static, pre and post operative radiological and intra-operative images.

METHOD: A 2 year old patient with a classic windsock duodenal web was managed using a 3 port (5mm) laparoscopic approach. The anterior wall of a massively enlarged 2nd part was exposed before opening by ultrasonic scalpel between percutaneously placed stay sutures. A thickened web was identified and prolapsed through the duodenotomy, and the position of the ampulla of Vater confirmed by gallbladder compression. A 60 to 70 % resection of the anterolateral aspect of the web was undertaken with ultrasonic scalpel, preserving the ampulla. Web resection was assisted by a percutaneous stitch placed through its apex. The duodenum was closed in the plane of opening using interrupted inverting, seromuscular, intracorporeal sutures.

RESULT: Total operating time was 75 minutes and the patient was allowed fluids on recovery with soft diet a day later. He was discharged on day 3 with parents reporting a significant change in his feed tolerance. A barium study performed 4 weeks later demonstrated a markedly improved proximal duodenal profile with unimpeded passage across the site of previous web obstruction.

CONCLUSION: Laparoscopic management of congenital duodenal web is a safe procedure which allows for optimal visualisation of all structures at all time. Percutaneously placed stay sutures avoid the need for more than 2 working ports. The ultrasonic dissector enables bloodless duodenotomy and web resection and does not appear to compromise duodenal healing. A single layer of interrupted intracorporeal suturing is adequate for closure of the hypertrophied duodenal wall. Neither duodenoduodenostomy nor duodenoplasty would appear to be necessary if the web is comprehensively inactivated. In many respects this experience endorses the benefits of a laparoscopic approach.



POSTER ABSTRACTS

P134 EXPERIENCE WITH A NEW ENERGY SOURCE FOR TISSUE FUSION IN PEDIATRIC PATIENTS

Todd A. Ponsky BA, Steven S. Rothenberg BA, Rocky Mountain Hospital for Children, Denver, CO, USA

INTRODUCTION: Options for effective techniques for vessel and tissue sealing in infants and children are limited because of the size and limited intracorporeal space of many pediatric patients. We evaluated a new energy source, "The ForceTriad" (Tyco Health, West Windsor, NJ) Ligasure which delivers both monopolar and bipolar energy in a 5mm format, that allows for tissue fusion and vessel sealing and division. This report documents our experience with this device

METHODS: A database review was performed looking for all cases that were performed in children using the ForceTriad Ligasure as the main source of hemostasis and tissue fusion. Two different handpieces were used a fine Maryland dissector type instrument with no cutting blade, and a sealer / cutter, both in a 5mm format.

RESULTS: A total of 60 cases were performed in children from September, 2006 to September, 2007 using the ForceTriad. The two most common cases were Nissen fundoplication (40 cases, Weight:8.5-95kg (avg 40.7kg), OR time: (15-70min) Avg 32min, Avg days to full feeds: 2), and lung lobectomy (11) cases, Weight:4.6-63kg (avg 27.3kg), OR time: (60-180min) Avg 123min, Avg hospital days: 3.1). Other procedures included, excision of choledochal cyst (3), aortopexy, closure of bronchopleural fistula, resection of a giant thymic cyst (1), thymectomy (1), parathyroid adenoma excision (1), total colectomy (2), and intestinal duplication resection (2). There were no failures of vessel or tissue fusion and no operative complications. A delayed hydropneumothorax developed in one lung resection and spontaneously resolved.

CONCLUSION: The ForceTriad provides a safe and effective energy source in a 5mm format. As compared to previous versions of the Ligasure there is less sticking, a quicker seal, and no tissue fusion failures.

P135 STRESS IS GOOD – PERFORMANCE UNDER STRESS AFTER SIMULATION TRAINING

Erik La Hei MD, James Wood MD, Rachel D'Cruz BS, Children's Hospital at Westmead, University of Sydney

BACKGROUND: See one, do one, teach one' is attributed to Halsted. He was the first to suggest that surgical training be based on observational learning followed by a period of graduated performance under supervision. This paradigm is changing with the increase in minimally invasive surgery and the increased availability of virtual reality simulation. Skill acquisition during Halstedian training occurs by explicit motor learning. This is known to result in less stable motor performance under stress than skills acquired by implicit motor learning. This can result in impaired dexterity and increased errors. We hypothesized that a surgical skill learned implicitly may deteriorate less under stress

METHODS: 10 medical students were allowed two hours of training without supervision using the LapSim surgical simulator. Each student received only the standardized feedback provided by the LapSim software, during training. Each student was then randomly assigned to perform a simple assessment of these skills either unobserved or in presence of a "critical" specialist laparoscopic surgeon. The specialist surgeon criticized performance according to a pre-arranged script. Routine performance metrics recorded by the LapSim software were analysed.

RESULTS: There was no deterioration in implicitly learned surgical skills in the stressful environment Furthermore all candidates performed significantly better in the stressful exam environment than in the practice environment ($p=0.007$). This was partly to be due to a significantly lower rate of tissue damage in the exam environment but the difference persisted when the damage coefficient was not applied and the z score only (incorporating all metrics of performance) was analysed. There was no significant difference between the improvement seen between those candidates exposed to stress during the exam and those able to take the

exam without stress. This lack of difference persisted when no damage coefficient was incorporated in the score.

CONCLUSION: Basic laparoscopic skills learned implicitly during simulation training may be less susceptible to deterioration under stress. We believe this has important implications for the incorporation of simulation in the curriculum.

P136 FEASIBILITY OF MICROLAPAROSCOPY FOR SURGICAL PROCEDURES OF ADVANCED COMPLEXITY IN CHILDREN

Salmai Turial MD, Martin Schwind MD, Veronika Engel MD, Alexandra Weltzien MD, Cordula Scherer MD, Felix Schier MD, Department of Pediatric Surgery, University Medical Center Mainz

PURPOSE: Previously we accomplished over 230 routine laparoscopic procedures by microlaparoscopy. In the next step, we conducted a prospective study to determine the value and the feasibility of the microlaparoscopic approach for surgical procedures of advanced complexity in children. We report our preliminary experience with these small instruments and the possibilities and limits of pure 2mm instrumentation and 1,9mm laparoscopy.

METHODS: A 1,9mm laparoscope is inserted at the umbilicus. Additional 2mm trocars are placed according to the type of procedure. The study includes 15 children (aged 2 weeks to 11 years, median 2.8 years). 18 advanced complexity procedures were carried out for Nissen fundoplication, thoracoscopic congenital diaphragmatic hernia repair in a newborn, hiatoplasty and repair in upside-down-stomach, laparoscopically assisted pull-through for Hirschsprung disease in a newborn and laparoscopy for acute abdominal illness e.g.

RESULTS: No complications occurred due to the exclusive use of 2mm instruments and 1,9mm scope. All procedures were done successfully by microlaparoscopy except one fundoplication has been converted to open procedure for reason of anatomical deformities. The average operative time for the 5mm group and for the 2mm group was similar compared to a similar age and type-of-intervention group.

CONCLUSION: The microlaparoscopic approach for surgical procedures of advanced complexity in pediatric surgery is feasible, safe and effective in condition of indications, surgeon's experience and the facilities. The advantages of microlaparoscopy are obvious: minimum of access trauma, "nearly scarless" healing, less risk of damage to abdominal organs, possibly less adhesions and postoperative pain. Spacious abdominal cavities require 5mm laparoscopes for better distant view. We suggest to further consider the use of the microlaparoscope for more advanced laparoscopic procedures in children.

P137 ROBOTIC-ASSISTED PAEDIATRIC LAPAROSCOPIC SURGERY: PRELIMINARY REPORT

P. Seymanti MD, L. Sangiorgio MD, A. Pini Prato, C. Carlini MD, Dipartimento di Scienze Chirurgiche in Et  Pediatrica-Ospedale Infantile SS, Antonio e Biagio e Cesare Arrigo, Alessandria, Italy

Since early 80's robots in operative theatre became of routine use. Robotic-assisted laparoscopy was first introduced in adults to facilitate surgery in war areas. Huge improvements have been made with progressive miniaturization and sophistication of instrumentation. Therefore, robotic-assisted paediatric surgery became more and more common. Nonetheless, robots in paediatric surgery are used at present only on selected cases in major research institutes. We will present our preliminary experience on 5 paediatric patients aged less than 16 years who underwent robotic-assisted laparoscopic procedures at the "Ospedale Infantile" in Alessandria, Italy in an 18-month period since January 2006 to June 2007. Data regarding clinical features of our patients, indications, procedures performed, technical details, length of surgery, length of hospitalization and final outcome will be provided and discussed. Less than 60 reports have been published up to date regarding this topic in pediatrics. To the best of our knowledge this is the first report from Italy on

POSTER ABSTRACTS



this regard. Our patients were operated on with the Da Vinci device which was available in the Adult General Surgery Department. The possibility to share facilities of relatively uncommon utilization allowed us to develop this preliminary experience, which, otherwise, would be extremely expensive and time-consuming.

P138 ROBOTIC REPAIR OF CONGENITAL DIAPHRAGMATIC ANOMALIES

Bethany J. Slater MD, Laura A. Phearman RN, John J. Meehan MD, Seattle Childrens Hospital & Regional Medical Center, University of Iowa Children's Hospital, Department of Surgery - Stanford University

PURPOSE: Congenital diaphragm anomalies including eventration, Morgagni diaphragmatic hernias (M-CDH), and Bochdalek diaphragmatic hernias (B-CDH) have been closed using minimally invasive surgery (MIS) with success in some reports. However, success has not been uniform in B-CDH and several reports published discouraging MIS as a method for closing these defects. These papers speculate the difficulty of closing the most posterolateral aspect of the defect with the rigid instruments may play into their less than satisfactory result. Robotic surgery is a new technology which may help close B-CDH anomalies as well as repairing other diaphragmatic anomalies, more effectively. Robotic instruments may allow for better access to these areas and we offer a preliminary report on our series of patients with diaphragmatic anomalies.

METHOD: With IRB approval, we retrospectively reviewed patients who underwent robotic repair for their diaphragmatic anomaly. There were two patients with eventration, five B-CDH and one M-CDH. All procedures were performed using the Standard Da Vinci surgical robot (Intuitive Surgical; Sunnyvale CA) with one camera arm (5 mm 2-D scope) and two instrument arms (5 mm).

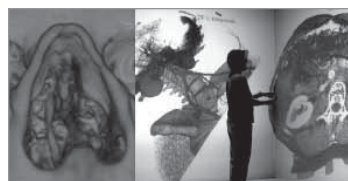
RESULTS: Average age was 3.9 months (4 days - 12 months). Average weight was 3.6 kg (2.2 kg - 10.5). Four of the five B-CDH patients were approached through the chest, one from the abdomen. Our first B-CDH attempt from the chest and our first eventration attempt were both converted to thoracoscopic procedures. From each failure, we developed better trocar placement and positioning ideas and were successful on the subsequent attempts. The abdominal approach for one B-CDH patient was selected because they were only 2.2 kg and we felt that a thoracic approach would not have allowed for enough room for the articulating robotic instruments to maneuver. The one patient with the M-CDH had their repair from an abdominal approach. The eventrations were both approached from the chest. Average operative time was 1 hour 20 minutes. No recurrences have developed with an average follow-up of 18 months.

CONCLUSION: Robotic surgery is safe and effective for repairing diaphragm anomalies in small children. Although the size of the patient in relation to the size of the current available robot can seem problematic, these issues can be overcome with careful planning. Although we prefer the thoracic approach for repairing the B-CDH, some smaller newborns - perhaps those less than 2.5 kg - may do better with the abdominal approach if using robotics since the articulating instruments requiring a significant length in order to maneuver.

P139 AN IMMERSIVE VIRTUAL REALITY ENVIRONMENT FOR PATIENT DATA VISUALIZATION AND ENDOSCOPIC SURGERY PLANNING

Jung Leng Foo MS, Thom Lobe MD, Eliot Winer PhD, Iowa State University, and Blank Children's Hospital

Visualizing patient data in a 3D representation can be an effective surgical planning tool. As medical imaging technologies improve with higher resolution scans, the use of virtual reality for interacting with 3D medical data adds another level of representation realism. The proposed software is designed to load and display any DICOM/PACS compatible image data for visualization and interaction in an immersive virtual environment. There are currently two separate modes: In the Examiner



enhance important structures. In the Fly-Through mode, the surgeon can create a pseudo-path along which a virtual endoscopic "camera" can navigate inside patient. As the camera moves along its path, it can also rotate 360 degrees for a complete view. A dataset of a patient's head was used as a test case, where the pseudo-path is set to be along the nasal passage. Figure 1a (left) shows the entrance to the nasal cavity. These tools allow the surgeon to perform virtual endoscopy on any suitable structure. The software is highly scalable as it can be used on a single desktop computer to a cluster of computers for an immersive multi-projection virtual environment. By wearing a pair of stereo goggles, the user is immersed within the model itself, thus providing a sense of realism as if the user is inside the patient. Figure 1b (right) shows the software in a four-wall virtual reality system.

P140 THORACOSCOPIC REPAIR OF ESOPHAGEAL ATRESIA AND TRACHEAESOPHAGEAL FISTULA (EA-TF) - A SINGLE SURGEON EXPERIENCE

Coskun Ozcan MD, Cisem Akyildiz MD, Ege University Faculty of Medicine, Department of Pediatric Surgery, Izmir, Turkey

BACKGROUND/AIM: Advances in minimally invasive surgical techniques has led to increasing use of thoracoscopic procedures in neonates. Patients with EA-TF who have been operated with this technique in our department were evaluated for the efficacy and the complications of thoracoscopic surgery.

PATIENTS/METHOD: During the last 2 years, a total of 12 patients with EA-TF underwent thoracoscopic repair. The mean age at operation was 3 days (1-9) and the mean weight was 2.7 kg (2.1-3.6). Various cardiac anomalies (n=9), annular pancreas (n=1), renal agenesis (n=1), and mandibular fusion defect (n=1) were the associated anomalies. Thoracoscopy via 3 ports (one 3 mm, two 5 mm) were done under the vision of a 30 degrees telescope. During the procedure right lung was collapsed by CO2 insufflation at a pressure level of 5-7 mmHg. After the dissection, the fistula was ligated with an endoscopic clip and divided. Proximal and distal parts of the esophagus were prepared and anastomosed with simple 5/0 PDS sutures. A chest tube was inserted through one of the trocar tracts.

RESULTS: The first operation of the series were converted to an open thoracotomy while the procedure was completed thoracoscopically in all the other 11 patients. The mean days of mechanical ventilation were 6.3 days (2-24). A leak at the anastomosis was developed in one patient because of postoperative empyema. This patient underwent thoracoscopic debridement and the leak was healed with conservative measures. No anastomotic leak was developed in the rest of the patients. An anastomotic stricture was developed in 6 patients during a mean follow-up period of 9.5 months and treated with dilatations and antireflux medication. A recurrent fistula was developed in one patient, and this patient was scheduled for reoperation.

CONCLUSION: Thoracoscopic repair of EA-TF can be performed safely in neonates and the results are comparable to previous reports of babies undergoing repair through a thoracotomy.

P141 THORACOSCOPIC MANAGEMENT OF COMPLICATED PARAPNEUMONIC EFFUSIONS IN YOUNG CHILDREN

S. Alhadi, M Asgar, Salmaniya

From the Divisions of pediatric surgery Salmaniya medical complex, Manama, kingdom of bahrain.

OBJECTIVE: To describe the role of Thoracoscopic management of complicated parapneumonic effusions (CPE) in very young children .



POSTER ABSTRACTS

DESIGN: Children with complicated parapneumonic effusions were prospectively studied between January 2007 and November 2007.

RESULTS: Seven cases of CPE were studied during the a-year period. In 3 cases a bacterial pathogen was found, with *S pneumoniae*. Two cases have chest tube before thoracoscopy. Chest x-ray, Ultrasound and CT scan done for all patients. Age of the patients from 5 to 24 months. All patients received antibiotic 3-6 weeks prior to thoracoscopy without improvement. All patients received fibrinolytic agent on second postoperative day. Duration of chest tube drainage ranging from 4-7 weeks, febrile days from 2-4 days, one case required ventilation in ICU, and hospital stay from 5-7 days.

CONCLUSION: The primitive outcome of Thorascopic management of complicated parapneumonic effusions (CPE) in very young children in our series is feasible and safe.

P142 MRI AS AN ALTERNATIVE TO CT IN THE PREOPERATIVE EVALUATION OF PECTUS EXCAVATUM

Caterina Morelli MD, Roberto Lo Piccolo MD, Marco Ghionzoli MD, Antonio Messineo MD, Anna Meyer, Children's hospital of Florence, Italy

Pectus excavatum (PE) is the most common defect of the anterior thoracic wall (1:1000-1:300). Repair is recommended for cosmetic reasons and for patients with the following pectus severity indexes: Haller Index (HI) >3.25, Vertebral Index (VI) >30, Frontosagittal Index (FSI) <30, determined by chest X-ray or CT scan. The use of CT, although it provides valuable information on PE as well to guide the Nuss repair, is controversial due to exposure to ionizing radiation.

Aim: Our hypothesis was that similar information on pectus indexes could be obtained using MRI instead of CT.

MATERIAL/METHODS: From January 2006 to December 2007, fifteen consecutive patients (aged 15 ± 3) with PE requiring Nuss repair underwent as pre-operative evaluation to chest ultrafast-CT and MRI. MRI was performed using a Philips Eclipse 1.5T while CT with a Brilliance 40. T1-weighted sequential slices were obtained during normal breathing, after ECG synchronization to reduce artefact from cardiac movement. Other T2-weighted slices were obtained during full inspiratory and full expiratory breath-holds.

RESULTS: All the information obtainable with CT scan were acquired from MRI. The pectus severity indices were easily obtained. Moreover, thanks to the possibility to do three passes in the same spot, MRI allowed us to acquire a more physiologic knowledge of the deformation. On the contrary, CT scan images were obtained, to reduce the amount of irradiation, only in full inspiration breath-holds.

CONCLUSIONS: From our results, MRI showed to be a technique of great value in the evaluation of patients with PE not only allowing us to get the same information obtained by CT but also to reach a more complete information on the defect. The lack of ionizing radiation, excellent soft tissue contrast and multiplanar capabilities are the major advantages of MRI.

P143 THORACOSCOPIC TREATMENT OF PULMONARY HYDATID CYST IN CHILDREN

Mustafa Kucukaydin MD, Ahmet N. Ciftler MD, Mahmut Guzel MD, Mehmet Uysal MD, Mustafa E. Dorterler MD, Serkan Arslan MD, Ahmet B. Dogan MD, Kadri C. Sulubulut MD, Ali Aslan MD, Erciyes University, School of Medicine, Department of Pediatric Surgery

BACKGROUND/AIM: Surgical treatment has remained the standard option in the management of hydatid disease. However, surgeons were able to replicate the principles of conventional surgery using minimally invasive techniques. Herein, we report six pediatric cases of pulmonary hydatid cyst treated successfully using the thorascopic approach.

MATERIAL/METHODS: From April 1999 to August 2007, nine boys and two girls aged between 6 and 16 years (average 9 years) old have been operated on for hydatid cyst of the lung by a thorascopic procedure. The patients were put in a full lateral decubitus position. Two 5-mm

and one 10 mm cannulas were placed in a triangular fashion to the mid axillary line. A 5-mm 30° telescope was introduced through middle port. For a noncomplicated cyst the hypertonic saline was injected, and then the endocyst was extracted using a 10 mm endobag. Irrigations, partial decortications and partial excision of the exocyst were performed and the cyst in using suture ligation for air leak. Infected endocysts and partial exocyst were extracted as the same manner. A chest tube was placed through the lower port site.

RESULTS: It was a vomited cyst in 1 case, a pyopneumocyst in 6 cases, and a noncomplicated and univesicular cyst in 4 cases. The patients had uneventful postoperative courses. Median follow up period was 4 years (range 4 months to 8 years). In follow-up period, they were free of symptoms with no recurrence on chest x-ray.

CONCLUSION: All stages of the surgical treatment of hydatid cyst of the lung in children can be easily accomplished by thoracoscopy. It is our impression that thorascopic management of pulmonary hydatid cyst is safe, offers the advantages of less pain, rapid recovery, less short and long term morbidity, and good cosmesis.

P144 THORACOSCOPIC TREATMENT OF COMPLICATED ESOPHAGEAL ATRESIA

Aixa Reusmann MD, Gastón Elmo MD, Mariano Boglione MD, J. P. Garrahan, Buenos Aires, Argentina

AIM: Report the feasibility of the thorascopic approach for the treatment of complications related to esophageal atresia. We present 2 cases of patients with EA initially corrected by thoracoscopy. Both developed anastomotic stricture and images consistent with recurrent fistula and were explored again by thoracoscopy.

CASE 1: A 9 months old male presented with an anastomotic stricture and a recurrent fistula secondary to a thorascopic repair of an EA. He underwent a second thorascopic approach to treat these complications. The esophagus was completely surrounded until the orifice of the fistula appeared in the trachea; it was repaired with interrupted suture. The fibrotic scar of the previous anastomosis was resected and a new one was made with full-thickness suture of the same material. At 18 months of life he feeds orally, without gastroesophageal reflux, dysphagia or respiratory pathology. The contrast study shows an esophagus with good caliber.

CASE 2: A 2 months old female with EA type III corrected thorascopically presented a severe anastomotic stricture that required dilatation. After the second dilatation coughing related with feeding and contrast in the airway appeared. With the suspicion of a recurrent fistula, another thoracoscopy was carried out. After dissecting the esophagus no fistula was evident so the stricture was resected and a new end to end anastomosis was made. At 10 months of life she has a normal esophagogram and is asymptomatic.

DISCUSSION: Almost all of our patients remain sedated and paralyzed in the immediate postoperative to minimize the risk of anastomotic leakage, especially if the anastomosis was made under tension. Both patients suffered accidental extubation and were intubated again, this might have contributed to the appearance of leakage and posterior anastomotic stricture and recurrent fistula. Recurrent fistula has an incidence between 5 and 14%, and it requires surgical treatment. Anastomotic strictures present in 30 to 40% of patients and usually respond to dilatations. Only intractable strictures need resection. We think that thoracoscopy is a useful approach for the EA, for the initial correction as well as for the treatment of complications. It offers an excellent visualization of structures with minimal adhesions.

P145 TUBE THORACOSTOMY IS RARELY NECESSARY FOLLOWING THORACOSCOPIC LUNG BIOPSY

David A. Partrick MD, The Children's Hospital, University of Colorado

PURPOSE: After completing an intrathoracic procedure, a tube thoracostomy is routinely placed. However, after an uncomplicated lung biopsy the chest tube rarely drains much fluid and is usually not associated

POSTER ABSTRACTS



with a prolonged air leak. The study hypothesis is that following thorascopic lung biopsy, once lung reinflation is demonstrated and no air leak is present, tube thoracostomy is no longer necessary and the chest tube can be safely removed intraoperatively.

METHODS: All children undergoing thorascopic lung biopsy were identified from 2001-2006. Operative notes were reviewed to identify if the chest tube was removed intraoperatively or if it remained in place postoperatively. Any complications were identified from the medical record.

RESULTS: Forty children had thorascopic lung biopsy performed by the author over the 6 year time period. Mean age of the study population was 6.6 years with a range of 4 weeks to 18 years. Single lung biopsies were obtained in 18 children and 22 involved two or more biopsy specimens during the same procedure. An endostapling device was utilized to obtain the lung biopsy in 21 patients (mean age 11.7 years) while endoloop suture was utilized for the remaining 19 (mean age 1.0 year). The majority of the children (29 or 73%) had their chest tubes removed intraoperatively. Only one patient required placement of a pigtail catheter postoperatively to resolve a persistent pneumothorax.

Diagnosis	CT Removed	CT Remained
Lung Nodule	12	4
ILD	11	4
Pulm HTN	4	2
Cystic Fibrosis	2	1
Total	29	11

CONCLUSIONS: Tube thoracostomy drainage beyond the operating room is often unnecessary after thorascopic lung biopsy. The majority of these chest tubes can be safely removed intraoperatively if there is no evidence of an air leak.

P146 VATS UNDER THORACIC EPIDURAL ANAESTHESIA IN CHILDREN – OUR EXPERIENCE IN 23 CASES

Jitendra D. Hazarey MS, R. S. Swarnakar MD, S. J. Hazare, B. M. Rajurkar, Getwell Hospital & Research Institute, JNMC, Sawangi, Meghe

Video assisted thorascopic surgery (VATS) is an excellent modality to manage complicated empyemas in children. however its wider applicability, specially in a resource starved rural area , is the need of one lung ventilation for prolonged procedures which adds to the cost and the need of a senior anaesthesiologist for every procedure. hence an attempt was made to proceed with VATS under regional block alone with the full preparation for intubation and one lung ventilation. 23 children , all above 2 yrs of age , were evaluated prospectively. 19 were of complicated empyemas of various durations and 4 were indicated for diagnosis and biopsy. We hereby present our results, difficulties encountered and the advantages noted.

P147 VIDEO ASSISTED TORACOSCOPIC (VAT) REMOVAL OF MATURE CYSTIC MEDIASTINAL TERATOMA IN A 4 YEARS OLD CHILD

Daniela Codrich MD, Gloria Pelizzo MD, Jürgen Schleef, Clinic of Paediatric Surgery and Urology, IRCCS Burlo Garofolo Children's Hospitalm Triestem Italy

BACKGROUND/AIM: Few sporadic cases of thorascopic removal of mediastinal masses in children are discussed in literature. We report the case of a large anterior mediastinal cystic-solid teratoma, removed by thorascopic assisted surgery in a small child.

CASE REPORT: A 4 years old female child was referred to our Institution because of a large mass (10x5x3cm) of the anterior mediastinum, without alteration of tumor markers. In the year before

admission, the child suffered from repeated upper respiratory infections and persistent coughing, which led to performance of a chest X-ray that showed an enlarged mediastinum, without shift and tracheal compression. This finding was subsequently studied with MRI and CTscans: a mixed cystic and solid lesion of about 10cm was evidenced. Blood test showed negative inflammatory signs and absence of tumor markers. The lesion was completely removed under general anesthesia with conventional intubation through a thorascopic approach with one 5mm and two 3mm-trocars, with the monopolar cautery. The patient was positioned in a lateral right decubitus, with slight (30°) elevation of the affected side. CO2 insufflation pressure was kept to 4mmHg to favour homolateral lung collapse. The cysts were evacuated before removal through an endobag. A thoracic drainage tube was left in place and removed the following day. Procedure duration was 210 minutes. No intraoperative complications were reported. Postoperative course was uneventful and the child was discharged on the third postoperative day.

CONCLUSIONS: Removal of mediastinal mature cystic teratoma is feasible with thorascopic surgery. This approach allows for a greater exposure of the anterior mediastinum rather than a sternotomic incision. Mass dissection was easily performed, even though particular attention was required to avoid any damage to the pericardium. We suggest this approach as a valid option for benign anterior mediastinal masses.

P148 TREATMENT OF FUNNEL CHEST FOLLOWING PREVIOUS THORACOTOMY

Takashi Nogami PhD, Makoto Yagi PhD, Hiroshi Yoshida PhD, Hideki Yoshida PhD, Division of Pediatric Surgery, Department of Surgery, Kinki University of Medicine

PURPOSE: A Nuss procedure spreads worldwide as a minimally invasive surgery for funnel chest. However, serious complications such as the cardiac perforation or lung damage have been reported. We have to take care of the treatment of funnel chest, especially in the patients who have the past history of thoracotomy. In this paper, we report those three cases.

CASE 1: A 12-year old boy was referred to our Hospital with the complaint of funnel chest . A chest X ray and CT examination showed a mass shadow at the right upper field, which was suspected of CCAM. In this case, a Nuss operation was performed following a right upper lobectomy by the VATS.

CASE 2: A five-year old boy. He underwent an open heart surgery for VSD at four months after birth. At the Nuss operation, the blunt dissection between the sternum and the pericardia was succeeded and the procedure was completed.

CASE 3: A six-year old girl. She experienced an open heart surgery for VSD at six months after birth, complicated chylothorax. To treat it, pleura was adhered detection through the small incision at the epigastrium. Therefore we performed Ravitch procedure in this case.

CONCLUSION: A Nuss procedure after previous thoracotomy needs a careful examination to avoid complications.

P149 MINIMALLY INVASIVE SURGERY IN ECTOPIC EXTRALOBAR PULMONARY SEQUESTRATION: ABOUT SIX CASES

Luc Joyeux MD, Nathalie Mejean MD, Thierry Rousseau MD, Jean-Francois Couaillier MD, Emmanuel Sapin PhD, Service de Chirurgie Pédiatrique, Hopital D'enfants, CHU Dijon

PURPOSE: ExtraLobar Pulmonary Sequestrations (ELS) are rare congenital anomalies. They are usually intrathoracic lesions. The authors report 6 cases of prenatally diagnosed lesions in ectopic sites treated during infancy with minimally invasive surgery (MIS).

METHODS: from January 2001 to December 2007, of 12 cases of ELS prenatally diagnosed and retrospectively reviewed, we isolated 6 children with atypical locations: 3 were hiatal lesions (mediastinal with intraabdominal dumbbell extension) and 3 left suprarenal. Their



POSTER ABSTRACTS

prenatal findings by Doppler ultrasonography (DUS) were heterogeneous hyperechogenic masses supplied by a systemic artery. Their locations were respectively inframediastinal preaortic (n=2), intraabdominal suprarenal (n=3) and hiatal intradiaphragmatic (n=1). All prenatal diagnoses were confirmed by DUS and computed tomography (CT) scan with intravenous (IV) contrast infusion and 3-dimensional (3D) reconstructions. In one left suprarenal case, the ELS looked intrathoracic on CT scan. In all cases, at least 1 anomalous systemic artery was visualized. 3 infants were symptomatic. Until now 5 cases underwent MIS, performed from the 15th day to the 14th month of life (mean, 7 months).

RESULTS: 4 procedures were performed laparoscopically and 1 thoracoscopically. There were 2 abdominal conversions. Nevertheless no intra or postoperative complications occurred. Hospital stay ranged from 2 to 5 days (mean, 3 days). All had uneventful follow-up (mean, 3 years; range, 3 months-6 years). Histopathology confirmed the diagnosis of pure pulmonary sequestration in all 5 cases.

CONCLUSIONS: ELS is a rare congenital bronchopulmonary foregut malformation. It is detected prenatally with increasing frequency by routine prenatal DUS, eventually completed by fetal magnetic resonance imaging (MRI) scan. Ectopic sites of ELS may result in diagnostic difficulties. Neuroblastoma and enteric duplication are the most frequent differential diagnoses. Postnatal diagnosis by DUS and either CT or MRI scan with infusion is realised to evaluate the exact extension of the structure and identify feeding blood vessels. Early surgical resection of ELS may be realized: (1) immediately if it is symptomatic; (2) from 6 months of age because of parental concerns facing a diagnostic dilemma, structural and infectious complications, possible mixed histology. MIS in small infants is a feasible and safe technique. Thanks to its magnification, the endoscopic approach allows meticulous control of the vessels coming into the mass, provides a definitive treatment and offers the benefits associated with MIS.

P150 LAPAROSCOPIC MANGEMENT OF FORAMEN OF MORGAGNI HERNIA IN CHILDHOOD

Mohamed Ben Brahim MD, Oumama El Ezzi RN, Amine Ksia RN, Mongi Mekki MD, Kais Maazoun MD, Lassaad Sahnoun MD, Imed Krichene MD, Mohsen Belghith MD, Abdellatif Nouri MD, Department of Pediatric Surgery-Fattouma Bourguiba Hospital-Monastir-Tunisia

Foramen of Morgagni hernia is a rare form of congenital diaphragmatic hernia. We report the use of laparoscopy to repair the diaphragmatic defect in 7 patients. The data concerning 7 infants with Morgagni hernias have been retrospectively reviewed. Their ages at presentation ranged from 7 months to 11 years. There were 4 males and 3 females. The majority of patients had repeated chest infections. The diagnosis was made on chest radiograph and barium enema. The hernia sacs were excised and the defects repaired in all patients by placement of interrupted synthetic nonabsorbable sutures between the posterior and the anterior rim of the defect. The children had uneventful postoperative courses, were discharged home early, and had no evidence of recurrence after a follow-up ranging from 8 months to 3 years. This technique for primary laparoscopic repair of Morgagni hernia is easy to perform and well tolerated by patients. Laparoscopic repair is considered to be a suitable and safe procedure for the treatment of Morgagni hernia.

P151 THORACOSCOPIC SURGERY FOR POSTERIOR CERVICO-MEDIASTINAL TUMORS IN CHILDREN

Delphine Demède MD, Frederic Hameury MD, Laurent Guibaud MD, Raphael Rousseau MD, Pierre Mouriquand MD, Pierre-Yves Mure MD, Division of Pediatric Surgery, Debrousse Hospital, Lyon, France

PURPOSE: The surgical approach for posterior cervico-mediastinal lesions is often complex and potentially delabrant. We report our experience of thoracoscopic surgery in such indications.

METHODS: Between november 2006 and january 2008, an indication

of posterior cervico-mediastinal mass excision was retained in 3 children (mean age of 16 months). Two lesions were located in the right postero-superior mediastinum (a neurenteric cyst and a ganglioneuroblastoma) and a lesion in the left postero-superior mediastinum (a neuroblastoma).

RESULTS: Thoracoscopy allowed a very good exposure of the lesions and the adjacent anatomic structures. The surgery was complete in two cases and incomplete in one (neuroblastoma covering the origin of left vertebral artery). No open conversion was necessary. Two children presented a postoperative Horner syndrome regressive in 6 weeks.

CONCLUSION: Thoracoscopic surgery of cervico-mediastinal lesions appears attractive because of its mini-invasive approach. It allows an excellent exposure to lesions which are often difficult to access through open surgery.

P152 ENDOSCOPIC MIC-KEY BUTTON PLACEMENT FOR CONTINENT VESICOSTOMY

Francois Becmeur PhD, Isabelle Lacreuse MD, Raphael Moog MD, Francesco Molinaro MD, Anne Schneider MD, Marie Devos MD, Department of Paediatric Surgery University of Strasbourg

INTRODUCTION: The use of a Mic-Key button for intermittent emptying of the bladder has been proposed by Hitchcock RJ et coll. en 2007.

Percutaneous button placement under endoscopic control is reported.

METHODS: The percutaneous gastrostomy kit according to Russel (Cook[®]) was used under cystoscopic control. The U-Stitches technique according to Georgeson allowed to secure the bladder to the abdominal anterior wall. A guide was introduced into the bladder through a needle. Three dilators, respectively 12, 14, and 16 FR, allowed the path for a probe or immediately the button. U-Stitches are removed one week later.

RESULTS: Since one year, three percutaneous continent vesicostomies were performed. Patient's ages were 2, 3 and 19 years. They were 1 girl and 2 boys. The indications for vesicostomy were : hypotonic bladder in a girl who suffered from a prenatal obstacle due to a double ureterocele, hypotonic bladder due to urethral valves in a boy and failure of a Mitrofanoff in a girl with a myelomeningocele. The procedure was safe without any intraoperative complication and needed less than 30 minutes. There are no complication or difficulty during the short follow-up (<11 months). No leakage is observed round the button. Patients and parents are satisfied.

CONCLUSION: When intermittent urethral catheterization can not be established, Mitrofanoff urinary diversion seems to be a major surgery for patients and their parents. Intermittent bladder emptying may be required for a transitory period. There is a place for a reversible vesicostomy. In these cases, button vesicostomy seems to be a good alternative. Until now, vesicostomy was classically performed with an open procedure.

We propose a percutaneous technique with an endoscopic control. Complementary treatments can be envisaged during the same time as botulinic injections into the detrusor or partial closure of the cervix with Macroplastic or Déflux. These are mini invasive techniques, easily acceptable, which can be proposed. If this kind of treatment is effective, it may avoid further major surgery. Physical handicaps may be treated with simple techniques. It is easier to convince patients to begin a treatment with minimal invasive procedures for improving their status. Percutaneous button vesicostomy placement under endoscopic control is safe and feasible and must be evaluated with large series.

P153 LAPAROSCOPIC REDO PYELOPLASTY IN INFANTS AND CHILDREN

Elisabeth Carricaburu MD, Hamdan Al Hazmi MD, Olivier Grimaud MD, Aurelie Schultz MD, Alaa El Ghoneimi PhD, Department of Pediatric Surgery and Urology, Hopital Robert Debre, Ap-Hp, University Paris 7

PURPOSE: Management of failed pyeloplasty remains problematic in young children. Laparoscopic redo pyeloplasty was already reported with

POSTER ABSTRACTS



success in children and adults. We have studied feasibility and results of laparoscopic redo pyeloplasty in young children and infants.

MATERIAL/METHODS: Since December 2006, all failed pyeloplasty after open surgery were operated by laparoscopy without taking in consideration their age. Four children aged: 5, 8, 21 months and 14 years were operated. Our study was limited to the youngest 3. Indications were persistent severe hydronephrosis associated with at least one of the following: repeated febrile UTI, flank pain, total obstruction on retro or antegrade imaging. Redo surgery was done after a mean interval 8 months (5 wks to 17 ms). All redos were done through 4 trocars transperitoneal approach.

RESULTS: The procedure was feasible in all without conversion. The cause of the persistent obstruction was clearly identified: twisted anastomosis, stenosis, malposition of the anastomosis. Mean operative time was 208 min (180-225). A double J stent was left in all cases. Mean hospital stay was 3.3 days. After a mean FU of 9 months, imaging has shown improved hydronephrosis and children are asymptomatic.

CONCLUSIONS: Though the retroperitoneal laparoscopic approach is our routine approach for pyeloplasty in children, we believe that in redo cases transperitoneal approach has the advantage of avoiding the re-dissection of lumbar fossa. The procedure was safely feasible in young children with successful short term results. The procedure remains technically demanding and long even in experienced hands

P154 LAPAROSCOPIC EXCISION OF URACHAL CYST IN PEDIATRIC AGE: 3 CASES REPORT

Salvatore Fabio Chiarenza MD, MariaGrazia Scarpa MD, Luciano Musi MD, Dept of Pediatric Surgery, S. Bortolo Hospital, Vicenza, Italy

INTRODUCTION: urachal remnant is the persistence of the embryological communication between the bladder and the umbilicus. There are different types of remnants: patent urachus, diverticulum, sinus, and urachal cyst that represent 30% of urachal anomalies. Excision is necessary for symptoms, or in asymptomatic patients due to potential malignant change. In paediatric patients, only a few cases of laparoscopic removal have been described. We report 3 cases of urachal cyst excision by laparoscope.

CASE REPORTS: Case 1: a 8 year-old boy presented with acute abdominal pain simulating pelvic appendicitis. Laparoscopy revealed a normal appendix, and an infected urachal cyst. Case 2: a 4 year-old girl presented with hematuria and dysuria. Renal ultrasound was negative but an hypoechogenic cyst on the bladder dome was noted. VCUG and renal scintigraphy were negative. Case 3 a 13-year old girl presented with recurrent abdominal pain. Coincidental finding of hypoechogenic cyst was noted on the bladder dome. In all three cases, complete three port laparoscopic removal was performed. The fistulous communication between the bladder and the cyst was identified, ligated, and separated. In cases 2 and 3, a small cuff of bladder dome was resected. Indwelling Foley catheter was removed on postoperative day 2. Patients were discharged on postoperative day 3. The diagnosis of urachal cyst was confirmed histologically. Follow-up (min.14 max 36 month) was without complications.

CONCLUSIONS: Laparoscopy is effective in the diagnosis and treatment of urachal remnants. It can be safely performed in pediatric patients, including for cases of infected urachal cysts.

P155 LAPAROSCOPIC NEPHRECTOMY FOR WILMS' TUMOR AFTER CHEMOTHERAPY: OUR INITIAL EXPERIENCE

Maria Grazia Scuderi MD, Andrea Di Cataldo PhD, Lucia Virardi MD, Mario Falsaperla MD, Aurelio Di Benedetto PhD, Vincenzo Di Benedetto PhD, U.O.C. di Chirurgia Pediatrica, Azienda Ospedaliero-Universitaria "Vittorio Emanuele", Azienda Ospedaliero-Universitaria "Policlinico" Università degli Studi di Catania.

PURPOSE: Open surgery is the classic approach for resecting Wilms' tumor (WT); anecdotal experiences of laparoscopic nephrectomise

have been reported. We report the result of our initial experience the laparoscopic nephrectomy for unilateral Wilms' tumor in children who underwent preoperative chemotherapy.

MATERIALS/METHODS: Three children with unilaterial unresectable nonmetastatic Wilms tumor were included in the Italian AIEOP WT 2003 protocol, received four weekly doses of vincristine (1,5mg/m₂) and two doses of actinomycin D(1,35 mg/m₂) and underwent laparoscopic nephrectomy. Their age was 2, 5 and 7. Despite the age difference, the technique was carried out according to the same procedure With the patients put in a flank position (30°), a transumbilical incision (12mm) was performed to realise the pneumoperitone. The abdominal cavity was always evaluated laparoscopically before the introduction of the other trocars according to tumor location. The tumour was dissected and extracted through a pfannenstiel incision. A intraperitoneal drain was placed in all cases.

RESULTS: All patients successfully underwent laparoscopic nephrectomy with complete removal of tumour. No conversions were necessary. The histological exam confirmed in all the cases the diagnosis of WT, stage III for tumoral margin invasion (case 1 -2) or tumoral rupture (case 3).

The mean (range) operative time was 143,3 min (120-180 min), the drain was removal after three days and the mean hospital stay 5,3 (4-7) days. The estetical results was good.

CONCLUSIONS: Laparoscopic nephrectomy for unilateral Wilms' tumor is feasible in children after chemotherapy. The initial results are encouraging compare to open surgery. The procedure is safe but because of its complexity a good pratical experience of surgeon is required.

P156 LAPAROSCOPIC SURGERY FOR VARICOCELES IN CHILDREN: A SINGLE CENTRE AUDIT

Charles Keys MD, Louise Barbour MD, Atul Sabharwal MD, RHSC, Glasgow

BACKGROUND: Varicoceles are associated with a time dependant decline in testicular function. The pathophysiology and timing of this remains unclear. However surgery for adolescent varicoceles is a relatively common procedure. There are several treatment options for this condition and in 1999 laparoscopic management was commenced at our institute. We performed an audit to compare our results with those reported in the literature.

METHODS: A retrospective casenote review of patients identified from our theatre database was performed. We reviewed patient demographics, indications, technique used, grade of surgeon and outcomes. A review of the literature was carried out to identify a gold standard to compare our results with.

RESULTS: Between 1999-2007 we operated on 24 adolescent varicoceles. All left side. Median age 13.5yrs (range 8-16). Indications for surgery included high grade varicocele, discomfort and testicular atrophy. All patients underwent laparoscopic Palomo technique dividing all vessels and lymphatics. The grade of primary operator was consultant (54%) and trainee (46%). Complications included wound infection (4.1%), hydrocele (12.5%) and recurrence (8.3%).

We found no consensus view regarding the management of varicoceles in adolescents within the literature, however, our outcomes compared favourably with other published results using the laparoscopic Palomo technique.

CONCLUSIONS: Laparoscopic management of varicoceles is safe and effective at our institute. The indications and timing of surgery remain varied. The surgery is performed by both consultants and trainees.

P157 URETEROSCOPY IN YOUNG CHIDREN

Bernard Boillot MD, Youssef Teklali MD, J. A. Long MD, Christian Piolat MD, J.J. Rambeaud MD, Depts of Urology and Pediatric Surgery, CHU Grenoble France

The authors report the results of a retrospective study of 10 children under 12 years old, and operated by ureteroscopy, for renal or ureteric stone.



POSTER ABSTRACTS

PATIENTS/METHODS: Between 2005 and 2007, 10 children under 12 years old (9 months to 11 years) have been treated for lithiasis : 18 ureteroscopic procedures were realised in 6 boys and 4 girls. 5 of these children were under 3 years old. Stones were ureteral in 4, pelvic in 4, and staghorn in 2.

Rigid ureteroscope Ch 7.5 was used 17 times, and flexible 1 time. A in situ laser-lithotripsy was realised 10 times, and a basket extraction 8 times. All children had post operative ureteral drainage.

RESULTS: 8 patients are stone free with a distance from 6 months to three years (mean : 15 months); 2 complications were noted during the procedures : a periureteric extravasation, and an accidental section of the guiding wire by laser .

CONCLUSION: Ureteroscopy is a mini invasive technique, wich can be used in children, with the same technical rules, and probably the same rates of success and complications .

P158 MINIMALLY INVASIVE TREATMENT OF BLADDER CALCULI AFTER REPAIR OF CLOACAL ANOMALY: A CASE REPORT

Akihiro Shimotakahara PhD, Yoshifumi Kato PhD, Kyeong Deok Lee PhD, Nana Nakazawa MD, Geoffrey J. Lane PhD, Atsuyuki Yamataka PhD, Department of Pediatric General and Urogenital Surgery, Juntendo University School of Medicine

CASE REPORT/SURGICAL TECHNIQUE: A 10-year-old girl had repair of cloacal anomaly at the age of 14 months, elsewhere. A posterior sagittal approach was used for reconstruction of her anorectum, vagina, and bladder, and a tube cystostomy had been placed for control of urinary incontinence secondary to functional bladder neck obstruction. She began to have bouts of recurrent severe lower abdominal pain and cystography and cystoscopy revealed multiple bladder calculi up to a maximum size of 2cm. She was referred to our institute for management of the calculi. In the operating room, a cystoscope was inserted into the bladder through the urethra, the cystostomy tube was removed, and a 5mm port was placed at the tube cystostomy site. A disposable endoscopic grasper was then inserted through the 5mm port and used to hold larger calculi under cystoscopic control so they could be fragmented using a pneumatic lithotripter (Swiss Lithoclast) inserted through the side channel of the cystoscope. All smaller calculi and calculi fragments were able to be taken out through the 5mm port without difficulty. Post-operative recovery was uneventful. At follow-up of 10 months, she is clinically well with no recurrence of calculi.

P159 UNUSUAL PRESENTATION OF ANTENATAL OVARIAN TORSION: FREE FLOATING ABDOMINAL CYSTS. OUR EXPERIENCE AND SURGICAL MANAGEMENT

Francesco Camoglio PhD, Nicola Zampieri MD, Gabriella Scirè MD, Alberto Ottolenghi PhD, Department of Surgical Sciences, Pediatric Surgical Unit, University of Verona, Policlinico G.B. Rossi, Piazzale L.A. Scuri n.1, 37134 Verona, Italy

BACKGROUND: Abdominal cystic formations in newborns are relatively common and often diagnostic suspicion arises before birth as a result of ultrasound scans carried out during pregnancy. Prenatal ovarian torsion is a rare condition very difficult to manage in the first days of life. We report and discuss the management of prenatal ovarian torsion with a free floating abdominal cyst detected on prenatal ultrasound.

MATERIALS/METHODS: We recorded the cases of antenatal abdominal cysts detected on ultrasound at the Department of Antenatal Diagnosis between January 2003 and January 2007. Only the patients with a free floating cyst were included in the study. Clinical and surgical findings were then recorded.

RESULTS: Two out of 57 patients underwent surgery for a free floating abdominal cyst during the second day of life. Postnatal Ultrasound scan,

Doppler ultrasound and laparoscopic exploration were useful to identify an unusual presentation of antenatal ovarian torsion with a complete atresia of the Fallopian tube.

CONCLUSIONS: The cases reported in this study suggest that a good clinical approach to all cases of abdominal cysts detected on prenatal ultrasound scans require postnatal Doppler and abdominal ultrasound with a laparoscopic exploration. Free floating abdominal cysts are rare but, at the same time, strictly correlated with autoamputation of the ovary/Fallopian tube complex.

P160 BALLISTIC SHOCK WAVE LITHOTRIPTOSCOPY

Sebastian Ionescu MD, Simion Tirlea MD, "M. S. Curie" Children Hospital, Bucharest, Romania

PURPOSE: The aim of this study is to evaluate the endoscopic lithotripsy efficiency and outcomes in pediatric patients with ureteral, vesical and urethral calculi.

METHODS: A retrospective review of medical records of 65 patients with ureteral, vesical and urethral calculi, operated between 1998-2007, in "M. S. Curie" Children Hospital, Bucharest, was conducted; all patients came for the check-up.

RESULTS: In this period, 48 patients with ureteral calculi, 11 patients with vesical calculi and 6 patients with urethral calculi underwent this endoscopic procedure. Children were aged between 6.8 - 16.5 years. In case of ureteral bilateral localization we realized two step lithotripsy, the second after 2 weeks period. The medical conservative treatment was inefficient in all those cases. There were not significant incidents or accidents, during or after the procedure. The size of the calculi ranged between 1.2 - 3.5 cm in diameter. The Cook stent was placed in the first 21 patients with ureteral calculi and took out after 8 - 10 days, as an outpatient procedure. In all patients a bladder catheter was placed for 1 - 2 days. We registered a hospitalization period of 3 - 4 days. One single dose prophylactic antibiotherapy was administrated during the operation. For urethral localizations, the mean operating time was 45 minutes and varied from 75 minutes for the first cases to 25 minutes for the last ones.

CONCLUSIONS: We believe that this technique is a safe, effective method of treatment of urinary tract lithiasis. It can be considered a cheaper alternative of ESWL.

P161 ALTERNATIVES IN LAPAROSCOPIC APPROACHES FOR RETROPERITONEAL PATHOLOGIES PRESENTING AS AN ADRENAL MASS

Baran Tokar MD, Oktav Bosnali MD, Huseyin Ilhan MD, Umut Alici MD, Dilsad Demet MD, Ozgur Aktas MD, Eskisehir Osmangazi University, School of Medicine, Department of Pediatric Surgery, Eskisehir, Turkey

BACKGROUND: Clinical and radiological investigations may show a retroperitoneal mass in adrenal gland (AG) location. If laparoscopic exploration is needed for biopsy or mass excision, there are several alternative approaches. The left and right sides should be considered differently.

METHODS: Seven children who needed laparoscopic exploration of AG location were included in this study. Data from the literature review also helped to make a classification of the approaches.

RESULTS: Our data and literature review show that laparoscopic exploration of the right side could be performed with retroperitoneal or transperitoneal approaches. For the left side, exposure could be done by retroperitoneal, transperitoneal or transdiaphragmatic way. Transperitoneal exploration of the left side could be subdivided as suprasplenic, infragastric or retrocolic. Our cases were a preperitoneal bronchogenic cyst neighbouring right AG, a right kidney upper pole abscess, a neuroblastoma on the right side, a simple liver cyst just near the right AG, a left kidney upper pole hematoma, a left AG hemorrhage, and a left aldosterone secreting adrenal adenoma. While transperitoneal approach

POSTER ABSTRACTS



was preferred in six patients, retroperitoneoscopy was performed in patient with right kidney upper pole abscess. For the left side transperitoneal exploration, we preferred infragastric or retrocolic exposures.

CONCLUSIONS: Depending on presentation of the lesion and the experience, surgeon must preoperatively determine how to make exposure of the mass located in the AG area. To know the alternatives also provides an easy conversion of the approach for exploration of the mass during the operation.

P162 LAPAROSCOPIC PYELOPLASTY FOR REPAIR OF URETEROPELVIC JUNCTION OBSTRUCTION IN CHILDREN

Manuel Lopez MD, Francois Becmeur PhD, Francesco Molinaro MD, Emmanuelle Guye MD, Raphael Moog PhD, François Varlet MD, Nord and Haute-pierre Hospital, University Hospital of Saint Etienne and Stranbourg, France

PURPOSE: To report our initial experience with laparoscopic pyeloplasty (LP) in children with pelvi-ureteric junction (PUJ) obstruction, to describe the evolution and to evaluate the results for these patients.

MATERIALS/METHODS: Between may 2003 and january 2007, we retrospectively reviewed the records of 32 consecutive children, the mean age was 7,7 years old with unilateral PUJ obstruction and deterioration of renal function on isotope renography, who underwent LP. The patient was placed in a _ lateral position with three ports. The PUJ was resected and the anastomosis made using absorbable sutures. A JJ stent was inserted by laparoscopy in a majority of patients. Follow-up included clinical and ultrasound assessment, and isotope renography at 6 months.

RESULTS: LP was feasible in 29 of 32 patients (91%). The procedure could not be completed by laparoscopy in three patients, the main reason being difficulty in completing the anastomosis. Only one case of a big redundant renal pelvis was reduced. Stent insertion was successful in all, except in one patient. An aberrant crossing vessel was found in twelve patients. For two of them we held up the aberrant crossing vessel and ureteropelvic junction by two points of vicryl, without the needed pyeloplasty. For the others 10 cases we performed a LP enabled ureteric transposition. There were 3 postoperative complications; pyelonephritis in two patients and one patient required operative intervention for PUJ leakage, and underwent nephrostomy with a further uneventful course. The mean operative time was 152 minutes (range 120 to 270 min), and the average hospital stay was 4,7 (4-8) days. In one patient the JJ stent was not in the bladder at the time of removal by cystoscopy, and ureteroscopy was used to retrieve it. Mean follow-up was 22 months (range 2 to 56 months). A total of 29 patients (91%) were asymptomatic after removal of the double JJ stents, showing reduction of the degree of hydronephrosis in all patients, and had also improved PUJ drainage on isotope renography or sonography.

CONCLUSIONS: LP is effective and safe in children with minimal morbidity and gives excellent short-term results. The feasibility is also excellent in patients younger than 1 year. The transabdominal approach revealed good exposition without a disadvantage for the patient. However the LP is more difficult and the operative time-remains longer than open pyeloplasty.

P163 ENDOSCOPIC TREATMENT OF MODERATE AND HIGH GRADE VESICoureTERAL REFLUX IN CHILDREN USING DEXTRANOMER/HYALURONIC ACID INJECTION

Mustafa Kucukaydin MD, Ahmet N. Ciftler MD, Mehmet Uysal MD, Mahmut Guzel MD, Muammer H Poyrazoglu MD, Zubejde Gunduz MD, Ahmet B. Dogan MD, Ali Aslan MD, Erciyes University School of Medicine, Departments of Pediatric Surgery and Pediatric Nephrology

BACKGROUND/AIM: Renal parenchymal injury in vesicoureteral reflux (VUR) occurs early, in most patients before age 3 years. It is generally believed that prevention of urinary tract infections may decrease the amount of renal parenchymal damage. Endoscopic treatment for VUR

has become an established alternative to long-term antibiotic prophylaxis and ureteral reimplantation. We retrospectively evaluated the effectiveness and safety of dextranomer/hyaluronic acid copolymer (DHAC) injection for moderate and high grade VUR in children.

MATERIALS/METHOD: Between 2002 and 2007, 102 patients, including 38 boys (37%) and 64 girls (63%), with an average age of 4 years (range 4 months to 13 years) underwent endoscopic treatment for VUR with DHAC (Deflux, Urodex). VUR was unilateral in 58 patients (57%) and bilateral in 44 (43%) (146 refluxing ureters). Reflux was grade II in 7 ureters (5%), III in 72 (49%), IV in 58 (40%) and V in 9 (6%). Dimercapto-succinic acid scan (DMSA) was performed in 102 children before injection and it demonstrated renal scarring in all the patients.

RESULTS: All patients underwent endoscopic treatment on an outpatient basis. VUR completely resolved in 103 ureters (70%) after a single injection of DHAC and it was downgraded to grade I in 9 (6%). Of the ureters 35 (24%) required a second injection and 17 (12 %) required a third injection and 13 ureters (9%) in 10 patients underwent antireflux surgery to resolve reflux.

CONCLUSIONS: Endoscopic treatment with DHAC is safe and highly effective for eradicating moderate and high grade VUR in children. Early intervention with endoscopic DHAC injection in children with moderate and high grade VUR may protect against renal scarring.

KEYWORDS: cicatrix, hyaluronic acid, kidney, ureter, vesico-ureteral reflux

P164 LAPAROSCOPIC APPROACH TO OVARIAN MASS IN CHILDREN AND ADOLESCENTS: ALREADY A STANDARD IN THERAPY

Jan Patino Mayer MD, Marcos Bettoli MD, Martina Hüging MD, Irina Hayek MD, Klaus Schaarschmidt PhD, Helios Klinik Berlin Buch, Germany, Pediatric Surgery Division; Childrens hospital of Eastern Ontario, Canada

INTRODUCTION: Functional cysts, ovarian torsion and benign neoplasms are the most common ovarian masses among young adolescents. The laparoscopic approach to giant ovarian cysts in paediatric population may be difficult regarding the risk of cyst rupture and limited working space.

METHODS: The experience of diagnosis and treatment of ovarian tumors operated in our clinic in the last 7 years was summarized in this study, to evaluate the treatment by laparoscopic surgery of adnexal disease occurring in young girls.

RESULTS: 11 patients were reviewed with pre-operative imaging by MRT scan or sonography, laboratory values and intra - operative findings. None resulted malignant in histology. All resections of ovarian cysts were performed laparoscopically. Outcome was uneventful in all.

Conclusion: Treatment is indicated if the diagnosis is in question, the cyst persists, in case of ovarian torsion or the patient is symptomatic.

Laparoscopy has become the approach favoured by most paediatric surgeons for the treatment of ovarian cysts. All surgical procedures for ovarian cysts should spare functional ovary as much as is technically possible. Simple cysts should be fenestrated. Complex or functional cysts should be excised, with preservation of the remaining ovary by careful preparation. Even in young girls, laparoscopic surgery can be performed in an acceptable manner using regular instruments designed for adults. Laparoscopic approach has satisfying results, with guarantee of good cosmetic outcome, important aspect for treated patients.

P165 VESICoureTERAL REFLUX TREATMENT OF NEUROGENIC BLADDER CHILDREN BY ENDOSCOPIC INJECTION

S. Alhindi BA, M Asgar BA, Divisions of Pediatric Surgery, Salmaniya Medical Complex, Manama, Kingdom of Bahrain

OBJECTIVE: To describe the role of deflux management of Vesicoureteral Reflux in neurogenic children.



POSTER ABSTRACTS

DESIGN: Children with neurogenic bladder with high grade vesicoureteric reflux were prospectively studied between January 2002 and may 2007.

Results: 19 cases of neurogenic bladder with high grade vesicoureteric reflux (38 units) were prospectively studied during the 4.5-year period. All cases had dilated upper tract. 15 cases doing CIC on daily bases underwent bilateral deflux injection. 4 cases had vesicostomy before deflux injection. Ultrasound and MCUG and isotope scan done for all patients as well urine culture. Age of the patients from 8 months to 6 years. All patients received antibiotic prior to endoscopic injection and one week after. All patients had US on 6 month postoperative day and MCUG on 12 months postoperative day. All patients discharged one day postoperative day. 29 ureteric refluxing units had complete resolved VUR after one injection. 6 ureters had grade one reflux and 3 ureters had grade two. Re-injection done after one year for grade two reflux. 4 of the 6 had follow up after one year and showed complete resolution and two unit return to grade one.

CONCLUSION: Management of Vesicoureteral Reflux in neurogenic children by endoscopic deflux injection is effective as short time and need long time follow up.

P166 LAPAROSCOPIC MANAGEMENT OF NON-PALPABLE TESTES (NPT)

Enaam F. Raboei MD, Sayed M. Sayed MD, King Fahd Armed Forces Hospital, Jeddah (KFAFH)

AIM: To study the value of laparoscopy & plan a management algorithm for dealing with non-palpable testes (NPT).

MATERIAL/METHODS: Retrospective study of medical files for patients operated for undescended or impalpable testes at KFAFH from (1999/2003). No U/S or MRI used for diagnosis of NPT. No hormonal therapy. No Bailez technique for laparoscopic access.

RESULTS: There were 143 undescended testes in 125 patients. Age range was (6 months - 12 years). More than 60% of the patients were below 1 yr of age. 15 bilateral 75 palpable 52.4%, 61 NPT (42 left & 19 right 68.9%), 7 (4.2%) lost prior to therapy. 11 open exploration 7.7%. Fifty 35% laparoscopic procedures for NPT. Laparoscopic findings were: No testis: 2 (4%), Entering: 19 (38%), Abdominal normal: 25 (50%) and Hypotrophic/atrophic: 4 (12%). 11 associated anomalies related to testes. Eleven patients have had other non related anomalies. Laparoscopic procedures according to findings were 25 standard orchidopexy (50%), 4 laparoscopic assisted orchidopexy, 2 orchidectomy, 18 (46%) two stages Fowler - Stephens (FS), 2 one stage FS and 3 laparoscopic orchidopexy (LO).

FOLLOW UP: Range from 1 - 6 years: 44 (93%) of the testes are of acceptable size and location. One (2.3%) atrophic testis after the 2 stages FS procedure. The Five (100%) testes post 1 stage FS or LO are of acceptable size and location.

CONCLUSION: The exact location of the testis is identified in 100 % of laparoscopic exploration for NPT. The high success rate of 100% with LO and one stage SF (excluding a long term complications) make them our procedure of choice in the future.

P167 ENDOSCOPIC TREATMENT WITH DEFLUX FOR REFLUXING DUPLEX SYSTEMS

Richard A. Courtney MD, David B. Tashjian MD, Kevin P. Moriarty MD, Baystate Children's Hospital

PURPOSE: The aim of this study was to review the experience of a single institution with the endoscopic Deflux® (Q-Med Scandinavia; Uppsala, Sweden) procedure and assess its effectiveness in treatment of refluxing duplex systems.

METHODS: A retrospective review of all patients that underwent endoscopic Deflux® treatment for vesicoureteral reflux (VUR) between June 2003 and July 2007 was performed. Patients with duplex ureteral systems were identified. Data collection included: age, gender, side of refluxing ureter, pre-operative radiologic grade of VUR on a voiding cystourethrogram (VCUG), presence of VUR on a radionuclide VCUG

3 months after the procedure, volume of Deflux® injected, number of Deflux® injections performed per patient, and number of patients that underwent re-implantation.

RESULTS: A total of 249 patients underwent the Deflux® procedure. Sixteen patients had duplex systems, two being bilateral for a total of 18 duplex ureteral systems. Four ureters had grade II reflux, eight grade III, four grade IV and two grade V. There were 2 males and 14 females with a mean age of 4.9 years. Deflux® injection volume ranged from 0.28 - 1.5 cc (mean 0.84cc). Fourteen ureters required one injection. Three ureters required two injections, and one ureter required three injections. The overall success rate of the procedure after a maximum of 3 injections was 95%. One patient with preoperative unilateral grade V VUR had persistent high grade reflux after two injections and opted to proceed to re-implantation. There have been no post-injection urinary tract infections, ureteral obstructions or late failures. The mean follow-up was 24 months (6 months to 48 months).

CONCLUSIONS: We conclude that the Deflux® procedure is a safe and effective minimally invasive treatment alternative for patients with refluxing duplex systems.

P168 TRANSPERITONEAL MINIMAL INVASIVE URETEROURETEROSTOMY FOR DUPLEX KIDNEY

H Steyaert MD, J Lauron MD, J.S. Valla PhD, Fondation L'Enfant Pour Enfants

Management of upper pole ureteropyelic dilatation in case of duplex kidney and well functioning upper moiety is possible using various techniques. One of the possible operations is an uretero-ureterostomy with a terminal anastomosis of the upper ureter laterally in the lower one.

Authors describe this operation conducted through a transabdominal laparoscopic route.

The two cases were left ones. In the first case one 5mm optical trocar and four 3mm operating trocars were used. In the second case only one 5 and two 3mm trocars were used.

Operation was completed in 3 hours in the first and 2 hours in the second case. A vesical catheter and an ureteral catheter were left in place for 4 days postoperatively. A drain was left in place in the abdomen for two days.

Authors show the technique used and describe some technical points in order to improve the feasibility of this elegant operation.

P169 FACTORS THAT INFLUENCE THE LEARNING CURVE IN RETROPERITONEAL LAPAROSCOPIC NEPHRECTOMY IN CHILDREN

Kiki Maoate MD, Adrian M. Skinner MD, Spencer W. Beasley MD, Dept of Paediatric Surgery, Christchurch Hospital, Christchurch, New Zealand

We analysed our initial experience of laparoscopic nephrectomy to evaluate the effect of experience and configuration of service on operative times, conversion rates and complications.

METHODOLOGY: A retrospective review of 75 consecutive children who underwent retroperitoneal laparoscopic nephrectomy or partial nephrectomy during a ten year period from 1997 at Christchurch Hospital, New Zealand was undertaken. Operative times, reasons for conversion to an open procedure, complications and the experience of the surgeon were analysed.

RESULTS: Four surgeons and a single registrar on annual rotation performed the procedure in 25 girls and 50 boys (range 8 months - 15 years). The number of cases/year ranged from 1 (1997) to 10 (2003). One surgeon performed 30% of the procedures and supervised or assisted the remainder. Operating times ranged from 38 to 225 minutes (mean 104 minutes). Over the ten year period the average operative time fell from 105 minutes to 91 minutes for combined surgeons: this compares with a mean of 187 minutes for other reported series. The operative times for all surgeons showed a tendency to reduce, but this was not marked. There were 5 conversions: because of previous inflammation and fibrosis

POSTER ABSTRACTS



(2); massive renal size (1); difficulty gaining retroperitoneal access (1) and major peritoneal breach (1). Two children had urine leakage from the ureteric stump, and one an incisional hernia.

CONCLUSIONS: This experience was vested predominantly in one surgeon who assisted or supervised a fellow consultant colleague. Operative times were not markedly influenced by experience. The relative lack of a learning curve was probably due to the procedures being performed by two surgeons familiar with laparoscopic techniques working together. This may account for the relatively short operative times, low conversion rate, and low complication rate.

P170 OUR TRANSPERITONEAL LAPAROSCOPIC DISMEMBERED PYELOPLASTY EXPERIENCE: THE IMPORTANCE OF REUSABLE LAPAROSCOPIC INSTRUMENTS

Gulce Hakguder MD, Oguz Ates MD, Ali Tekin MD, Osman Z. Karakus MD, Cimen Olguner MD, Mustafa Olguner MD, Feza M. Akgur MD, Dokuz Eylul University, Medical School, Department of Pediatric Surgery, Izmir Turkey

AIM: Recent technical advances in laparoscopic instruments permit to perform more delicate manipulations on vulnerable tissues with fine suture materials, such as TLDP. Transperitoneal laparoscopic dismembered pyeloplasty (TLDP) is rapidly becoming an acceptable procedure for the treatment of ureteropelvic junction obstruction (UPJO) in the pediatric population. We herein present our TLDP experience using reusable instruments.

MATERIALS/METHOD: Between January 2006-December 2007, 12 patients (9 boys, 3 girls), 13 systems, aging 2-14 years underwent TLDP. One 10 mm, two 5 mm trocars were used. A transanastomotic double J catheter was placed percutaneously antegrade before completing the anastomosis in all patients. Catheters were removed one month after the operation. All patients were followed and evaluated with ultrasonography and dynamic renal scintigraphy postoperatively.

RESULTS: Eight left, three right and 1 bilateral UPJO's were treated with TLDP. Among the patients, one patient was a failed open dismembered pyeloplasty patient, one had an ectopic pelvic kidney and in another patient crossing vessel was present. Bilateral UPJO patient underwent TLDP in two different sessions. No intraoperative complications were noted. Mean hospital stay was 2.2 ± 0.4 days. Scintigraphic examination showed improvement in the drainage curve in all the patients.

CONCLUSION: TLDP was performed safely in all pediatric age groups with minimal morbidity and excellent short-term results. TLDP is also feasible in the correction of failed dismembered pyeloplasties. During TLDP, the technical properties of the instruments are as important as the surgeon's experience where more delicate dissection, cutting and intracorporeal suturing are needed. Laparoscopic pyeloplasty becoming an alternative to open counterpart even in ectopic kidneys and redo cases with the advantages of shorter hospital stay and better cosmesis

P171 LAPAROSCOPIC MANAGEMENT OF NONPALPABLE TESTES

Mustafa Kucukaydin MD, Mahmut Guzel MD, Ahmet N. Ciftler MD, Kadri C. Sulubulut MD, Mehmet Uysal MD, Mustafa E. Dorterler MD, Ahmet B. Dogan MD, Serkan Arslan MD, Ali Aslan MD, Erciyes University School of Medicine, Department of Pediatric Surgery

BACKGROUND AND AIM: Diagnostic laparoscopy has changed the surgical approach to nonpalpable testes (NPT). The aim of this study was to determine the value of laparoscopy in managing patients with NPT and to suggest guidelines for the interpretation of laparoscopic findings. **Materials and Methods:** Between January 2002 and December 2007, 39 children aged 15 months - 12 years (average 4.1 years) with NPT underwent laparoscopy. NPT were located on the right side in 14 (36%) cases, on the left in 17 (46%), and were bilateral in 7 (18%) for a total of 45 testicular units.

RESULTS: Seventeen (37%) intraabdominal testes were found in 14 (36%) cases. There were 22 (48%) cord structures entering the internal inguinal ring in 19 (49%) patients, 5 cases (13%) had intraabdominal blind-ending cord structures and in one patient there were female internal genital organs. In 14 patients who had 18 intrabdominal testes, 4 second step Fowler-Stephens procedure, 9 laparoscopic and 4 inguinal orchiopexy were performed. In 19 patients with spermatic cord structures entering the internal inguinal ring, an inguinal exploration was performed. In these patients, 5 normal and 17 atrophic testes were found. The inguinal orchiopexy were performed for 5 testes and orchiectomy for 17 atrophic testes. In 5 cases that had intraabdominal blind-ending cord structures and one patient who had female internal genital organs no additional surgical procedure was performed.

CONCLUSIONS: Laparoscopy is a valuable tool in diagnosing and treating cases of NPT. The laparoscopic evaluation of abdominal testes can provide indications for suitable surgical technique; it makes most of abdominal exploration unnecessary. The value of laparoscopy is even greater if the anatomical aspect of the internal ring and spermatic cord structures is carefully evaluated.

Key words: Nonpalpable testis, laparoscopy, cryptorchidism

P172 AVAGARD™ IN PEDIATRIC LAPAROENDOSCOPIC SURGERY: SAFE, EFFECTIVE AND TIME EFFICIENT

Jeffrey S. Palmer MD, Glickman Urological and Kidney Institute, Cleveland Clinic Children's Hospital, Cleveland, Ohio, USA

OBJECTIVES: Avagard™, chlorhexidine gluconate 1% solution and ethyl alcohol 61% w/w, is a scrubless, waterless, and brushless hand antiseptic promoted as an alternative to traditional pre-surgical brush hand scrubbing. Avagard was compared to hand brush scrub preparation by the urologist in preparation for outpatient and inpatient pediatric laparoendoscopic operations.

METHODS: We evaluated the first 250 patients to undergo laparoscopic and endoscopic procedures that we used Avagard as a preoperative hand antiseptic and compared them to the last 250 consecutive laparoendoscopic patients that we performed traditional antiseptic-impregnated hand brush scrubbing. Patients and surgeon were monitored for side effects. Patients were monitored postoperatively for signs of urinary tract and wound infections. A cost analysis of the use of Avagard compared to an antiseptic-impregnated hand brush for preoperative hand preparation was performed.

RESULTS: Neither patient nor surgeon experienced any side effects including skin irritation or allergic reaction in either group. The incidence of wound infection was none in the Avagard group and 1 in the hand-scrub group, while the incidence of urinary tract infection was 1 and none, respectively (not statistically significant). All infections were successfully treated with a single course of oral antibiotics without any long-term sequelae. The use of Avagard was cost effective and more time efficient.

CONCLUSIONS: This study demonstrates that Avagard is a safe, easy to apply, fast, and effective surgical hand preparation for pediatric laparoendoscopic surgery. Its use is cost effective and time efficient in relation to the traditional surgical scrub.

P173 PASSIVE DILATION BY URETERAL STENTING PRIOR TO URETEROSCOPY: ACTIVE DILATION ELIMINATED

Jeffrey S. Palmer MD, J.S. Palmer, Glickman Urological and Kidney Institute, Cleveland Clinic Children's Hospital, Cleveland, Ohio, USA

INTRODUCTION: Active dilation of the ureteral orifice is commonly performed to access the ureteral orifice in the adult and pediatric population prior to ureteroscopy. Our study evaluated the use of passive dilation by ureteral stenting of ureteral orifices that were inaccessible at initial cystoscopic evaluation in children prior to a ureteroscopic procedure.

METHODS: We evaluated all children less than 18 years of age undergoing a ureteroscopic procedure that were not able to have the ureteral orifice endoscopically accessed by a ureteroscope.



POSTER ABSTRACTS

RESULTS: A total of 42 children between 7.3 and 14.1 years of age (median 11.2 years) underwent 45 passive dilations of initially inaccessible ureters. There were 22 boys and 20 girls. Stents remained in place from 2 to 8 weeks (median 3 weeks). All patients underwent successful flexible and/or semirigid ureteroscopy after preoperative stent placement. Active dilation of the ureteral orifice was not required in any patient at the time of ureteroscopy. There were no complications from stent placement or from the ureteroscopic procedures. No patients had a urinary tract infection. Only 1 patient required anticholinergic therapy due to bladder spasms from stent insertion, but no patient required early stent removal.

CONCLUSION: Our study demonstrates that passive dilation of the ureteral orifice in preparation for ureteroscopy is a successful, straightforward, and beneficial technique to perform in children.

P174 SAFETY AND EFFICACY OF RETROGRADE PROXIMAL SEMIRIGID URETEROSCOPY

Jeffrey S. Palmer MD, Glickman Urological and Kidney Institute, Cleveland Clinic Children's Hospital, Cleveland, Ohio, USA

OBJECTIVES: Semirigid ureteroscopy in adults and children is traditionally reserved only for distal ureteral procedures due to the risk of injury associated with proximal ureteroscopy. The potential advantages of the use of semirigid compared to flexible ureteroscopes include enhanced optics and larger working channels. The safety of proximal semirigid ureteroscopy in prepubertal children has not been established.

METHODS: We evaluated all children 12 years of age and younger who underwent attempted semirigid proximal ureteroscopy. All patients were evaluated postoperatively with renal and bladder ultrasonography and abdominal radiography if the stone was visible prior to treatment.

RESULTS: Twenty-nine consecutive children (range 3.4 to 12 years) underwent attempted semirigid proximal ureteroscopic procedures. Twenty-five children of the 29 (86%) successfully underwent 25 semirigid procedures. Only 4 children of the 29 (14%) were converted from semirigid to flexible ureteroscopy in order to successfully perform 4 ureteroscopic procedures. The indications for ureteroscopy were treatment of ureteral and/or renal pelvic calculi (27 patients) and evaluation of hematuria (2 patients). No stones of the affected system were noted ureteroscopically at the end of procedures. The range of follow-up was 0.6 to 3.6 years (median of 1.6 years) for the semirigid ureteroscopic patients. No complications occurred during any of the procedures.

CONCLUSIONS: Proximal semirigid ureteroscopy can be safely and successfully performed in a high percentage of prepubertal children to treat proximal ureteral and renal pelvis calculi as well as to perform diagnostic ureteroscopy.

P175 USE OF KISS CATHETER IN ROBOTIC-ASSISTED LAPAROSCOPIC PYELOPLASTY IN CHILDREN

Jeffrey S. Palmer MD, Glickman Urological and Kidney Institute, Cleveland Clinic Children's Hospital, Cleveland, Ohio, USA

OBJECTIVES: Kidney Internal Splint/Stent (KISS), a percutaneous nephroureteral catheter, is commonly used postoperatively after open pyeloplasty in children in order to bridge the anastomosis to permit renal drainage. One advantage of this catheter in children over the double J stent is that the former can be removed in the office without sedation or anesthesia. The KISS catheter can also be cut to the appropriate size so as to only bridge the anastomosis without entering the bladder, thereby preventing bladder spasms and urinary reflux across the anastomosis. We report on the first case using the KISS catheter in a laparoscopic pyeloplasty.

METHODS: A 7-year-old boy with left ureteropelvic junction obstruction underwent a robotic-assisted dismembered pyeloplasty. A 4-French KISS catheter was brought into the operative field through a working port, inserted into the renal pelvis/ureter defect, brought through a small pyelotomy proximal to the anastomosis, and the pelvoureteral anastomosis

was performed. The catheter was then brought through and sutured to the skin, and then connected to a small collection bag. A perinephric Penrose drain was also left in place.

RESULTS: A renal ultrasonogram performed 1 week postoperatively did not demonstrate perinephric fluid collections and the KISS catheter was removed in the office. The patient did not have any complications including urinary tract infection, urinary leak, or wound infection.

CONCLUSIONS: This case demonstrates that a KISS catheter can be utilized for robotic-assisted laparoscopic pyeloplasty in children. Additional patients are warranted to further evaluate the use of KISS.

P176 LAPAROSCOPIC PROCEDURES FOR SIMPLE RENAL CYSTS IN CHILDREN (79 CASES)

Igor V. Poddoubnyi MD, Aivar K. Faizulin MD, Kirill N. Tolstov MD, Andrei A. Isaev BS, Moscow State University of Medicine and Dentistry, Department of Pediatric Surgery

The purpose of this report is to analyze our 13 years experience in laparoscopic management of simple renal cysts in children.

Materials and methods: all 79 patients who underwent laparoscopic resection of renal cysts between 1995 and 2007, were reviewed. The age of the patients varied from 1 to 17 years: 1-3 years- 8; 4-6 years- 18; 7-10 years- 21; 11-17 years- 32. There were 49 boys (62%) and 30 girls (38%). Distinct clinical symptoms were recorded in 27 patients (34.2%), no symptoms in 52 (65.8%). The growing cystic size more than 3 cm in diameter was the indication for laparoscopic treatment. Thus the cystic size varied from 3 to 13 cm. The cyst was located in the left kidney in 32 patients (40.5%), in the right in 47 cases (59.5%). The localization of the cyst was - in the upper segment (37), in the lower segment (15), in the middle segment (13) and peripelvic (14). We used our own classification of cyst correlation with renal parenchyma and capsule that was very useful during the laparoscopic procedure: extrarenal (11 cases); subcapsular (10); intraparenchymatous (26); mixed (32 cases). 6 patients had already undergone unsuccessful sclerotherapy under ultrasound guidance (in other clinics). All 79 laparoscopic procedures were performed using three trocars. The main stages of the operation were the following: visualization and mobilization of the cyst or the renal part with cyst; intraoperative puncture, aspiration and sclerotherapy (96% ethanol) of the cyst; unroofing of the cyst - as broad as possible, with 2-4 mm of renal parenchyma resection in the cases of intraparenchymatous cysts; thorough bipolar coagulation of the remaining inner cyst cover; tamponade of the remaining cavity with omental or perirenal fat graft was performed in 26 cases when less than 50% of cystic circle could be removed.

RESULTS: The mean operating time was 45 min. (range, 25-110 min.). No serious complications occurred, there were no cases of conversion to open procedure. Cosmetic and functional results were excellent in all cases. During the period of postoperative observation (from 3 months to 13 years) no cases of recurrence were registered, no indications for additional treatment took place.

CONCLUSION: Laparoscopic resection is our method of choice in the treatment of growing simple renal cysts. This technique is universal for all cyst variants and provides 100% effectiveness without significant complications or cases of recurrence.

EVALUATION & CME FORMS: Please complete the evaluation and CME forms and return to the IPEG Registration Desk. Please allow 60 days from the event date for all forms to be processed and CME certificates to be sent out.

NOTES





NOTES

IPEG's 18th Annual Congress for Endosurgery in Children

April 22 - 25, 2009

Phoenix Convention Center,
Phoenix, Arizona, USA

(will be held in conjunction with SAGES)

**Call for Abstracts
Information
Coming Soon!**



PHOENIX 2009



www.ipeg.org



IPEG's 17th ANNUAL CONGRESS

for Endosurgery in Children

JUNE 12-15, 2008 🌸 PALAIS STÉPHANIE 🌸 CANNES, FRANCE

Save the Date!

IPEG's 18th Annual Congress for Endosurgery in Children

April 22-25, 2009 • Phoenix Convention Center • Phoenix, AZ, USA

(Held in Conjunction with SAGES)

2009 IPEG Call for Abstracts information coming soon!

2008 IPEG Corporate Supporters

*IPEG gratefully acknowledges the following companies
for their generous support.*

DIAMOND LEVEL

**Karl Storz Endoscopy -America
Stryker**

PLATINUM LEVEL

Ethicon Endosurgery, Inc.



www.ipeg.org