

TABLE of CONTENTS

GENERAL INFORMATION

| | |
|---|---|
| Administrative Office & Hotel Contact Information | 1 |
| General Assembly | 1 |
| Why IPEG, Accreditation, IPEG Member Benefits & Meeting Goals | 2 |
| Corporate Supporters | 3 |
| General Hours | 3 |
| Best Basic Science Abstract Award | 3 |

MEETING INFORMATION & COURSE DESCRIPTIONS

| | |
|--|----|
| IPEG Meeting-At-A-Glance Schedule | 4 |
| IPEG 2007 Pediatric Suturing Skills Workshop | 8 |
| Program Schedule | 9 |
| Exhibition Floorplan | 24 |
| Exhibitors | 25 |

MEETING LEADERS, FACULTY & PAST PRESIDENTS

| | |
|--|----|
| Meeting Leaders & Faculty | 27 |
| IPEG 2007 Faculty | 29 |
| IPEG Past Presidents | 33 |
| Lecturers & Special Guest Speakers | 33 |

ABSTRACTS

| | |
|------------------------------------|----|
| Disclosures | 34 |
| Oral Presentation Abstracts | 35 |
| Video Presentation Abstracts | 49 |
| Poster Abstracts Listings | 60 |
| Poster Abstracts | 66 |

ADMINISTRATIVE OFFICE



International Pediatric Endosurgery Group (IPEG)

11300 West Olympic Blvd., Suite 600 • Los Angeles, CA 90064 USA

Phone: + 1 310-437-0553, Ext. 103 or 122 • Fax: + 1 310-437-0585

Website: www.ipeg.org

Jennifer Clark, *Executive Director*

HOTEL CONTACT INFORMATION

Hilton Buenos Aires

Av. Macacha Güemes 351 Puerto Madero • C1106BKG Buenos Aires, Argentina

Tel: + 54 (11) 4891-0000 • Fax: + 54 (11) 4891-0100

GENERAL ASSEMBLY

Saturday September 8, 2007 • 11:30 am –12:00 pm

Location: Pacifico B Ballroom

All IPEG members are invited to attend the general assembly, at which IPEG members will be updated on business conducted during the past year. Additionally, the new slate of officers will be presented for approval.

WHY IPEG?

Now is an excellent time to become an IPEG member. By becoming an IPEG member, you can receive a substantial discount on the meeting registration. Your IPEG dues also include a subscription to the *Journal of Laparoendoscopic & Advance Surgical Techniques* (A US \$900 value is yours for FREE!).

ACCREDITATION

This activity has been planned and implemented in accordance with the Essentials and Standards of the Accreditation Council for Continuing Medical Education through the joint sponsorship of the Society of American Gastrointestinal and Endoscopic Surgeons (SAGES) and the International Pediatric Endosurgery Group (IPEG). SAGES is accredited by the ACCME to provide continuing medical education for physicians. SAGES designates this Continuing Medical Education activity for a maximum of 21.25 AMA PRA Category 1 Credit(s)™. Physicians should only claim credit commensurate with the extent of their participation in the activity.

- **7.0 credits for Thursday Sessions**
- **5.75 credits for Friday Sessions**
- **4.0 credits for the Suturing Workshop**
- **4.5 credits for Saturday Sessions**

IPEG MEMBER BENEFITS

IPEG exists to support excellence in Pediatric Minimal Access Surgery and endoscopy through education and research; to provide a forum for the exchange of ideas in Pediatric Minimal Access Surgery and endoscopy; and to encourage and support development of standards of training and practice in Pediatric Minimal Access Surgery and Endoscopy. Benefits of membership include:

- Subscription to our official journal: *Journal of Laparoendoscopic & Advanced Surgical Techniques* (A US \$900 savings! IPEG members receive the Journal free of charge.)
- Significant discounts on registration fees for the Annual Congress for Endosurgery in Children (*Note:* registering for the IPEG Scientific Session, as a member, will save you the equivalent of one year's dues.)
- Affordable dues for surgeons and surgeons-in-training in any country
- Opportunities to meet and discuss pediatric minimally invasive surgery with the leaders and innovators of the field
- Access to the IPEG outcomes site on the web

For more information and applications, please go to: <http://www.ipeg.org/whyjoin.html>

GOALS of 2007 MEETING

International Pediatric Endosurgery Group (IPEG)

- To advance the use of minimal invasive endoscopic surgical procedures in children
- To explore the value of new minimally invasive surgical concepts and new endoscopic surgical techniques for use in children
- To discuss controversial topics in pediatric endosurgery and the future role of endosurgery in children
- To provide opportunity for younger surgeons to acquire a knowledge of endoscopic surgical procedures in children through exposure to experts in the field
- To provide workshops to disseminate practical skills
- To describe emerging technologies in MIS

IPEG 2007 CORPORATE SUPPORTERS

Diamond Level Donors

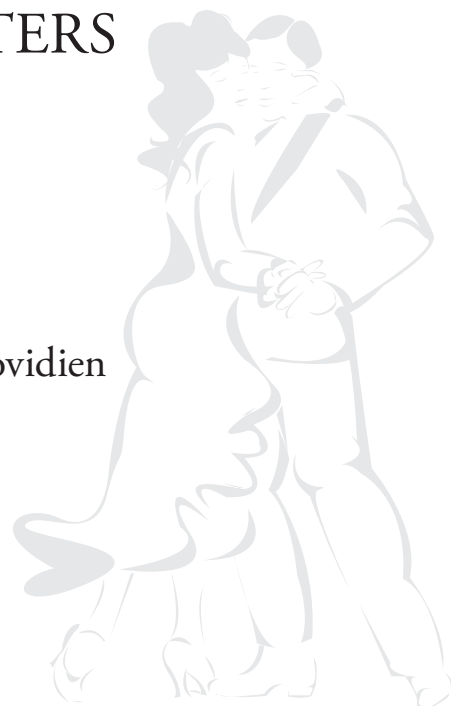- Karl Storz Endoscopy
- Stryker Endoscopy

Platinum Level Donors

- Covidien / Autosuture & Valleylab, division of Covidien
- Intuitive Surgical
- Ethicon Endo-Surgery, Inc.

Bronze Level Donor

- Gyrus ACMI



GENERAL HOURS

EXHIBIT HOURS

| | |
|-----------------------------|--------------------|
| Friday, September 7 | 10:00 am – 4:00 pm |
| Saturday, September 8 | 10:00 am – 6:00 pm |
| Sunday, September 9 | 10:00 am – 6:00 pm |

REGISTRATION HOURS

| | |
|------------------------------|-------------------|
| Wednesday, September 5 | 3:00 pm – 8:00 pm |
| Thursday, September 6 | 6:30 am – 6:00 pm |
| Friday, September 7 | 6:30 am – 6:00 pm |
| Saturday, September 8 | 7:00 am – 3:00 pm |

POSTER HOURS

| | |
|-----------------------------|--------------------|
| Thursday, September 6 | 11:00 am – 5:00 pm |
| Poster Tour | 5:00 pm – 6:15 pm |
| Friday, September 7 | 10:00 am – 4:00 pm |
| Poster Tour | 4:00 pm – 5:15 pm |

Don't forget to visit the Joint IPEG/WOFAPS Exhibit Hall!

The Hall opens at 10:00 am on Friday, September 7.

BEST BASIC SCIENCE ABSTRACT AWARD

The **Best Basic Science Abstract Award** will be a cash prize of US \$1000 to be presented during the Thursday session of the Abstract Presentations. The Program Committee will select the Award recipient. The IPEG Executive Committee is committed to education and feels this is a very concrete way to express that commitment.

IPEG 2007 MEETING-AT-A-GLANCE

Thursday, September 6

| TIME | EVENT | LOCATION |
|---------------------|--|----------------------------------|
| 8:00 am – 10:00 am | IPEG Breakfast Robotic Surgery Symposium <i>Chairs:</i> Jürgen Schleef, MD (Europe) & Jean-Stéphane Valla, MD (Europe) | Pacifico B - 2nd Floor |
| 10:00 am – 10:15 am | Report from the SAGES/MIRA Robotic Consensus Conference John Meehan, MD | Pacifico B - 2nd Floor |
| 10:15 am – 10:30 am | Welcome Address Atsuyuki Yamataka, MD, IPEG President | Pacifico B - 2nd Floor |
| 10:30 am – 11:00 am | BREAK | Pacifico B Foyer - 2nd Floor |
| 11:00 am – 12:15 pm | IPEG Scientific Session <i>Chair:</i> Benno M. Ure, MD, PhD | Pacifico B - 2nd Floor |
| 12:15 pm – 12:30 pm | Basic Science Award | Pacifico B - 2nd Floor |
| 12:30 pm – 1:30 pm | LUNCH BREAK | |
| 1:30 pm – 3:30 pm | Interactive Panel: Anorectal malformations <i>Chairs:</i> Jacob C. Langer, MD (N. America) & Marc A. Levitt MD (USA) | Pacifico B - 2nd Floor |
| 3:30 pm – 5:00 pm | Paper Session # 1: Thoracic and Miscellaneous <i>Chairs:</i> Douglas Barnhart, MD (USA) & Munther J. Haddad, MBBCH, FRCS (Europe) | Pacifico B - 2nd Floor |
| 5:00 pm – 6:15 pm | Poster Tour | Quebracho and Pacara - 5th Floor |

IPEG 2007 MEETING-AT-A-GLANCE

Friday, September 7

| TIME | EVENT | LOCATION |
|---------------------|---|------------------------------|
| 8:00 am – 9:00 am | Interactive Panel Breakfast Session: “My Favorite Tricks” <i>Chairs:</i> Behrouz Banieghbal MD, FRCS (South Africa) & Carroll M. Harmon, MD, PhD (USA)  | Pacifico B – 2nd Floor |
| 9:00 am – 9:30 am | Presidential Address Atsuyuki Yamataka, MD (Asia) <i>Introduction By:</i> Jean-Stéphane Valla, MD | Pacifico B – 2nd Floor |
| 9:30 am – 10:45 am | Paper Session #2: Gastrointestinal and Hepatobiliary <i>Chairs:</i> Jorge Mogilner, MD (Israel) & W. Raleigh Thompson, MD (USA) | Pacifico B – 2nd Floor |
| 10:45 am – 11:00 am | BREAK | Pacifico B Foyer – 2nd Floor |
| 11:00 am – 11:15 am | Introduction to Emerging Technology <i>Introduction By:</i> Steven S. Rothenberg, MD <i>Special Guest:</i> George Berci M.D., FACS, FRCS, Ed | Pacifico B – 2nd Floor |
| 11:15 am – 12:15 pm | Paper Session #3: Emerging Technology <i>Chairs:</i> Timothy D. Kane, MD (USA) & Felix Schier, MD (Europe) | Pacifico B – 2nd Floor |
| 12:15 pm – 2:15 pm | Interactive Panel Session: “How I Do It” <i>Chair:</i> Keith E. Georgeson, MD (USA) | Pacifico B – 2nd Floor |
| 2:15 pm – 3:15 pm | Keynote Lecture: “Delivering Medical and Surgical Care in Outer Space: Challenges and Accomplishments over the Decades” (Traducción en Español) <i>Introduction By:</i> Thomas H. Inge, MD, PhD <i>Guest Speaker:</i> Michael Reed Barratt, MD, NASA Astronaut (Mission Specialist) | Pacifico B – 2nd Floor |

SUTURING SKILLS WORKSHOPS

Chair: David van der Zee, MD

| | | |
|--------------------|--------------------------|--|
| 8:00 am – 12:00 pm | Group 1 | Atlantico ABC – 2nd Floor |
| 2:30 pm – 6:30 pm | Group 2 | Atlantico ABC – 2nd Floor |
| 10:00 am – 4:00 pm | Exhibit Hours | Pacifico A – 2nd Floor |
| 4:00 pm – 5:15 pm | Poster Tour | Quebracho and Pacara – 5th Floor |
| 7:30 pm – 11:00 pm | IPEG’s Main Event | <i>Off-site:</i> Esquina Carlos Gardel |

IPEG 2007 MEETING-AT-A-GLANCE

Saturday, September 8

| TIME | EVENT | LOCATION |
|---------------------|--|------------------------------|
| 8:00 am – 9:30 am | Breakfast Video Session <i>Chairs:</i> Olivier Reinberg, MD (Europe) & JL Peiro Ibañez, MD (Europe) | Pacifico B – 2nd Floor |
| 9:30 am – 11:00 am | Panel Session: Biliary Atresia <i>Chairs:</i> Klaas M.A. Bax, MD (Europe) & Keith Georgeson, MD (USA) | Pacifico B – 2nd Floor |
| 11:00 am – 11:30 am | BREAK | Pacifico B Foyer – 2nd Floor |
| 11:30 am – 12:00 pm | IPEG - General Assembly | Pacifico B – 2nd Floor |
| 12:00 pm – 12:30 pm | Karl Storz Lecture: “The Fetus Becomes an Endosurgical Patient” (Traducción en Español) <i>Introduction By:</i> Marcelo H Martinez-Ferro, MD <i>Guest Speaker:</i> Michael Harrison, MD, University of California San Francisco (USA) | Pacifico B – 2nd Floor |
| 12:30 pm – 1:30 pm | FAREWELL LUNCH | Buen Ayre ABC – Subfloor |
| 1:30 pm – 2:30 pm | Paper Session #4: Urology and Miscellaneous <i>Chairs:</i> Azad S. Najmaldin, MD, FRCS (USA) & Mark L. Wulkan, MD (USA) | Pacifico B – 2nd Floor |
| 10:00 am – 4:00 pm | Exhibits | Pacifico A – 2nd Floor |

IPEG – WOFAPS STATE OF THE ART LECTURES

(Traducción en Español)

Moderators: Gordon A. MacKinlay, MD (IPEG) & Jurgen Schlee, MD (WOFAPS)

| | | |
|---|---|------------------------------|
| 2:30 pm – 3:00 pm | Neonatal MIS <i>Panelist:</i> Marcelo H. Martinez Ferro, MD (IPEG) | Pacifico B – 2nd Floor |
| 3:00 pm – 3:30 pm | Esophageal Atresia <i>Panelist:</i> Klaas MA Bax, MD (IPEG) | Pacifico B – 2nd Floor |
| 3:30 pm – 4:00 pm | Gall Bladder and Spleen <i>Panelist:</i> George W. Holcomb III, MD (IPEG) | Pacifico B – 2nd Floor |
| 4:00 pm – 4:15 pm | BREAK | Pacifico B Foyer - 2nd Floor |
| Moderators: Thomas H. Inge, MD, PhD (IPEG) & Vincenzo Jassoni, MD (WOFAPS) | | |
| 4:15 pm – 4:45 pm | Pulmonary Resection <i>Panelist:</i> Steven S. Rothenberg, MD (IPEG) | Pacifico B – 2nd Floor |
| 4:45 pm – 5:15 pm | Urology <i>Panelist:</i> Jean – Stéphane Valla, MD (IPEG) | Pacifico B – 2nd Floor |
| 5:15 pm – 5:30 pm | BREAK | Pacifico B Foyer - 2nd Floor |
| Moderators: Celeste Hollands, MD (IPEG) & Atsuyuki Yamataka, MD (WOFAPS) | | |
| 5:30 pm – 6:00 pm | Robotics <i>Panelist:</i> Thom E. Lobe, MD (IPEG) | Pacifico B – 2nd Floor |
| 6:00 pm – 6:30 pm | Anorectal Malformations <i>Panelist:</i> Keith Georgeson, MD (IPEG) | Pacifico B – 2nd Floor |

IPEG 2007 MEETING-AT-A-GLANCE

Sunday, September 9

IPEG – WOFAPS ROUND TABLES: MIS vs. OPEN PANELS

(Traducción en Español)

Vesicoureteral Reflux

Moderators: Hock L. Tan, MD (IPEG) & Marty Koyle, MD (WOFAPS)

| | | |
|-------------------|---|------------------------------|
| 8:00 am – 8:12 am | Laparoscopic Interperitoneal <i>Panelist:</i> Mario Riquelme, MD (IPEG) | Pacifico B – 2nd Floor |
| 8:12 am – 8:24 am | Pneumovesicum Intravesical <i>Panelist:</i> C.K. Yeung, Prof (IPEG) | Pacifico B – 2nd Floor |
| 8:24 am – 8:36 am | STING <i>Panelist:</i> Prem Puri, MD (WOFAPS) | Pacifico B – 2nd Floor |
| 8:36 am – 8:48 am | STING <i>Panelist:</i> Goran Lackgren, MD (WOFAPS) | Pacifico B – 2nd Floor |
| 8:48 am – 9:18 am | Panel Discussion | Pacifico B – 2nd Floor |
| 9:18 am – 9:38 am | Discussion (Panel & Participants) | Pacifico B – 2nd Floor |
| 9:38 am – 9:48 am | BREAK | Pacifico B Foyer – 2nd Floor |

Thoracic Wall Malformations

Moderators: Paschoal N. Neto, MD (IPEG) & Patricio Varela, MD (WOFAPS)

| | | |
|---------------------|--|------------------------------|
| 9:48 am – 10:00 am | Compression for Carinatum <i>Panelist:</i> Thomas Inge, MD (IPEG) | Pacifico B – 2nd Floor |
| 10:00 am – 10:12 am | Modification to Nuss Procedure <i>Panelist:</i> Klaus Schaarschmidt, MD (IPEG) | Pacifico B – 2nd Floor |
| 10:12 am – 10:24 am | Nuss Procedure <i>Panelist:</i> Donald Nuss, MD (WOFAPS) | Pacifico B – 2nd Floor |
| 10:24 am – 10:36 am | Rib Distractors for Jeune Syndrome <i>Panelist:</i> John HT. Waldhausen, MD (IPEG) | Pacifico B – 2nd Floor |
| 10:36 am – 11:06 am | Thoracic Wall Malformations: Panel Discussion | Pacifico B – 2nd Floor |
| 11:06 am – 11:36 am | Thoracic Wall Malformations: Discussion (Panel & Participants) | Pacifico B – 2nd Floor |
| 11:36 am – 11:48 am | BREAK | Pacifico B Foyer – 2nd Floor |

Hirschsprung's Disease

Moderators: Maria Marcela Bailez, MD (IPEG) & Tomas Wester, MD (WOFAPS)

| | | |
|---------------------|---|------------------------|
| 11:48 am – 12:00 pm | Panelist 1: Atsuyuki Yamataka, MD (IPEG) | Pacifico B – 2nd Floor |
| 12:12 pm – 12:24 pm | Panelist 2: Gordon A. MacKinlay, MD (IPEG) | Pacifico B – 2nd Floor |
| 12:24 pm – 12:36 pm | Panelist 3: Luis De La Torre, MD (WOFAPS) | Pacifico B – 2nd Floor |
| 12:36 pm – 12:48 pm | Panelist 4: Jack Langer, MD (WOFAPS) | Pacifico B – 2nd Floor |
| 12:48 pm – 1:00 pm | Panel Discussion | Pacifico B – 2nd Floor |
| 1:00 pm – 1:30 pm | Discussion (Panel & Participant) | Pacifico B – 2nd Floor |

IPEG 2007 PEDIATRIC SUTURING SKILLS WORKSHOP

Chair: David van der Zee, MD

Description:

This half-day course provides participants with the practical knowledge and technical skills required during the performance of surgical suturing. Faculty will focus on both lecture and demonstration including video as well as post-course assessments. Using inanimate material, attendees will practice intracorporeal and continuous suturing on either virtual or open-box trainers. Space is limited to only 20 participants. A select number of scholarships will be made available to attendees from low currency countries. If interested, please forward your curriculum vitae and a brief letter indicating your request along with your completed registration form to the IPEG office. Participants will be requested to fill in a questionnaire prior to the course.

Objectives:

Suturing and intracorporeal knotting are considered to be the most difficult Endoscopic surgical task to perform. After this course, the participants should have mastered these tasks.

- Master the art of intracorporeal suturing
- Perform intracorporeal suturing under tension using the tumbled square knot
- Learn continuous suturing techniques and the Aberdeen termination
- Practice techniques with the aid of Tissue models in Endoscopic simulators & virtual reality trainers
- Have confidence to use the acquired techniques safely in patients

Course Schedule, Friday, September 7, 2007

| GROUP 1: 8:00 am – 12:00 pm | |
|-----------------------------|---|
| 8:00 am – 8:15 am | Introduction and Course Pre-Assessment |
| 8:15 am – 8:45 am | Intracorporeal Suturing Lecture and Demonstration |
| 8:45 am – 9:45 am | Individual 2-D Suturing Practical Session/VRT |
| 9:45 am – 10:05 am | Continuous Suturing Lecture and Demonstration |
| 10:05 am – 11:05 am | Individual 2-D Suturing Practical Session/VRT |
| 11:05 am – 11:15 am | Continuous Suturing Lecture French Knot/VRT |
| 11:15 am – 11:45 am | Individual 2-D Suturing Practical Session/Test |
| 11:45 am – 12:00 pm | Course Post Assessment |

| GROUP 2: 2:30 pm – 6:30 pm | |
|----------------------------|---|
| 2:30 pm – 2:45 pm | Introduction and Course Pre-Assessment |
| 2:45 pm – 3:15 pm | Intracorporeal Suturing Lecture and Demonstration |
| 3:15 pm – 4:15 pm | Individual 2-D Suturing Practical Session/VRT |
| 4:15 pm – 4:35 pm | Continuous Suturing Lecture and Demonstration |
| 4:35 pm – 5:35 pm | Individual 2-D Suturing Practical Session/VRT |
| 5:35 pm – 5:45 pm | Continuous Suturing Lecture French Knot/VRT |
| 5:45 pm – 6:15 pm | Individual 2-D Suturing Practical Session/Test |
| 6:15 pm – 6:30 pm | Course Post Assessment |

Lab Instructors:

Greame Adamson, MD
 Maria Marcela Bailez, MD
 Sanjeev Dutta, MD, FRCS

Jacob C. Langer, MD
 Girolamo Mattioli, MD
 Felix Schier, MD

Jean – Stéphane Valla, MD
 Mark L. Wulkan, MD

*IPEG acknowledges the following companies for educational grants and contributions-in-kind in support of this workshop:
 Ethicon Endo-Surgery, Inc.; Karl Storz Endoscopy-America; Surgical Science*

BREAKFAST ROBOTIC SURGERY SYMPOSIUM

8:00 am – 10:00 am

Location: Pacifico B

Moderators: Jürgen Schleef, MD & Jean–Stéphane Valla, MD

Description:

Robotic Pediatric Surgery has vigorously advanced in recent years. Many pediatric surgeons who have not succeeded in minimal access training (MIS) now also find themselves challenged by Robotic Surgery and with a desire to know if this is the next road to take. In addition, many pediatric surgeons who operate using advanced MIS procedures also have a desire to know the advantages and disadvantages of Robotic Surgery and how MIS techniques, they perform daily, can be applied using the robot. This symposium targets pediatric surgeons who have interest in learning about the potential of using robotics in the operating room setting. The symposium will have three segments. There will be an opportunity for questions and discussion.

- Benefits and Risks of the Robot
- Video demonstrations of the use of the robot
- Report from the SAGES / MIRA Robotics Consensus Conference.

Objectives:

1. Learn about the risks and benefits that exist in robotic surgery
2. Learn about recent and future advancements in robotic surgery
3. Be aware of the principles that were developed during the SAGES / MIRA Consensus conference.
4. Familiarization of the robot using video presentations.

| TIME | PANELIST |
|--------------------|---------------------|
| 8:00 am – 8:30 am | Santiago Horgan, MD |
| 8:30 am – 9:00 am | Michael Irish, MD |
| 9:00 am – 9:30 am | Thom E. Lobe, MD |
| 9:30 am – 10:00 am | John Meehan, MD |

IPEG acknowledges Intuitive Surgical for an educational grant in support of this symposium.

REPORT FROM THE SAGES/MIRA ROBOTIC CONSENSUS CONFERENCE

10:00 am – 10:15 am

Location: Pacifico B

Speaker: John Meehan, MD

Description:

Report on the SAGES/MIRA Consensus Conference held in June 2006, in New York City

WELCOME ADDRESS

10:15 am – 10:30 am

Location: Pacifico B

Atsuyuki Yamataka, MD – IPEG President

BREAK

10:30 am – 11:00 am

SCIENTIFIC SESSION

11:00 am – 12:15 pm*Location:* Pacifico B*Chair:* Benno M. Ure, MD, PhD

| | |
|------|---|
| S001 | Minimal Access Pediatric Surgery in the Literature: A Systematic Review <u>Neil Orzech, MD</u> , Mohammed Zamakhshary, MD, Jacob Langer, MD, Department of Surgery, Hospital for Sick Children, Toronto, Canada |
| S002 | Clinical Anorectal Function and Manometric Study After Laparoscopically Assisted Anorectoplasty for Imperforate Anus <u>Sumi Kudou, MD</u> , Yoshihiro Kitano, MD, Hiroo Uchida, MD, Katsumi Yotsumoto, MD, Tetsuya Ishimaru, MD, Chikashi Gotoh, MD, Hiroshi Kawashima, MD, Michio Kaneko, MD, Tadashi Iwanaka, MD, Department of Pediatric Surgery; Saitama Children's Medical Center, Department of Pediatric Surgery; University of Tsukuba, Department of Pediatric Surgery; University of Tokyo |
| S003 | Experience with Minimally Invasive Surgery in Neonates <2.5 Kg. Lessons Learned, Needs Defined <u>Steven S. Rothenberg, MD</u> , The HealthOne Children's Hospital |
| S004 | Long Term Follow-Up of ERPT: Laparoscopic Better Than Laparotomic <u>Girolamo Mattioli, MPA</u> , Alessio Pini Prato, MD, Camilla Giunta, MD, Stefano Avanzini, MD, Gentilino Valerio, MD, Vincenzo Jasonni, MD, Istituto Giannina Gaslini |
| S005 | Carbon Dioxide Suppressed Neutrophil Metabolism and Migreation <u>Akihiro Shimotakahara, MD</u> , Joachim F. Kuebler, MD, Gertrud Vieten, DO, Martin L. Metzelder, MD, Benno M. Ure, MD, Department of Pediatric Surgery, Hannover Medical School |
| S006 | Practice Makes Perfect: Progressive Improvement of Laparoscopic Pyloromyotomy Results with Experience. <u>Ravindra K Vegunta, MD</u> , Jay H. Woodland, MD, Arthur L Rawlings, MD, Elizabeth J Wallace, MS, Richard H. Pearl, MD, University of Illinois College of Medicine at Peoria; Children's Hospital of Illinois, Peoria. |
| S007 | Anasthetic Management and Changes in CO2 Excretion During Thoracoscopic Surgery in. <u>Merrill MCHoney, PhD</u> , Fraser Munro, MD, Gordon MacKinlay, MD, Adam Capek, Louise Aldridge, MD, Royal Hospital For Sick Children Edinburgh, Edinburgh UK |
| S008 | Laparoscopy with CO2 or Helium Does Not Increase the Lethality to a Subsequent Bacterial Peritonitis in a Mice Model. <u>Joachim F Kuebler, MD</u> , Akihiro Shimotakahara, MD, Martin L. Metzelder, MD, Gertrud Vieten, PhD, Benno M Ure, MD, Department of Pediatric Surgery, Medical University of Hannover, Hannover, Germany |
| S009 | Trocar Incision Tensions Do Not Sum <u>Thane A Blinman, MD</u> , Children's Hospital of Philadelphia |
| S010 | Relationship Between Time of Reperfusion and Recruitment of Neutrophils, E-Selectin Expression, and Germ Cell Apoptosis in a Rat Model of Testicular Ischemia <u>Jorge G Mogilner, MD</u> , Robert Greenblatt, BS, Katya Voskoboinik, BA, Michael Lurie, MD, Igor Sukhotnik, MD, Dept of Pediatric Surgery and Pathology, Bnai Zion Medical Center, Rappaport Faculty of Medicine, Technion- Israel Institute of Technology |

BASIC SCIENCE AWARD

12:15 pm – 12:30 pm*Location:* Pacifico B

LUNCH BREAK

12:30 pm – 1:30 pm

INTERACTIVE PANEL: ANORECTAL MALFORMATIONS

1:30 pm – 3:30 pm

Location: Pacifico B

Chairs: Jacob C. Langer, MD & Marc A. Levitt, MD

Description:

This is an interactive panel with participation from the audience, based on the presentation of complex cases of anorectal malformations in children. Before each presentation, the panelists will brief the audience on their experience and case log, so that the audience can familiarize themselves with the topic. Cases are selected by the panelists and panel chairs and will include how minimally invasive techniques were implemented in each case. The presentations will also include complex cases and their resolution. After each presentation, the public will vote on what approach they would most likely chose. The panelists will then offer his or her personal opinion of each choice.

Objectives

1. Familiarize participants with the “state of the art” of Minimally Invasive Surgery (MIS) for anorectal malformations in children.
2. Analyze the advantages and disadvantages of these techniques in relation to conventional techniques.
3. Learn the limitations and contraindications of Minimally Invasive Surgery (MIS) in children with anorectal malformations.
4. Learn how to handle complications using these techniques.
5. Become aware of the new opportunities that Minimally Invasive Surgery (MIS) offers.

| TIME | PANELIST |
|-------------------|--------------------------|
| 1:30 pm – 2:00 pm | Marcela Maria Bailez, MD |
| 2:00 pm – 2:30 pm | Christopher Kimber, MD |
| 2:30 pm – 3:00 pm | Keith E. Georgeson, MD |
| 3:00 pm – 3:30 pm | Atsuyuki Yamataka, MD |

IPEG acknowledges Stryker Endoscopy for an educational grant in support of this session.

PAPER SESSION #1: THORACIC & MISCELLANEOUS

3:30 pm – 5:00 pm

Location: Pacifico B

Chairs: Douglas Barnhart, MD & Munther J. Haddad, MBBCH, FRCS

| | |
|------|--|
| S011 | Experience with Thoracoscopic Approaches to Tracheal Disease in Infants and Children Steven S Rothenberg, MD, The HealthOne Children's Hospital |
| S012 | High Frequency Oscillatory Ventilation for Thoracoscopy <u>Nadeem Haider, MD</u> , Naved K. Alizai, MD, Cornelli Van Wyk, MD, Azad Najmaldin, MD, Leeds General Infirmary, UK |
| S013 | Thoracic and Lumbar Super selective Endoscopic Sympathetic Block (ESB), the Better Solution for Palmar, Facial and Plantar Hyperhidrosis/ Rythrodermia of Childhood and Adolescence? <u>K. Schaarschmidt, PhD</u> , A Kolberg-Schwerdt, MD, M. Lempe, MD, F. Schlesinger, MD, Helios Center for Pediatric & Adolescent Surgery, Berlin-Buch, Germany |
| S014 | Thoracoscopic Approach in Treatment of Lung Hydatid Horacosopic Approach in Treatment of Lung Hydatid Disease in Children: Results of 21 Cases <u>Vladimir Kotlobovski, MD</u> , Sagidula Dosmagambetov, MD, Aslan Ergaliev, MPA, Department of Laparoscopic Surgery, Regional Pediatric Hospital, Aktobe, Kazakhstan |
| S015 | Neonatal Minimal Invasive Surgery for Congenital Diaphragmatic Hernias. <u>Olivier Reinberg, MD</u> , François Becmeur, MD, Hossein Allal, MD, Pascal De Lagausie, MD, Hubert Lardy, MD, Paul Philippe, MD, Manuel Lopez, MD, François Varlet, MD, CHU Lausanne, Strasbourg, Montpellier, Marseilles, Tours, Luxembourg, Saint Etienne (Switzerland, France, Luxembourg) |
| S016 | The Development Training Devices for Neonatal Surgery <u>Karen A. Diefenbach, MD</u> , Suzanne Yoder, MD, R. Lawrence Moss, MD, Milissa A McKee, MD, Yale School of Medicine |

| | |
|------|--|
| S017 | Utilization of Thoracoscopy in Infants and Children Shawn D. St Peter, MD, Daniel J. Ostlie, MD, Abhilash Nair, MD, KuoJen Tsao, MD, George W. Holcomb III, MD, Children's Mercy Hospital |
| S018 | Preliminary Results of Thoracoscopic Repair in Neonatal Diaphragmatic Hernia: Two Institution Experience. Arturo Aranda, MD, Mark D. Gaon, MD, Philip K. Frykman, Thomas T. Hui, MD, Christian Ochoa, MD, James E. Stein, MD, Steve C. Chen, MD, Cathy E Shin, MD, Childrens Hospital Los Angeles, University of Southern California; Cedars-Sinai Medical Center, Los Angeles, California |
| S019 | Postoperative Chylothorax in Children: When Does conservative Treatment Become More Invasive Than Minimal Invasive Surgery? Karim Khelif, MD, Sebastian Ralea, MD, Dominique Biarent, MD, Marc-Henri De Laet, MD, University Children's Hospital Queen Fabiola / Brussels - Belgium |
| S020 | Dynamic Compression System (DCS) for the Correction of Pectus Carinatum Marcelo Martinez Ferro, MD, Carlos Fraire, MD, Silvia Bernard, Hospital Privado de Ninos & Hospital J.P.Garrahan |
| S021 | Thoracoscopic Lung Biopsy in Children with Endoloop Allows Smaller Trocar Sites Todd A Ponsky, MD, Steven Rothenberg, MD, Rocky Mountain Hospital for Children |
| S022 | Endosurgical Treatment of Diaphragmatic Anomalies in Children Alexander Razumovsky, MD, Victor Rachkov, MD, Zorikto Mitupov, PhD, Olga Mihailova, PhD, Manap Alhasov, MD, Russian State Medical University, Moscow, Russia, Filatov Children's Hospital, Moscow, Russia |
| S023 | Thorascopic versus Open Repair of Tracheoesophageal Fistula and Esophageal Atresia Brian Lugo, MD, Yigit Guner, MD, Thang Nguyen, MD, Cathy Shin, MD, Henri Ford, MD, Nam Nguyen, MD, Childrens Hospital Los Angeles |

POSTER TOURS

5:00 pm – 6:15 pm

Location: Pacara & Quebracho

FRIDAY, SEPTEMBER 7, 2007

NEW INTERACTIVE PANEL BREAKFAST SESSION: “MY FAVORITE TRICKS”

8:00 am – 9:00 am

Location: Pacifico B

Chairs: Behrouz Banieghbal, MD, FRCS& Carroll M. Harmon, MD, PhD

IPEG acknowledges Stryker Endoscopy for an educational grant in support of this session.

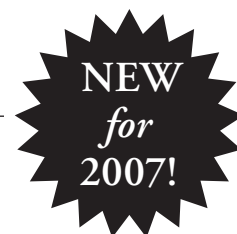Description:

This is a new session! The topic is open and the objective is to have participants share their “tricks” in performing minimal invasive surgery (MIS), e.g. knotting techniques, instrument use, trocar placement, special maneuvers, special positioning of the patient or of the surgeon, etc. This session will also include audience participation. Participants will have 3 minutes to present their video and / or power-point presentation. The audience will be asked to comment on each “trick” and the audience will be asked to select the best “trick”

Objectives

1. To promote the exchange of new ideas and techniques.
2. To promote the advancement of Minimally Invasive Surgery (MIS) for pediatric patients.
3. To stimulate the development of new ideas and techniques.

| | |
|------|--|
| V001 | Incisionless and Trocarless Transanal Resection of The Rectosigmoid for Severe Idiopathic Constipation Richard A. Falcone, MD, Marc A. Levitt, MD, Alberto Pena, MD, Cincinnati Children's Hospital Medical Center |
|------|--|



| | |
|------|--|
| V002 | Laparoscopic Retroperitoneal Pouch Splenopexy for Wandering Spleen <u>Michael J. Leinwand, MD</u> , Marc T. Downing, MD, Adrian Seah, BS, The Children's Hospital at Bronson, Kalamazoo, MI, USA |
| V003 | The Use of Sugisis for Hiatal Reinforcement at the Time of Re-do Laparoscopic Fundoplication <u>George W Holcomb, III</u> , MD, Casey M. Calkins, MD, Children's Mercy Hospital |
| V004 | Technique of Uretericvideo Assisted Tailoring and Reimplantation for Ureterovesical Obstruction Using CO2 Bladder Insufflation <u>J.S Valla, MD</u> , Hospital Lenval |
| S024 | Single Port Thoracoscopic Sympatectomy in Youngsters with Palmar Hyperhidrosis -Eleven Years of Experience <u>Dragan Kravarusic, MD</u> , Anton Kwasha, MD, Elena Dlugy, MD, Ran Steinberg, MD, Elad Feigin, MD, Jacob Katz, MD, Enrique Freud, MD, Schneider Children's Medical Center |
| S025 | Stealth Surgery: Transaxillary Subcutaneous Endoscopic Excision of Benign Neck and Chest Wall Lesions <u>Sanjeev Dutta, MD</u> , Bethany Slater, MD, Marilyn Butler, MD, Craig T. Albanese, MD, Lucile Packard Children's Hospital, Stanford University Medical Center |
| S026 | A Simple Method Of Laparoscopic Gastrostomy Revision <u>Marcos Bettolli, MD</u> , Claudio de Carli, MD, C-C Jackson, MD, Brian Sweeney, MD, Steven Rubin, MD, Children's Hospital of Eastern Ontario |
| V005 | Laparoscopic Repair of Morgagni Type Diaphragmatic Hernias <u>Arturo Aranda, MD</u> , Wang Kasper, MD, Cathy E Shin, MD, Childrens Hospital Los Angeles, Univeristy of Southern California |
| S027 | Our Experience in Laparoscopic Extravesical Transperitoneal Approach for Vesicoureteral Reflux <u>Mario Riquelme, MD</u> , Mario Q. Riquelme, MD, Carlos Rodriguez, MD, Arturo Aranda, MD, Hosp. Christus-Muguerza; Hosp. San Jose Tec, Monterrey, Mexico |
| S028 | Use of Bovine Pericardial Strips to Prevent Air Leak in Thoracoscopic Repair of a Spontaneous Pneumothorax <u>Robert G. Neumann, MD</u> , Michael D. Rollins, MD, Tamir H Keshen, MD, Division of Pediatric Surgery, Saint Louis Children's Hospital, Washington University School of Medicine, Saint Louis, Missouri, USA |
| S029 | Cholecystectomy with 3 Trocars and Gallbladder Suspension (24 cases) <u>Cecilia Tolg, MD</u> , Jean François Colombani, MD, Anis Echaieb, MD, CHU Fort de France Martinique |
| S030 | Laparoscopic Inguinal Hernia Repair Reinforced by Plica Unbilicalis Medialis in Children <u>Vladimir Kotlobovskiy, MD</u> , Anatoly Dronov, MD, Aslan Ergaliev, Damir Dzenalae, MD, Marat Iliasov, Alexander Skok, Department of Laparoscopic Surgery, Regional Pediatric Hospital, Aktobe, Kazakhstan |
| V006 | Laparoscopic Inversion Ligation Inguinal Hernia Repair in Girls <u>Celeste Hollands, MD</u> , University at Buffalo |
| V007 | Laparoscopic Diaphragmatic Plication <u>Troy L. Spide, MD</u> , Daniel J Ostle, MD, Children's Mercy Hospital |
| S031 | The Use of Plastic Bag From a Drain Packing Instead of Endobag in Children – A Safe, Effective and Economical Alternative Salmai Turial, MD, Martin Schwind, MD, Veronika Engel, MD, Mohamed Al Moghnam, MD, Thomas Hueckstaedt, MD, Felix Schier, MD, University Medical Center Mainz, Department of Paediatric Surgery |
| S032 | Infant Laparoscopic Pyeloplasty: Points of Technique <u>Lisandro A. Piaggio, MD</u> , Paul H. Noh, MD, Julia S Barthold, MD, T. Ernesto Figueroa, MD, Amos Nehman, MD, Ricardo Gonzalez, A I DuPont Hospital for Children, Wilmington, DE and Hospital Italiano Regional del Sur, Bahia Blanca, BA, Argentina |
| S033 | Laparoscopic Surgery in Duodenal Diaphragm. Surgical Technique <u>Jorge Godoy, MD</u> , Marina Poblete, MD, Angel Blanco, MD, Servicio de Cirugía Pediátrica, Hospital Luis Calvo Mackenna and Clínica Las Condes, Santiago, Chile. |
| V008 | Pediatric Trans-Axillary Totally Endoscopic Parathyroidectomy <u>Thom E. Lobe, MD</u> , Simon K. Wright, MD, Blank Children's Hospital |

PRESIDENTIAL ADDRESS: ATSUYUKI YAMATAKA, MD

9:00 am – 9:30 am*Location:* Pacifico B*Introduction by:* Jean – Stéphane Valla, MD*IPEG acknowledges our Diamond and Platinum Donors for their support of this event:**Diamond:* Karl Storz Endoscopy-America, Stryker Endoscopy*Platinum:* Covidien, Ethicon Endo-Surgery, Intuitive Surgical

PAPER SESSION #2: GASTROINTESTINAL & HEPATOBILIARY

9:30 am – 10:45 am*Location:* Pacifico B*Chair:* Jorge Mogilner, MD & W. Raleigh Thompson, MD

| | |
|------|--|
| S034 | A Metaanalysis of Laparoscopic Obesity Surgery in Adolescence <u>Oliver J. Muensterer, MD</u> , Susann Blueher, MD, Holger Till, MD, Departments of Pediatric Surgery and Pediatrics, Children's University Hospital of Leipzig, Coordination center for clinical studies Leipzig (KKSL) |
| S035 | Does the Placement of a Freca Gastrostomy at the Time of Laparoscopic Fundoplication Impact on Outcome? <u>Anies Mahomed, MD</u> , Department of Paediatric Surgery, Royal Alexandra Children's Hospital, Brighton, BN1 3JN |
| S036 | Laparoscopic Resection of Abdominal Neuroblastic Tumors <u>Marc-David LeClair, MD</u> , P. De Lagausie, MD, F Becmeur, MD, F. Varlet, MD, C. Thomas, MD, J.S. Valla, MD, H. Lardy, MD, T. Petit, P. Philippe-Chomette, MD, P.Y. Mure, MD, S. Sarnacki, MD, J. Michon, MD, Y. Heloury, MD, Pediatric Surgery Departments of Nantes, Robert Debre-Paris, Stratsbourg, Saint-Etienne, Nice, Tours, Caen, Debrousse-Lyon, Enfants Malades-Paris, and Paediatric Oncology, Nantes, France |
| S037 | Laparoscopy is Effective for Reduction of Intussusception in Children but Should Not Be Used for Associated Bowel Resection <u>L. V. Proklova, MD</u> , R. N. Haricharan, MD, C.J. Aprahamian, MD, T. L. Morgan, MD, W. D. Hardin, MD, C. M. Harmon, MD, J. M. Saito, MD K. E. Georgeson, MD, D.C. Barnhart, MD, University of Alabama at Birmingham, AL, USA; Northern State Medical University Arkhangelsk, Russia |
| S038 | Is Intraoperative Anal Endosonography Necessary During Laparoscopy-Assisted Georgeson's Procedure for High Type Imperforate Anus? <u>Satoko Shiyonagi, MD</u> , Kazuhiro Kaneyama, MD, Hiroko Watayo, MD, Yutaka Hayashi, MD, Atsuyuki Yamataka, MD, Juntendo University School of Medicine |
| S039 | Laparoscopic Excision of Choledochal Cyst in Children <u>Yeming Wu, MD</u> , Li Hong, MD, Zhilong Yan, MD, Shanghai Children's Medical Center |
| S040 | Laparoscopic Total Cyst Excision with Roux-en -Y Hepatoenterostomy for Choledochal Cyst: 102 Cases Experience <u>Long Li, MD</u> , Liu-Ming HUang, MD, Suo-Lin Li, MD, the Capital Institution of Pediatrics，the First Affiliated Hospital of Peking University, Beijing;andthe Second Affiliated Hospital of Heber Medical University, Hebei, China |
| S041 | Laparoscopic Un-Roofing of Congenital Splenic Cysts in Children <u>Jan O. Rutqvist, MD</u> , Stig Ramel, PhD, Astrid Lindgren Childrens Hospital, Karolinska University Hospital, Stockholm, Sweden |
| S042 | Laparoscopic Cholecystectomy in the Pediatric Population <u>Scott J. Keckler, MD</u> , Shawn D St. Peter, MD, Abhilash Nair, MD, Daniel J Ostlie, MD, George W Holcomb III, MD, Children's Mercy Hospital |
| S043 | The Value of Laparoscopy in Pediatric Surgical Oncology <u>Gordon A. Mackinlay, MD</u> , Stephanie A. Warne, MD, Fraser D. Murno, MD, Royal Hospital for Sick Children, Edinburgh, Scotland |
| S044 | Robotic Gastric Banding In Adolescents And Children: A Comparative Study <u>Aayed R. Alqahtani, MD</u> , King Saud Uneversity, College of Medicine, Riyadh, Saudi Arabia |

BREAK

10:45 am – 11:00 am

INTRODUCTION TO EMERGING TECHNOLOGY

11:00 am – 11:15 am

Location: Pacifico B

Introduction By: Steven E. Rothenberg, MD

Special Guest: George Berci M.D., FACS, FRCS, Ed (hon)

Personal Data:

George Berci, MD, FACS, FRCS Ed (hon) was born in Szeged, Hungary and Immigrated to Australia in 1957. He then Immigrated to the United States and has been a Permanent Resident in the U.S.A since 1969.

Education:

1950 Medical Doctor Degree received with “Summa Cum Laude”, University Szeged, Hungary

1954 Specialist Degree (Board) in Surgery Budapest, Hungary

Accomplishments:

- In 1962, he developed a miniature camera and broadcast a live image from inside the body for the first time.
- He brought the Hopkins Rod Lens System to endoscopy when he found that it had a medical application
- He brought the xenon light source to the surgical community making it possible to see images clearer.
- He developed the modern choledoscope and a half dozen other G.I. scopes.
- He developed or invented a wide range of endoscopic instruments unrelated to general surgery including the Berci-Ward laryngoscope, The Kantor Berci laryngoscope, a pediatric bronchoscope, a pediatric laparoscope, several dozen hand instruments, a flexible video intubating scope, a video microscope, and most recently, an integrated video intubation system.
- He wrote the definitive text on endoscopy in 1976 and authored 11 other books.
- He developed a video intubating system for both adult and pediatric patients

Organizations:

1957 Temporary Registration Medical Board Victoria, Australia

1959 Medical Registration Medical Board Victoria, Australia

1965 Royal Australian College of Surgeons (Board of Regents) “Surgical Knowledge and Skills accepted as equivalent to the Primary Examination of the Surgical Fellowship”.

1969 Educational Council of Foreign Medical Graduates (ECFMG), Diploma (USA)

1973 California, USA state license

1980 Fellow of the American College of Surgeons

1992 Honorary Fellow of the Royal College of Surgeons, Edinburgh

1993 President of The Society of American Gastrointestinal and Endoscopic Surgeons (SAGES)

His work for SAGES has been incessant and visionary. In addition to serving on almost every committee and chairing several, he served on the Board of Governors for 9 years, as Vice President and then President. He directed the 1990 ground breaking postgraduate course in Atlanta. He initiated and directed the first series of training the trainers courses in Laparoscopic cholecystectomy in 1990 and 1991 and was a Founding Director of the SAGES Education and Research Foundation. He has been an editor of Surgical Endoscopy since its inception.

Dr. Berci is Clinical Professor of Surgery, U.S.C. Medical Center, and Director of Endoscopic Research, Cedars Sinai Medical Center, Los Angeles. Born in Hungary, he earned his medical degree, from the University of Szeged and was a Rockefeller Fellow in Surgery at the University of Melbourne, Australia after escaping from Hungary in 1956. He has published 12 books, 76 chapters or manual, 37 teaching films, videos or CD's, and 215 papers in peer reviewed journals covering general/MIS surgery, gynecology, ENT, urology, anesthesia, pediatrics and neurosurgery.

In 2001, Cedars Sinai Medical Center named a Chair in his honor, known as the Karl Storz mini Invasive Surgery Chair in Honor of George Berci.



**George Berci M.D.,
FACS, FRCS, Ed (hon)**

PAPER SESSION #3: EMERGING TECHNOLOGY

11:15 am – 12:15 pm*Location:* Pacifico B*Chairs:* Timothy D. Kane, MD & Felix Schier, MD

| | |
|------|---|
| V009 | Laparoscopic Duodenal Atresia Repair with U-Clips <u>George W. Holcomb, III, MD</u> , Shawn D. St. Peter, MD, Children's Mercy Hospital |
| V010 | Endoscopic Obliteration of a Recurrent Tracheoesophageal Fistula Using Surgisis <u>George W. Holcomb, III, MD</u> , Casey M. Calkins, MD, Shawn D. St. Peter, MD, Children's Mercy Hospital |
| S045 | 48 Hours Wireless Oesophageal pH-Monitoring in Children-Are Two Days Better Than One? <u>Anna Gunnarsdóttir, MD</u> , Pernilla Stenström, MD, Einar Arnbjörnsson, PhD, Department of Paediatric Surgery, Lund University Hospital, 221 85 Lund, Sweden |
| S046 | Nephrectomy by N.O.T.E.S. <u>Estêvão Lima, MD</u> , Carla Rolanda, MD, José M Pêgo, MD, Tiago Henriques-Coelho, MD, David Silva, MS, Guilherme Macedo, PhD, José L Carvalho, MD, Jorge Correia-Pinto, PhD, Division of Pediatric Surgery, Hospital S João, Porto; School of Health Sciences, University of Minho, Braga, Portugal |
| V011 | Laparoscopic Resection of a Large Benign Hepatic Tumor. <u>Deepika Nehra, BS</u> , Samuel Rice-Townsend, BS, Sanjeev Dutta, MD, Lucile Packard Children's Hospital, Stanford University School of Medicine |
| V012 | Video-Assisted Trans-Oral Endoscopic Resection Retropharyngeal Ectopic Thymus in a Newborn Presenting with Airway Obstruction <u>Simon K. Wright, MD</u> , Thom E Lobe, MD, Michael S. Irish, MD, Blank Children's Hospital, Des Moines, IA |
| V013 | Laparoscopic Pancreatocystgastrostomy for Pancreatic Pseudocyst <u>Shawn D. St Peter, BA</u> , Daniel J. Ostlie, BA, Children's Mercy Hospital |
| S047 | First Application of New Bedside Mechanical Robotic Instruments, Through Conventional Trocars in standard Pediatric Laparoscopy and Thoracoscopy. <u>Klaus Schaarschmidt, MD</u> , Andreas Kolberg-Schwerdt, MD, Michael Lempe, MD, Frank Schlesinger, MD, Helios Center for Pediatric & Adolescent Surgery, Berlin-Buch, Germany |
| S048 | Water-Jet a Novel Highly Selective Energy Source Sparing Vessel and Nerves for Rapid, Bloodless Endoscopic Parenchymal Dissection, Preliminary experience. <u>Klaus Schaarschmidt, MD</u> , Andreas Kolberg-Schwerdt, MD, Michael Lempe, MD, Frank Schlesinger, MD, Helios Center for Pediatric & Adolescent Surgery, Berlin-Buch, Germany |
| S049 | Novel, Ergonomic Handle Designs for Laparoscopic Instrumentation. <u>Russell Woo, MD</u> , Michael Ho, BS, Alissa Murphy, BS, Bonita Song, BS, Patrick Summers, BS, Sanjeev Dutta, MD, Lucille Packard Children's Hospital, Stanford University Medical Center |
| S050 | The Robotic Gyrus PK: A New Articulating Thermal Sealing Device for Robotic Surgery <u>John J Meehan, MD</u> , University of Iowa Children's Hospital |
| S057 | Experience with a New 3mm Laparoscope in Complex Neonatal Minimally Invasive Surgery: A Preliminary Report <u>Philip K. Frykman, MD</u> , Masanobu Hagiike, MD, Thomas T. Hui, MD, George Berci, MD, Division of Pediatric Surgery1, Department of Surgery2, Cedars-Sinai Medical Center, Los Angeles, California. Department of Surgery3, David Geffen School of Medicine at the University of California, Los Angeles |

IPEG acknowledges an educational grant from Intuitive Surgical in support of this session.

INTERACTIVE PANEL SESSION: "HOW I DO IT"

Time: 12:15pm – 2:15pm*Location:* Pacifico B*Chaired by:* Keith E. Georgeson, MD**Description:**

IPEG is an international society, in which its participants have often benefited from the exchange of ideas. In this session, you will discuss the minimally invasive techniques most frequently used around the world. Technical details of these procedures vary from place to place. Therefore, the objective of this panel is to convey to the participants the various similarities and differences that exist among expert surgeons. Four topics will be presented (Nissen fundoplication, pyloromyotomy, inguinal hernia closure, and surgery for TEF). Each topic will be discussed by an international panel of experts and each expert will explain, "How I do it" and "Why I do it". The panel chairs will collect beforehand the techniques and opinions of the panelists and will prepare a series of questions for the audience. The audience will be asked to participate at the end of each topic.

OBJECTIVES

1. Maximize the exchange of information that a true International Society like IPEG can provide.
2. Familiarize the participants with the “state of the art” of Minimally Invasive Surgery (MIS) in children.
3. Inspire participants to become aware of the various minimally invasive techniques and to become open to new ideas.

| NISSEN <i>Moderator: Girolamo Mattioli, MD</i> | |
|--|---------------------------|
| 12:15 pm – 12:20 pm | Hossein Allal, MD |
| 12:20 pm – 12:25 pm | George W. Holcomb III, MD |
| 12:25 pm – 12:30 pm | Tadashi Iwanaka, MD, PhD |
| 12:30 pm – 12:35 pm | Max C. Schlobach, MD |
| 12:35 pm – 12:45 pm | Discussion |

| PYLORIC <i>Moderator: W. Raleigh Thompson, MD</i> | |
|---|---------------------------|
| 12:45 pm – 12:50 pm | Tadashi Iwanaka MD, PhD |
| 12:50 pm – 12:55 pm | Jean – Stéphane Valla, MD |
| 12:55 pm – 1:00 pm | David van der Zee, MD |
| 1:00 pm – 1:05 pm | John HT Waldhausen, MD |
| 1:05 pm – 1:15 pm | Discussion |

| HERNIA <i>Moderator: Azad S. Najmaldin, MD, FRCS</i> | |
|--|------------------------|
| 1:15m – 1:20pm | Edward Esteves, MD |
| 1:20pm – 1:25pm | J. Duncan Phillips, MD |
| 1:25ppm – 1:30pm | Felix.Schier, MD |
| 1:30pm – 1:35pm | Hiroo Takehara, MD |
| 1:35pm – 1:45pm | Discussion |

| TEF <i>Moderator: Harold Lovvor, MD</i> | |
|---|-------------------------------|
| 1:45 pm – 1:50 pm | Klaas MA Bax, MD |
| 1:50 pm – 1:55 pm | Marcelo H. Martinez Ferro, MD |
| 1:55 pm – 2:00 pm | Steven S. Rothenberg, MD |
| 2:00 pm – 2:05 pm | C.K. Yeung, MD |
| 2:05 pm – 2:15 pm | Discussion |

IPEG acknowledges an educational grant from Karl Storz Endoscopy in support of this session.

KEYNOTE LECTURE (*Traducción en Español*)

2:15 pm – 3:15 pm

Location: Pacifico B

**“Delivering Medical and Surgical Care in Outer Space:
Challenges and Accomplishments over the Decades”**

Introduction By: Thomas H. Inge, MD, PhD

Guest Speaker: Michael Reed Barratt, MD, NASA Astronaut (Mission Specialist)

Personal Data:

Born on April 16, 1959 in Vancouver, WA. Considers Camas, WA, to be his hometown.



**Michael Reed Barratt,
MD, NASA Astronaut
(Mission Specialist)**

Education:

Graduated from Camas High School, Camas, WA, 1977. B.S., Zoology, University of Washington, 1981. M.D., Northwestern University, 1985. Completed three-year residency in Internal Medicine at Northwestern University 1988, completed Chief Residency year at Veterans Administration Lakeside Hospital in Chicago, 1989; Completed residency and Master's program in Aerospace Medicine, Wright State University, 1991. Board certified in Internal and Aerospace Medicine.

Organizations:

Aerospace Medical Association; American College of Physicians; Alpha Omega Alpha Medical Honor Society; American Institute for the Advancement of Science; Aikido Association of America; Aircraft Owners and Pilot's Association.

Special Honors:

W. Randolph Lovelace Award (1998), Society of NASA Flight Surgeons; Rotary National Award for Space Achievement Foundation Nominee (1998); Melbourne W. Boynton Award (1995), American Astronautical Society; USAF Flight Surgeons Julian Ward Award (1992); Wright State University Outstanding Graduate Student, Aerospace Medicine (1991); Alpha Omega Alpha Medical Honor Society, Northwestern University Medical School, Chicago, IL (1988); Phi Beta Kappa, University of Washington, Seattle, WA (1981); Excellence in Experimental Biology Award, University of Washington, Seattle, WA (1981); Mortar Board National Collegiate Honor Society, University of Washington, Seattle, WA (1980); Valedictorian, Camas High School, Camas, Washington (1977).

Experience:

Dr. Barratt came to NASA JSC in May 1991 employed as aerospace project physician with KRUG Life Sciences. From May 91 to July 92, he served on the Health Maintenance Facility Project as manager of the Hyperbaric and Respiratory Subsystems for Space Station Freedom. He was involved in development of on-orbit treatment capability for space decompression disorders and advanced life support protocols for the microgravity environment. In July 1992, he was assigned as NASA Flight Surgeon working in Space Shuttle Medical Operations. In January 1994, he was assigned to the joint US/Russian Space Program. He spent over 12 months onsite working and training in the Cosmonaut Training Center, Star City, Russia in support of the Mir-18 / STS-71 mission.

From July 95 through July 98, he served as Medical Operations Lead for the International Space Station (ISS). Activities included drafting ISS Medical Operations requirements, revising and coordinating ISS medical standards among international partner participants, medical hardware development and evaluation for ISS. A frequent traveler to Russia, he worked with counterparts at the Gagarin Cosmonaut Training Center and Institute of Biomedical Problems, as well as other International Partner centers. Dr. Barratt served as lead crew surgeon for first expedition crew to ISS from July 98 until selected as an astronaut candidate.

NASA Experience:

Selected as a mission specialist by NASA in July 2000, Dr. Barratt reported for training in August 2000. Following the completion of two years of training and evaluation, he was assigned technical duties in the Astronaut Office Station Operations Branch. Dr. Barratt is currently in training for long duration flight on the ISS.

EXHIBITS

10:00 am – 4:00 pm

Location: Pacifico A

POSTER TOURS

4:00 pm – 5:15 pm

Location: Pacara & Quebracho

IPEG'S MAIN EVENT

Friday, September 7, 2007 • 7:30 pm – 11:00 pm

ESQUINA CARLOS GARDEL

Carlos Gardel 3200 • C1215AAB Barrio Del Abasto

Featuring tango performances, gauchos, and more!

IPEG acknowledges our Diamond and Platinum Donors for their support of this event:

Diamond: Karl Storz Endoscopy-America, Stryker Endoscopy

Platinum: Covidien, Ethicon Endo-Surgery, Intuitive Surgical



BREAKFAST VIDEO SESSION

8:00am – 9:30am*Location:* Pacifico B*Chairs:* Olivier Reinberg, MD & JL Peiro Ibañez, MD

| | |
|------|--|
| V014 | Laparoscopic Colectomy and Pelvic Pouch Procedure <u>Ivan R. Diamond, MD</u> , Gudrun Aspelund, MD, Jacob C. Langer, MD, Division of General Surgery, The Hospital for Sick Children, Toronto, Canada |
| V015 | Thoracoscopic Repair of Long Gap Esophageal Atresia <u>Steven S. Rothenberg, MD</u> , The HealthOne Children's Hospital |
| V016 | Thoracoscopic Upper Lobectomies for Symptomatic Congenital Lung Cysts Sherif Emil, MD, Wendy Su, MD, Fombe Ndiforchu, MD, University of California Irvine |
| V017 | Staged Laparoscopic Cephallic Pancreatectomy for the Treatment of Persistent Hyperinsulinism <u>Maria M. Bailez, MD</u> , H. Questa, MD, F. Prieto, MD, Pediatric Surgery, J. P. Garrahan Hospital, Buenos Aires, Argentina |
| V018 | Laparoscopic Radical Hysterectomy and Bilateral Pelvic Lymphadenectomy in a 14 Year Old Girl with A Uterine Adenocarcinoma <u>Maria M. Bailez, MD</u> , Leopoldo Videla Rivero, MD, Beatriz Videla Rivero, MD, Aixa Reusmann, MD, Natalia Amburri, MD, *Pediatric Surgery Garrahan Hospital and **Gynecology Callao Surgical Institute, Buenos Aires |
| V019 | Laparoscopic Revision of An Open Pyloromyotomy <u>Michael V. Tirabassi, MD</u> , Michael Morowitz, MD, Carroll M. Harmon, MD, Douglas C. Barnhart, MD, University of Alabama |
| V020 | Thoracoscopic Treatment Of A Neonatal Traumatic Pneumatocele <u>Carl-Christian Jackson, MD</u> , M. Bettolli, MD, C. De Carli, MD, S. Rubin, MD, Brian Sweeney, MD, Children's Hospital of Eastern Ontario |
| V021 | Robotically-Assisted Right Adrenalectomy in a 7 month-old Child <u>Michael S. Irish, MD</u> , Go Miyano, MD, Thom E. Lobe, MD, Blank Children's Hospital |
| V022 | Laparoscopic Treatment of Duodenal Hematoma <u>B. Banieghbal, MD</u> , University of Witwatersrand, Johannesburg |
| V023 | Thoracoscopic Pneumonectomy for Severe Bronchiectasis in A 9 Year Old Female <u>Dean M. Anselmo, MD</u> , Donald B. Shaul, MD, Childrens Hospital Los Angeles, Keck-USC School of Medicine |

BILIARY ATRESIA

9:30 am – 11:00 am*Location:* Pacifico B*Chairs:* Klaas M.A. Bax, MD & Keith E. Georgeson, MD**Description:**

Minimally Invasive Surgery (MIS) in children has been vigorously advanced in recent years. An example of this advancement is the use of laparoscopy in children with biliary atresia. Although some expert surgeons consider laparoscopic techniques an excellent option for biliary atresia, this topic is still controversial. The effectiveness of maintaining the long-term biliary flow compared to open techniques is a matter of debate. The aim of this session is to make participants aware of the role of laparoscopy in children with biliary atresia.

Objectives:

1. To make the participant aware of the present role of this particular technique and its immediate and long-term results.
2. To learn techniques and experiences from expert surgeons and their opinion on future aspects.
3. To understand controversies on the role of this technique.

| TIME | PANELIST |
|-------------------|--------------------|
| 9:30am –9:48am | Edward Esteves, MD |
| 9:48am –10:06am | Long Li, MD |
| 10:06am –10:24am | John Meehan, MD |
| 10:24am –10:42am | Benno M. Ure, MD |
| 10:42am –11:00 am | C.K. Yeung, MD |

BREAK

11:00 am – 11:30 am

IPEG GENERAL ASSEMBLY

11:30 am – 12:00 pm

Location: Pacifico B

KARL STORZ LECTURE (*Traducción en Español*)

12:00 pm – 12:30 pm

Location: Pacifico B

“The Fetus Becomes an Endosurgical Patient”

Introduction By: Marcelo H Martinez Ferro, MD

Guest Speaker: Michael Harrison, MD, University of California, San Francisco

IPEG acknowledges Karl Storz Endoscopy for an educational grant in support of this symposium.

Dr. Michael Harrison is Professor Emeritus of Surgery, Pediatrics, and Obstetrics, Gynecology and Reproductive Sciences, and Director of the Fetal Treatment Center at the University of California, San Francisco Medical Center and Children's. He maintains board-certification in pediatric surgery.

A cum laude graduate (and former lightweight Varsity Crew Team captain) of Yale University, Dr. Harrison went on to receive his M.D., magna cum laude, from Harvard Medical School. He chose a career in surgery and remained in the Boston area to complete general surgery residency training at the Massachusetts General Hospital. Sensing that his long-term career would be in academic pediatric surgery, he poised himself for subspecialty fellowship by taking two years off from clinical training to work as a postdoctoral research fellow in the Laboratory of Immunology at the NIH. There, he not only satisfied his own scientific curiosity, but learned the methods and techniques of basic science investigation that would provide the scaffolding for his own independent research later in his career.

Upon completion of general surgery residency, he entered pediatric surgery fellowship at the Children's Hospital of Los Angeles and the Rikshospitalet in Oslo, Norway. It was immediately after this training program that Dr. Harrison's work in fetal surgery began. In January 1978, Dr. Harrison accepted a faculty position at UCSF because it offered what he believed was the best opportunity to explore an idea he had been nurturing since internship, namely, the possibility of fixing certain fetal anatomic defects before birth to avoid the devastating and sometimes irreversible consequences he encountered in newborns. During the 1980s and 1990s, he and his research colleagues developed and refined many of the techniques that have made fetal surgery the fast-evolving and major contribution it is within the surgical profession and within fetal therapy itself. The March of Dimes provided much needed funding to pursue some of the early laboratory investigations. Clinically, Dr. Harrison worked closely with obstetricians, anesthesiologists, geneticists, sonographers, surgical subspecialists, neonatologists, nurses, and ethicists to lay the foundation for what would be the multidisciplinary UCSF Fetal Treatment Center. The Center is now entering its third decade of operations. The efforts of the Fetal Treatment team took the enterprise from laboratory to the first NIH-sponsored fetal surgery clinical trials to test the safety and feasibility of procedures for anomalies such as congenital diaphragmatic hernia, twin-twin transfusion syndrome, and fetal myelomeningocele.



**Michael R. Harrison,
MD, UCSF**

Those same efforts were furthered by the development of laparoscopy, which led to groundbreaking work in the development of techniques for fetoscopic surgery, or “Fetendo.” Fetendo has become the basis for minimally invasive fetal surgery worldwide. Dr. Harrison’s work has made a significant impact on the performance of surgery to treat the smallest patients through a wide range of techniques. More important, his work has provided both great insight into the underlying causes of birth defects and a possible strategy to prevent or ameliorate the consequences of the untreated disease.

Throughout his career, Dr. Harrison has maintained an active, busy clinical practice. He is also an active member of many prominent organizations in the surgical profession, including the American Pediatric Surgical Association for which he serves as a member of the Committee on Fetal Therapy, and the International Fetal Medicine and Surgery Society for which he is a founding member and twice-elected president. Additionally, Dr. Harrison serves on a number of editorial boards, including those of the *Journal of Pediatric Surgery and Fetal Diagnosis and Therapy*. He has published nearly 400 peer-reviewed articles on a multitude of pediatric surgery and fetal surgery topics, and remains a highly requested lecturer and guest speaker for numerous surgical and medical societies around the world. In 1984, he published the first comprehensive textbook on fetal therapy, *The Unborn Patient: Prenatal Diagnosis and Treatment*, which is now in its third edition.

Dr. Harrison’s expertise in pediatric and fetal surgery has international renown. He has been recognized by colleagues for his contributions to the field and honored with a number of awards. Most recently, Dr. Harrison received the prestigious American College of Surgeons Jacobson Innovation Award in honor of his work in creating the specialty of fetal surgery, and he is the 2006 recipient of the Arnold M. Salzberg Award given by the American Academy of Pediatrics Surgery Section to surgeons who have distinguished themselves as mentors. Considered to be a surgeon ahead of his time, Dr. Harrison’s experimental work in animal models and clinical work on human fetuses and newborns made him the pioneer and recognized founder of fetal surgery as a specialty field in the United States and abroad, and his accomplishments remain the guiding force for the future of fetal medicine and the fight to prevent birth defects. He is widely regarded as the ‘father of fetal surgery.’

Dr. Harrison and his wife, Gretchen, currently live in the San Francisco Bay Area and have four grown children.

FAREWELL BRUNCH

12:30 pm – 1:30 pm

PAPER SESSION #4: UROLOGY & MISCELLANEOUS

1:30 pm – 2:30 pm

Location: Pacifico B

Chairs: Azad S. Najmaldin, MD, FRCS & Mark L. Wulkan, MD

| | |
|------|--|
| S051 | Fetoscopic Cord Ligation in Twin – Twin Transfusion: The Australian Experience <u>Tim J. Roberts, MD</u> , Peter Z. Borzi, MD, Fung y Chan, MD, Andrew Q. Edwards, MD, Chris Z. Kimber, MD, Monash Medical Centre, Melbourne; Mater and Royal Women’s Hospitals, Brisbane Australia |
| V024 | Retroperitoneal Pyeloplasty for Ureteropelvic Junction (UPJ) Obstruction Some to Solve the Technical Difficulties <u>J.S. Valla, MD</u> , Hospital Laval |
| V025 | Robotic Resection of a Prostatic Utricle <u>John J Meehan, MD</u> , Louis Kantzavelos, MD, Chris Austin, MD, Children’s Hospital of Iowa |
| S052 | Laparoscopic Extravesical Ureteral Reimplantation (LEUR): Mid and Long-Term Follow-Up Results Compared with the Open Technique <u>Pedro José López, MD</u> , Yair Cadena G., MD, Alessandro Tavares, MD, Vanessa Muñoz, MD, Octavio Castillo, MD, José M. Escala, MD, M. Gabriela Retamal, MD, Nelly Letelier, MD, Ricardo Zubieta, MD, Department of Urology, Hospital de Niños Dr. Exequiel González Cortés, Santiago, Chile |
| V026 | Laparoscopic Ipsilateral Uretero-Ureterostomy in Infants and Children for Duplication Anomalies of the Urinary Tract. <u>Amos Neheman, MD</u> , Lisandro Piaggio, MD, Paul h Noh, MD, Ricardo Gonzalez, A. I duPont Hospital for Children |
| S053 | Assisted Laparoscopic Artificial Urinary Sphincter Implantation Initial Experience in Pediatric Population <u>Juan Moldes, PhD</u> , Eduardo Ruiz, PhD, Maria Ormaechea, MPH, Giusepucci Carlos, MPH, Marcelo Urquiza Lino, MPH, Martin Alarcon, MPH, Francisco de Badiola, PhD, Section of Pediatric Urology, Department of Pediatrics, Hospital Italiano de Buenos Aires, Buenos Aires, Argentina |

| | |
|------|--|
| V027 | Fetoscopic Separation of Conjoined Twins Foong-Yen Lim, MD, Timothy M. Crombleholme, MD, Jeffrey C. Livingston, MD, Fetal Care Center of Cincinnati, Cincinnati Children's Hospital Medical Center and University of Cincinnati |
| S054 | Update Of Therapeutic Indications Of Fetoscopy J.L. Peiró, MD, E. Carreras, MD, G. Guillén, MD, S. Arevalo, MD, M. A. Sánchez-Durán, MD, F. Castillo, MD, J. Lloret, MD, V. Martínez-Ibáñez, PhD, Fetal Surgery Program. Hospital Vall d'Hebron, Barcelona. Spain. |
| S055 | Laparoscopic Varicocele Ligation versus Inguinal Varicocelectomy. A comparison of techniques S. Duarte, MD, S. Piñeiro, MD, A. García Bayce, MD, A. Britos, MD, H. Pacheco, MD, R. Berazategui, MD, Clínica Quirúrgica Pediátrica, Facultad de Medicina, Centro Hospitalario Pereira Rossell, Montevideo, Uruguay. |
| S056 | Minimally Invasive Treatment Protocol for Vesicoureteral Reflux in Children: Selective Treatment with Effective Cure for CK Yeung, MD, Biji Sreedhar, PhD, JDY Sihoe, MS, Edwin Chan, MS, Chinese University of Hong Kong |
| V028 | Laparoscopic Continent Appendicocostomy Into A Concealed Stoma: Optimizing Cosmesis And Continence Amos Neheman, MD, Lisandro Piaggio, MD, T. Ernesto Figueroa, MD, Ricardo Gonzalez, A. I duPont Hospital for Children |

EXHIBITS

10:00 am – 4:00 pm

Location: Pacifico A

IPEG-WOFAPS STATE OF THE ART LECTURES (*Traducción en Español*)

2:30 pm – 6:30 pm

Location: Pacifico B

Moderators: Gordon A. MacKinlay, MD (IPEG) Jurgen Schlee, MD (WOFAPS)

| <i>Moderators:</i> Gordon A. MacKinlay, MD (IPEG) & Jurgen Schlee, MD (WOFAPS) | | |
|---|--------------------------------|--------------------------------------|
| 2:30 pm – 3:00 pm | Neonatal MIS | Marcelo H. Martinez Ferro, MD (IPEG) |
| 3:00 pm – 3:30 pm | Esophageal Atresia | Klaas MA Bax, MD (IPEG) |
| 3:30 pm – 4:00 pm | Gall Bladder and Spleen | George W. Holcomb III, MD (IPEG) |
| 4:00 pm – 4:15 pm | BREAK | |
| <i>Moderators:</i> Thomas H. Inge, MD, PhD (IPEG) & Vincenzo Jassoni, MD (WOFAPS) | | |
| 4:15 pm – 4:45 pm | Pulmonary Resection | Steven S. Rothenberg, MD (IPEG) |
| 4:45 pm – 5:15 pm | Urology | Jean – Stéphane Valla, MD (IPEG) |
| 5:15 pm – 5:30 pm | BREAK | |
| <i>Moderators:</i> Celeste Hollands, MD (IPEG) & Atsuyuki Yamataka, MD (WOFAPS) | | |
| 5:30 pm – 6:00 pm | Robotics | Thom E. Lobe, MD (IPEG) |
| 6:00 pm – 6:30 pm | Anorectal Malformations | Keith E. Georgeson, MD (IPEG) |

IPEG -WOFAPS ROUND TABLES - MIS VS. OPEN PANELS

(Traducción en Español)

8:00 am – 1:30 pm

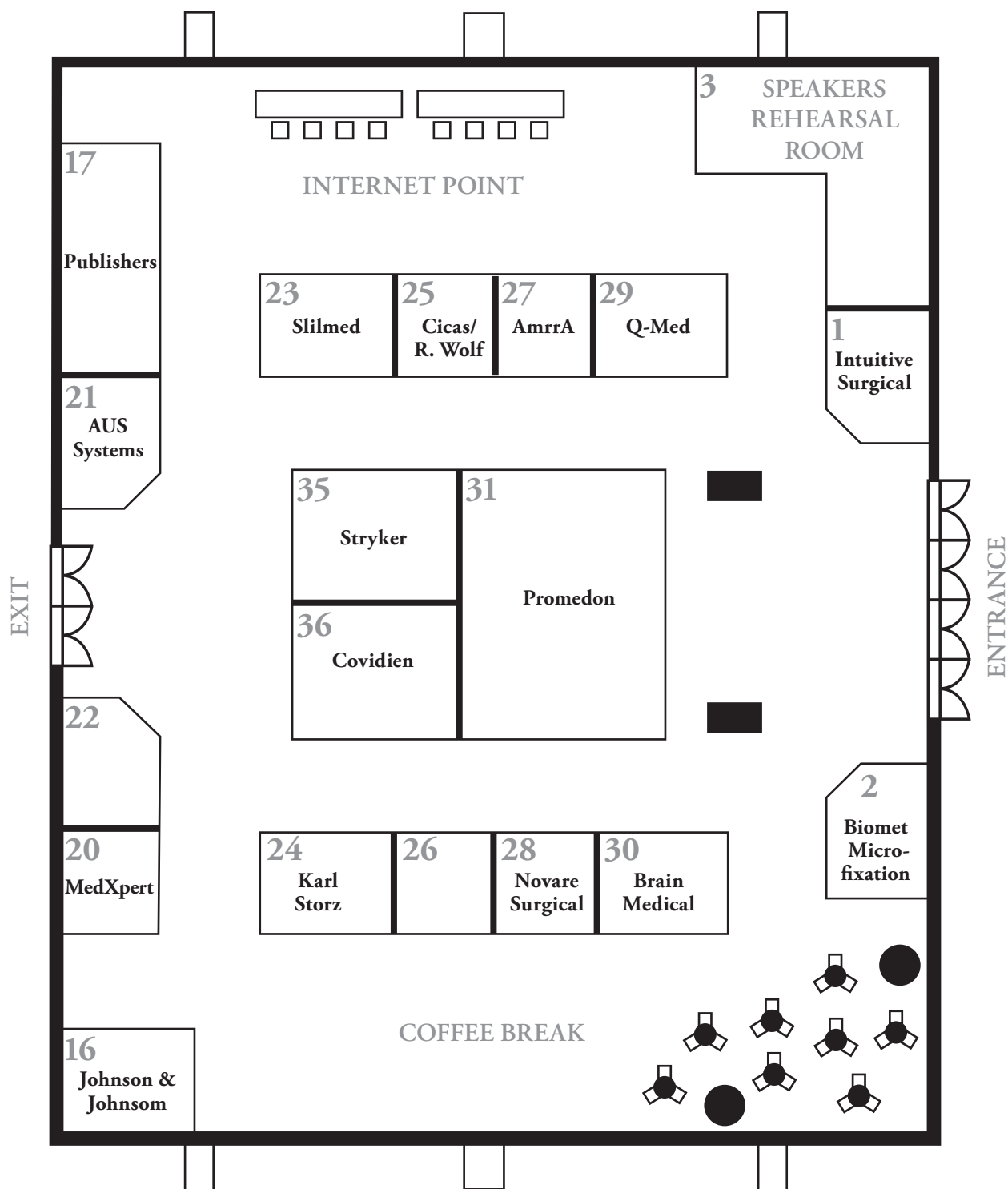
Location: Pacifico B

IPEG acknowledges an educational grant from Covidien in support of this session.

| VESICoureTERAL REFLUX | | |
|---|--|--------------------------------|
| Moderators: Hock L. Tan, MD (IPEG) & Marty Koyle, MD (WOFAPS) | | |
| 8:00 am – 8:12 am | Laparoscopic Interperitoneal | Mario Riquelme, MD (IPEG) |
| 8:12 am – 8:24 am | Pneumovesicum Intravesical | C.K. Yeung, Prof (IPEG) |
| 8:24 am – 8:36 am | STING | Prem Puri, MD (WOFAPS) |
| 8:36 am – 8:48 am | STING | Goran Lackgren, MD (WOFAPS) |
| 8:48 am – 9:18 am | Panel Discussion | |
| 9:18 am – 9:38 am | Discussion (Panel & Participants) | |
| 9:38 am – 9:48 am | BREAK | |
| THORACIC WALL MALFORMATIONS | | |
| Moderators: Paschoal N. Neto, MD (IPEG) & Patricio Varela, MD (WOFAPS) | | |
| 9:48 am – 10:00 am | Compression for Carinatum | Thomas Inge, MD (IPEG) |
| 10:00 am – 10:12 am | Modification to Nuss Procedure | Klaus Schaarschmidt, MD (IPEG) |
| 10:12 am – 10:24 am | Nuss Procedure | Donald Nuss, MD (WOFAPS) |
| 10:24 am – 10:36 am | Rib Distractors for Jeune Syndrome | John HT. Waldhausen, MD (IPEG) |
| 10:36 am – 11:06 am | Panel Discussion | |
| 11:06 am – 11:36 am | Discussion (Panel & Participants) | |
| 11:36 am – 11:48 am | BREAK | |
| HIRCHSPRUNG’S DISEASE | | |
| Moderators: Maria Marcela Bailez, MD (IPEG) & Tomas Wester, MD (WOFAPS) | | |
| 11:48 am – 12:00 pm | Panelist 1: Atsuyuki Yamataka, MD (IPEG) | |
| 12:12 pm – 12:24 pm | Panelist 2: Gordon A. MacKinlay, MD (IPEG) | |
| 12:24 pm – 12:36 pm | Panelist 3: Luis De La Torre, MD (WOFAPS) | |
| 12:36 pm – 12:48 pm | Panelist 4: Jack Langer, MD (WOFAPS) | |
| 12:48 pm – 1:00 pm | Panel Discussion | |
| 1:00 pm – 1:30 pm | Discussion (Panel & Participant) | |

The program and talks presented at IPEG's 16th Annual Congress are copyrighted products of the International Pediatric Endosurgery Group. Any reproduction or rebroadcasting without the express written consent of IPEG is strictly prohibited.

EXHIBITION FLOORPLAN



Pacific Room Level 2

EXHIBITORS

AmrrA Electromedicina (27)

Darwin 217
1414 - Ciudad Autónoma de Buenos Aires
Buenos Aires - Argentina
(+54)(11) 4857-0834
(+54)(11) 4854-6726
amrra@amrra.com
www.amrra.com

Colchones térmicos – Estimuladores intraquirúrgicos – Neuroestimuladores y neurolocalizadores para anestesia – Pinzas Bipolares – Posicionadores Action para pacientes – Frontoluces – Grabado y cintas para identificación de instrumental – Electroacupuntores y Tens.

AUS Systems PTY LTD (21)

3 Charles Street
5009 - Allenby Gardens
South Australia - Australia
(+61)(8) 8346-6400
(+61)(8) 8346-6411
enquiries@aussystems.com.au
www.aussystems.com

rbi2 Suction Rectal Biopsy System". For Controlled, Consistent Rectal Biopsies Of Mucosa And Sub Mucosa For Pathological Examination For The Diagnosis Of Hirschsprung's Disease

Biomet Microfixation (2)

Av. Hipólito Irigoyen 4230
1212 - Buenos Aires
Capital
Argentina
(+54)(11) 4981-1478
(+54)(11) 4981-2018
wllorenzargentina@fibertel.com.ar
www.biometmicrofixation.com
Productos para cirugía bucal, plastic, maxilofacial.

Brain Medical (30)

6 N° 638 _
1900 – La Plata
Buenos Aires – Argentina
(+54)(221) 4272709
(+54)(221) 4835999
oscarrevello@brainmedical.com.ar
www.brainmedical.com.ar
Implante para tratamiento reflujo vesico-vreteral e incontinencia urinaria macroplastique – Uroplasty placas y tornillos bioabsorbible para osteosintesis pediátrica. Osteomed.

CICAS- R. Wolf (25)

Montevideo 464
1019 – Ciudad de Buenos Aires
Buenos Aires – Argentina
cicastapiagomez@fibertel.com.ar
Endoscopia

Covidien (36)

Agüero 351
C1171ABC - Capital Federal
Buenos Aires - Argentina
(+54)(11) 4863-5300
(+54)(11) 4863-4142
info.argentina@covidien.com
www.covidien.com
We are Covidien. One of the largest providers of advanced medical devices, imaging products and pharmaceutical in the world. For everything from simple ambulatory procedure to a complex surgery using our minimally invasive surgical devices known as Autosuture, ValleyLab energy based technologies, unique Sofradim mesh and Polysuture. Formerly Tyco Healthcare, we are now a dynamic independent healthcare company, committed to providing positive innovations and partnerships to the medical community.

Intuitive Surgical (1)

1266 Kifer Road, Building 101
94086 - Sunnyvale
CA - USA
408-523-2100
408-523-1390
angie.lupkes@intusurg.com
www.intuitivesurgical.com
The Company's da Vinci® Surgical System offers breakthrough technology designed to enhance surgical capability, improve clinical outcomes and drive operational efficiencies.

Johnson & Johnson Medical (16)

Monseñor Magliano 3061
B1642GLA – San Isidro
Buenos Aires – Argentina
(+54)(11) 4708-6660
(+54)(11) 4708-6791
agoetz@medar.jnj.com
www.jnjarg.com.ar
Ethicon y Ethicon Endo Surgery.

Karl Storz (24)

Mittelstrasse 8
78532 – Tuttlingen
Germany
(+49) 7461-708378
(+49) 7461-708377
www.karlstorz.de

MedXpert (20)

Poststr. 55
79423
Heitersheim - German
(+49)(7634) 506886
(+49)(7634) 506887
info@medxpert.de
www.medxpert.de

MedXpert is a German manufacturer and worldwide supplier. Come and meet us – visit our stand and discover the most recent developments and innovative solutions for chest wall indications.

Novare Surgical (28)

10440 Bubb Road, Suite A
95014 - Cupertino
CA - USA
(+1)(408) 873 3161
(+1)(408) 873 3168
customers@novaresurgical.com
www.novaresurgical.com

RealHand Instruments are the first High Dexterity (HD) instruments, a new device category for minimally invasive surgery.

Promedon (31)

Av. Circunvalación 3085
5000 – Córdoba
Córdoba – Argentina
(+54)(351) 4650055
internationalsales@promedon.com.ar
www.promedon.com

Innovative Synthetic Injectable Bulking Agent for the treatment of Vesicoureteral Reflux in Children.

Q-Med AB (29)

Seminariegatan 21
SE-752 28
Uppsala - Sweden
(+46)(18) 4749000
(+46)(18) 4749001
a-b.johansson@q-med.com
www.q-med.com / www.deflux.com

DEFLUX™ - the minimally invasive endoscopic treatment for vesico-ureteral reflux (VUR) in children.

Silimed Ltda. (23)

Rua Figueiredo Rocha, 374 – Vigário Geral
21240-660 – Rio de Janeiro
Rio de Janeiro – Brasil
(+55)(21) 3687-7147
(+55)(21) 3687-7140/7141
silimed@silimed.com.br
www.silimed.com.br

Silimed is a Brazilian company present in the market since 1978, and manufacturer of silicone implants and devices for urology, plastic surgery and other specialities. Being among the three major companies in this segment, Silimed exports to more than fifty countries in all five continents. Silimed's products are manufactured with FDA approved raw materials and according to Brazilian, European and American standards, all of them bearing the CE mark.

Stryker (35)

5900 Optical Court
95138 - San Jose
CA - United States
(+1)(800) 435-0220
(+1)(408) 754-2531
Samantha.pavelko@stryker.com
www.stryker.com

Stop by the Stryker booth #201 to see the 1188 HD Camera, the next evolution of Stryker 3-Chip® HD Cameras.

Wiley-Blackwell

350 Main Street
02148 - Malden
MA - USA
(+1)(781) 3888200
(+1)(781) 3888210
customerservices@blackwellpublishing.com
www.blackwellpublishing.com

Wiley-Blackwell - world's leading society publisher, publishing approximately 1,250 scholarly peer-reviewed journals and an extensive collection of books with global appeal.

MEETING LEADERS & FACULTY

IPEG Meeting Leaders

Program Chairman: Marcelo H. Martinez Ferro, MD
Olivos, Buenos Aires, Argentina

IPEG Breakfast Robotic Surgery Symposium

Chairs: Jürgen Schleef, MD
Trieste, Italy
Jean-Stéphane Valla, MD
Nice, France

Breakfast Symposium: "My Favorite Tricks"

Chairs: Behrouz Banieghbalm MD, FRCS
Cresta, Johannesburg, Republic Of South Africa
Carroll M. Harmon, MD, PhD
Birmingham, Alabama, USA

Breakfast Video Session

Chairs: JL Peiro Ibañez, MD
Barcelona, Spain
Olivier Reinberg, MD
Lausanne, Switzerland

IPEG Scientific Session

Chair: Benno M. Ure, MD, PhD
Hannover, Germany

Plenary Sessions

Paper Session #1: Thoracic and Miscellaneous

Chairs: Douglas Barnhart, MD
Birmingham, Alabama, USA
Munther J. Haddad, MBBCH, FRCS
London, United Kingdom

Paper Session #2: Gastrointestinal and Hepatobiliary

Chairs: Jorge Mogilner, MD
Haifa, Israel
W. Raleigh Thompson, MD
Coral Gables, Florida, USA

Paper Session #3: Emerging Technology

Short Paper/Poster Presentations

Chairs: Timothy D. Kane, MD
Pittsburgh, Pennsylvania, USA
Felix Schier, MD
Lanagenbeckstr, Germany

Paper Session #4: Urology and Miscellaneous

Chairs: Azad S. Najmaldin, MD, FRCS
Leeds, United Kingdom
Mark L. Wulkan, MD
Atlanta, Georgia, USA

Suturing Skills Workshops

Chair: David van der Zee, MD
Utrecht, The Netherlands

Panels

Chairs: Behrouz Banieghbal, MD
Cresta, Johannesburg, Republic of South Africa
Klaas (N) M.A. Bax, MD
Rotterdam, The Netherlands
Keith E. Georgeson, MD
Birmingham, Alabama, USA
Carroll M. Harmon, MD, PhD
Birmingham, Alabama, USA
Jacob C. Langer, MD
Toronto, Ontario, Canada
Marc A. Levitt, MD
Cincinnati, Ohio, USA

Poster Tour

Chairs: Spencer W. Beasley, MD, FACS
Christchurch, New Zealand
Vincenzo Jassoni, MD
Genoa, Italy
Dragan Kravarusic, MD
Calgary, Alberta, Canada
Takeshi Miyano, MD, FACS
Tokyo, Japan
Steven Rubin, MD
Ottawa, Ontario, Canada
Gunter-Heinrich Willital, PhD.
Muster, Germany

Executive Committee

President: Atsuyuki Yamataka, MD
Tokyo, Japan
President Elect: Jean-Stéphane Valla, MD
Nice, France
Vice President: Behrouz Banieghbal, MD, FRCS
Cresta, Johannesburg, Rep. of South Africa
Vice President: George W. Holcomb III, MD
Kansas City, Missouri, USA
Secretary: Marcelo H. Martinez Ferro, MD
Olivos, Buenos Aires, Argentina
Treasurer: Thomas H. Inge, MD, PhD
Cincinnati, Ohio, USA
Journal Editor: Thom E. Lobe, MD
Des Moines, Iowa, USA
Asia/Africa Representative: Tadashi Iwanaka, MD, PhD
Tokyo, Japan
European Representative: Gordon A. MacKinlay, MD
Edinburgh, Scotland, United Kingdom
Americas Representative: Marc A. Levitt, MD
*Cincinnati, Ohio, USA (*Chairman)*

EVALUATION & CME CREDIT FORMS

Please complete the meeting evaluation form
and return to the registration desk.

Program Committee

Craig T. Albanese, MD
Stanford, California, USA
 Ciro Esposito, MD, PhD
Naples, ITALY
 Keith E. Georgeson, MD
Birmingham, Alabama, USA
 Munther J. Haddad, MBBCH, FRCS
London, UNITED KINGDOM
 Carroll M. Harmon, MD, PhD
Birmingham, Alabama, USA
 George W. Holcomb III, MD
Kansas City, Missouri, USA
 Thomas H. Inge, MD, PhD
Cincinnati, Ohio, USA
 Marc A. Levitt, MD
Cincinnati, Ohio, USA
 Thom E. Lobe, MD
Des Moines, Iowa, USA

Marcelo H. Martinez Ferro, MD
Olivos, Buenos Aires, ARGENTINA
 Girolamo Mattioli, MD
Genoa, ITALY
 Jürgen Schleef, MD
Trieste, ITALY
 Henri Steyaert, MD
Nice, FRANCE
 Jean-Stéphane Valla, MD
Nice, FRANCE
 David van der Zee, MD, PhD
Utrecht, The NETHERLAND
 John H.T. Waldhausen, MD
Seattle, Washington, USA
 Mark L. Wulkan, MD
Atlanta, Georgia, USA
 Atsuyuki Yamataka, MD
Tokyo, JAPAN

2007 IPEG FACULTY



Greame Adamson, MD
*Ninewells Hospital
Dundee, United Kingdom*



Hossein Allal, MD
*Department of Visceral
Pediatrique Surgery
Montpellier, France*



Maria Marcela Bailez, MD
*Garrahan Children's
Hospital Buenos Aires
Buenos Aires, Argentina*



Behrouz Banieghbal, MD
*CH Baragwanath Hospital
Johannesburg, South Africa*



Douglas C. Barnhart, MD
*Univ. of Alabama Birmingham
– Children's Hospital
Birmingham, Alabama, USA*




Klaas MA Bax, MD
*Wilhelmina Children's
Hospital/Utrecht
Utrecht, The Netherlands*



Spencer W. Beasley, MD
*Christchurch Hospital
Christchurch, New Zealand*



Sanjeev Dutta, MD
*780 Welch Rd. #206
Stanford, California, USA*



Edward Esteves, MD
*Clinics Hospital
Goiania City, Brazil*



Keith Georgeson, MD
*University of Alabama
School of Medicine
Birmingham, Alabama, USA*



Munther J. Haddad, MD
*Chelsea & Westminster
Hospital
London, United Kingdom*



Carroll M. Harmon, MD
*Children's Center
for Weight Management
Birmingham, Alabama, USA*



George W. Holcomb, MD
*Department of Surgery –
Children's Mercy Hospital
Kansas City, Missouri, USA*



Celeste Hollands, MD
*University of Buffalo
Clarence, New York, USA*



Santiago Horgan, MD
*UCSD
San Diego, California, USA*




Thomas H. Inge, MD
*Cincinnati Children's
Hospital Medical Center
Cincinnati, Ohio, USA*



Michael S. Irish, MD
*Blank Children's Hospital
Des Moines, Iowa, USA*



Tadashi Iwanaka, MD
*Tokyo University Hospital
Tokyo, Japan*



Vincenzo Jassoni, MD
Genoa, Italy



Timothy D Kane, MD
*University of Pittsburgh
Medical Center
Pittsburgh, Pennsylvania, USA*



Chris Kimber, MD
*The Children's Surgery
Malvern, Victoria, Australia*



Dragan Kravarusic, MD
*Alberta Children's Hospital
Calgary, Alberta, Canada*



Jacob C. Langer, MD
*Hospital for Sick Children
Toronto, Ontario, Canada*



Marc A. Levitt, MD
*Cincinnati Children's
Hospital Medical Center
Cincinnati, Ohio, USA*



Long Li, MD
*The Capital Institution
of Pediatrics
Beijing, China*



Thom E Lobe, MD
*Blank Children's Hospital
Des Moines, Iowa, USA*



Harold N. Lovvorn III, MD
*Vanderbilt Children's Hospital
Nashville, Tennessee, USA*



Gordon A. MacKinlay, MD
*Royal Hosp. For Sick Children
Edinburgh, Scotland, United
Kingdom*



**Marcelo H. Martinez
Ferro, MD**
*Foundacion Hospitalaria
Children's Hospital
Olivos, Buenos Aires, Argentina*



Girolamo Mattioli, MD
*Gaslini Research Institute
Genova, Italy*



John Meehan, MD
*University of Iowa
Children's Hospital
Iowa City, Iowa, USA*



Takeshi Miyano, MD
*Juntendo University
School of Medicine
Tokyo, Japan*



Jorge Mogilner, MD
*Bnai Zion Medical Center
 Haifa, Israel*



Azad S. Najmaldin, MD
*St. James University Hospital
 Leeds, United Kingdom*



Paschoal N. Napolitano, MD
*Borges Lagoa St. 1450
 Sao Paulo, Brazil*



Jose L. Peiro, MD
*Hospital Vall d'Hebron, Dpto.
 De Cirugia Pediatrica
 Barcelona, Spain*



J. Duncan Phillips, MD
*University of North Carolina
 at Chapel Hill, School of Med.
 Chapel Hill, North Carolina,
 USA*



Olivier Reinberg, MD
*Centre Hospitalier
 Universitaire Vaudois
 Lausanne, Switzerland*



Mario A. Riquelme, MD
*Hospital San Jose
 Monterrey, Mexico*



Steven S. Rothenberg, MD
*Presbyterian/St Lukes
 Hospital Denver
 Denver, Colorado, USA*



Steven Rubin, MD
*Children's Hospital
 of Eastern Ontario
 Ottawa, Ontario, Canada*



Klaus Schaarschmidt, MD
*Hobrechtsfelder Chaussee 100
 Berlin, Germany*



Felix Schier, MD
*University Medical Center
 Mainz, Germany*




Juergen Schlee, MD
*Children's Hospital
 Trieste, Italy*



Max C. Schlobach, MD
*Felicio Rocho Hospital
 Belo Horizonte, Brazil*



Hiroo Takehara, MD
*University of Tokushima
 School of Medicine
 Tokushima, Japan*



Hock L. Tan, MD
*Women's & Children's Hospital
 North Adelaide, South
 Australia*



W. Raleigh Thompson, MD
*University of Miami
 School of Medicine
 Coral Gable, Florida, USA*



Benno M. Ure, MD, PhD
*Hannover Medical School
Hannover, Germany*




Jean-Stéphane Valla, MD
*Hopital Pour Enfants
Nice, France*



David C. van der Zee, MD, PhD
*Univ. Medical Center Utrecht
Utrecht, The Netherlands*



John HT. Waldhausen, MD
*Children's Hospital
& Regional Medical Center
Seattle, Washington, USA*



Gunter-Heinrich Willital, MD
*Für Kinder- Und
Neugeborenenchirurgie
Munster, Germany*



Mark L. Wulkan, MD
*Emory University
School of Medicine
Atlanta, Georgia, USA*



Atsuyuki Yamataka, MD
*Juntendo University
School of Medicine
Tokyo, Japan*



C.K. Yeung, MD
*Chinese University
of Hong Kong
New Territories, Hong Kong,
China*

IPEG PAST PRESIDENTS

Keith E. Georgeson, MD (2006)
 Klaas (N) M.A. Bax, MD (2005)
 C.K. Yeung, MD (2004)
 Craig T. Albanese, MD (2003)
 Vincenzo Jassoni, MD (2002)
 Peter A. Borzi, MD (2001)

Steven S. Rothenberg, MD (2000)
 Jürgen Waldschmidt, MD (1999)
 Hock L. Tan, MD (1998)
 Takeshi Miyano, MD (1997)
 Steven Rubin, MD (1996)
 Gunter-Heinrich Willital, MD (1995)

LECTURES & SPECIAL GUEST SPEAKERS

Friday, September 7, 2007



PRESIDENTIAL ADDRESS

9:00 am – 9:30 am

Atsuyuki Yamataka, MD (Asia)

Associate Professor

Juntendo University School of Medicine – Tokyo, JAPAN



INTRODUCTION TO EMERGING TECHNOLOGY

11:00 am – 11:15 am

George Berci, MD, FACS, FRCS, Ed

Past president of the Society of American Endoscopic Surgeons (SAGES)

Director of the Division of Surgical Endoscopy

Cedars Sinai Medical Center – Beverly Hills, California, USA



KEYNOTE LECTURE (*Traducción en Español*)

***“Delivering Surgical and Medical Care in Outer Space:
 Challenges and Accomplishments over the Decades”***

2:15 pm – 3:15 pm

Michael Reed Barratt, MD

NASA Astronaut (Mission Specialist)

Lyndon B. Johnson Space Center

Houston, Texas, USA

Saturday, September 8, 2007



KARL STORZ LECTURE (*Traducción en Español*)

“The Fetus Becomes an Endosurgical Patient”

12:00 pm – 12:30 pm

Michael Harrison, MD

*Professor Emeritus of Surgery, Pediatrics, and Obstetrics, Gynecology,
 and Reproductive Science*

University of California San Francisco (UCSF) – San Francisco, California (USA)

DISCLOSURES

| FIRST NAME | LAST NAME | DISCLOSURE | WHAT WAS RECEIVED | ROLE |
|-----------------|----------------|--------------------------|----------------------------------|--------------------------|
| Graeme | Adamson | Nothing to disclose | | |
| Hossein | Allal | Nothing to disclose | | |
| Maria Marcela | Bailez | Nothing to disclose | | |
| Behrouz | Banieghbal | Nothing to disclose | | |
| Douglas C. | Barnhart | Nothing to disclose | | |
| Klaas | Bax | Nothing to disclose | | |
| Spencer | Beasley | Nothing to disclose | | |
| Sanjeev | Dutta | Nothing to disclose | | |
| Edward | Esteves | Nothing to disclose | | |
| Keith | Georgeson | Nothing to disclose | | |
| Munther | Haddad | Nothing to disclose | | |
| Carroll | Harmon | Nothing to disclose | | |
| Michael | Harrison | Nothing to disclose | | |
| George W. | Holcomb III | Nothing to disclose | | |
| Celeste | Hollands | Nothing to disclose | | |
| Santiago | Horgan | Intuitive Surgical | Consulting Fee | Consulting |
| Thomas | Inge | Nothing to disclose | | |
| Michael S. | Irish | Intuitive Surgical | Consulting Fee | Surgical Proctor |
| Tadashi | Iwanaka | Nothing to disclose | | |
| Vincenzo | Jasonni | Nothing to disclose | | |
| Timothy D. | Kane | Nothing to disclose | | |
| Christopher | Kimber | Nothing to disclose | | |
| Dragan | Kravarusic | Nothing to disclose | | |
| Jacob C. | Langer | Nothing to disclose | | |
| Marc | Levitt | Nothing to disclose | | |
| Long | Li | Nothing to disclose | | |
| Thom | Lobe | Nothing to disclose | | |
| Harold N. | Lovvorn III | Nothing to disclose | | |
| Gordon | Mackinlay | Nothing to disclose | | |
| Marcelo | Martinez Ferro | Nothing to disclose | | |
| Girolamo | Mattioli | Nothing to disclose | | |
| John | Meehan | Nothing to disclose | | |
| Takeshi | Miyano | Nothing to disclose | | |
| Jorge | Mogilner | Nothing to disclose | | |
| Azad | Najmaldin | Nothing to disclose | | |
| Paschoal N. | Napolitano | Nothing to disclose | | |
| Jose L. | Peiro | Nothing to disclose | | |
| J. Duncan | Phillips | Nothing to disclose | | |
| Olivier | Reinberg | Nothing to disclose | | |
| Mario | Riquelme | Nothing to disclose | | |
| Steven | Rothenberg | Karl Storz Valley Lab | Consulting Fee Consulting Fee | Consulting Consulting |
| Steven | Rubin | Nothing to disclose | | |
| Klaus | Schaarschmidt | Nothing to disclose | | |
| Felix | Schier | Nothing to disclose | | |
| Juergen | Schleef | Nothing to disclose | | |
| Max C. | Schlobach | Nothing to disclose | | |
| Hiroo | Takehara | Nothing to disclose | | |
| W. Raleigh | Thompson | Nothing to disclose | | |
| Benno | Ure | Nothing to disclose | | |
| Jean-Stephane | Valla | Nothing to disclose | | |
| David | van der Zee | Nothing to disclose | | |
| John | Waldhausen | Nothing to disclose | | |
| Gunter-Heinrich | Willital | Nothing to disclose | | |
| Mark | Wulkan | Stryker | Honoraria | Advisory Committee |
| Atsuyuki | Yamataka | Nothing to disclose | | |
| C.Y. | Yeung | Nothing to disclose | | |

ORAL PRESENTATION ABSTRACTS

S001 MINIMAL ACCESS PEDIATRIC SURGERY IN THE LITERATURE: A SYSTEMATIC REVIEW

Neil Orzech MD, Mohammed Zamakhshary MD, Jacob Langer MD, Department of Surgery, Hospital for Sick Children, Toronto, Canada

AIM: To perform a systematic review of articles focused on Minimal Access Pediatric Surgery (MAPS), to determine if the quality of evidence produced over the last ten years has improved with respect to focus and methodology.

METHODS: An electronic systematic search of MEDLINE, PUBMED, Cochrane and OVID databases was performed. Search terms pertaining to MAPS were used. Studies of human subjects under 18 years from 1995 to 2006 were included. Review articles, meta-analyses, editorials, and studies published pertaining to specialties other than Pediatric General Surgery were excluded. Data collected included: study characteristics, methods, and outcomes recorded. Approval by a Research Ethics Board was recorded where applicable and articles were assessed for the reporting of learning curves and study limitations. A manual search of the Journal of Pediatric Surgery, Pediatric surgery international and surgical endoscopy and references of included articles was also performed. Studies were divided into 2 groups according to publication date: ?early era? (1995-2000) and ?late era? (2001-2006). Data were compared using correlation, chi squares and univariate analyses.

RESULTS: 410 studies fit the inclusion criteria. Of those, 260 (63.4%) were published in the late era. The majority (56.8%) were published in pediatric surgical journals ($p=0.029$). The two eras were comparable with regard to: country of origin, single-institution studies, clinical focus, length of follow up, and quality of outcomes reporting. Case reports and case series were the most common study designs. More studies in the late era reported REB approval ($p=0.0001$) and clearly documented limitation of study design ($p=0.02$).

CONCLUSION: There has been a significant increase in the number of MAPS articles. Recent studies were more likely to report limitations of the study design, but overall there was no increase in level of evidence in the MAPS literature over the past 12 years. Although more research has been performed by pediatric minimal access surgeons in recent years, more attention needs to be paid to producing higher quality evidence.

S002 CLINICAL ANORECTAL FUNCTION AND MANOMETRIC STUDY AFTER LAPAROSCOPICALLY ASSISTED ANORECTOPLASTY FOR IMPERFORATE ANUS

Sumi Kudou MD, Yoshihiro Kitano MD, Hiroo Uchida MD, Katsumi Yotsumoto MD, Tetsuya Ishimaru MD, Chikashi Gotoh MD, Hiroshi Kawashima MD, Michio Kaneko MD, Tadashi Iwanaka MD, Department of Pediatric Surgery; Saitama Children's Medical Center, Department of Pediatric Surgery; University of Tsukuba, Department of Pediatric Surgery; University of Tokyo

BACKGROUND: We previously reported midterm follow-up study of high-type imperforate anus after laparoscopically assisted anorectoplasty (LAARP) (J. Pediatr Surg. 40, 1923-6, 2005). In this report Kelly score was 3.8 ± 1.3 in the LAARP group, and 3.4 ± 0.8 in the posterior sagittal anorectoplasty (PSARP) group. There was no significant difference between both groups, partly because the age at the time of evaluation was 2 years younger in the LAARP group than that in the PSARP group due to historical retrospective study.

PURPOSE: The patients in LAARP group became almost same age as those in the PSARP group at the previous study. The aim of this study is to re-evaluate postoperative anorectal function of high-type imperforate anus after LAARP against PSARP at the same age of 6.

METHOD: From May 2000 to May 2002, thirteen patients were treated with LAARP. Their age range at operation was 4 to 16 months old. The distribution of the types of imperforate anus was: 7 recto-urethral fistulae, 2 recto-vesical fistulae, 2 recto-vaginal fistulae, 1 ano-rectal agenesis without fistula, and 1 recto-cloacal fistula. Clinical data of the LAARP group were compared with the PSARP group ($n=7$) operated between May 1998 and April 2000. All of these patients were treated with initial colostomy in the new born period. Daily glycerin enemas were given for postoperative bowel management for at least 3 years postoperatively. Age at the evaluation of this study was 5-7 years in both groups. Anorectal function was evaluated by manometry and the Kelly score. One boy from the LAARP group was excluded from this study because of severe incontinence due to spina bifida.

RESULT: Age at the evaluation in the LAARP group was almost same as that in the PSARP group (6.44 ± 0.79 vs 6.05 ± 1.03 , respectively). Kelly score in the LAARP group was significantly higher than that in the PSARP group (4.5 ± 1.1 vs 3.4 ± 0.8 , $P<0.05$). The recent results of manometric studies including pressure of anal sphincter and anorectal reflex are also reported.

CONCLUSION: The LAARP group showed higher Kelly score than the PSARP group at the age of 6. We conclude that LAARP demonstrated its superiority on postoperative anorectal function.

S003 EXPERIENCE WITH MINIMALLY INVASIVE SURGERY IN NEONATES <2.5 KG. LESSONS LEARNED, NEEDS DEFINED

Steven S Rothenberg MD, The HealthOne Children's Hospital

PURPOSE: To evaluate the safety and efficacy of minimally invasive surgical techniques in neonate < 2.5Kg

METHODS: From January 1994 to December 2006, 97 neonates, wt 1.1 to 2.5 Kg underwent advanced thoracoscopic and laparoscopic procedures. These included TEF repair, duodenal and jejunal atresia repair, PDA ligation, CDH repair, diaphragmatic plication, Nissen fundoplication, pullthrough procedure, pyloromyotomy, ladd's procedure, enterolysis, and others. These procedures were performed using specially designed 3mm instruments, 2.7 or 4mm scopes, and most were performed in specifically designed endosuites. Insufflation pressures of 12 to 15 mmHg were used for laparoscopy and 4 to 8 for thoracoscopic procedures.

RESULTS: 95 of 97 procedures were completed successfully, the intra-operative complication rate 2%, post-operative rate was 5.7%. There was no identifiable complications or morbidity related to abdominal insufflation or single lung ventilation when used.

CONCLUSIONS: MIS in the smallest neonates is well tolerated with similar advantages to that seen in larger infants and children. The most difficult task remains suturing but this can be mastered with appropriate training, experience, and instrumentation.

S004 LONG TERM FOLLOW-UP OF ERPT: LAPAROSCOPIC BETTER THAN LAPAROTOMIC

Girolamo Mattioli MPA, Alessio Pini Prato MD, Camilla Giunta MD, Stefano Avanzini MD, Gentilino Valerio MD, Vincenzo Jasonni MD, Istituto Giannina Gaslini

INTRODUCTION: The aim of this paper is to present long term results of patients with classic Hirschsprung's disease operated on with a Georgeson or Soave-Boley ERPT.

PATIENTS AND METHODS: We evaluated patients who underwent laparoscopic assisted endorectal pull-through according to Georgeson or laparotomic ERPT according to Soave-Boley. Inclusion criteria were: 1) Surgical procedure performed by the same experienced surgical group, 2) aganglionosis confined to the left colon, 3) absence of associated IND, 4) minimum follow up of six months. A comprehensive questionnaire for continence and quality of life, demographic data, postoperative complications and long-term results were compared.

RESULTS: In the period between January 1993 and November 2006, 252 patients were admitted to our Unit and 151 underwent a pull-through procedure. Fifteen patients who underwent a Soave-Georgeson procedure and 20 who underwent a Soave-Boley procedure (3 of them were converted from initial laparoscopic approach) were eligible for this study and were therefore evaluated for the long term results. Length of surgery and postop stay proved to be shorter for patients who underwent Georgeson procedure. Growth and intestinal adaptation were similar in both groups of patients. Fecal and urinary incontinence were never complained in both groups, constipation had similar incidence as did postoperative enterocolitis that occurred in less than 15% of patients. Our series of patients showed similar results in terms of overall outcome. Nevertheless, cosmetic results were better for patients who underwent a Georgeson procedure.

CONCLUSIONS: Soave-Georgeson and Soave-Boley procedures provide similar results and similar long-term outcome however the minimally invasive approach achieves better cosmetic appearance, reduce hospitalisation and improve patients' perspective and psychological acceptance.

S005 CARBON DIOXIDE SUPPRESSES NEUTROPHIL METABOLISM AND MIGRATION

Akihiro Shimotakahara MD, Joachim F Kuebler MD, Gertrud Vieten DO, Martin L Metzelder MD, Benno M Ure MD, Department of Pediatric Surgery, Hannover Medical School

BACKGROUND: Carbon dioxide (CO₂) insufflation during laparoscopy causes an acidic environment in the peritoneal cavity and dampens the systemic stress response to surgery. The peritoneal acidosis has been shown to suppress the inflammatory response of local macrophages, but the direct effects of CO₂ and acidosis on neutrophils, the dominant cell population in the peritoneal cavity during inflammation, remain unknown.

METHODS: PMNs were isolated from peripheral blood of healthy volunteers. Spontaneous and IL-8 induced migration of PMNs were measured with a transwell chamber system during exposure (2h) to: 1. CO₂ (100% CO₂, pH 6.2); 2. Acidification (95% Air / 5% CO₂, pH 6.2); 3. Hypoxia (95% helium / 5% CO₂, pH 7.4) 4. Control (95% air / 5% CO₂, pH 7.4). In a second set of experiments, PMNs were incubated in CO₂, acidic or control milieu for 4h and thereafter their cellular metabolism was evaluated using an MTT conversion assay.

RESULTS: CO₂ incubation completely blocked spontaneous as well as IL-8 induced migration of PMNs ($p < .001$ vs. controls) and significantly suppressed the MTT conversion. Acidification and to a lesser degree hypoxia mimicked the effects of CO₂ with a significant decrease of PMN migration compared to controls ($p < .05$).

CONCLUSION: CO₂ and extracellular acidosis directly affect neutrophils and suppress their function and metabolism. This mechanism could contribute to the beneficial immunomodulation during laparoscopic surgery. Nonetheless, further studies are needed to identify the consequences of a dampened neutrophil function in septic or oncologic patients.

S006 PRACTICE MAKES PERFECT: PROGRESSIVE IMPROVEMENT OF LAPAROSCOPIC PYLOROMYOTOMY RESULTS WITH EXPERIENCE

Ravindra K Vegunta MD, Jay H Woodland MD, Arthur L Rawlings MD, Elizabeth J Wallace MS, Richard H Pearl MD, University of Illinois College of Medicine at Peoria; Children's Hospital of Illinois, Peoria.

INTRODUCTION: Laparoscopic approach to pyloromyotomy is gaining favor among pediatric surgeons. We present our experience with our first 185 consecutive laparoscopic pyloromyotomies.

METHOD: IRB approved retrospective outcomes analysis of all laparoscopic pyloromyotomies performed in our institution since its inception in March 2001 and September 2006.

RESULTS: A total 185 infants underwent laparoscopic pyloromyotomies during the study period. The infants were 33 (10-155) days old, 87% were male, body weight: 4 (2.05-7) kilograms, duration of symptoms: 7 (1-60) days, resuscitation time: 16.75 (0.75-52) hours, surgery duration: 25 (12-79) minutes, feeds were started 3 (2.5-23) hours after surgery, post-operative length of stay (LOS): 25.5 (9.5-244) hours and total LOS: 45 (19-296) hours. All numbers are medians with range in parentheses. There were seven complications (3.78%): four incomplete pyloromyotomies (2.16%), two perforations (1.08%) and one wound infection (0.5%). Three were converted to open. Of the two perforations one was a delayed duodenal perforation. There has been a progressive drop in the time required for surgery from a median of 29 minutes in the first 30 cases to 21 in the last 30. Post-operative LOS has fallen from a median of 26 hours in the first half to 24.5 in the later half. Of the seven total complications, five occurred in the first third of the cases and two in the last two-thirds. Three of the four incomplete myotomies in our series happened within the first 43 cases.

CONCLUSION: Most of the early results of laparoscopic pyloromyotomy showed a higher rate of mucosal perforations and incomplete myotomies when compared with open pyloromyotomy. We are able to demonstrate that, with practice, one can expect progressive improvement in the outcomes following laparoscopic pyloromyotomy in infants. Our rates of total complications, mucosal perforations, and wound infections are all favorable when compared with published open results.

**S007 ANAESTHETIC MANAGEMENT AND CHANGES IN CO₂ EXCRETION DURING THORACOSCOPIC SURGERY IN CHILDREN**

Merrill Mchoney PhD, Fraser Munro MD, Gordon Mackinlay MD, Adam Capek, Louise Aldridge MD, Royal Hospital For Sick Children Edinburgh, Edinburgh UK

AIM: To review the anaesthetic management and changes in CO₂ excretion during thoracoscopic surgery in children.

METHODS: We analysed end tidal carbon dioxide concentration (EtCO₂; kPa) during CO₂ pneumothorax as a guide to excretion. Core temperature was also recorded as an index of whole body metabolism and thermoregulation. EtCO₂ was measured on a continuous basis, and recorded every 10 minutes. Baseline and highest EtCO₂ were used to derive the maximum change. Average EtCO₂ was also analysed over 3 time periods: 1) pre-insufflation 2) during insufflation of CO₂ and 3) after desufflation. Data presented as mean \pm SEM. Differences were compared using paired t-tests or repeated measure ANOVA. Correlations were performed using linear regression. Changes were also compared to children undergoing laparoscopy.

RESULTS: Median age was 1.9 years (range 1 day-15 years). Patient weight was 12kg (interquartile range 3.5-29.5). Ventilation was by either a single lung (10) or two lung ventilation (30). Overall EtCO₂ increased significantly ($p < .01$) from preinsufflation value of 5.1 ± 0.2 to 6.4 ± 0.3 during insufflation; values were still significantly elevated after desufflation 6.4 ± 0.4 . Single lung ventilation was associated with higher EtCO₂ levels during insufflation ($p = .02$). The pattern of change in EtCO₂ was similar in neonates ($n = 6$) within the group. There were no correlations between the maximum change in EtCO₂ and patient age, weight or operation length. In children undergoing laparoscopy EtCO₂ was 4.7 ± 0.2 pre-insufflation, peaked at 1 hour (5.3 ± 0.2 , $p < .001$) and subsequently decreased in response to ventilatory adjustments. There was a significant increase in core temperature during thoracoscopy ($p = .007$) from preop 35.9 ± 0.3 to postop 36.9 ± 0.2 .

CONCLUSION: CO₂ excretion significantly increases in children undergoing thoracoscopy; changes were higher than that seen during laparoscopy. This is well tolerated by simple increase in ventilation. Thoracoscopy may preserve intraoperative thermoregulation.

S008 LAPAROSCOPY WITH CO₂ OR HELIUM DOES NOT INCREASE THE LETHALITY TO A SUBSEQUENT BACTERIAL PERITONITIS IN A MICE MODEL

Joachim F Kuebler MD, Akihiro Shimotakahara MD, Martin L Metzelder MD, Gertrud Vieten PhD, Benno M Ure MD, Department of Pediatric Surgery, Medical University of Hannover, Hannover, Germany

AIM: Insufflation of CO₂ into the abdominal cavity during laparoscopy is known to suppress the local and systemic inflammatory response, i.e. the lethality of peritoneal LPS injection in mice. Nonetheless, an active immune response is needed to contain a bacterial contamination of the abdominal cavity. Therefore, the aim of our study was to investigate the lethality of a bacterial peritonitis after CO₂ or helium pneumoperitoneum in mice.

METHODS: Male C57/B6 mice (23-27g) in ketamine/xylazine anesthesia were subjected to a 3mmHg pneumoperitoneum using CO₂ ($n = 15$) or helium ($n = 17$) or midline laparotomy ($n = 18$). After 1h exposure, abdominal sepsis was induced by cecal ligation and puncture and animal activity and survival were monitored for 7d. In additional experiments, the effect of the CO₂ pneumoperitoneum or laparotomy on blood oxygenation in the spontaneously breathing mice was measured (each $n = 4$).

RESULTS: Application of the low pressure CO₂ pneumoperitoneum versus laparotomy did not change arterial pCO₂ in spontaneously breathing, anesthetized mice (56 ± 4 mmHg versus 52 ± 2 mmHg, $p > .05$). After cecal ligation and puncture mice displayed symptoms of abdominal sepsis and there was a delayed lethality. Post-mortem examination revealed peritonitis with intraabdominal abscess formation. The highest survival rate was observed after application of a CO₂ pneumoperitoneum, but the difference between the groups did not reach significance (30% helium, 40% laparotomy, 50% CO₂, $p > .05$ Kaplan Meyer survival rate).

CONCLUSIONS: The modulation of the immune response due to the application of a CO₂ pneumoperitoneum during laparoscopy does not lead to an increased lethality of a subsequent abdominal sepsis.

S009 TROCAR INCISION TENSIONS DO NOT SUM

Thane A Blinman MD, *Children's Hospital of Philadelphia*

INTRODUCTION: Critics of minimally invasive methods sometimes argue that the sum of lengths of multiple trocar sites produces morbidity equivalent to a conventional incision of equal length. This argument assumes correctly that pain and scarring are proportional to total tension normal to a linear incision. But the argument also assumes that total tension sums linearly with incision length. Here, I demonstrate why that premise is not valid.

METHODS: Closing tension perpendicular to any incision (elliptical with $a \gg b$) is a function of the length $f(L)$ of the incision, reaching a maximum at a point at $L/2$, and is proportional to a constant C (for directionally and strain rate independent tissue stress). The total closing tension is the sum of normal segmental tensions along the incision length. The total tension is the integral, which can be solved for $f(L)=2/3L$:

$$T_{\text{total}} = 2C \int_0^L f(L) dL \quad T_{\text{total}} \approx C \cdot \frac{L^2}{6}$$

Incisions of various lengths are modeled, and several plausible alternative incision scenarios for various procedures are compared.

RESULTS: Total tension rises non-linearly with increasing wound length. As a result, total tension across multiple incisions is less than the total tension for an incision of the same total length. Laparoscopic appendectomy and Nissen create 37% and 20% relative total tension compared to equivalent open incisions. Two 3mm trocars require less tension than a single 5mm trocar

CONCLUSION: Conventional incisions are always subject to more total tension than any combination of trocar incisions of equal total length. This relationship supports good MIS practices such as: Using smallest effective trocars; adding a trocar in more difficult procedures; and, using two small trocars instead of one larger one.

S010 RELATIONSHIP BETWEEN TIME OF REPERFUSION AND RECRUITMENT OF NEUTROPHILS, E-SELECTIN EXPRESSION, AND GERM CELL APOPTOSIS IN A RAT MODEL OF TESTICULAR ISCHEMIA

Jorge G Mogilner MD, Robert Greenblatt BS, Katya Voskoboinik BA, Michael Lurie MD, Igor Sukhotnik MD, *Dept of Pediatric Surgery and Pathology, Bnai Zion Medical Center, Rappaport Faculty of Medicine, Technion- Israel Institute of Technology*

BACKGROUND: Recent evidence suggests that neutrophil recruitment may initiate germ cell apoptosis in the ischemic testis. The purpose of the present study was to examine the relationships between time of reperfusion and between neutrophil recruitment, E-selectin expression and germ cell apoptosis in the ischemic and contralateral testis following testicular ischemia-reperfusion (IR) injury in a rat.

METHODS: Adult male Sprague-Dawley rats were divided randomly into six experimental groups: Group A- Sham operated animals; Groups B, C, D, E, F - rats underwent 90 minutes of unilateral testicular ischemia following by 1, 6, 24, 48 and 72 hours of reperfusion, respectively. The rats were sacrificed and the testes were harvested. Johnsen's criteria and the number of germinal cell layers were measured to categorize the spermatogenesis. TUNEL assay was used to determine germ cell apoptosis. The recruitment of neutrophils (PMN) was calculated per 100 venules. Expression of E-selectin was determined using immunohistochemical analysis. Statistical analysis was performed using Student T-test, with P less than 0.05 considered statistically significant.

RESULTS: In the ischemic testis, E-selectin expression and PMN recruitment increased significantly after 1 hour of reperfusion and achieve maximal levels after 6 hours followed by gradual decrease after 24, 48 and 72 hours and was accompanied by increased germ cell apoptosis after 6 hours. In contralateral testis, E-selectin expression and PMN recruitment increase significantly after 1 hour of reperfusion. E-selectin expression remained unchanged during the first 24 hours, followed by gradual decrease, while PMN recruitment remains unchanged during first 48 hours, followed by gradual decrease. Both the number of apoptotic cells and the number of tubules containing apoptotic cells in contralateral testis increased following 6 hour of reperfusion, achieved statistical significance after 24 hours, and decreased after 72 hours of reperfusion.

CONCLUSION: Germ cell apoptosis in the contralateral testis increases most significantly within first 24-48 hours following by gradual decrease. E-selectin expression and neutrophil recruitment increases within the first 6 hours and may apparently initiate the increase in germ cell apoptosis.

S011 EXPERIENCE WITH THORACOSCOPIC**APPROACHES TO TRACHEAL DISEASE IN INFANTS AND CHILDREN**

Steven S Rothenberg MD, *The HealthOne Children's Hospital*

PURPOSE: To describe the technique and examine the safety and efficacy of approaching tracheal anatomic pathology using a thoracoscopic approach

METHODS: From January 2002 to August 2006 5 patients with anatomic abnormalities of the distal trachea were approached thoracoscopically. This included a giant tracheal pouch, three tracheal bronchi, and one recurrent TEF. Ages ranged from 9 months to 8 years, wt 7.2 to 42 KG. The procedures were performed through the right chest with the patients in a modified prone position.

RESULTS: All procedures were completed successfully thoracoscopically. operative time ranged from 60 to 130 minutes. Procedures included resection of a tracheal pouch, resection of an aberrant segment, 2 upper lobectomy, and division and closure of a recurrent fistula. There were no operative or post-operative complications. Chest tube duration averaged 1 day and hospital stays averaged 2.2 days

CONCLUSIONS: Thoracoscopy provides an excellent technique for approaching anatomic abnormalities of the lower third of the trachea. The patients benefit from the same advantages of low morbidity and shortened hospital stay as with other thoracoscopic procedures.

S012 HIGH FREQUENCY OSCILLATORY VENTILATION FOR THORACOSCOPY

Nadeem Haider, Naved K Alizai, Cornelli Van Wyk, Azad Najmaldin, *Leeds General Infirmary, UK*

AIM: To present the application of high frequency oscillatory ventilation (HFOV) in thoracoscopic repair of oesophageal atresia and tracheo-oesophageal fistula (TOF) and to highlight the perceived advantages.

METHODS: Five consecutive babies underwent thoracoscopy for repair of TOF. The mean gestational age and birth weight were 37.4 weeks (range: 28+5? 41 weeks) , and 2460 gms (range: 1100? 3800 gms) respectively. HFOV was employed in all cases. Data was collected prospectively.

RESULTS: Ventilation was uneventful, and complete lung collapse resulted in excellent view in all. The thoracoscopic procedure was completed successfully in 3 babies and converted to open method in the remaining 2, because of inappropriate instrumentation in one (1100 gm baby) and a wide gap atresia in the second (> 4cm). There were no intraoperative or early post operative complications. The babies were fed via a nasogastric tube 48 hours post operatively and orally at 5-7 days. Post operative oesophagogram at 5 days did not show a leak in any case.

CONCLUSION: In thoracoscopy, HFOV allows for excellent working space and uneventful postoperative ventilation.

S013 THORACIC AND LUMBAR SUPERSELECTIVE ENDOSCOPIC SYMPATHETIC BLOCK (ESB), THE BETTER SOLUTION FOR PALMAR, FACIAL AND PLANTAR HYPERHIDROSIS/ERYTHRODERMIA OF CHILDHOOD AND ADOLESCENCE?

K Schaarschmidt PhD, A Kolberg-Schwerdt MD, M Lempe MD, F Schlesinger MD, *Helios Center for Pediatric & Adolescent Surgery, Berlin-Buch, Germany*

OBJECTIVE OF STUDY: Severe palmar/axillary, facial and plantar hyperhidrosis or facial erythrodermia are disabling: The children are socially excluded, can't work with paper, don't shake hands, slip in open shoes and intend or attempt suicide. AICI, Iontophoresis, botulinus, β-blockers, antidepressives and psychotherapy may be disappointing. Functional sympathetic surgery is freight by the risk of compensatory sweating and Horner's syndrome increasing with the number of treated levels. This study intends to minimize interference with sympathetic innervation and introduce a potentially reversible procedure. In 3 cases extensive skin loss due to bilateral palmar and/or plantar dishidrosiform eczema required urgent sympathetic surgery.

METHODS AND PROCEDURES: In 104 children and adolescents (age 17.8 ± 8.9 y, range 6.7-25 y) unresponsive to conservative treatment, a limited endoscopic sympathetic procedure was performed. 65 sympathectomies and 177 superselective sympathetic blocks were employed, in all except two bilaterally. For palmar (axillary) hyperhidrosis a 65 T3 (T4) sympathectomies and increasingly 117 T3 (T4) sympathetic blocks, for facial hyperhidrosis and/or erythrodermia 54 T2 sympathetic blocks and for plantar hyperhidrosis 6 lumbar L3 blocks were performed.

RESULTS: There was no intra- or postoperative complication, no haemorrhage, no Horner, but 2/65 cases had severe transient compensatory sweating after T3 + T4 sympathectomy for palmar + axillary hyperhidrosis as opposed to 0/117 superselective sympathetic blocks ($p < 0.05$). In two early patients one side was unsatisfactory on and a redo T2 or T3 sympathectomy were performed and two children required a drainage for residual pneumothorax. All children were cured from hyperhidrosis or erythrodermia and after 35.8 ± 11.9 months (range 5.4–76.2 mo) all patients would have had the procedure done again.

CONCLUSIONS: Extensive ablations of 2–4 ganglia have been employed in children but the increased risk of compensatory sweating was underestimated! Although small in number this study indicates, that a more conservative approach affecting only one ganglion is safer and sufficient in most cases. Moreover, superselective sympathetic block (reversible for at least 8–12 weeks) is equally effective as sympathectomy and thus in children may be preferable to ablative sympathetic surgery. Meticulous attention to technical details and HDTV-equipment are critical.

S014 THORACOSCOPIC APPROACH IN TREATMENT OF LUNG HYDATID DISEASE IN CHILDREN: RESULTS OF 21 CASES

Vladimir Kotlobovskiy MD, Sagidula Dosmagambetov MD, Aslan Ergaliev MPA, Department of Laparoscopic Surgery, Regional Pediatric Hospital, Aktobe, Kazakhstan

AIM: Evaluation of efficiency of thoracoscopic approach for treatment of lung hydatid disease in children.

MATERIALS: Since 1993 till 2007 186 children with hydatid disease ranging from 4 to 15 (7, 1+3, 3) years of age underwent endoscopic surgery. In 132 (77%) cases hydatid cysts were located in liver, in 7 (4, 1%) ? in kidneys, in 5 (2, 9%) ? in omentum, in 3 (1, 8%) ? in ovaries and tubes, in 2 (1, 2%) cases ? in pancreas, in 21 (12, 3%) ? in lungs. These children with lung hydatid disease ranging from 5 to 14 (7, 8+3, 1) years of age underwent thoracoscopic surgery. Twelve (57, 2%) patients were males, 9 (42, 8%) ? females. Ultrasonography, x-ray chest examination, CT scan, serological tests were used as diagnostic procedures before surgery. All patients accepted 10 mg/kg of albendazolum during 2 weeks preoperatively. We performed thoracoscopic approach only in cases of solitary noncomplicated hydatid cyst. The diameter of cysts ranged from 4 to 7 cm. Bronchoscopic occlusion of the lobe bronch and then the main lung bronch performed before the surgery at the cysts side. We used 3 trocars approach for most cases. Puncture and aspiration of hydatid fluid performed as a first step of the procedure. Then 1% betadine solution injected into the cysts cavity and aspirated after the 10 seconds exposition. We used 11, 15 mm trocars for vacuum extraction of endocyst. One or two chest tubes were inserted under vision control, and removed on a 2 or 3 days after the surgery. Bronchoscopic removing of occlusion sponge from the main bronch performed just after the surgery, and from the lobe bronch on a 2 or 3 days after the surgery. All patients accepted 10 mg/kg of albendazolum postoperatively during 2–6 weeks. Operation time, conversion rate, complications rate, length of hospital stay were analyzed.

RESULTS: There were no cases of mortality. Conversion rate was 1 (4, 8%) case. Duration of operation time was 52.4 ± 16 min. Postoperative surgical complications rate was 2 (9, 5%) cases of bronchogenic fistula. Both were spontaneously closed on 3 and 5 days postoperatively. Duration of the hospital stay was 7.4 ± 1.3 days. There were no recurrence.

CONCLUSION: Thoracoscopic approach was successfully performed in 95% cases of single noncomplicated cysts of lung hydatid disease in children. It demonstrates good post-operative results, low rate of complications, short duration of operation time and hospital stay.

S015 NEONATAL MINIMAL INVASIVE SURGERY FOR CONGENITAL DIAPHRAGMATIC HERNIAS

Olivier Reinberg MD, François Becmeur MD, Hossein Allal MD, Pascal De Lagaussie MD, Hubert Lardy MD, Paul Philippe MD, Manuel Lopez MD, François Varlet MD, CHU Lausanne, Strasbourg, Montpellier, Marseilles, Tours, Luxembourg, Saint Etienne (Switzerland, France, Luxembourg)

OBJECTIVE: Minimal invasive surgery (MIS) for late-presenting congenital diaphragmatic hernias (CDH) has been described, but only very few neonatal cases have been reported. The aim of this study is to report the multicentric experience in those rare cases and to compare the laparoscopic and the thoracoscopic approach.

PATIENTS: Using MIS procedures, 22 cases (10 males/12 fem.) from 7 centers have been operated for CDH within the 2 first weeks of life, 19 of them before Day 5. None but one had associated malformations. They were 7 preterms (32–36 WGA) and 15 over 37 WGA, all but 1 (1800g) being over 2600g. 14/22 were intubated at birth.

RESULTS: MIS procedures were performed in 10 cases by laparoscopic and in 12 by thoracoscopic approaches. No severe complication were observed. In 13 patients, reduction of the intra-thoracic content was easily performed (9 thoracoscopies; 4 laparoscopies), in 6 cases difficult and in another 3 impossible (1 left CDH when the left liver lobe was trapped in the defect and 2 right CDH when the liver could not be mobilized, all 3 by laparoscopy). Reduction was easier in wide diaphragmatic defects and by thoracoscopy. Reasons for the 9 conversions (5 laparoscopies vs 4 thoracoscopies) encountered were in 3 cases the liver shifted into the thorax, in 4 the lack of adequate vision to close the defect (laparoscopies), in 1 case the volume of the abdomen was too small for the bowel (thoracoscopy) and in 1 case anesthetic problem related to the lateral position of the patient and insufflation (thoracoscopy). The reduction of the spleen was always achieved either by thoracoscopy or by laparoscopy. Four defects were too wide for direct closure and needed to be closed with a patch. All 4 were converted, one being done through a video-assisted thoracoscopy. There were 2 recurrences (2 thoracoscopies), one being reoperated successfully by thoracoscopy.

CONCLUSION: CDH can be safely closed in the neonatal period by a MIS procedure. The overall success rate is 59%. Indication for MIS is not related to WGA, to weight at birth (if > 2600 g) or to the importance of the immediate neonatal care. Patients with no associated anomaly and who are hemodynamically stabilized can benefit from MIS procedure. Reduction of the herniated organs seems easier by thoracoscopy. Right CDH, liver lobe herniation into the thorax and the need for a patch are the most frequent reasons for conversion.

S016 THE DEVELOPMENT TRAINING DEVICES FOR NEONATAL SURGERY

Karen A Diefenbach MD, Suzanne Yoder MD, R. Lawrence Moss MD, Milissa A McKee MD, Yale School of Medicine

INTRODUCTION: Endoscopic surgery in the neonate presents unique technical challenges. The purpose of this project was to develop minimally invasive surgery trainers for pediatric surgeons to acquire the skills necessary to repair congenital anomalies in newborns.

METHODS: Infants weighing between 2.5kg and 3.5 kg were measured to record multiple data points on which to base a scale model of a neonate. Devices scaled for a 2.88 kg infant were developed for both laparoscopic and thoracoscopic procedures. Construct validity tests were then performed using participants of different skill level and experience. Laparoscopic trainers were used for dexterity skills, running the bowel, and intracorporeal suturing and knot-tying. Suturing and knot-tying under tension were performed in a thoracoscopic trainer designed to represent a congenital diaphragmatic hernia model.

RESULTS: The average adjusted gestational age of the infants measured was 38.7 weeks and the average weight of the infants was 2.88 kg. Completion times for the performance of tasks and the occurrence of errors (missed attempts, dropped items, air-knots, etc.) were recorded. Completion times for beginners averaged 4:55, 5:57, and 5:57 for dexterity skills, running the bowel, and suturing/knot-tying respectively. Advanced participants averaged 4:30, 3:47, and 4:03 compared to expert participants who averaged 3:04, 2:26, and 1:57 for the same tasks.

CONCLUSIONS: Performance by experienced participants was better than beginner participants in both time to completion and accuracy of completion of assigned tasks. This verifies the construct validity of the trainers. Future studies will compare a participant's operating room performance before and after the use of the trainers as well as the operating room performance of participants versus non-participants.

S017 UTILIZATION OF THORACOSCOPY IN INFANTS AND CHILDREN

Shawn D St Peter MD, Daniel J Ostlie MD, Abhilash Nair MD, KuoJen Tsao MD, George W Holcomb III MD, Children's Mercy Hospital

BACKGROUND: The safety and efficacy of thoracoscopy for thoracic lesions and conditions in children is evolving. Our experience with thoracoscopy has expanded in recent years. Therefore, we reviewed our most recent 7 year experience to examine the current applications for thoracoscopy in children.

METHODS: A retrospective review of all patients undergoing a thoracoscopic operation at Children's Mercy Hospital between January 1, 2000, and December 31, 2006, was performed. Data points reviewed included demographics, type of operation, final diagnosis, complications, and recovery.

RESULTS: During the study period, 205 children underwent 206 thoracoscopic procedures. The mean age was 9.5 years with a mean weight of 37.4 kg. 48% were male. Application of thoracoscopy included decortication for empyema in 57 patients, wedge resection for lung lesions in 32, exposure for correction of scoliosis in 26, excision or biopsy of an extrapulmonary mass in 24, operation for spontaneous pneumothorax in 21, lung biopsy for a diffuse parenchymal process in 14, repair of esophageal atresia with a lobectomy in 9, tracheoesophageal fistula (EA/TEF) in 8, clearance of the pleural space for hemothorax or effusion in 3 and repair of bronchopleural fistula in 1. Conversion was performed in 3 patients, all of whom were undergoing lobectomy. Two of these were right upper lobectomies and the other was a left lower lobectomy with severe infection and inflammation. The mean time of chest tube drainage (excluding scoliosis and EA/TEF patients) was 2.7 days. There were no major intra-operative thoracoscopic complications. A correct diagnosis was rendered in all patients undergoing biopsy. One patient required a second thoracoscopic biopsy to better define a mediastinal mass. Two patients developed post-operative atelectasis after scoliosis procedures. One patient had a small persistent pneumothorax after bleb resection for a spontaneous pneumothorax.

CONCLUSIONS: In pediatric patients with thoracic pathology, thoracoscopy is highly effective for attaining the goal of the operation with a low rate of conversion and complications.

S018 PRELIMINARY RESULTS OF THORACOSCOPIC REPAIR IN NEONATAL DIAPHRAGMATIC HERNIA: TWO INSTITUTION EXPERIENCE

Arturo Aranda MD, Mark D Gaon MD, Philip K Frykman, Thomas T Hui MD, Christian Ochoa MD, James E Stein MD, Steve C Chen MD, Cathy E Shin MD, Childrens Hospital Los Angeles, University of Southern California; Cedars-Sinai Medical Center, Los Angeles, California

INTRODUCTION: The use of minimally invasive surgery in the neonatal population is increasing. Thoracoscopic intervention for congenital diaphragmatic hernia (CDH) is no exception.

OBJECTIVE: To describe a two institution initial experience with thoracoscopic repair of diaphragmatic defects in neonates.

METHODS: At two institutions during 2005-2006, all infants with CDH who were physiologically stable with no pulmonary hypertension, requiring only minimal ventilator support and had no associated cardiac anomalies at the time of surgery underwent thoracoscopic repair of the CDH.

RESULTS: Eight selected neonates (first 2 weeks of life) with CDH were repaired thoracoscopically. Seven were successfully completed by thoracoscopy with three mesh placements, and four primarily. One right-sided CDH was converted to laparotomy with mesh placement. Minimal insufflation pressure was used, up to 5mmHg. The average operating room time was 138 minutes. There were no instances of intra-operative respiratory or cardiac instability and only one post-operative hernia recurrence. Follow up has been 5-20 months. Primary repair - 4, Thoracoscopic Mesh - 3, Conversion to Open with mesh placement - 1, Total - 8

CONCLUSION: Thoracoscopic repair of CDH in newborns is safe in a selected group of patients. Thoracoscopic mesh repair is technically feasible. The preliminary results and experience in this small two institutions cohort identified a recurrence in only one of the seven infants repaired thoracoscopically. Technical optimization and further critical analysis is required.

S019 POSTOPERATIVE CHYLOTHORAX IN CHILDREN: WHEN DOES CONSERVATIVE TREATMENT BECOME MORE INVASIVE THAN MINIMAL INVASIVE SURGERY?

Karim Khelif MD, Sebastian Ralea MD, Dominique Biarent MD, Marc-Henri De Laet MD, University Children's Hospital Queen Fabiola / Brussels - Belgium

PURPOSE: Chylothorax is an uncommon and highly morbid complication of pediatric cardiac surgery. Conservative management is the first line treatment. However, there is no agreement on timing of surgical intervention after failed medical treatment. We analysed retrospectively the complications of conservative and operative management of postoperative chylothorax.

MATERIAL AND METHODS: ICU databases were used to identify postoperative chylothorax patients. From January 2002 to December 2005, chylothorax was diagnosed in 18 children after a total of 904 cardiac procedures, for an incidence of 2%.

RESULTS: Mean age at initial surgery was 2 years 9 months. Diagnosis was made at a median of 4.5 days after surgery. Initial management was conservative in all patients, including nutritional modifications and somatostatin in 8 patients. Chyle leakage ceased in 12 patients after mean drainage duration of 17 days. 4 patients stopped leaking during the first week, 1 during the second week, 4 during the third and 3 during the fourth week. The remaining 6 patients required further surgical attention. Complications occurring on conservative treatment were broke up in weeks. During the first week only one complication occurred (pneumonia), whereas in the second 12 complications occurred (8 infectious, 3 metabolic and 1 coagulopathy). 13 complications occurred during the third week (7 infectious, 2 nutritional, and 2 coagulopathy, 1 pneumothorax and 1 trapped lung). 4 complications occurred in the 4th week (1 metabolic, 1 severe malnutrition, bedsores, and generalised skin mycosis). According to these data, 95% (19/20) of complications occurred after the first week 6 of the 18 patients underwent a right thoracoscopic thoracic duct ligation, on the basis of non improving high output leakage (2), severe weight loss and progressive hypoproteinemia (2) and life threatening complications (2). Lymph leakage ceased in all patients after a median duration of 5.5 days with no postoperative complications (mean follow-up: 22 months).

CONCLUSION: Prolonged nonoperative management of persistent chylothorax beyond 1 week, carries an appalling complication rate. We therefore suggest thoracic duct ligation should be undertaken without delay in postoperative chylothorax after one week of failed conservative treatment.

S020 DYNAMIC COMPRESSION SYSTEM (DCS) FOR THE CORRECTION OF PECTUS CARINATUM

Marcelo Martinez-Ferro MD, Carlos Fraire MD, Silvia Bernard, Hospital Privado de Niños & Hospital J.P. Garrahan

OBJECTIVE: Evaluate the results obtained with the use of a Dynamic Compression System (DCS), for the treatment of patients with pectus carinatum.

METHODS: Between April 2001 and March 2006 we treated 124 patients with Pectus Carinatum using a specially designed external compression device. Follow-up algorithm started after the placement of the compressor and included controls at 1, 3, 6 months and then with 3 months intervals until a successful correction was achieved. The DCS is a custom-made aluminum brace that is adaptable to the sternum protrusion. In the last cases, an electronic pressure measuring device was added into the brace. Pressure was measured in PSI. The system requires periodical adjustments and re-shaping. For evaluation of the results a double blinded (Patient-Doctor) subjective scale (1 to 10), was designed and applied.

RESULTS: 124 patients were treated in a 5 year period. 90 were males (72, 5%) and the mean age was of 12, 49 years, (range: 3 to 18 years). 14 patients (11, 2%) presented associated anomalies. The mean time of utilization per patient was 7 hours per day during 8 months (range 3 to 20 months). 18 patients abandoned treatment and were not evaluated for final results. Of the 106 remaining patients, 56 ended the treatment. 48/56 (85.7%) presented 7 to 10 points (excellent, very good and good results), and 8 (14, 3%) patients presented 1 to 6 points (poor and bad results). Measurement of Corrective Pressure (CP) in PSI proved that it is recommended to start with less than 2.5 PSI to avoid skin lesion and that pressures higher than 7 PSI are not candidates for this treatment.

CONCLUSION: DCS is a very effective non-surgical treatment for pectus carinatum and should be always indicated before any other surgical approach. CP measuring may be a crucial tool to avoid complications as skin lesions, partial or poor results and patient desertion. <@>

S021 THORACOSCOPIC LUNG BIOPSY IN CHILDREN WITH ENDOLOOP ALLOWS SMALLER TROCAR SITES

Todd A Ponsky MD, Steven Rothenberg MD, Rocky Mountain Hospital for Children

INTRODUCTION: Thoracoscopy is replacing open lung biopsies because it is less invasive. However, most surgeons divide the lung with an endostapler which requires a 12mm trocar. Also the smallest endostapler requires a minimum of 4.5cm of intrathoracic space to open, making its use in patients less than 10kg impractical. This report describes the use of the endoloop technique in small pediatric patients undergoing thoracoscopic lung biopsies.

TECHNIQUE: From 1993 to Feb 2007 69 patients underwent thoracoscopic lung biopsy for diagnosis and therapy. Ages ranged from 2 weeks to 4 years and weight from 2 kg to 22 kg. One 5mm and two 3mm trocars are inserted into the thorax and the pleural space is insufflated to 4 to 8mmHg. An endoloop is laid over the anticipated biopsy site and that site is grasped through the endoloop. The endoloop is then cinched down. A second loop is then placed adjacent to the first. The lung is then divided distal to the endoloops and removed through the 5mm trocar site. The lung is then re-expanded and no chest drain is left in post-operatively.

RESULTS: All 69 procedures were completed successfully thoracoscopically. Two biopsy specimens were obtained in most cases. Operative time ranged from 10- 35 minutes (average 20). There were no intra-operative complications. One patient required re-intubation and ventilator support on post-operative day 1 and developed a pneumothorax on post-operative day 2 requiring a chest tube. There were no other complications.

CONCLUSIONS: The thoracoscopic approach to lung biopsy is the preferred method of obtaining lung tissue for diagnosis. The use of the endoloop technique is a safe and effective technique in small pediatric patients avoiding problems with the limited size of the chest cavity in patients less than 10kg and avoids the use of large incisions in a small child.

S022 ENDOSURGICAL TREATMENT OF DIAPHRAGMATIC ANOMALIES IN CHILDREN

Alexander Razumovsky MD, Victor Rachkov MD, Zorikto Mitupov PhD, Olga Mihailova PhD, Manap Alhasov MD, Russian State Medical University, Moscow, Russia. Filatov Children's Hospital, Moscow, Russia

Development of endosurgery made possible to use the thoracoscopic and laparoscopic technics for correction of diaphragmatic anomalies.

MATERIALS AND METHODS: Since 2001 in the Filatov Children's Hospital 56 patients with diaphragmatic hernias were operated. In 48 cases we used endoscopic methods for surgery. There were 9 patients with diaphragmatic hernias (Bochdalek, Morgagni), 4 patients with retrosternal hernias, 22 patients with diaphragmatic hypoplasia and 13 with large hiatal hernias. Age of this group ? 1 month ? 14 years. In case of diaphragmatic hernia we used either thoracoscopic or laparoscopic approach. In 4 cases we had to fix the diaphragm to rib. In case of diaphragmatic hypoplasia we performed thoracoscopic goffering of diaphragm. In retrosternal hernias we used laparoscopic approach to return intestines in abdomen cavity, to resect suc and to close the defect. In children with large hiatal hernias we performed laparoscopic Nissen fundoplication with hiatoplasty. In case of reoperation (after open surgery ? 5 cases) we used Teflon material to strengthen the stitches.

RESULTS: In all cases we got good functional result. There were no complications during operations. In two laparoscopic funduplications (relapse of hiatal hernia after open surgery) we had to perform laparotomy due to severe adhesions

CONCLUSION: The endoscopic correction of diaphragmatic anomalies is possible in spite of age of patient and previous operations.

S023 THORACOSCOPIC VERSUS OPEN REPAIR OF TRACHEOESOPHAGEAL FISTULA AND ESOPHAGEAL ATRESIA

Brian Lugo MD, Yigit Guner MD, Thang Nguyen MD, Cathy Shin MD, Henri Ford MD, Nam Nguyen MD, Childrens Hospital Los Angeles

BACKGROUND/OBJECTIVE: Recent studies show that the minimally invasive approach to the repair of esophageal atresia (EA) and tracheoesophageal fistula (TEF) is feasible. This study aims to evaluate the efficacy and safety of the thoracoscopic technique versus traditional open thoracotomy.

METHOD: After appropriate IRB approval was obtained, we performed a retrospective chart review of EA/TEF cases from June 2000 to July 2006. Patient characteristics, operative time, duration of narcotic usage, conversion factors, postoperative complications, and long-term follow-up were recorded and compared.

RESULTS: 35 Type-C EA/TEF patients were evaluated, 27 of which underwent traditional repair via thoracotomy. There were 8 thoracoscopic attempts, 7 of which were successfully completed without conversion. Over all, the average operative time was 143.2 minutes (range, 75-215 minutes) for the thoracoscopic approach, compared to 124.6 minutes (range 82-210) for thoracotomy; mean duration of narcotic use was 52 hours (range, 24-72

hours) as compared to 176.6 hours (range 96-384 hours); the average time to extubation was 106.6 hours (range 72-212 hours) compared to 126 hours (range 72-288). There were no intra-operative complications or deaths in either group. The anastomotic leak rate was 12.5% vs.22%, whereas the stricture rate was 12.5% vs 40% for the closed and open techniques respectively. In the thoracoscopic cohort, one case was converted due to poor lung compliance and poor visualization in a 1 kg neonate, and one death occurred secondary to post extubation respiratory failure unrelated to the operation. 71% of patients had associated anomalies the most common of which were cardiac defects. The average follow up was 18 months and 28 months for the thoracoscopic and open groups respectively.

CONCLUSION: Thoracoscopic repair of esophageal atresia and tracheoesophageal fistula is feasible but technically challenging. Early results demonstrate comparable outcomes to that of the open technique. More data is needed to further evaluate the procedure.

S024 SINGLE PORT THORACOSCOPIC SYMPATECTOMY IN YOUNGSTERS WITH PALMAR HYPERHYDROSIS -ELEVEN YEARS OF EXPERIENCE

Dragan Kravarusic, Anton Kwasha, Elena Dlugy, Ran Steinberg, Elad Feigin, Jacob Katz, Enrique Freud, Schneider Children's Medical Center

BACKGROUND: Hyperhidrosis can cause significant social handicaps in youngsters. Although treatments such as oral medication, botox, and iontophoresis are available, surgical sympathectomy is being increasingly utilized.

PURPOSE: The aim of this retrospective study was to evaluate the long term outcome and value of transaxillary single-port thoracic sympathectomy for the treatment of hyperhidrosis.

METHODS: Between January 1995 and December 2006, 148 patients (66 M, 82 F, mean age 13.8 SD \pm 4.0 y) underwent trans-axillary thoracoscopic sympathectomy via a 12-mm single-port approach with destruction of the sympathetic ganglia at T[2] and T[3] using monopolar cautery. Data on postoperative morbidity and outcome were analyzed to validate the technique.

RESULTS: Mean operative time per side was 18 min; there was no conversion to an open procedure. Ninety-five percent of the patients were discharged the next day. Complications included unilateral transient Horner's syndrome in 1 patients (0.67%); residual pneumothorax requiring chest drainage in 2 patients (1.35%); and segmental atelectasis of the lung in 7 patients (4.72%) which was treated conservatively. Complete relief of palmar symptoms was observed in all patients (mean follow-up 5.03 SD \pm 1.76 y), 38% experienced some form of compensatory hyperhidrosis.

CONCLUSIONS: Single-port thoracoscopic sympathectomy produces excellent medical and cosmetic results in patients with palmar hyperhidrosis, and is associated with a short hospital stay and a low risk of complications. Although overall satisfaction rate is high, patients and parents should be fully informed about the high potential for compensatory sweating.

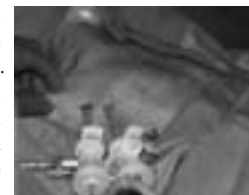S025 STEALTH SURGERY: TRANSAXILLARY SUBCUTANEOUS ENDOSCOPIC EXCISION OF BENIGN NECK AND CHEST WALL LESIONS

Sanjeev Dutta MD, Bethany Slater MD, Marilyn Butler MD, Craig T Albanese MD, Lucile Packard Children's Hospital, Stanford University Medical Center

PURPOSE: Benign neck lesions removed through an overlying incision can leave an aesthetically displeasing scar. We previously reported our experience with subcutaneous endoscopic excision of benign forehead masses through a hidden scalp incision. We now report on a similar technique that utilizes a transaxillary subcutaneous approach (Figure) for removal of lesions of the neck and chest wall.

METHODS: Retrospective chart review of 8 elective transaxillary subcutaneous endoscopic procedures from March to February 2006. The lesions included torticollis (3 patients), an enlarged cervical lymph node, a thyroglossal duct cyst, a giant back lipoma, an ectopic dilated vein, and a parathyroid adenoma. Outcome measures included need for conversion, cosmetic outcome, and complications.

RESULTS: There were no intraoperative complications and all procedures were completed endoscopically. There were 2 minor postoperative



complications (wound infection and seroma). All patients had no evidence of surgical procedure on the neck, and families were pleased with the cosmetic results.

CONCLUSION: A transaxillary subcutaneous endoscopic approach can be applied effectively to a variety of benign lesions of the neck and chest wall, allowing adequate exposure for dissection with excellent visualization. As this approach hides all scars in the axilla, patients have no visible scars, which is cosmetically appealing and of particular benefit in keloid formers.

S026 A SIMPLE METHOD OF LAPAROSCOPIC GASTROSTOMY REVISION

Marcos Bettolli MD, Claudio de Carli MD, C-C Jackson MD, Brian Sweeney MD, Steven Rubin MD, Children's Hospital of Eastern Ontario

BACKGROUND: Gastrostomies play an important role in managing long-term enteral feeding problems in children. Independent of the technique utilized, 6% of gastrostomies ultimately require surgical revision. The aim of this study is to describe a simple and effective laparoscopic technique to revise gastrostomies.

MATERIALS AND METHODS: We retrospectively reviewed 12 patients (males=8, female= 4), with a mean age of 5.5 years (range 1.4 to 15 years), requiring revision of their gastrostomy. The indications for gastrostomy revision were, cephalad migration of the gastrostomy site towards the ribs (n=4) and to facilitate the performance of laparoscopic Nissen fundoplication (n=8). A 3- port technique (gastrostomy migration) or 5- port technique (Nissen fundoplication) was used. The gastrostomy tract was taken down from the abdominal wall with a ligasure (Valley Lab) or endo shears with cautery. Once the stomach was completely detached a 0 PDS Endoloop (Ethicon) was used to close the gastrostomy. A laparoscopic assisted gastrostomy was subsequently performed.

RESULTS: Routinely, a gastrostomy-tube contrast study was performed in all patients 24 hours post operatively with no extravasation of contrast reported. Enteral feeds were re established after the study. No morbidity was associated with this technique.

CONCLUSIONS: We found this technique to be a simple, fast and effective method to control the stomach at the time of gastrostomy revision. This technique may also be a useful approach in the management of persistent gastrocutaneous fistulae.

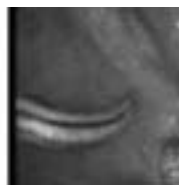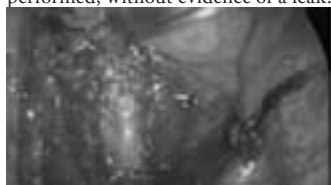
S027 OUR EXPERIENCE IN LAPAROSCOPIC EXTRAVESICAL TRANSPERITONEAL APPROACH FOR VESICoureTERAL REFLUX

Riquelme Mario MD, Riquelme-Q Mario MD, Rodriguez Carlos MD, Arturo Aranda MD, Hosp. Christus-Muguerza; Hosp. San Jose Tec, Monterrey, Mexico

INTRODUCTION: Laparoscopy may have a place in the VUR treatment, as previously reported in some small series without impact on current management. There has never been a publication with a detailed description of the technique.

OBJECTIVE: To describe with details the surgical technique used for laparoscopic extravesical vesicoureteral reimplant.

METHODS: The patient is in supine position, with the surgeon at the head. The procedure was done with three ports, with the right-hand port being a 5mm for the use of the harmonic scalpel. The abdomen is insufflated up to 8-10mmHg CO₂ and a 30 or 45 degree scope was used. The ureter is dissected free in its mid and distal portions. In females, the dissection is initiated in the anterior surface of the broad ligament. In males, the vas deferens crosses the ureter and is susceptible to injury. The detrusor tunnel is cut using the harmonic to a length of 1.5 cm to 2cm in a pyloromyotomy-like fashion, in order to bury the ureter in the detrusor. Polyester 3-0, with a RB-2 needle is used. Intra o extracorporeal knotting. Care is taken to different details such as passing the needle under the ureter in order to have the ureter buried and care not to injury the ureter. Assessment of a floppy detorsorrhaphy and a non-ectasic ureter is important. At the end of the procedure, a cystogram was performed, without evidence of a leak.



RESULTS: The procedure was successfully performed laparoscopically. No intraoperative or postoperative complications. Feedings started on postoperative day (POD) 1, discharged on POD 2. Surgical time was 110 minutes. The reflux was corrected. After a 49 months period of follow up, no urinary infection is reported, patient is asymptomatic and thriving.

CONCLUSION: Laparoscopic extravesical vesicoureteral reimplant is a safe and feasible approach for VUR. The preliminary results published in previous papers support the good alternative this minimally invasive procedure is.

S028 USE OF BOVINE PERICARDIAL STRIPS TO PREVENT AIR LEAK IN THORACOSCOPIC REPAIR OF A SPONTANEOUS PNEUMOTHORAX

Robert G Neumann MD, Michael D Rollins MD, Tamir H Keshen MD, Division of Pediatric Surgery, Saint Louis Children's Hospital, Washington University School of Medicine, Saint Louis, Missouri, USA

INTRODUCTION: Bovine pericardial strips have been used successfully to buttress pulmonary resection staple lines and prevent prolonged air leakage in adults. However, this technique has not been reported for blebectomy in pediatric patients, specifically those with cystic fibrosis. We present a case using bovine pericardial strips to prevent air leak after blebectomy in an adolescent with cystic fibrosis.

CASE: An 18-year-old male with cystic fibrosis and poor nutritional status presented to the emergency department with a spontaneous pneumothorax. Chest x-ray and subsequent chest CT demonstrated multiple apical blebs in the left upper lobe. Following chest tube placement and institution of parenteral nutrition, the patient experienced a persistent air leak for three weeks. A thoracoscopic left upper lobe apical segmentectomy was performed via a 5mm left inferolateral trocar, a 5mm subscapular trocar, and a 12mm left posterolateral trocar. The endo-GIA 45 staple line was bolstered with bovine pericardial strips and an abrasive pleurodesis was performed. There were no intra-operative complications. Upon re-expansion of the lung, the staple line remained intact with no evidence of air leak. On post-operative day 6, the chest tube was removed when the drainage was reduced to 30ml over 24hrs. The patient was discharged and a follow-up chest radiograph one month later revealed a well expanded left lung.

CONCLUSION: Bovine pericardial strips can be used safely in the pediatric population to bolster staple lines during thoracoscopic segmentectomy. This technique may be particularly useful in patients with friable lung tissue and suboptimal nutrition, commonly associated with cystic fibrosis.

S029 CHOLECYSTECTOMY WITH 3 TROCARDS AND GALLBLADDER SUSPENSION (24 CASES)

Cecilia Tolg MD, Jean François Colombani MD, Anis Echaieb MD, CHU Fort de France Martinique

INTRODUCTION: The technique of laparoscopic cholecystectomy (LC) still has areas of refinements. Refinements. To decrease safely the number of ports we used currently a percutaneous suspension of the gallbladder. We used also the harmonic scalpel to decrease the repetition of the devices movements: insertion and extraction to gain time and safety. With the youngest patients (less than 10 years) we used the 3 mm ports and we couldn't use the harmonic scalpel.

METHODS: during the late five years (2001 to 2006) 24 patients with cholelithiasis underwent 3 ports LC, 12 were performed by young surgeons. The majority had sickle cell disease or a mixed haemolytic anaemia.

RESULTS: in only 2 cases a fourth port was necessary: one case for anatomic reason (too small gallbladder) and one case for cholecystitis and adhesion of the colon on the gallbladder. In 22 cases the exposition of the Calot's triangle was easy and effective. There was no common bile duct injury and no conversion. The mean operative time was 90 minutes.

CONCLUSION: The three ports LC is feasible even in children with sickle cell disease and can be easily teach. The cosmetic result is very good and can be obtain by a very safe procedure. This technique can be used by all paediatric surgeon and doesn't need special skill like a 2 port or a 1 port LC.

S030 LAPAROSCOPIC INGUINAL HERNIA REPAIR REINFORCED BY PLICA UNBILICALIS MEDIALIS IN CHILDREN,

Vladimir Kotlovskiy MD, Anatoly Dronov MD, Aslan Ergaliev, Damir Dzenaliev MD, Marat Iliasov, Alexander Skok, Department of Laparoscopic Surgery, Regional Pediatric Hospital, Aktobe, Kazakhstan

AIM: To evaluate the efficiency of laparoscopic inguinal hernia repair reinforced by plica umbilicalis medialis in children.

MATERIALS: Since 1993 till 2005 1064 children with inguinal hernia ranging from 1 month to 15 (6, 7, 1+-4, 3) years of age underwent laparoscopic hernia repair. There were 7 (0, 66%) cases of recurrence. Since 2006 we use laparoscopic hernia repair reinforced by plica umbilicalis medialis. At this time 146 patients underwent laparoscopic hernia repair. We applied this technique in 26 (17, 8%) cases of large internal inguinal ring (more than 2 cm). Twenty fore (92, 3%) patients were males, 2 (7, 7%) ? females. We used 3 trocars approach and 3 mm instruments for most of these cases. At the first stage of hernia repair we applied pouch suture or lateral suture techniques. Then the first line of sutures reinforced by plica umbilicalis medialis. It fixed to the lateral and lower margin of internal ring by 3 ? 4 non absorbable sutures.

RESULTS: There were no cases of complications and recurrence. Duration of operation time was 23.4+-7.3 min. All patients were discharged at the next day after surgery.

CONCLUSION: Laparoscopic inguinal hernia repair reinforced by plica umbilicalis medialis decreases the rate of inguinal hernia recurrence. It demonstrates good post-operative results, short duration of operation time and hospital stay. It may be apply in cases of wide internal inguinal ring to prevent recurrence.

S031 THE USE OF PLASTIC BAG FROM A DRAIN PACKING INSTEAD OF ENDOBAG IN CHILDREN ? A SAFE, EFFECTIVE AND ECONOMICAL ALTERNATIVE

Salmal Turial MD, Martin Schwind MD, Veronika Engel MD, Mohamed Al Moghnam MD, Thomas Hueckstaedt MD, Felix Schier MD, University Medical Center Mainz, Department of Paediatric Surgery

PURPOSE: Intra-abdominal masses are removed during laparoscopy using different types of endobags. We use 2mm working trocars only, but for endobag the use of a large diameter trocar is needed. We report our experience with an improvised "endobag" made from a simple plastic bag from a drain packing used for the removal of the specimens instead of commercial endobags.

METHODE: A plastic bag from a drain Packing (6x12 cm original size) was placed in to abdominal cavity through a 5mm optic trocar at umbilicus. The scope was replaced through 5 mm trocar and the plastic bag was intraabdominally uncoiled with 2mm instruments. Angular cutting of the bag opening makes easy to open it in the abdominal cavity. After the placement of the surgical specimen into the bag, the opening site is exteriorized with a 2mm grasper through the optic trocar at umbilicus. The bag was removed over a slightly widened trocar incision.

RESULTS: We removed various of specimens (e.g. appendix, ovarian cyst, specimens from salpingo-oophorectomies, Liver-, spleen- mesenteric-urachial- cysts, kidney) in over 80 cases. They were successfully retrieved the specimens in all cases. No intraoperative complications and no rupture of the bag were seen. The plastic bag is very tearproof and very comfortable in handling compare to a finger of a surgical glove, which we used for this procedure previously.

CONCLUSION: The use of this plastic bags instead of commercial available endobags presents several advantages; the equipment is readily available, they are less expensive and economical, practical and safe. The technique is easy to perform. There is ample space to manipulate the specimen within, and there is minimal risk of contamination throughout the procedure. Finally it leads for better cosmetic results since the removal of the specimens occur through umbilicus without need for additional 10 mm trocar or incision.

S032 INFANT LAPAROSCOPIC PYELOPLASTY: POINTS OF TECHNIQUE, LISANDRO A PIAGGIO MD

Paul H Noh MD, Julia S Barthold MD, T Ernesto Figueroa MD, Amos Nebman MD, Ricardo Gonzalez, A I DuPont Hospital for Children, Wilmington, DE and Hospital Italiano Regional del Sur, Bahia Blanca, BA, Argentina

INTRODUCTION: Although laparoscopic pyeloplasty (LP) in children was reported more than a decade ago, its indication in the small infant remains controversial. At our institution LP has been the technique of choice in all age groups for the last two years. Here we present a video with our technique for LP in infants and the results of the subgroup of smaller patients in our series.

MATERIAL AND METHODS: Fourteen patients younger than a year old were operated. Important points of the technique include: dressing including the abdomen and genitalia in the operative field, cystoscopy and retrograde pyelogram with stent placement at the beginning of the procedure,

transperitoneal approach, three ports placement: camera 5-4 mm, working ports (2) 3 mm, careful dissection of the ureteropelvic junction, percutaneous hitch stitch in the pelvis, ureterotomy with Koh ultramicro scissors or pyeloplasty scissors, alignment of the anastomosis with a percutaneous stitch, repair with a running suture of 6-0 polydioxanone (needle BV-1, C1) taking small bites from proximal to distal, avoidance to ?crash the tissue?.

RESULTS: mean age (range) was 4 (0.5-11) months, mean surgical time 234 minutes, blood loss was negligible, there were no complications or conversions to open surgery, postoperative narcotic requirement was minimal, mean hospitalization was 1.7 days. At a mean follow up of 6 months there were no failures.

CONCLUSIONS: with adequate instruments and a careful technique, LP is an excellent option for infants with ureteropelvic junction obstruction.

S033 LAPAROSCOPIC SURGERY IN DUODENAL DIAPHRAGM. SURGICAL TECHNIQUE

Jorge Godoy MD, Marina Poblete MD, Angel Blanco MD, Servicio de Cirugía Pediátrica, Hospital Luis Calvo Mackenna and Clínica Las Condes, Santiago, Chile.

INTRODUCTION: The Duodenal Diaphragm (DD) is a pathology that appears in 1 of each 10, 000 to 30, 000 new born alive; 30% are associated with 21 Trisomy and other digestive malformations such as: Esophageal Atresia (7-12%), Intestinal Malrotation, Preduodenal Portal Vein, Anorectal Malformations and other Intestinal Atresias. The Laparoscopy has allowed to solve satisfactorily many pathologies. In the literature there is few notified cases of DD with Laparoscopic treatment.

OBJECTIVE: To communicate our experience, surgical technique, post-op and follow-up of the Laparoscopic Treatment of DD.

RESULTS: Six patients with DD was operate by Laparoscopic Surgery, five with associated Intestinal Malrotation. Five with Trisomy 21 ; Five women and 1 man. Ages: 19, 10, 2, 2, 1 and 3 months at time of surgery. All had vomits and were studied with upper gastrointestinal imaging to confirm the diagnosis.

SURGICAL TECHNIQUE: In the first 2 cases we used 4 trocars and then in the other 4 cases we used 3 trocars (3 and 5 mm). In the last 4 cases we used percutaneous stitches to retract the liver. Duodenum was mobilized via Kocher maneuver. The site of obstruction was detected by the discrepancy in the size of the bowel above and below the obstruction. In this place longitudinal and anterior duodenotomy was performed, and the web was opened leaving the posterior portion containing the papilla in situ. Then, transverse suture was made with Vicryl 5-0 interrupted sutures, The first two stitches were the ones at the ends and then they were taken off out side off the peritoneal cavity, for traction. Intestinal malrotation was corrected and appendectomy was made in five patients. A local drainage was left for three days in all cases. Refeeding occurred in 3 - 4 day . The hospital discharge occurred in 6, 8, 6, 7, 15 and 6 day. In this series there were no complications. Follow-up 45, 36, 28, 8, 8, and 7 months: Five patients are asymptomatic, without vomits and 1 had Gastroesophageal reflux. All have upper gastrointestinal imaging control, without duodenal stenosis.

COMMENTARY: The satisfactory surgical resolution and evolution of these patients allow us to propose the Laparoscopic Surgery like an alternative for the treatment of the DD.

S034 A METAANALYSIS OF LAPAROSCOPIC OBESITY SURGERY IN ADOLESCENCE

Oliver J Muensterer MD, Susann Blueher MD, Holger Till MD, Departments of Pediatric Surgery and Pediatrics, Children's University Hospital of Leipzig, Coordination center for clinical studies Leipzig (KKSL)

INTRODUCTION: The incidence of morbid obesity in adolescence is on the rise in most developed countries. Surgical therapeutic options developed in adults are employed increasingly in adolescents, but the experience of the individual treatment centers is limited. Therefore, we performed a metaanalysis of the published data to answer the following questions: 1) Which surgical techniques are most often employed in adolescents? What are the short- and long-term results of obesity surgery in youths? 3) What are the most prevalent complications in this age group? 4) Are certain methods more appropriate than others in adolescents?

MATERIALS AND METHODS: A PubMed literature search was performed using combinations of the key words "obesity surgery", "bariatric surgery", "adolescent" and "children". A total of 802 abstracts were found and evaluated.

RESULTS: Of the recalled abstracts, 38 were judged by the authors as relevant for the proposed study questions. These consisted of 2 cohort studies, 12 case series (9 retrospective), 6 case reports, 15 reviews and 3 published guidelines by professional association. No controlled studies were found. The oldest report on this subject was published in 1995. Most cumulatively published patients underwent laparoscopic gastric banding (n=249) and roux-Y gastric bypass (n=72). All other methods were much less prevalent (n=21 patients total). The most frequent complications after gastric banding were infection, dislocation and erosion of the device itself or the subcutaneous port. The typical complications of roux-Y gastric bypass were anastomotic leak, infection, relative protein malabsorption, and anemia. Both methods were similarly effective for postoperative weight loss.

CONCLUSIONS: Currently, the surgical techniques offered to obese adolescents are those developed and extensively evaluated in adults. Both the restrictive method of gastric banding and the malabsorptive method of roux-Y gastric bypass exhibit specific problems that may be magnified in youths due to their longer postoperative life expectancy. In this patient group, a minimally-invasive procedure without placement of a foreign body that avoids the long-term malabsorption of essential nutrients and vitamins would be favorable. In this regard, laparoscopic sleeve gastrectomy may be advantageous.

S035 DOES THE PLACEMENT OF A FRECA GASTROSTOMY AT THE TIME OF LAPAROSCOPIC FUNDOPPLICATION IMPACT ON OUTCOME?

Anies Mahomed MD, Department of Paediatric Surgery, Royal Alexandra Children's Hospital, Brighton, BNI 3JN

BACKGROUND: Several types of gastrostomy devices exist. The principle advantages to using a Freca PEG(FP)[Fresenius Kabi, Germany] following fundoplication, include: ease of insertion and a secure fit at the exit site which minimises leaks allowing for early feeding. However placement of a FP involves drawing the retaining disc through a freshly performed wrap. The safety of this technique and its impact on patient performance has hitherto not been reported.

AIM: To assess the performance of paediatric patients having a FP placed at the time of laparoscopic fundoplication.

TECHNIQUE: A Freca device was placed at the completion of fundoplication using a routine laparo-endoscopic approach. Following endoscopic retrieval of the guidewire a FP is drawn progradely through the wrap and fixed to the anterior abdominal wall.

METHOD: This is a 10 year, ambispective review, of a surgeon's experience of utilising this technique for PEG placement following laparoscopic fundoplications. Patient details were retrieved from a prospectively held Microsoft Excel database and basic demographic, operative and performance measures were analysed.

RESULTS: Of a total series of 67 laparoscopic fundoplications, 20 with neurological compromise, underwent FP placement at the time of surgery. Mean age of patients was 3.37 years with a M:F ratio of 1.1:1. A size 9 FRECA was placed in patients less than 10kgs(12) with larger patients(8) having a size 15. A Watson anterior wrap was performed in 16 cases with 4 having a Nissen fundoplication. Seven of these cases had pre-existing FP's which were taken down at the start of the procedure before replacement post fundoplication. Feeding was resumed the morning following surgery and was tolerated by all cases except for 3 with delayed gastric emptying. One of these cases suffered peri-gastrostomy leakage which settled after 10 days. Other complications (3) were not PEG related. The median stay was 4 days and patients were followed for a mean of 684 days. Over this period 4 patients relapsed and were placed on full medical treatment. FP's were changed to a button device under general anaesthetic between 3 to 24 months following placement. Change was uncomplicated and none have required redo surgery.

CONCLUSION: Freca PEG placement at the time of laparoscopic fundoplication is safe and does not compromise the outcome of surgery. The size of patient is not an impediment to its placement and the device can be used instantly in the majority allowing for an early discharge. Major complications are infrequent, however, change to a button device within 2 years of initial placement is sometimes necessary but is well tolerated

S036 LAPAROSCOPIC RESECTION OF ABDOMINAL NEUROBLASTIC TUMORS

Marc-David Leclair, P De Lagausie, F Becmeur, F Varlet, C Thomas, Js Valla, H Lardy, T Petit, P Philippe-Chomette, Py Mure, S Sarnacki, J Michon, Y Helourey, Pediatric Surgery Departments Of Nantes, Robert Debre-Paris, Strasbourg, Saint-Etienne, Nice, Tours, Caen, Debrousse-Lyon, Enfants Malades-Paris, And Paediatric Oncology, Nantes, France

BACKGROUND: Since indications for laparoscopic adrenalectomy have progressively expanded to paediatric surgery, preliminary reports have studied the laparoscopic approach for abdominal neuroblastic tumours. We aimed to report on the indications and the results of laparoscopic resection in a large series of abdominal neuroblastomas (NB) and ganglioneuromas (GN).

METHODS: A retrospective multicenter study identified 54 children with neuroblastic tumours, including 47 children with abdominal neuroblastoma (29 localized, 12 stage 4, and 6 stage 4s) and 7 with abdominal GN, who underwent laparoscopic resection of their abdominal primary tumour. The median age (range) at surgery was 16 (1-122) months (12 and 127 months for NB and GN respectively). The location of the primary tumor was the adrenal gland in 50 children, and the para-aortic left retroperitoneal space in 4. The median largest tumour diameter was 37mm (12-110). Resection was performed through transperitoneal laparoscopy (n=43) or retroperitoneoscopy (n=11). The latter was more frequently used when a benign lesion was suspected (4/7 GN vs 7/47 NB).

RESULTS: Complete macroscopic resection was achieved in 52/54 children (96%). The median duration of pneumoperitoneum was 80min. (30-200), and the length of hospital stay was 3 days (2-9). Four procedures (7%) were converted to open surgery, and tumour rupture occurred in 3 cases. No event occurred in the group of children with benign tumours (GN). Of the 29 children with localized neuroblastoma, there was a 96% overall survival (OS) rate after a median follow-up of 28 months (4-94). There was one local relapse in this subgroup, with subsequent complete remission. For the whole 47 neuroblastomas cohort, four children died and three presented a recurrence resulting in OS, disease-free survival and event-free survival rates of 84% \pm 8.1, 84% \pm 8.2, and 77% \pm 9.1 respectively.

CONCLUSION: Laparoscopic resection of abdominal neuroblastic tumors allows effective local control of the disease in a wide range of clinical situations, with an acceptable morbidity.

S037 LAPAROSCOPY IS EFFECTIVE FOR REDUCTION OF INTUSSUSCEPTION IN CHILDREN BUT SHOULD NOT BE USED FOR ASSOCIATED BOWEL RESECTION

L V Proklova, R N Haricharan, C J Aprahamian, T L Morgan, W D Hardin, C M Harmon, J M Saito, K E Georgeson, D C Barnhart, University of Alabama at Birmingham, AL, USA; Northern State Medical University Arkhangelsk, Russia

PURPOSE: The purpose of our study was to evaluate the laparoscopic reduction of intussusception and the need for bowel resection in children requiring operative intervention for intussusception after attempted non-surgical reduction.

METHODS: After IRB approval, all children who required surgical intervention for intussusception between September 1999 and January 2007 were reviewed. Demographic, clinical, radiological, operative and hospital stay data were collected on all children who underwent laparoscopic procedures.

RESULTS: During the study period 56 children underwent an operation for intussusception; 38 were attempted laparoscopically. The median age of children attempted laparoscopically was 12 months (range 2 months-12 years). The major presenting complaints were vomiting (84%), abdominal pain (78%), bloody stools (38%) and abdominal distension (16%). At laparoscopy, 31 ileocolic, 4 ileo-ileal, 1 colocolic and 2 ileo-ileocolic intussusceptions were identified. Of the 38 children who underwent laparoscopy, 23(60.5%) were successfully reduced laparoscopically (median operative time 26 minutes), and 15(39.5%) were converted to laparotomy (median operative time 97 minutes). Common reasons for conversion to laparotomy were incomplete reduction-10 children (67%) or inadequate visualization due to bowel distension-3 (20%). Of the children who could not be completely reduced laparoscopically, 80% (12 of 15) required bowel resection. Further reduction of intussuscepted bowel was possible in all cases converted to laparotomy, allowing a less extensive bowel resection in 12 cases that required resection. There were no intraoperative complications. Postoperatively, 2 children had

anastomotic leaks after resection, and 1 child had one episode of recurrent intussusception that spontaneously reduced. Median postoperative hospital stay was 3 days (1-39 days).

CONCLUSIONS: Laparoscopic reduction of intussusception is successful in the majority of patients in whom abdominal distension does not preclude laparoscopy. Children in whom laparoscopic reduction fails typically require bowel resection. However, laparoscopic bowel resection is not recommended as further reduction of intussusception can be achieved upon conversion to laparotomy.

S038 IS INTRAOPERATIVE ANAL ENDOSONOGRAPHY NECESSARY DURING LAPAROSCOPY-ASSISTED GEORGESON'S PROCEDURE FOR HIGH TYPE IMPERFORATE ANUS?

Satoko Shiyanagi MD, Kazuhiro Kaneyama MD, Hiroko Watayo MD, Yutaka Hayashi MD, Atsuyuki Yamataka MD, Juntendo University School of Medicine

PURPOSE: To evaluate the relevance of anal endosonography (AES) during laparoscopy-assisted Georgeson's procedure (GP) for high type imperforate anus (HIA) using a continence evaluation questionnaire (CEQ) and postoperative AES (P-AES).

METHODS: 15 HIA patients who underwent GP were enrolled in this prospective study. Six had intraoperative AES (IO-group) to confirm the accuracy of the pull-through (PT) canal, and 9 did not (No-group). In the No-AES group, the PT canal was created by simply dissecting the perineum/pelvic floor along the loose connective tissue plane with a pair of mosquito forceps. Postoperatively, all 15 had P-AES and differences in muscle-thickness (M-T) of the external sphincter (ES) and puborectalis (PR) at 3 and 9 o'clock respectively, were measured. If the PT colon was located centrally, the difference in M-T for each muscle was nearly zero. Nine of our patients (4 from the IO-group; 5 from the No-group) who had been followed-up for over 3 years were given a CEQ covering 5 categories (frequency of motions, severity of staining, severity of perianal erosions, anal shape, and requirement for medications) each with a full score of 2, giving a maximum CEQ of 10. All subjects were reviewed prospectively by one surgeon. Comparison of CEQ results between groups in this study was only possible for the first 4 years after GP because the maximum duration of follow-up in the IO-group was 4 years, and in the No-group was 6 years.

RESULTS: Mean age at GP for both groups was not statistically different. There were no statistical differences between the 2 groups on P-AES for mean M-T of ES and PR (For ES: IO-group was 0.18 ± 0.16 mm; No-group was 0.16 ± 0.13 mm, $p=0.79$; for PR: IO-group was 0.15 ± 0.23 mm; No-group was 0.26 ± 0.16 mm, $p=0.3$). Mean annual CEQ scores for the IO-group 1, 2, 3, and 4 years after GP were 5.3, 6.3, 7.4 and 8.4, respectively, while for the No-group were 5.9, 7.1, 8.1 and 8.2, respectively, indicating there was no statistical difference between the 2 groups.

CONCLUSION: Our results suggest that IO-AES is not necessary during GP because there is no difference in clinical and functional status that can be attributed to IO-AES. We believe a potential PT canal actually exists anatomically and is filled with loose connective tissue that can be dissected safely and accurately without using anal endosonography intraoperatively.

S039 LAPAROSCOPIC EXCISION OF CHOLEDOCHAL CYST IN CHILDREN

Yeming Wu MD, Li Hong MD, Zhilong Yan MD, Shanghai Children's Medical Center

BACKGROUND: The application of minimally-invasive surgery for complex biliary tract disease is still in its infancy. We present our series of laparoscopic excision of choledochal cyst and hepaticoenterostomy (LCCH) assessing surgical outcome.

MATERIALS AND METHODS: The charts of 29 consecutive children who underwent LCC (ages: 2m-14 y. Average: 45.2 ± 37 m) were retrospectively reviewed. Cyst diameters ranged from 12-70 mm. All procedures were performed with 4 or 5 trocars using 5 and/or 10 mm ports. LCCH was completed entirely via laparoscopy.

RESULTS: 25/29 LCCH were successfully completed (86%). 4 children were converted to traditional laparotomy secondary to intra-operative hemorrhage related to dissection of inflamed large cyst walls. There were no clinical bile leaks and on short term follow-up (range: 1-40 mo.), cholangitis or other stricture-related complications have not developed.

CONCLUSIONS: Laparoscopic excision of choledochal cysts is feasible and can be safely performed in children with acceptable surgical outcome. The

risk of post-operative cholangitis appears satisfactory on short-term follow-up, but longer follow-up is necessary before recommending this procedure as the new standard of care.

S040 LAPAROSCOPIC TOTAL CYST EXCISION WITH ROUX-EN-Y HEPATOENTEROSTOMY FOR CHOLEDOCHAL CYST: 102 CASES EXPERIENCE

Long Li MD, Liu-Ming Huang MD, Suo-Lin Li MD, the Capital Institution of Pediatrics & #65292; the First Affiliated Hospital of Peking University, Beijing; and the Second Affiliated Hospital of Hebei Medical University, Hebei, China

PURPOSE: The aim of this study is to describe the technical experience and outcome in laparoscopic total cyst excision with Roux-en-Y hepatoenterostomy for choledochal cyst in children.

METHODS: 102 patients with choledochal cyst underwent laparoscopic cyst excision with Roux-en-Y hepatoenterostomy between June 2001 and October 2006 in the three pediatric surgical centers of Beijing and Hebei. Their ages ranged from 32 days to 18 years (average age 3.2 years). Four trocars were utilized with 3 to 5 mm instrumentation. The gallbladder and the dilated bile duct were completely excised. By using laparoscope as the intraoperative endoscopy, the intrahepatic bile ducts were examined for stone debris and ductal stenosis. The Roux-en-Y jejunojunctional anastomosis was performed extracorporeally by exteriorizing the jejunum through the extending umbilical incision (1 to 1.5 cm), and an end-to-side anastomosis was carried out intracorporeally by the continuous hand suture methods between the stump of the hepatic duct and the Roux-en-Y limb.

RESULTS: 102 laparoscopic hepaticoenterostomies were accomplished laparoscopically without conversion. Average duration of operation was 224 min (ranged from 155 to 456 min), intraoperative bleeding was 5 to 10 ml without necessity for blood transfusion. 21 of 102 patients were associated with hepatic ductal stenosis and underwent laparoscopic excision of the cyst and ductoplasty. In one of the 21 cases, the bile leak was noticed from day 1 through 26 postoperatively. Two patients developed GI bleeding from day 2 through day 5 and seven postoperatively. One five-year-old girl died of hyperkalemia ($K+10.85$ mmol/L) on 7.5 hours after the operation. The postoperative course was uneventful in the other 98 patients with hospital stay ranged from 3 to 6 days after the operation. One patient developed roux-Y limb intestinal obstruction at the sixth month after operation and underwent the intestinal resection and the jejunal limb re-anastomosis. There was no intra- or postoperative complication in the other cases on three months to six years follow-up visits.

CONCLUSION: Laparoscopic total cyst excision with Roux-en-Y hepatoenterostomy is feasible, safe and effective for the treatment of choledochal cyst in children. The laparoscopic magnified view supplying the detail variations of the biliary system and accurate hepatic hilum visualization are great helpful and facilitate for the successful operation.

S041 LAPAROSCOPIC UN-ROOFING OF CONGENITAL SPLENIC CYSTS IN CHILDREN

Jan O Rutqvist MD, Stig Ramel PhD, Astrid Lindgren Childrens Hospital, Karolinska University Hospital, Stockholm, Sweden

BACKGROUND: Until 1998 all congenital splenic cysts at our department were operated with open splenic resection leaving a minor part of the spleen left. Between 1999 and 2005 seven patients underwent a minimal invasive approach. There are few reports in the literature on the subject.

MATERIAL AND METHOD: Average age at surgery was 12 years and 2 months (3y 4m-14y 4m) and there were 4 girls and 3 boys. One patient was referred after trauma with a ruptured cyst but healed without acute surgery. All seven were explored as elective cases. The mean value of the largest diameter of the cysts was 12 (9, 5-15) cm. One cyst was already ruptured and atrophic due to a smaller trauma 2 weeks before surgery. The other six were un-roofed with ultrasonic scissors or Ligasure® and the cyst epithelium was denaturalized by diathermy, ultrasonic energy or argonplasma diathermy. We used a three port technique. The patients were followed up prospectively with ultrasonography.

RESULTS: No intra or post operative complications occurred. The mean follow up time was 2 years and 11 months (1y 3m-5y 6m). 5/7 patients had rest cavities in the spleen but no symptoms. No patient needed a reoperation. All patients were pleased with their scars.

CONCLUSION: Laparoscopic un-roofing for congenital splenic cysts is a safe method that spares the spleen and gives an excellent cosmetic result.

S042 LAPAROSCOPIC CHOLECYSTECTOMY IN THE PEDIATRIC POPULATION

Scott J Keckler MD, Shawn D St. Peter MD, Abhilash Nair MD, Daniel J Ostlie MD, George W Holcomb III MD, Children's Mercy Hospital

BACKGROUND: The experience with laparoscopic cholecystectomy in children trails the adult experience and remains underreported. Therefore, we audited our experience to examine the indications for this operation, and the results with our most recent experience with laparoscopic cholecystectomy.

METHODS: A retrospective review of our most recent 6 years experience with laparoscopic cholecystectomy at Children's Mercy Hospital between September 5, 2000, and June 1, 2006, was performed. Data points reviewed included demographics, indication for operation, operative time, complications, and recovery.

RESULTS: During the study period, 169 patients were identified. The mean age was 12.8 years (range 0-21) with a mean weight of 57.7 kg. Indications for cholecystectomy were symptomatic gallstones in 135 patients, biliary dyskinesia in 20, calculous cholecystitis in 5, concomitant cholecystectomy and splenectomy in 3, gallstone pancreatitis in 3, gallbladder polyps in 1, acalculous cholecystitis in 1 and congenital cystic duct obstruction in 1. The mean operative time (excluding the concomitant splenectomies) was 80 minutes (range 30-285). An intraoperative cholangiogram was performed in 32 patients. Common duct stones were cleared intraoperatively in 5 patients. Two patients required post-operative endoscopy to retrieve stones. No ductal injuries or bile leaks have occurred. Biliary dyskinesia was diagnosed in 10% of the first 30 patients and 23% of the most recent 30 patients. The mean ejection fraction in these patients was 17%. All experienced resolution of symptoms after cholecystectomy.

CONCLUSIONS: Laparoscopic cholecystectomy is safe and effective in children. Biliary dyskinesia is becoming more frequently diagnosed in children, and these patients respond favorably to cholecystectomy. As opposed to the adult population, the incidence of complicated gallstone disease appears less common in children as most present with symptomatic cholelithiasis without active inflammation.

S043 THE VALUE OF LAPAROSCOPY IN PAEDIATRIC SURGICAL ONCOLOGY

Gordon A Mackinlay MD, Stephanie A Warne MD, Fraser D Munro MD, Royal Hospital For Sick Children, Edinburgh, Scotland

AIM: Laparoscopic techniques play a major role in paediatric surgery but are not well established in paediatric surgical oncology. We review our experience of laparoscopic surgery for the diagnosis and management of paediatric abdominal tumours and to document the advantages and complications for this group.

METHODS: Records and radiographs of all oncology patients undergoing laparoscopy from Jan 1996 - Dec 2006 were reviewed retrospectively. All operations were performed by the same 2 surgeons and details of the procedure, diagnosis and outcomes were recorded.

RESULTS: Seventy-seven Laparoscopic procedures were performed in 68 paediatric oncology patients during the study period at mean 9.2 years (Range 1 week to 12.8 years). Diagnostic laparoscopy with biopsy was performed to assess primary tumour or recurrence in 40 patients and histopathological diagnosis was confirmed in all of these. Laparoscopic procedures to excise a solid tumour were performed in 23 patients: 7 adrenal neuroblastoma, 2 ganglioneuroma, 2 pheochromocytoma, 1 adrenocorticoid-secreting tumour, 4 Wilms' tumour, 1 Renal cell carcinoma, 1 Mesoblastic nephroma, 2 pelvic rhabdomyosarcomas and 1 pelvic ganglioneuroblastoma. In 4 of the 23 although initial assessment and mobilisation of the tumour was performed laparoscopically, the procedure was converted to open for safe dissection of the tumour from major vascular structures (3 neuroblastoma & 1 Wilms' tumour). Other laparoscopic procedures to support ongoing oncology care include: Gastrostomy insertion for feeding in 5; Denver shunt insertion for malignant ascites in 1, ovarian strip harvest in 5, diagnosis of typhlitis in 1, intussusception in 1 and division of adhesions in 2 patients. Seven patients have died from their disease following treatment with a mean follow up of 4.2 years. There have been no reports of disease recurrence at port sites. The one significant post op complication was a delayed colonic perforation following laparoscopic nephrectomy.

CONCLUSION: Laparoscopic surgery is a safe and reliable tool for diagnosis of all intra abdominal tumours or suspected tumour recurrence. It can also be used successfully to surgically excise the majority of paediatric solid tumours. Laparoscopy can also play a useful role for short-term support procedures such as feeding gastrostomy but also for long-term considerations such as the preservation of potential fertility by ovarian strip harvest. The benefits

of laparoscopy for the paediatric patient are therefore multifaceted and of enormous importance in the oncology group. In units where the surgical expertise is available the laparoscopy should be considered in the diagnosis and treatment of all paediatric oncology patients.

S044 ROBOTIC GASTRIC BANDING IN ADOLESCENTS AND CHILDREN: A COMPARATIVE STUDY

Aayed R Alqahtani MD, King Saud University, College of Medicine, Riyadh, Saudi Arabia

BACKGROUND: Minimally invasive techniques are becoming the 'gold standard' approach to the surgical treatment of obesity in adult patients. Robotic surgical systems have the potential to advance the use and development of minimally invasive procedures. To date there is no comparative study of outcomes following Robotic-assisted gastric banding (RAGB) vs. laparoscopic adjustable gastric banding (LAGB) in children and adolescents. This study was undertaken to compare a single surgeon's results using the da Vinci Surgical System with those using LAGB in this group of patients.

METHODS: 25 patients underwent RAGB were compared with 50 patients who underwent LAGB. Data were collected on patient age, gender, body mass index (BMI), co-morbidities, operative time, complication rates, and length of stay

RESULTS: No significant differences in age, gender, co-morbidities, complication rates, or length of stay were found between the two groups. The mean operating time was significantly shorter for LAGB than for RAGB.

CONCLUSIONS: This study details the first comparative study, to our knowledge, between RAGB and LAGB in children and adolescent. It demonstrates the feasibility and safety of such a procedure. However, the setup of the robotic system is time consuming at present.

S045 48 HOURS WIRELESS OESOPHAGEAL PH-MONITORING IN CHILDREN-ARE TWO DAYS BETTER THAN ONE?

Anna Gunnarsdóttir MD, Pernilla Stenström MD, Einar Arnbjörnsson PhD, Department of Paediatric Surgery, Lund University Hospital, 221 85 Lund, Sweden

BACKGROUND: The technique of a catheter-free, Bravo?, pH-monitoring system for oesophageal pH-monitoring has now been implemented in clinical practice in children. This allows pH-monitoring with less discomfort and less restrained activity during the measurement. The capsule is placed in general anesthesia and the question arises whether the pH measurements should be performed through 48 hours or if a 24 hours pH measurement only gives sufficient and reliable results.

AIM: The aim of this study was to investigate the results of a pH-measurement through 24 hours and 48 hours, with comparison of measurements of the first and the second day.

CHILDREN AND METHODS: Included are eleven consecutive children with symptomatic gastro-oesophageal reflux problems. They underwent upper gastrointestinal endoscopy under general anesthesia with transoral placement of a radio-transmitting BRAVO? capsule, placed two vertebrae columns above the diaphragm. Acid exposure was monitored via a portable receiver during 48 hours. The children's symptoms during measurements were registered. Student's t-test for paired samples was used after power analysis.

RESULTS: The BRAVO? capsule was successfully attached to the esophageal mucosa in all cases with minor technical problem in only one patient. 48 hour pH-monitoring was completed in all patients. The median percentage time with esophageal pH <4 was 6, 9±8, 7 on day one and 7, 6±11, 3 on day two and the DeMeester score was 26, 0±27, 3 and 29, 8±37, 9 respectively, with no statistical significance between day 1 and 2.

CONCLUSIONS: Ambulatory pH-monitoring using the Bravo? system is feasible and safe. This was well tolerated in children. There was no significant difference between the pH-measurement on the first and the second day. Our results support the use of the pH-measurement for 24 hours only.

S046 NEPHRECTOMY BY N.O.T.E.S.

Estêvão Lima MD, Carla Rolanda MD, José M Pêgo MD, Tiago Henriques-Coelho MD, David Silva MS, Guilherme Macedo PhD, José L Carvalho MD, Jorge Correia-Pinto PhD, Division of Pediatric Surgery, Hospital S João, Porto; School of Health Sciences, University of Minho, Braga, Portugal

Natural Orifices Transluminal Endoscopic Surgery (N.O.T.E.S.) is being developed as the next step in minimally invasive surgery.

Recently, transgastric and transvesical ports have been described as feasible, safe and useful to perform complex abdominal procedures such as cholecystectomy.

OBJECTIVE: To assess the feasibility and technical benefits of transgastric and transvesical combined approach to perform moderately complex intra-abdominal procedures such as nephrectomy.

METHODS: We created a transgastric and transvesical combined approach to perform nephrectomy in six consecutive anesthetized female pigs. Transgastric access was achieved after perforation and dilatation of gastric wall with a needle knife and balloon, respectively. Under cystoscopic control, an ureteral catheter, a guide-wire and a dilator of ureteral sheath were used to place a transvesical 5 mm overtube into peritoneal cavity. Using a gastroscope positioned transgastrically, an ureteroscope and an ultrasonic scissors positioned transvesically, we carried out nephrectomy in all animals.

RESULTS: Establishment of transvesical and transgastric accesses took place without complications. Under a CO₂-pneumoperitoneum controlled by the transvesical port, the right or left kidney identification, renal vessels and ureter exposure were achieved in all cases. Transvesical revealed useful for grasping and manipulation, enhancing gastroscope-guided dissection. After complete vessels and ureter dissection, we used an ultrasonic scissors through the transvesical port that allowed dividing them safely. Excluding one case where mild hemorrhage occurred, all remaining nephrectomies were carried out without incidents. Once the closure of the gastric hole revealed unreliable using endoclips, the animals were sacrificed and necropsy was performed immediately after surgical procedure.

CONCLUSIONS: Transgastric and transvesical combined approach is feasible and revealed particularly useful to perform nephrectomy through exclusive natural orifices.

S047 FIRST APPLICATION OF NEW BEDSIDE MECHANICAL ROBOTIC INSTRUMENTS, THROUGH CONVENTIONAL TROCARS IN STANDARD PEDIATRIC LAPAROSCOPY AND THORACOSCOPY.

Klaus Schaarschmidt MD, Andreas Kolberg-Schwerdt MD, Michael Lempe MD, Frank Schlesinger MD, Helios Center for Pediatric & Adolescent Surgery, Berlin-Buch, Germany

BACKGROUND: Originally robotic surgery should provide increased dexterity in limited spaces, but available systems were devised for safe off-patient battlefield surgery and never designed for the smallest children. Thus, the potential advantages of robotic technology could never be fully applied in infants on a larger scale and so far largely simple and standard procedures were performed mainly on older children. Major drawbacks were the off-patient console design of robotic systems (surgeons console + patient-side cart steering instruments), the size of robotic arms limiting bedside access in infants, set-up times, the concern that the console might lose control and do harm (eg. software breakdown/bug) and the initial and maintenance cost of a system with limited applications. The loss of haptic feed-back in console systems (essential in fine dissection and suture-tying) is not outweighed by potential advantages like tremor reduction or motion scaling.

METHODS AND PROCEDURES: New mechanical robotic instruments (Radius Surgical System - Tübingen Scientific Inc.) offer wrist-like movements and changeable tips of a robotic setup (7 degrees of freedom) plus delicate haptic feed-back, but are used bedside through standard trocars and can be introduced into an ongoing procedure without additional setup. So far they were used for hemifundoplication, partial splenectomy, bowel resection and thoracoscopy.

RESULTS: The experience of few months and just over 10 patients is very limited, but suturing and handling were considerably facilitated in all patients and the mechanical system offered all advantages of robotic surgery, so that we missed no feature of the tested console systems. The only drawback are the so far 10mm instruments and the limited scope of 3 available tips. However, 5 mm instruments, new tips and features like different energy sources are on the way.

CONCLUSION: We have been waiting for bedside robotic manipulators for nearly 10 years and are happy to have an alternative to console settings now that they are available and affordable (28000 USD for 2 instrument-set). We demonstrate technique and use of this simple device and expect a rapid spread of the technique

S048 WATER-JET A NOVEL HIGHLY SELECTIVE ENERGY SOURCE SPARING VESSEL AND NERVES FOR RAPID, BLOODLESS ENDOSCOPIC PARENCHYMAL DISSECTION, PRELIMINARY EXPERIENCE

Klaus Schaarschmidt BA, Andreas Kolberg-Schwerdt BA, Michael Lempe BA, Frank Schlesinger MD, Helios Center for Pediatric & Adolescent Surgery, Berlin-Buch, Germany

BACKGROUND: The cutting properties of an ultrafine 120µm high-pressure water jet have been improved by new nozzle-configurations producing a twisted jet exerting a drill-like momentum on tissue surfaces, which separates different tissues exactly at anatomical cleavage planes. Soft parenchymal tissue is washed out selectively and removed by the combined jet-suction handpiece, while the network of blood vessel and nerves is preserved and can be spared or cut selectively by other energy sources like Ultrasound scissor or ultracision. The water jet has a wide range of applications from visceral to orthopedic, orofacial and neurosurgery and can be used as a continuous or pulsatile medium with adjustable frequencies from 1-6 Hertz and adjustable pressures from 1-150 bar and adjustable suction (1-800mbar).

METHODS AND PROCEDURES: From 4/2000 to 2/2007 the Erbe-Helix Hydrojet (Erbe Inc. Tuebingen, Germany) device technique was initially used in open parenchymal surgery without vessel clamping like partial liver, kidney and splenic resection as well as in pediatric oncologic surgery particularly to preserve nerves and vessels surrounded by tumors like in neuroblastoma. During the last five years it was applied to suitable laparoscopic cases like partial hepatic resection, partial splenic resection, complete enucleation of giant splenic cysts or rectal dissection in laparoscopic redo surgery for Hirschsprungs disease. In thoracoscopic surgery the technique proved to be extremely useful for endoscopic or hybrid resection of four giant thoracic tumours particularly if surrounded nerves like phrenic or vagus nerve had to be spared.

RESULTS: Water-Jet dissection (Erbe) using sterile saline solution is considerably more rapid than ultrasound aspiration (CUSA) and worked well in 21 hybrid and endoscopic applications -working pressures of 20bars (nerve or vessel dissection) to -40-60 bars (liver resection) are optimal. In endoscopy, curved applicators positioned through flexible trocars and an additional suction are helpful and the lens must be positioned in a way to avoid splashing of fluid to the lens.

CONCLUSION: Water-Jet dissection is a useful highly selective new dissection tool. Combined applicators for use with diathermy or argon beamer are developed. Useful application parameters are demonstrated and technical details are discussed.

S049 NOVEL, ERGONOMIC HANDLE DESIGNS FOR LAPAROSCOPIC INSTRUMENTATION

Russell Woo MD, Michael Ho BS, Alissa Murphy BS, Bonita Song BS, Patrick Summers BS, Sanjeev Dutta MD, Lucille Packard Children's Hospital, Stanford University Medical Center

BACKGROUND: Paresthesias of the lateral digital nerve of the first finger have been reported after prolonged use of laparoscopic instrumentation. A collaborative effort between surgeons and engineers was established to develop novel laparoscopic handle designs with improved ergonomic features.

METHODS: A needs assessment was performed utilizing extensive literature review, expert interviews, and procedural observation. Brainstorming sessions were used to develop alternative laparoscopic instrument handle designs. Iterative prototyping led to the development of multiple possible designs. First-generation designs were narrowed based on simplicity, cost, and effectiveness. Functional, second-generation prototypes were evaluated by eight surgeons using a laparoscopic trainer and a standardized, subjective evaluation form. The prototype instruments were also compared to standard, pistol grip laparoscopic instruments. Evaluation measures included qualitative assessment of large motion ability, precision, stability, tip rotation, and actuation.

PRELIMINARY RESULTS: Four functional prototypes were developed. One prototype design utilizing a thumb dial actuation mechanism scored the highest in all categories. Two designs consistently scored higher than the standard, pistol grip instrumentation.

FUTURE DIRECTIONS: User feedback is currently being utilized to further refine the two highest scoring prototype designs. Third-generation prototypes will be used to perform simulated surgical tasks over an extended period of time in order to objectively evaluate their ergonomic characteristics and overall effectiveness compared to standard laparoscopic tools.

S050 THE ROBOTIC GYRUS PK: A NEW ARTICULATING THERMAL SEALING DEVICE FOR ROBOTIC SURGERY*John J Meehan MD, University of Iowa Children's Hospital*

PURPOSE: One criticism of robotic surgery is the limited selection of instrumentation. In particular, sealing devices such as the Ligasure (ValleyLab) and the Gyrus (Gyrus ACMI) have not been available for use with the Da Vinci Surgical Robot (Intuitive Surgical). Therefore, surgeons had to incorporate standard non-articulating hand held laparoscopic devices into their operations by having the bedside assistant use these devices. This took a significant portion of the procedure out of the hands of the operating surgeon. However, a new pulse modulating device, the robotic Gyrus PK, has been manufactured specifically for the Da Vinci. We present our initial experience with this new device with results and video demonstration.

METHODS: From July, 2006 through February, 2007 we used the robotic Gyrus PK in 5 patients, age 8 months to 14 years. Procedures included a lobectomy for bronchiectasis, resection of an intralobar pulmonary sequestration, resection of a large ileal intestinal duplication, a total proctocolectomy with ileoanal pullthrough, and a splenectomy.

RESULTS: The Gyrus was used to take down the mesentery of the bowel in both GI cases, the hilum of spleen in the splenectomy, the lobar hilum in the pulmonary lobectomy and the aberrant arterial supply in the pulmonary sequestration. No blood loss was noted. Although the aberrant arterial vessel appeared to be sealed in the sequestration, the size of the vessel (7 mm) was at the limit of the recommended use for the device. We elected to place an endoclip on the vessel to ensure occlusion before we ended the procedure. In the two pulmonary cases, the Gyrus was also used to transect the pulmonary parenchyma. A chest tube was placed overnight in each case but no air leak was noted either at the time of surgery or postoperatively.

CONCLUSION: The robotic Gyrus PK offers a powerful new tool for robotic surgery. This articulating device has a variety of applications including sealing pulmonary parenchyma and blood vessels up to 7 mm. However, this current device is only available in a diameter of 8 mm and does not have a severing blade. Ideally, a smaller 5 mm device with a severing blade will be developed.

S051 FETOSCOPIC CORD LIGATION IN TWIN ? TWIN TRANSFUSION : THE AUSTRALIAN EXPERIENCE*Tim j Roberts MD, Peter Z Borzi MD, Fung y Chan MD, Andrew q Edwards MD, Chris z Kimber MD, Monash Medical Centre, Melbourne: Mater and Royal Women's Hospitals, Brisbane Australia*

PURPOSE: Fetoscopic cord ligation largely been replaced by placental laser coagulation under fetoscopic control. This procedure is still required in cases of acardiac twin, severe hydrocephalos and failed laser. Severe twin-twin transfusion has a mortality of up to 90% if left untreated with major neurological morbidity in the survivors. We reviewed the cord ligation experience at 3 major maternity centres with expertise in fetal surgery.

METHODS: All case of fetoscopic cord ligation performed at the Monash Medical Centre Victoria and two Queensland hospitals (Mater and Royal Women's) over a six year period (2000- 2006) were reviewed. The fetal loss rate, perinatal outcome and maternal complications were documented. Fetoscopic difficulties were recorded.

RESULTS: After comprehensive fetal and maternal evaluation, 17 severe case of twin- twin transfusion underwent cord ligation. Two of these cases involved triplets. Average gestational age at procedure was 23 weeks (range 17-27) Bipolar diathermy or suture ligation was performed in all case under visual guidance using a 2 port approach (3mm diam). Twelve of the 17 cases results in a liveborn singleton delivery. Four of the 12 were premature (27 -31 weeks). There were 3 immediate complete fetal losses and 2 delayed losses (1 week later secondary to spontaneous labour). No major neurological abnormality has been detected in the surviving infants. Survival improved with operator experience.

CONCLUSIONS: In our centres, fetoscopic cord ablation has a 71% success rate. This is comparable with other large international series. This technique still has a limited role in complex twin-twin disorders in particular short cords or stuck acardiac twins.

S052 LAPAROSCOPIC EXTRAVESICAL URETERAL REIMPLANTATION (LEUR): MID AND LONG-TERM FOLLOW-UP RESULTS COMPARED WITH THE OPEN TECHNIQUE*Pedro José López MD, Yair Cadena G. MD, Alessandro Tavares MD, Vanessa Muñoz MD, Octavio Castillo MD, José M. Escala MD, M. Gabriela Retamal MD, Nelly Letelier MD, Ricardo Zubieta MD, Department of Urology, Hospital de Niños Dr. Exequiel González Cortés, Santiago, Chile*

OBJECTIVES: To analyze if laparoscopy can reach the success rate of the open ureteral reimplantation (OUR) technique with the additional benefits of the minimally-invasive surgery (MIS).

METHODS: Comparative study between the 9 patients who underwent LEUR at our institution in a 5 year period and 9 patients who underwent OUR (Lich-Gregoir technique) at the same period. Demographic data, surgical and postoperative outcomes were compared between the groups.

RESULTS: The laparoscopic and open surgery groups had similar preoperative characteristics (age and sex distribution, grades of VUR, presence of preoperative voiding dysfunction). All patients underwent a unilateral repair. Mean operative times were 130 min (range 75-180) and 53min (range 45-70) for the laparoscopic and control groups, respectively ($p < 0.05$). There was 1 conversion. Following our protocol, all patients remained hospitalized with a bladder stent for 5 days; consequently, times of hospitalization and bladder stenting were similar for both groups. Ipsilateral cure of VUR was achieved in 100% of cases in both groups, but 2 patients developed contralateral VUR in the follow-up (the patient who was converted and 1 laparoscopic patient). One patient in the laparoscopic group developed transient urgeincontinence with spontaneous resolution.

CONCLUSIONS: The LEUR is technically feasible. It shows acceptable operating times, which may decrease further with the learning curve. In this preliminary experience, LEUR demonstrated to be as safe and effective as the open procedure in a mid to long-term follow-up. However, due to the protocol design, the possibility of a shorter hospital stay or better bladder recovery after MIS could not be demonstrated. Further study is necessary to show possible advantages of LEUR in patients in which a difficult access to the retrovesical ureter is anticipated (older children, obese patients or patients with severe postural deformities) and also in cases of bilateral VUR.

KEYWORDS: laparoscopy, pediatrics, vesicoureteral reflux, extravesical

S053 ASSISTED LAPAROSCOPIC ARTIFICIAL URINARY SPHINCTER IMPLANTATION .INITIAL EXPERIENCE IN PEDIATRIC POPULATION*Juan Moldes PhD, Eduardo Ruiz PhD, Maria Ormaechea MPH, Giusepucci Carlos MPH, Marcelo Urquiza Lino MPH, Martin Alarcon MPH, Francisco de Badiola PhD, Section of Pediatric Urology, Department of Pediatrics, Hospital Italiano de Buenos Aires, Buenos Aires, Argentina*

PURPOSE: We present our initial experience in posterior bladder approach using laparoscopic techniques to place an Artificial Urinary Sphincter (AUS).

MATERIALS AND METHODS: From 1990 to 2006 132 pediatric patients with urinary incontinence underwent artificial urinary sphincter placement. In the last 4 years we used the posterior laparoscopic bladder approach in 8 patients to dissect the bladder neck under direct vision. There were 6 female and 2 male patients with a mean age of 8, 7 years (range:3-20) and mean weight of 29, 5 kg (range:14-72). The etiology of incontinence in all the patients was myelodysplasia. 3 patients had simultaneous surgical procedures. In 2 cases a laparoscopic Malone procedure was done and in the third we performed a subureteral endoscopic injection of bulking agent. After a complete laparoscopic exposure of the posterior and lateral walls of the bladder neck, a small Phannestiel incision was made to place the cuff and the rest of the components of the AUS.

RESULTS: The mean follow up was 23 months (range:3-38). The average surgical time was 188 minutes (range 145-220), the mean oral feedin begun at 17, 4 hs postop. (range 3-24) and hospital stays from operation until discharge were 1, 4 days (range 1-2). We have no intraoperative complications. One patient presented a bilateral uretero vesical obstruction after the cuff activation that required an uretero vesical reimplantation.

CONCLUSIONS: The laparoscopic dissection of the bladder neck is safe and secure. It is not technical demandant and it gives the possibility to dissect the posterior wall of the bladder neck under direct vision . The results in achieving continence are similar to the reported in the literature.

EVALUATION & CME CREDIT FORMS

*Please complete the meeting evaluation form
and return to the registration desk.*

S054 UPDATE OF THERAPEUTIC INDICATIONS OF FETOSCOPY

J L Peiró MD, E Carreras MD, G Guillén MD, S Arevalo MD, M A Sánchez-Durán MD, F Castillo MD, J Lloret MD, V Martínez-Ibáñez PhD, Fetal Surgery Program. Hospital Vall d'Hebron. Barcelona. Spain.

INTRODUCTION: Since antenatal ultrasounds (us) allows to detect fetal malformations, intrauterine intervention is contemplated to correct or interfere in the natural history of these anomalies. Derivative techniques by the placement of us-guided shunts, open fetal surgery, carrying out hysterotomy and exposition of fetus, and finally, surgical fetoscopic techniques like the so called "Fetendo" (Fetal-endoscopy) are now therapeutic possibilities.

METHODS: Fetoscopic intervention is performed under epidural anaesthesia, and allows access to the uterine cavity by means of a fetoscope that contains a 1.2 mm. telescope. The fetoscope is passed through a sheath of 3 mm. that is introduced by Seldinger, after the us-guided needle puncture of the amniotic cavity. Depending on the placental position is carried out percutaneous or by means of a mini-laparotomy to expose the uterus. The visibility is maintained with an amnioinfusion system of Hartmann's solution heated to 38°C. This procedure offers access to the placental surface, umbilical cord and foetus.

RESULTS: To date, we have performed 191 fetoscopies in our Hospital from 2002. This technique was used in 141 cases to treat twin-to-twin transfusion syndrom (TTTS) in biamniotic monochorionic gestations by means laser coagulation of communicant placental vessels, in 35 cases for the ligation of the umbilical cord in cases of discordant monochorionic twins with serious or lethal anomaly in one of the fetuses and for treat the sequence of reversed arterial perfusion (TRAP). Finally, we use fetoscopy in 15 cases for the prenatal treatment of severe congenital diaphragmatic hernia (CDH) by fetal tracheal occlusion with an endotracheal balloon. Other indications, that yet there we are not used in human, are low urinary tract obstruction, for the laser ablation of urethral valves, and amniotic band syndrome for the rescue of an extremity. Has tried to apply with poor results in sacrococcygeal teratoma, by laser or radio-frequency ablation, and for the repair of the myelomeningocele. The more frequent complications are the detachment of membranes and preterm prelabour rupture of the membranes (PPROM) that carry a preterm delivery. Others are detachment of placenta and chorioamnionitis.

CONCLUSIONS: Main enemy of open fetal surgery is premature rupture of membranes and preterm labor because uterine dynamics stimulated by surgical aggression. Advances in tocolysis and less invasive surgical techniques as fetoscopy reduce incidence of this problems. At present, fetoscopy is effective for the treatment of the complications of monochorionic twin gestations, amniotic bands, posterior urethral valves and tracheal occlusion for severe CDH. Refinement of this technique and technological advances will permit its utilization for other pathologies in the future.

S055 LAPAROSCOPIC VARICOCELE LIGATION VERSUS INGUINAL VARICOCELECTOMY. A COMPARISON OF TECHNIQUES

S Duarte MD, S Piñeiro MD, A García Bayce MD, A Britos MD, H Pacheco MD, R Berazategui MD, Clínica Quirúrgica Pediátrica, Facultad de Medicina, Centro Hospitalario Pereira Rossell. Montevideo, Uruguay.

BACKGROUND: Varicocele therapy is a controversial issue, with no single approach adopted as the best therapeutic option.

OBJECTIVES: To compare the effectiveness, recurrence, outcome and postoperative hydrocele rate between laparoscopic varicocele ligation (LVL) and inguinal varicocelectomy with magnification (IVM) in two patient cohorts.

PATIENTS AND METHODS: Patients aged < 14 years were prospectively assigned into two groups for surgical correction of varicocele at the University's Children Hospital of Montevideo, Uruguay, (Pereira Rossell Hospital Center) during a 2 year period. Indications for surgery included: varicocele grade II or III according to the WHO score, inguinal or scrotal pain and/or ipsilateral testicular growth failure. Surgery was not performed to subclinical or grade I varicoceles. Effectiveness of two techniques, recurrence and postoperative hydrocele formation were evaluated by physical examination and inguinal - scrotal Colour Doppler Ultrasonography (CDUS) which were performed before and after surgery in all patients. Mean follow-up was 18 months (range, 33 to 9) In a period of 2 years a total of 35 varicocelectomies were performed sequentially in 35 boys and young adolescents with a mean age of 13 years using the LVL and IVM approaches. From July 2004 to June 2005 16 patients were included in Group A, who underwent IVM. The testicular artery and lymphatics were identified and preserved using a 2.5

loupe for optical magnification. From July 2005 to June 2006 19 patients were included in group B who underwent laparoscopic technique with mass ligation of the internal spermatic vessels.

RESULTS: There was no difference for hospital stay comparing both groups. There was not testicular atrophy in any patient. Operative time was significantly longer for IVM. Group A had 5 recurrences compared with one partial persistence in Group B. No hydroceles developed in group A. Five minimal hydroceles that did not require any treatment developed in group B.

CONCLUSIONS: LVL resulted easier to perform and a more effective technique than IVM for the treatment of varicocele. Statistical analysis showed a significant difference in varicocele recurrence (p 0.042). Posoperative hydrocele rate was higher in the LVL group. Although the difference is statistically significant (p 0.026) the hydrocele grade was minimum, without consequences and did not require treatment in any case.

S056 MINIMALLY INVASIVE TREATMENT PROTOCOL FOR VESICoureTERAL REFLUX IN CHILDREN: SELECTIVE TREATMENT WITH EFFECTIVE CURE FOR ALL

CK Yeung MD, Bijji Sreedhar PhD, JDY Sihoe MS, Edwin Chan MS, Chinese University of Hong Kong

PURPOSE: We report a minimally invasive treatment protocol for vesicoureteral reflux (VUR) in infants and children with a selective use of dextranomer/hyaluronic acid copolymer (Deflux) injection for mild grades or uncomplicated VUR and pneumovesicoscopic ureteric implantation for severe grades or complicated VUR

MATERIAL AND METHODS: Children presenting with persistent primary VUR (Grade II - V) refusing antireflux surgery were recruited. At entry, each patient had a voiding cystourethrogram (VCUG), renal ultrasonogram (US), isotopic renogram (DMSA). The minimally invasive management protocol included 1) endoscopic sub-ureteric injection for milder grades (Grade II - III, Grade IV unilateral) and 2) endoscopic Cohen's cross-trigonal ureteral reimplantation with CO2 pneumovesicum for dilating (Grade IV Bilateral to Grade V) VUR, associated with UTI and multiple pyelonephritic renal scarring. Resolution of VUR was confirmed by VCUG at a minimum follow up period of 6 months after the procedure

RESULTS: One hundred and seventeen patients (45 bilateral) were treated. Endoscopic sub-ureteric injection was given to 24 children (M/F: 8/16, Mean age: 5.75 ± 3.61yrs, 72 refluxing ureters) and Endoscopic cross-trigonal ureteric reimplantation was successfully performed in 93 children (M/F: 72/21, Mean age: 5.1 ± 5.61, 90 refluxing ureters). Follow-up cystogram showed complete resolution of VUR in 69 ureters (96%), and in 89 ureters (99%), in those who underwent subureteric injection and ureteric reimplantation respectively. VUR downgraded in 1 (underwent surgical intervention) and persisted in 3 ureters treated with subureteric injection and were treated successfully by repeat injection.

CONCLUSIONS: This new minimally invasive treatment algorithm with a combined and selective use of Deflux injection for mild grades of VUR and endoscopic pneumovesical ureteral reimplant for severe VUR offers very effective cure for all grades of VUR. The very high cure rate alleviates the need for follow-up VCUG's and long term antibiotic treatment

S057 EXPERIENCE WITH A NEW 3 MM LAPAROSCOPE IN COMPLEX NEONATAL MINIMALLY INVASIVE SURGERY: A PRELIMINARY REPORT

Philip K Frykman MD, Masanobu Hagiike MD, Thomas T Hui MD, George Berci MD, Division of Pediatric Surgery1, Department of Surgery2, Cedars-Sinai Medical Center, Los Angeles, California. Department of Surgery3, David Geffen School of Medicine at the University of California, Los Angeles

Neonatal minimally invasive surgery requires small light weight instruments and excellent image quality to be performed safely and efficiently. We performed laboratory studies comparing image quality of a new 3 mm 14 cm telescope with a 5 mm 25 cm telescope with identical viewing angles and found they were very similar. We employed the new 3 mm telescope exclusively in endosurgical procedures on five infants weighing less than 4 kg and found the image quality and light intensity to be more than adequate. In addition, we found the shorter length and lighter weight easier to maneuver in the limited working space of the neonatal abdomen or hemithorax. Our experience with the new 3 mm telescope is superb for the demands of complex neonatal endosurgical procedures. Video of procedures will be presented.

VIDEO PRESENTATION ABSTRACTS

V001 INCISIONLESS AND TROCARELESS TRANSANAL RESECTION OF THE RECTOSIGMOID FOR SEVERE IDIOPATHIC CONSTIPATION

Richard A Falcone MD, Marc A Levitt MD, Alberto Pena MD, Cincinnati Children's Hospital Medical Center

Colonic dysmotility, idiopathic constipation, or pseudoobstruction are all terms to describe patients with severe motility disorders of the intestinal tract. The necessary management of such patients covers a broad spectrum from simple dietary changes to intestinal transplantation. A unique subgroup of these patients have an enormously dilated rectosigmoid and a relatively normal caliber proximal colon. Strategies to help such patients include treatment with enormous doses of laxatives. Although this is often successful, the associated quality of life can be quite poor secondary to vomiting, cramping, and bloating. In such patients we have offered resection of the most dilated segment utilizing a minimally invasive transanal approach.

The accompanying video demonstrates our technique for the performance of a completely transanal resection of 60 cm of rectosigmoid in a 10 year old boy with severe idiopathic constipation. We have now performed this surgery in 10 children with idiopathic constipation at a mean age of 10 years old. Overall, patients have had an average of a 60% reduction in laxative requirement to have daily bowel movements without soiling and with an x-ray clean of stool. One patient has had a stricture which responded to dilation and one has required further colonic resection secondary to persistent severe constipation.

This minimally invasive and relatively painless procedure offers a unique approach to the management of this challenging clinical problem.

V002 LAPAROSCOPIC RETROPERITONEAL POUCH SPLENOPEXY FOR WANDERING SPLEEN

Michael J Leinuand MD, Marc T Downing MD, Adrian Seah BS, The Children's Hospital at Bronson, Kalamazoo, MI, USA

BACKGROUND: Wandering spleen is a rare condition in which there is a laxity or absence of the normal ligaments that anchor the spleen. This anomaly increases the risk for splenic torsion leading to symptoms of abdominal pain. In this situation, splenopexy is the treatment of choice to avoid the complication of postsplenectomy sepsis. Various techniques for splenopexy have been performed including suture ligation directly to the diaphragm, placement into an intraperitoneal pouch of absorbable mesh or omentum, and placement into a retroperitoneal pouch. Recently, our group successfully performed a laparoscopic splenopexy using a retroperitoneal pouch. We present it herein as a video case report.

METHODS: Our patient is a 16 year old girl with a one year history of intermittent left-sided abdominal pain and a palpable central abdominal mass. Ultrasound demonstrated a mobile mass in her mid-abdomen consistent with a wandering spleen. Laparoscopic splenopexy was performed using three 5 mm incisions. The spleen was placed into a retroperitoneal pouch created in the left abdominal wall. The peritoneum was closed over the spleen in an interrupted fashion leaving a window for the splenic vessels.

RESULTS: The laparoscopic splenopexy was completed in 120 minutes. The postoperative course was uneventful, and the patient was discharged home on the first postoperative day. After one month, she was asymptomatic, and ultrasonography showed the spleen to be in its retroperitoneal pouch with normal blood flow.

CONCLUSION: Laparoscopic retroperitoneal pouch splenopexy appears to be a safe and effective approach to the wandering spleen.

V003 THE USE OF SUGISIS FOR HIATAL REINFORCEMENT AT THE TIME OF RE-DO LAPAROSCOPIC FUNDOPLICATION

George W Holcomb, III MD, Casey M Calkins MD, Children's Mercy Hospital

Transmigration of the fundoplication wrap has been shown to occur in 5% to 10% of patients following laparoscopic Nissen fundoplication. Often, the fundoplication wrap is intact. Correction of this problem involves relocation of the wrap into the abdomen and closure of a markedly enlarged esophageal hiatus. If the wrap is not intact, re-do fundoplication is also necessary. This video will depict the salient features of laparoscopic repair in a patient who developed transmigration of the fundoplication wrap following a laparoscopic

Nissen fundoplication. In order to reinforce the closure of the enlarged esophageal hiatus, a piece of Surgisis (Cook, Inc., Bloomington, IN) was fashioned and used to reinforce the hiatal closure.

V004 TECHNIQUE OF URETERICVIDEO ASSISTED TAILORING AND REIMPLANTATION FOR URETEROVESICAL OBSTRUCTION USING CO2 BLADDER INSUFFLATION

J.S. Valla, MD, Hopital Lenval

The technique described here in a video is particularly applicable to the primary obstructed mega-ureter but also in case of secondary uretero-vesical obstruction: the goal is to relieve the obstruction and at the same time to prevent vesico-ureteric reflux. As for transvesicoscopic ureteric reimplantation three 5mm ports are inserted supra-pubically in the bladder. 5mm scope provides intravesical vision; after ureteral intravesical mobilisation, the mega-dolicho uretere is extracted together with the ipsilateral port through the bladder and abdominal wall. Outside the abdomen, excision of the redundant portion and tailoring is performed using classical open surgical techniques. The narrowed segment of the ureter is reintroduced in the bladder together with the port; a submucosal tunnel is fashioned according to COHEN technique and the ureter is passed through it; the ureteral extremity is anchored to the bladder musculature and circumferentially to the mucosal edges of the tunnel. Port holes are close; a bladder catheter is left for 2 days. Ureteric splinting may or may not be considered necessary.

This technique is also appropriate in case of bilateral megauretere.

V005 LAPAROSCOPIC REPAIR OF MORGAGNI TYPE DIAPHRAGMATIC HERNIAS

Arturo Aranda MD, Wang Kasper MD, Cathy E Shin MD, Childrens Hospital Los Angeles, Univeristy of Southern California

INTRODUCTION: The repair of an anterior diaphragmatic hernia (Morgagni) in the pediatric population can be quite challenging and often requires a large size incision due to its localization and limited exposure. The use of minimally invasive surgery (MIS) for the repair of Morgagni type diaphragmatic hernias have been done in several centers worldwide.

OBJECTIVE: To describe in a video presentation the surgical technique in repairing an anterior diaphragmatic hernia.

METHODS: The procedure was done with three 3mm ports. The abdomen was insufflated at a pressure of 8-12mm Hg and the visceral contents were reduced. The edges of the diaphragmatic defect were dissected, mobilized and the hernia sac excised. Primary closure was achieved in the first case, using an initial extracorporeal traction stitch and then both intra- and extracorporeal knot tying. In the second case, all repair stitches were introduced transabdominally, through the posterior rim of diaphragm and then passed back out through the abdominal wall. Knots were tied above the fascia within the subcutaneous skin.

RESULTS: The procedures were successfully performed laparoscopically. There were no intraoperative or postoperative complications. Feedings were started on postoperative day (POD) 1, discharged on POD 3 on both cases. The first patient after 12 months of follow up is asymptomatic and on X-ray, without recurrence. The second patient has been asymptomatic after a month of follow-up.

CONCLUSION: Laparoscopic approach for the repair of Diaphragmatic hernias, Morgagni type, can be a very good alternative for the repair of this defect, and can be done safely using different techniques.

V006 LAPAROSCOPIC INVERSION LIGATION INGUINAL HERNIA REPAIR IN GIRLS

Celeste Hollands MD, University at Buffalo

This video demonstrates the technique for laparoscopic inversion ligation or LIL inguinal hernia repair in girls.

V007 LAPAROSCOPIC DIAPHRAGMATIC PLICATION

Troy L Spilde MD, Daniel J Ostlie MD, Children's Mercy Hospital

PURPOSE: The purpose of this video is to demonstrate our technique using the laparoscopic approach for plication of a paralyzed right diaphragm.

METHODS: A 5.7 kg, 4 month old female was born with a paralyzed right diaphragm. She developed poor feeding and weight gain in association with

decreased activity level and paradoxical motion of the right diaphragm necessitating plication. A 5mm umbilical cannula and three 2.7 mm laparoscopic instruments placed in a transabdominal wall fashion were used to perform the repair.

RESULTS: The patient was discharged on postoperative day one. She had improved feeding and gained weight in the first postoperative week, with return of normal activity by two weeks. She has continued to do well with 6 months followup.

CONCLUSIONS: Laparoscopic plication of the diaphragm is a safe technique in the setting of paralyzed diaphragm.

V008 PEDIATRIC TRANS-AXILLARY TOTALLY ENDOSCOPIC PARATHYROIDECTOMY

Thom E Lobe MD, Simon K Wright MD, Blank Children's Hospital

Minimal access head and neck surgery as a rapidly evolving area of minimally invasive surgery. Relatively few applications of totally endoscopic techniques for pediatric head and neck surgery have been described. The markedly reduced morbidity of Trans-Axillary Totally Endoscopic (TATE) access to the neck makes this approach well-suited for pediatric endocrine surgery. We present what is to our knowledge the first report of totally endoscopic transaxillary parathyroidectomy in the pediatric population. We have extensive experience with TATE thyroidectomy. This approach is identical for parathyroidectomy. Operative time was less than 40 minutes and rapid PTH demonstrated physiologic cure. No complication occurred. Nearly no pain was experienced postoperatively and the patient was discharged to home the day of surgery. We conclude that Trans-Axillary Totally Endoscopic parathyroidectomy is a feasible and desirable method for parathyroidectomy in the pediatric population.

V009 LAPAROSCOPIC DUODENAL ATRESIA REPAIR WITH U-CLIPS

George W Holcomb, III MD, Shawn D St. Peter MD, Children's Mercy Hospital

A two day old infant female was diagnosed with duodenal atresia on an abdominal radiograph. She was taken to the operating room for laparoscopic duodenal atresia repair. After trying a variety of port positions, we have settled on positioning our instruments and cannulas as follows: A 5 mm cannula is placed in the umbilicus for insertion of the telescope. Two stab incisions are made in the right lower abdomen, one for a grasping forceps, and one for a dissecting instrument and a needle driver. A transabdominal suture is placed extracorporeally around the ligament of Treitz to help elevate the liver. In addition, a 3 mm liver retractor is also introduced in the right upper abdomen.

The salient features of our approach are depicted in the video including the utilization of U-clips (Medtronic, Inc., Minneapolis, MN) for performing the anastomosis. An upper GI contrast study was performed on the sixth postoperative day which showed no evidence of anastomotic complications. Oral feedings were started that day and the baby was discharged two weeks postoperatively. She has not developed any problems in the three months that she has been followed after the operation.

This video will be shown at the 2007 APSA meeting.

V010 ENDOSCOPIC OBLITERATION OF A RECURRENT TRACHEOESOPHAGEAL FISTULA USING SURGISIS

George W Holcomb, III MD, Casey M Calkins MD, Shawn D St. Peter MD, Children's Mercy Hospital

This patient is now 2½ years old and was born with esophageal atresia and tracheoesophageal fistula. She underwent thoracoscopic repair shortly after birth and recovered uneventfully until six months later when she presented with evidence of a recurrent tracheoesophageal fistula. She then underwent a right extra-pleural thoracotomy with repair of the recurrent tracheoesophageal fistula and interposition of parietal pleura between the esophageal and tracheal suture lines. Five months later, she returned with coughing symptoms and an esophagram suggested a small recurrent tracheoesophageal fistula. She was taken to the operating room for bronchoscopy at which time a fibrin glue was introduced into the depths of the fistula. This was unsuccessful in obliterating the fistula. She then underwent a repeat bronchoscopy at which time three pieces of 8-ply Surgisis Gold (Cook, Inc., Bloomington, IN) were cut into a 1 x 1 cm circle and introduced into the fistula tract. This technique has been successful in that she has not developed a recurrent fistula with over a two year follow-up.

The salient features of the technique of introduction of the Surgisis Gold into the tracheoesophageal fistula will be depicted.

This video will be shown at the 2007 APSA meeting.

V011 LAPAROSCOPIC RESECTION OF A LARGE BENIGN HEPATIC TUMOR

Deepika Nehra BS, Samuel Rice-Townsend BS, Sanjeev Dutta MD, Lucile Packard Children's Hospital, Stanford University School of Medicine

INTRODUCTION: Laparoscopic resection of liver masses in children has remained undeveloped despite the wide acceptance of minimal access pediatric surgery. We present the laparoscopic resection of a large benign hepatic mass in a child using a combination of technologies that enable precise dissection.

CASE PRESENTATION: A 2-year old boy presented with a large asymptomatic abdominal mass. CT scan and MRI demonstrated an 11x10x7cm tumor arising from the right hepatic lobe. Biopsy demonstrated mesenchymal hamartoma. After 6 months observation, the mass was unchanged and the parents elected for operative resection.

SURGICAL PROCEDURE: The patient was positioned supine at the foot of the bed and four ports were placed. A laparoscopic ultrasound probe was inserted to clearly identify tumor borders and help guide diathermy scoring of the liver capsule in preparation for nonanatomic resection. The liver parenchyma was transected using a laparoscopic hydro-dissection device. At regular intervals the skeletonized vessels and ducts were sealed and transected using a 10-mm Ligasure (Valleylab, CO). The ultrasound probe was intermittently applied to each raw surface to demonstrate intact tumor with a margin of normal parenchyma in the specimen. Once resection of the tumor was complete, the raw surface was coagulated using short bursts of the laparoscopic Argon Beam Coagulator (Conmed, NY). Fibrin sealant glue was applied to ensure hemostasis and prevent bile leak. Though morcellation and removal through a port site was possible, a bag large enough to accommodate the specimen was not available hence it is removed through a 6 cm Pfannenstiel incision.

POST-OPERATIVE COURSE: The patient had an uneventful recovery and was discharged on postoperative day 3. Pathology confirmed mesenchymal hamartoma with negative surgical margins. This video demonstrated the feasibility of nonanatomic laparoscopic benign hepatic tumor resection in a child.

V012 VIDEO-ASSISTED TRANS-ORAL ENDOSCOPIC RESECTION RETROPHARYNGEAL ECTOPIC THYMUS IN A NEWBORN PRESENTING WITH AIRWAY OBSTRUCTION

Simon K Wright MD, Thom E Lobe MD, Michael S Irish MD, Blank Children's Hospital, Des Moines, IA

Video-assisted head and neck surgery is a rapidly evolving category of operative techniques aimed at reducing incision length and morbidity in head and neck surgery. Until now, these techniques have not been translated into transoral applications, and have mainly been confined to endocrine procedures in the adult population. This report describes the first application of the video-assisted technique in the airway. We describe the use of transoral video-assisted endoscopic techniques for the minimally invasive resection of a large obstructive ectopic retropharyngeal thymus in a newborn presenting with airway obstruction. In this case, the 3 cm ectopic thymus was safely removed through a mini-incision high in the posterior wall of the pharynx, resulting in minimal morbidity and avoiding a transcervical approach. The distinguishing features of this technique are demonstrated and versatility of applications discussed.

V013 LAPAROSCOPIC PANCREATOCYSTGASTROSTOMY FOR PANCREATIC PSEUDOCYST

Shawn D St Peter BA, Daniel J Ostlie BA, Children's Mercy Hospital

PURPOSE: The purpose of this video is to demonstrate the laparoscopic creation of a cystogastrostomy for pancreatic pseudocyst.

METHODS: A 14 year old female presented with gallstone pancreatitis and underwent uneventful cholecystectomy. She subsequently developed a large pancreatic pseudocyst that led to symptoms of gastric outlet obstruction. A laparoscopic pancreatocystogastrostomy was created in a transgastric fashion using 5 and 12 mm laparoscopic instruments and endoscopic staplers.

RESULTS: The patient had an uneventful recovery and was discharged on postoperative day five. She had improved tolerance of oral feeds and no further symptoms of outlet obstruction. Abdominal ultrasound at 4 months postoperatively showed complete resolution of the pancreatic pseudocyst. She remains symptom free at nine months after laparoscopic drainage.

CONCLUSIONS: Although technically demanding, laparoscopic cystogastrostomy for pancreatic pseudocyst can be accomplished safely and effectively via the laparoscopic approach.

V014 LAPAROSCOPIC COLECTOMY AND PELVIC POUCH PROCEDURE

Ivan R Diamond MD, Gudrun Aspelund MD, Jacob C Langer MD, Division of General Surgery, The Hospital for Sick Children, Toronto, Canada

This video demonstrates our technique for laparoscopic colectomy and pelvic pouch creation in a 16-year old girl who presented with an acute flare of ulcerative colitis that did not respond to maximal medical management. The procedure was done via 4 ports (12mm umbilical and right lower quadrant and 5mm left lower and upper quadrants). Mobilization of the colon was undertaken laparoscopically using the ligasure, with extraction of the colon and ileal J-pouch creation done through the right-lower quadrant port site. The rectosigmoid dissection and pouch-anal anastomosis were both completed laparoscopically, and a loop ileostomy was sited at the right-lower quadrant port site. This approach produces an excellent long-term cosmetic result. The patient had an uneventful post-operative course, and was discharged on the 6th post-operative day.

V015 THORACOSCOPIC REPAIR OF LONG GAP ESOPHAGEAL ATRESIA

Steven S Rothenberg MD, The HealthOne Children's Hospital

This video demonstrates the technique of thoracoscopic repair of a long gap pure esophageal atresia. This patient is a 6 week old former 32 week premature infant born with pure esophageal atresia and imperforate anus. At 6 weeks of age and 3.4 KG the baby underwent repair of a pure long gap esophageal atresia. The gap was 5 1/2 vertebral bodies on xray.

The procedure was done without single lung ventilation and with 3 ports.

The procedure took 85 minutes.

The patient was kept sedated and intubated for 5 days. G-tube feeds were resumed on POD#10.

This video demonstrates that long gap atresia can be safely and effectively managed using a thoracoscopic approach, diminishing the morbidity associated with other techniques.

V016 THORACOSCOPIC UPPER LOBECTOMIES FOR SYMPTOMATIC CONGENITAL LUNG CYSTS

Sherif Emil MD, Wendy Su MD, Fombe Ndiforhu MD, University of California Irvine

Thoracoscopic techniques are increasingly being used for lung resections in children with congenital cystic lesions. Experience suggests that upper lobes are more difficult to resect than lower lobes, and that resection after episodes of infection can be more complicated.

This video will show a left upper lobectomy in a 12 year old boy and a right upper lobectomy in a 1 year old girl. Both patients presented with significant pneumonias due to underlying cystic lesions of the upper lobes. Thoracoscopic resections were completed after the infections were successfully treated. Both patients had excellent outcomes.

The video will show the radiologic imaging of both patients and the essential steps in thoracoscopically dissecting and resecting the upper lobe in each patient.

V017 STAGED LAPAROSCOPIC CEPHALIC PANCREATECTOMY FOR THE TREATMENT OF PERSISTENT HYPERINSULINISM,

Maria M Bailez MD, H - Questa MD, F - Prieto MD, Pediatric Surgery, J. P. Garrahan Hospital . Buenos Aires .Argentina

PURPOSE: Illustrate the laparoscopic maneuvers to resect the pancreas preserving the duodenum and bile duct in a 4 months old patient.

CASE PRESENTATION: A 43 days old girl underwent laparoscopic subtotal pancreatectomy with the diagnosis of congenital hyperinsulinism after failed medical treatment. Frozen section biopsies were taken during resection which

stopped in the presence of normal pancreas. Definitive histology informed diffuse pancreatic cells hyperplasia. Because of persistent hyperinsulinism a new laparoscopic approach was planned to resect the head of the pancreas .

TECHNIQUE: We use 3 ports (one umbilical 4 mm for the scope , one 3 mm in the left and one short 5 mm in the right flank . Percutaneous stitches were used to lift the stomach and expose the pancreas. Omental adhesions were freed using the bipolar sealer (Ligasure). The cephalic pancreas was carefully dissected from the duodenum and mesenteric vessels by means of a 3 mm hook or the 5mm bipolar sealer .Green dye was injected into the gallbladder to help identifying the retropancreatic portion of the bile duct which was left behind. Visualization was very clear and the multiple small vessels between the duodenum and pancreas were coagulated easily using the hook electrode or bipolar sealer without bleeding. An aggressive dissection of the duodenum and bile duct was necessary for radical resection.

RESULTS: Operative time was 176 minutes .The patient restarted feeding 30 hs after the procedure. The patient is receiving medication to treat postoperative hypoinsulinism.

V018 LAPAROSCOPIC RADICAL HYSTERECTOMY AND BILATERAL PELVIC Lymphadenectomy IN A 14 YEARS OLD GIRL WITH A UTERINE

*Maria M Bailez MD, Leopoldo Videla Rivero MD, Beatriz Videla Rivero MD, Aixa Reusmann MD, Natalia Tamburri MD, *Pediatric Surgery Garrahan Hospital and ** Gynecology Callao Surgical Institute, Buenos Aires*

Several groups have demonstrated that laparoscopic gynecological oncologic procedures can be performed safely .Some guidelines need to be followed so that the surgical results are as radical as the ones achieved by laparotomy.

AIM: Present the technical details of an unusual procedure in pediatrics.

CASE: A 14 years old girl presented with anemia and hypermenorrhea. She had fever, vaginal discharge and weight loss in the last 5 months. She was not sexually active .The level of hemoglobin was 5, 8 g /dl . Ultrasonography and MRI showed a heterogeneous mass in the back lower uterus. Simultaneous vaginoscopy and laparoscopy showed a friable tumor in the vagina coming from the cervix of the uterus . with a normal looking outside uterine surface and abdominal cavity .Histology confirmed a serous adenocarcinoma of the cervix. A radical hysterectomy and lymphadenectomy was indicated

SURGICAL TECHNIQUE: Classical gynecological laparoscopic position with intrauterine manipulator was used. Four trocars were used according to Wattiez technique : one umbilical 10mm , one high suprapubic 5mm for the surgeon's right hand and two 5mm in the lateral lower abdomen (the left for the surgeon's left hand and the right for the assistant). The perineal assistant was required to apply a strong pressure on the uterine manipulator to safely identify the uterine vessels. Vessels were coagulated using bipolar forceps. The infundibulopelvic vessels and ligaments were coagulated and sectioned .The ureters were followed and dissected. Isolation and coagulation of the uterine artery at the origin from the external iliac artery by the use of bipolar forceps .The anterior broad ligament was opened downward and toward the bladder .The bladder pillars were coagulated and cut completely freeing the bladder from the uterus . Colpotomy with vaginal resection of the bulky cervical tumor followed. Different steps of bilateral iliac lymphadenectomy included : Identification of the bifurcation of the common iliac artery and the proximal end of the obturator nerve. Histology showed a cervical tumor of 3 X 2, 6 cm with compromise of the anterior vaginal cuff. The resection margin was 0, 4 cm .Nodes and parametrios were negative .Estadification was pT2a N0 Mx (IIA)

RESULTS: Operative time was 160 minutes . There were no intraoperative complications. The patient presented a transient neurogenic bladder treated with intermittent catheterization and medication.

V019 LAPAROSCOPIC REVISION OF AN OPEN PYLOROMYOTOMY

Michael V Tirabassi MD, Michael Morowitz MD, Carroll M Harmon MD, Douglas C Barnhart MD, University of Alabama

This video is the case of a 3 month old boy referred to us approximately one month after receiving an open, transumbilical pyloromyotomy for hypertrophic pyloric stenosis. Since his procedure he has failed to thrive, still vomiting with nearly every feed. An Upper GI series was consistent with a gastric outlet obstruction. Before considering a revision of his pyloromyotomy an ultrasound was performed to confirm his original diagnosis of hypertrophic pyloric stenosis. We elected to proceed with a revision of his pyloromyotomy laparoscopically. Notably during the procedure his pylorus was softer and more difficult to split than usual. This may have been due to the previous

attempted pyloromyotomy, or this may have contributed to the failure of the prior pyloromyotomy. We did consider revising this boy's pyloromyotomy via an open technique, either via the umbilicus or a right upper quadrant incision. We were concerned that delivering the pylorus via the umbilicus would be difficult, limiting the exposure to the pylorus, and increasing the chances of the revision failing. A right upper quadrant incision would have easily given the exposure necessary to complete the revision procedure safely. However, we were reluctant to use this approach. We felt the laparoscopic approach was better for this revision for two reasons. First, we felt the cosmetic appearance of a second open incision would be undesirable. Secondly, we felt that the magnification of the laparoscope would be beneficial. On post-operative day number one our patient was tolerating goal feeds and at three week follow-up he was doing well, gaining weight, and had no further complications from pyloric stenosis. As we have learned from recurrent reflux disease after Nissen fundoplication, having a previous open procedure does not preclude the patient from having a revision done laparoscopically.

V020 THORACOSCOPIC TREATMENT OF A NEONATAL TRAUMATIC PNEUMATOCELE

Carl-Christian Jackson MD, M Bettolli MD, C De Carli MD, S rubin MD, Brian Sweeney MD, Children's Hospital of Eastern Ontario

BACKGROUND: Traumatic pneumatoceles (TP) may rarely appear after pulmonary parenchymal or bronchial disruption. Treatment is usually expectant. Surgical intervention is reserved for complications, such as infection, expansion or respiratory deterioration. A 30-week EGA female was transferred to our NICU with severe hydrops fetalis, respiratory failure, and associated chylothoraces. Emergent bilateral tube thoracostomy was performed, complicated by intraparenchymal placement of the left chest tube. The baby had persistent respiratory compromise. Chest x-ray evaluation suggested an expanding left-sided TP. CT scanning provided confirmation. Radiologically guided attempts at drainage were unsuccessful. We describe the thoracoscopic management of this case.

MATERIALS AND METHODS: Thoracoscopy was chosen to provide initial evaluation and possible definitive treatment. A two-trocar technique using 3.5 mm ports and a 3 mm 30° thoracoscope was used. After dissection fully defined the TP, it was unroofed using cautery scissors. A chest tube was placed.

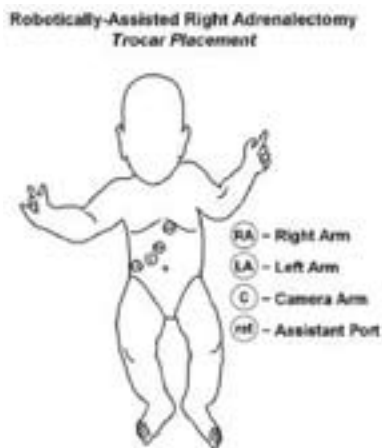
RESULTS: The patient made an uncomplicated recovery and was extubated 12 hours post operatively. There was no evidence of an air leak and the chest tube was removed after 72 hours. Follow-up chest x-rays showed full resolution of the pneumatocele. The patient remains without evidence of recurrence at 3 months.

CONCLUSIONS: Thoracoscopy allows the safe and simple treatment of a symptomatic TP. To our knowledge, this is the first description of this mode of treatment of TP. This technique should prove equally useful in the more common setting of symptomatic postpneumonic

V021 ROBOTICALLY-ASSISTED RIGHT ADRENALECTOMY IN A 7 MONTH-OLD CHILD,

Michael S Irish MD, Go Miyano MD, Thom E Lobe MD, Blank Children's Hospital

An incidentally noted, 2 cm, calcified, abdominal mass was noted in a healthy, 7 month-old male on abdominal x-ray. CT imaging was obtained which indicated the lesion was within or replaced the right adrenal gland. Metanephrines were normal. The mass was resected using the Da Vinci Surgical System. Ports were placed as illustrated. A 5 mm laparoscopic Kittner, held by a Thompson retractor, was used to provide liver retraction. There were no complications and the patient left the hospital on the 1st postoperative day. The microscopic diagnosis was that of a calcified, cystic, degenerated adrenal gland with no evidence of neuroblastoma.



V022 LAPAROSCOPIC TREATMENT OF DUODENAL HEMATOMA

B. Banieghbal MD, University of Witwatersrand, Johannesburg

INTRODUCTION: Duodenal hematoma is a rare presentation in blunt abdominal trauma, accounting for less than 2% of cases in large series. Conservative treatment normally results in the resolution of the symptoms in majority of cases, but this may take as long as 30 days. Surgical drainage is occasionally needed (less than 10% of patients) in recent publications. To our knowledge, laparoscopic drainage has not been described for this condition. We would like to present a video of this procedure.

MATERIAL: An 11-year-old boy was admitted to hospital 4 days post-blunt abdominal trauma. He had a tender upper abdomen, CT scan and a Ba-meal confirmed a duodenal hematoma and contused pancreatic head. He remained symptomatic after one week of conservative treatment and following lengthy discussion with his parents, laparoscopic drainage of his duodenal hematoma was undertaken.

PROCEDURE: 12mmHg pneumo-peritoneum was established and a 4-port approach was used. The ports were inserted in the same approximate position as that for laparoscopic cholecystectomy. Inflammatory mass, consisting of the omentum, hepatic flexure of the colon and gall-bladder was disentangled. Full visualization of the second part of the duodenum was thus achieved. A hook diathermy was used to incise the duodenal wall, followed by suction evacuation of the hematoma. For added safety, a small omental patch was sutured over the serosal defect. The patient was commenced on light diet the next day and was discharged 48 hours post-operatively. He has remained asymptomatic at his 3 months' follow-up.

CONCLUSION: Surgical drainage for duodenal hematoma is seldom required, but if it is deemed necessary the ideal method is the laparoscopic approach.

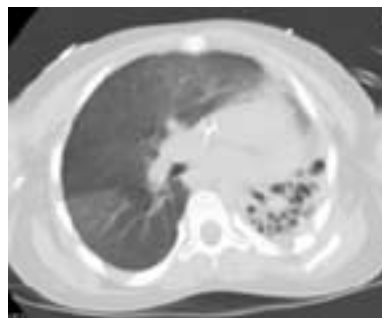
V023 THORACOSCOPIC PNEUMONECTOMY FOR SEVERE BRONCHIECTASIS IN A 9 YEAR OLD FEMALE

Dean M Anselmo MD, Donald B Shaul MD, Childrens Hospital Los Angeles, Keck-USC School of Medicine

INTRODUCTION: Thoracoscopic total pneumonectomy has not been previously described in the pediatric surgical literature. The authors describe a case of pneumonectomy performed via minimally invasive approach in a 9-year-old female with Down's syndrome and GERD.

CASE REPORT: The patient suffered from multiple recurrent aspiration pneumonias, which progressed to bronchiectasis of the entire left lung (Figure). As a result, the patient was hypoxemic and required continuous supplemental oxygen. Preoperative perfusion scans showed diminished perfusion of the left lung. Thoracoscopy was performed using 3- 5mm trocars and one 11mm trocar. Insufflation pressure was maintained at 5 mmHg. Dissection was performed at the hilum using hook electrocautery and Ligasure device (ValleyLab, Boulder, CO). The pulmonary artery, veins and left mainstem bronchus were sequentially divided using a 35 mm endo-GIA vascular stapler (Ethicon Endo-Surgery, Cincinnati, OH). There were no intraoperative complications and her oxygen requirement is significantly decreased postoperatively.

CONCLUSION: Thoracoscopic pneumonectomy is a safe and technically feasible approach for severe bronchiectasis in children.



V024 RETROPERITONEAL PYELOPLASTY FOR URETEROPELVIC JUNCTION (UPJ) OBSTRUCTION: SOME TO SOLVE THE TECHNICAL DIFFICULTIES

J.S. Valla, MD, Hopital Lenval

THE goal of minimal access repair is similar to that of open pyeloplasty which is to create a wide, tension-free, watertight anastomosis. In this video, our retroperitoneoscopic approach in lateral position is explained step by step.

3 trocars are inserted ; the kidney is approached posteriorly ; the UPJ is freed with minimal dissection. A 5/0 stay suture is placed at the level of the UPJ and anchored to the psoas muscle for presentation and stabilisation (extracorporeal slipping knot). The redundant renal pelvis is then partially incised, leaving the external part tied to the stay-suture ; in a same way the ureter is opened and spatulated leaving its proximal stenotic part attached to the stay suture. For the next most challenging step, the ureteropelvic anastomosis, the crucial point is to get a stable image : a camera holder is needed. The anterior part of the ureteropelvic anastomosis is performed using 5 or 6 zero absorbable running suture (intracorporeal knot). If needed a double J-stent is inserted at that time through the upper port : the entry of the stent into the bladder is confirmed by the backflow of urine from the bladder which is filled with methylene blue. Then the posterior part of the anastomosis is completed using also running suture ; the UPJ is completely excised and the stay suture is removed. The last step is to close the pelvis.

In conclusion this technique has been used in more than 50 patients -4 months to 18 years old- with the same results than with open surgery.

V025 ROBOTIC RESECTION OF A PROSTATIC UTRICLE

John J Meehan MD, Louis Kantzavelos MD, Chris Austin MD, Children's Hospital of Iowa

Resection of a prostatic utricle can be very difficult due to the problems accessing this area for both the open and laparoscopic abdominal approach. The posterior sagittal approach has also been accomplished but can leave the patient with a significant wound issue. However, robotic surgery may allow easier access to this difficult territory. We present a robotic resection of a prostatic utricle in a 15 month old child with ambiguous genitalia. The procedure was accomplished using a 12 mm 3 dimensional camera, two 5 mm robot instrument ports, and one 5 mm accessory port. The patient tolerated the procedure well, had no complications, and was discharged home on post-operative day #1. Due to the difficulties in the approach to the prostatic utricle, the articulating instruments of robotic surgery technology allow much easier access than traditional rigid laparoscopic instruments.

V026 LAPAROSCOPIC IPSILATERAL URETERO-URETEROSTOMY IN INFANTS AND CHILDREN FOR DUPLICATION ANOMALIES OF THE URINARY TRACT

Amos Neheman MD, Lisandro Piaggio MD, Paul h Noh MD, Ricardo Gonzalez, A. I duPont Hospital for Children

PURPOSE: To report our experience with laparoscopic ipsilateral uretero-ureterostomy (LIUU) for duplication anomalies of the urinary tract in infants and children and the short term results in eight patients.

METHODS: LIUU was performed transperitoneally with 3 to 4 ports for unilateral and bilateral cases respectively. Cystoscopy, retrograde pyelogram and stent placement in the recipient ureter was performed at the beginning of the case. The anastomosis was carried out with running or interrupted 5-0 or 6-0 absorbable sutures. An abdominal drain and Foley catheter were left indwelling in all cases. Demographic data, body measurements, type of procedure and indication, laterality, intra and postoperative complications, analgesia requirement, length of hospitalization and outcome were recorded.

RESULTS: There were 9 LIUU in 7 patients (2 males and 5 females). Mean age was 50 months (range 1.3-190). Diagnosis was bilateral lower pole vesicoureteral reflux in 2 cases and ectopic ureter in 7 cases. Mean operative time including cystoscopy was 257 minutes (range 140-430) and estimated blood loss 3 ml. There were no intraoperative complications. Mean morphine requirement was 0.13 mg/kg. Two patients needed acetaminophen only for pain management. All patients were discharged with no narcotics at median of 3 days (range 1-7). There were 2 postoperative febrile urinary tract infections. Follow up renal ultrasound demonstrated no significant hydronephrosis of the moieties involved.

CONCLUSIONS: In this initial experience LIUU was done safely and effectively even in the small infants. Postoperative course was uneventful with negligible blood loss and minimal analgesia requirement with initial results comparable to those of open surgery

V027 FETOSCOPIC SEPARATION OF CONJOINED TWINS

Foong-Yen Lim MD, Timothy M Crombleholme MD, Jeffrey C Livingston MD, Fetal Care Center of Cincinnati, Cincinnati Children's Hospital Medical Center and University of Cincinnati

We present a case in which a set of conjoined twins were separated in-utero fetoscopically. At 20 weeks gestation a 38-year-old primigravida was diagnosed with monochorionic diamniotic twins. The umbilical cord was conjoined as was the ileum running through the cord. These were associated with an allantoic cyst. The cyst was quite large splaying and compressing the umbilical vessels resulting in abnormal doppler velocimetry. One twin had limb-body wall complex manifested as severe scoliosis, limb abnormalities and a double-outlet right ventricle. The co-twin had a persistent cloaca and a patent urachus. Meconium refluxed from the cloaca through the patent urachus into the allantoic cyst. After extensive counseling, the mother elected to proceed with fetoscopic separation of the twins as in-utero demise of the baby with limb-body wall complex was anticipated and would have a high risk of taking the co-twin with it. The procedure was performed under epidural anesthesia. Ultrasound was used to confirm the position of each twin and to identify the inter-twin membrane. 2 spots were selected for placement of a fetoscope and an operating port sonographically. The fetoscope was inserted into the amniotic cavity of the twin with limb-body wall complex. An anomalous umbilical cord was seen. Vessels and bowel were evidence through the Wharton's jelly. We inserted a 3-mm port under ultrasound guidance. A bipolar grasper was used to test-clamp the cord at the abdominal cord insertion site. This resulted in immediate bradycardia in the fetus with limb-body wall complex but did not affect the co-twin. There appeared to be terminal bradycardia in the fetus with limb-body wall complex. We were concerned that releasing the clamping would result in hemorrhage into this fetus, potentially placing the co-twin at risk. Thus, we proceeded with cord coagulation, first with 60 watts of power then 80 and 100 watts sequentially. These were repeated 3 times to ensure complete obliteration of the umbilical vessels. A grasping forceps was used to place a #0-silk suture around the cord to place a ligature around the ileum and the vessels but the tissues were too tenuous to allow cinching of the knot without cutting through. Thus, additional coagulation was performed and the bowel separated. We then performed a cystotomy in the allantoic cyst and decompressed the cyst completely, restoring doppler velocimetry in the umbilical vessels to normal. We reduced amniotic fluid volume to normal. Antibiotics were instilled before removal of the fetoscope and the 3-mm port.

V028 LAPAROSCOPIC CONTINENT APPENDICOCCESTOMY INTO A CONCEALED STOMA: OPTIMIZING COSMESIS AND CONTINENCE

Amos Neheman MD, Lisandro Piaggio MD, T Ernesto Figueroa MD, Ricardo Gonzalez, A. I duPont hospital for children

POSTER ABSTRACTS LISTINGS

Distinguished Posters:

Poster Group A - Top 40 Rated Posters

GASTROINTESTINAL & HEPATOBILIARY

- P001 Doi, Takashi** "A New Technique for Preventing Wrap Disruption/Migration After Laparoscopic Nissen Fundoplication: An Experimental Study"
- P002 Lopez, Manuel** "Laparoscopic Treatment in Children with Disorders of Greater Omentum"
- P003 Czauderna, Piotr** "Video-Assisted Repair of Duodenal Duplication in an Infant - Case Report"
- P004 Gunnarsdóttir, Anna** "Wireless Oesophageal Ph Measurement in Children"
- P005 De Carli, Claudio** "Laparoscopic-Assisted Colostomy in Children"
- P006 Keshen, Tamir** "Laparoscopic Nissen Fundoplication is Technically Feasible in Neonates with Recent Gastroschisis Repair"
- P007 Sesia (Kubiak), Sergio (Rainer)** "Laparoscopic Single-Port Technique for Appendectomy in Children"
- P008 Elmo, Gastón** "Laparoscopic Treatment of Congenital Duodenal Obstructive Disease"
- P009 Flores, Paula** "Comparative Analysis Between Open (UCO) and Laparoscopic (UCL) Treatment of Ulcerative Colitis (Uc) in Pediatric Patients: Single Centre Experience"
- P010 Lee, Shin-yi** "One Trocar Laparoscopic Appendectomy In Children"
- P011 Zitsman, Jeffrey** "The Pace of Weight Loss in Adolescent Laparoscopic Gastric Banding: Short-Term Results"
- P012 Whyte, Christine** "Outpatient Laparoscopic Interval Appendectomy for Perforated Appendicitis"
- P013 Zhang, Jun** "Laparoscopic Roux-en-y Pancreaticoenterostomy for Congenital Pancreatic Ductal Dilatation in Children"
- P014 Bouhadiba, Nordeen** "Meta-Analysis of Laparoscopic Versus Circumbilical Pyloromyotomy."

MISCELLANEOUS

- P015 Garcia Hernandez, Carlos** "Laparoscopic Approach of the Inguinal Pathologies in Children"
- P016 Hassan, Mohamed** "New Laparoscopic Flip Flap Technique Versus Conventional Inguinal Hernia Repair in Children. Is it Worth it?"
- P017 Proklova, Lyudmila** "Recurrences After Laparoscopic Inguinal Hernia Repair as Related to Type of Closure of the Patent Processus Vaginalis."
- P018 Banieghbal, B** "Laparoscopic Surgery and Aids"
- P019 Diefenbach, Karen** "Advances In Pediatric Surgery Resident MIS Experience"

ROBOTICS & EMERGING TECHNOLOGY

- P020 Ohya, Toshiki** "A New Laparoscopic Instrument with a Concept of Intra-Peritoneal Assembly"
- P021 Antao, Brice** "The Economics of Robotic Surgery in Children"
- P022 Sinha, Chandrasen** "Robotic Assisted Surgery in Children"

THORAX

- P023 Steiner, Zvi** "Do Children Tolerate Thoracoscopic Sympathectomy Better Than Adults?"
- P024 Correia-pinto, Jorge** "Transvesical Thoracoscopy: A Natural Orifices Transluminal Endoscopic Approach for the Thorax"
- P025 Guelfand, Miguel** "Minimally Invasive Diaphragmatic Approach. The New Gold Standard"
- P026 Bradnock, Timothy** "Thoracoscopic Lobectomy for Symptomatic CCAM in a Five Month Old Infant: A Cautionary Tale from the Pathologist."
- P027 Peiró, Jose** "Parapneumonic Empyema in Children: Comparative Study of Clinical Evolution According to the Initial Treatment (Vats Versus Urokinase)."

UROLOGY

- P028 Varlet, François** "Enlarged Nephrectomy by Laparoscopy for Renal Tumors in Children: Initial Experience."
- P029 Neheman, Amos** "100 Cases of Transperitoneal Laparoscopic Renal Surgery in Infants and Children Without Conversions or Transfusion"
- P030 Wu, Rongde** "Gross Pathology Classification of Duplex Kidney and Laparoscopy Management"
- P031 Szavay, Philipp** "Laparoscopic Pyeloplasty in Children Below One Year of Age"
- P032 Turial, Salmai** "Testicular Perfusion and Growth After Laparoscopic Inguinal Hernia Repair in Children"
- P033 Hakguder, Gulce** "Evaluation and Guidance of Endoscopic Treatment of Vesicoureteral Reflux with Peroperative Direct Cystography"
- P034 Takehara, Hiroo** "The New Surgical Concept for Hydrocele of the Cord or Scrotum in Children: Based on Experience of 701 LPECS"
- P035 Cisek, Lars** "Stenting is Unnecessary in Laparoscopic Pyeloplasty."
- P036 Cisek, Lars** "Prone Retroperitoneoscopic Heminephrectomy"

Posters Displays: Poster Group B

GASTROINTESTINAL & HEPATOBILIARY

- P041 Chahine, A. Alfred** "Laparoscopic Retrieval of Post-appendectomy Retained Fecalith in the Pediatric Population"
- P042 Dasgupta, Roshni** "Combined Laparoscopic and Interventional Radiologic Approach to Abdominal Lymphatic Malformations"
- P043 Vejdan, Amir** "Laparoscopic Evaluation for Bilateral Hernia in Children"
- P044 Haricharan, Ramanath** "Risk Factors for Bilaterality of Inguinal Hernia in Children and the Effect of Choice of Laparoscopic Technique on Bilateral Repair"
- P045 Berchi Garcia, Francisco José** "Laparoscopic Surgery for Choledochal Cysts in Children"
- P046 Carmona-barba, Rene** "Laparoscopic Management of Duodenal Obstruction in Newborn, Experience in 6 Cases and Their Outcome."
- P047 Lazarus, C** "Laparoscopically Inserted Button Colostomy as a Venting Stoma and Access Port for the Administration of Antegrade Enemas in African Degenerative Leiomyopathy."
- P048 Kleiner, O** "Prior U-Stitch Gastrostomy Does Not Complicate Subsequent Laparoscopic Fundoplication in Pediatric Patients"
- P049 Mueller, Claudia** "Wound Infection After Pediatric Laparoscopic Appendectomy is Unrelated to Method of Specimen Retrieval"
- P050 Chiarenza, S.f.chiarenza** "Modified Laparoscopic Hill Gastropepy in the Treatment of Gerd in Pediatric Age Preliminary Report"
- P051 Numanoglu, A** "Laparoscopic Assisted Endo-Anal Pull-Through for Hirschsprungs Disease"
- P052 Reinberg, Olivier** "Combined Endoscopic and Laparoscopic Procedures in Children."
- P053 Ross, William** "Cardiomyotomy Modification of Heller-Dor Procedure for Pediatric Achalasia"
- P054 Grewal, Harsh** "Teaching Pediatric Laparoscopic Pyloromyotomy in the Skills Lab: A Feline Box Trainer Model"
- P055 Samarakkody, Udaya** "The Laparoscopic Abdominal Procedures Have a Better Quality of Recovery Than Open Procedures."
- P056 Chokshi, Nikunj** "Laparoscopic Choledochal Cyst Resection; Preliminary Experience"
- P057 Shariff, Faiz** "Postcholecystectomy Syndrome After Lapchole in Children"
- P058 Yagmurlu, Aydin** "Laparoscopic Total Colectomy in Children"

P059 Tokar, Baran "Is it Right to Place Ultrasound-Base Decision Making at The Forefront of the Evaluation of Suspected Appendicitis?"

P060 Antao, B "Safety, Diagnostic Yield and Therapeutic Potential of Double Balloon Enteroscopy in the Small Bowel in Children"

P061 Weinberg, Mark "Laparoscopically Assisted Peritoneal Shunt Insertion in Children with Hydrocephalus"

P062 Hakguder, Gulce "Single Port Laparoscop_c Appendectomy Conducted Solely Intracorporeally with the Aid of a Transabdominal Sling Suture: Results of the New Technique"

P063 Saxena, Amulya "Diagnostic Criteria for Bile Stones in Children Undergoing Laparoscopic Surgery"

P064 Nachulewicz, Pawel "Laparoscopic Hemisplenectomy Using Radiofrequency Monopolar Coagulation Device."

P065 Rachkov, Victor "Surgical Treatment of Gastro-esophageal Reflux in Children."

MISCELLANEOUS

P066 Omotosho, Philip "Laparoscopic Management of Infantile Cushing's Syndrome"

P067 Henriques, João "Midgut Volvulus After Laparoscopic Appendectomy"

P068 Riquelme, Mario "Laparoscopic Diagnosis and Treatment of a Double Uterus with a Vaginal Septum"

P069 Weiss, Richard "Laparoscopic Management of a Recurrent Pheochromocytoma in a Patient with Von Hippel Lindau Syndrome"

P070 Omotosho, Philip "Laparoscopic Resection of an Obturator Nerve Schwannoma"

P071 Proklova, Lyudmila "Ultrasound-Guided Interventions in Pediatric Surgery: Experience in 136 Patients."

P072 Brocklebank, Lyn "Nursing Attitudes Towards Minimal Access Surgery"

P073 Guelfand, Miguel "Laparoscopic Gastric Banding in Adolescence Obese Patients: An Extra Help"

P074 Slater, Bethany "Institutional Experience with Laparoscopic Partial Splenectomy for Hereditary Spherocytosis."

P075 Haricharan, Ramanath "Laparoscopic Management of Ovarian Torsion in Girls is Straightforward and May Improve Chances of Ovarian Salvage"

P076 Yagmurlu, Aydin "A Less Invasive Alternative to Open Biopsies: Laparoscopic Biopsy"

P077 Stormer, Emma "A Review of Laparoscopic Training in Paediatric Surgery in the UK"

P078 Mackinlay, Gordon "The Role of Laparoscopy in the Excision of Paediatric Solid Tumours"

Posters Displays: Poster Group C

MISCELLANEOUS

P078 Mackinlay, Gordon "The Role Of Laparoscopy In The Excision Of Paediatric Solid Tumours"

P079 Guvenc, Haluk "Minimal Invasive Surgical Approach In The Management Of Pediatric Hydatid Disease"

P080 Guvenc, Haluk "Minimal Invasive Approach In Infant And Childhood Ovarian Pathologies"

P081 Bingol Kologlu, Meltem "Laparoscopic Management Of Adnexal Pathology In Children: A Gold Standart"

MY FAVORITE TRICKS

P082 Phillips, J. "Evolution Of The Surgical Management Of Neonatal Ovarian Cysts: Laparoscopic-assisted Trans-umbilical Extra-corporeal Ovarian Cystectomy (Latec)"

P083 Guelfand, Miguel "Is Primary Anastomosis A Valid Option In Newborn <1500 G With Necrotizing Enterocolitis? - A Prospective Study."

ROBOTICS & EMERGING TECHNOLOGY

P084 Antao, B "In Vivo Real Time Colonoscopic Endotherapy Targeted By Confocal Endomicroscopy In Colonic Heterotopia"

THORAX

P085 Kravarusic, Dragan "Minimal Access Surgery As Primary Approach For Repair Of The Late Presenting Congenital Diaphragmatic Hernias -two Centers Data-"

P086 Gamba, Piergiorgio "Thoracoscopic Lung Biopsy And Wedge Resection In Compromised Pediatric Patients"

P087 Moldes, Juan "Spontaneous Pneumothorax In The Thoracoscopic Era"

P088 Mackinlay, Gordon "Minimal Access Surgery In Paediatric Thoracic Pathology – A 5 Year Review"

P089 Saxena, Amulya "Efficacy Of Right Thoracoscopy In Minimal Invasive Repair Of Pectus Excavatum"

P090 Johnson, Sidney "Thoracoscopic Ligation Of The Thoracic Duct For Congenital Chylothorax"

P091 Garza, Jennifer "Laparoscopic Subxiphoid Pericardial Exploration"

UROLOGY

P092 Britos, W "Laparsocopic Treatment For Intra Abdominal Testis"

P093 Surer, Ilhami "Endoscopic Intraureteric Positive Charged Dextranomer Sephadex Copolymer Injection To Treat High Grade Vur In Ectopic Ureters"

P094 Surer, Ilhami "The Endoscopic Treatment Of High Grade Vur: Single Surgeon's Experience"

P095 Banu, Tahmina "Cystoscopic Removal Of Leeches"

P096 Lintula, Hannu "Laparoscopic Versus Open Orchidopexy In Children With Intraabdominal Testes"

P097 Lopez, Manuel "Laparoscopy Nephrectomy For Wilms Tumors"

P098 Grewal, Harsh "The Role Of Laparoscopy In Managing The Pediatric Patient With Non-palpable Testes"

P099 López, Pedro "Urethral Diverticulum After Laparoscopic-assisted Anorectal Pullthrough (Laarp) For Anorectal Malformation: Is It Always Necessary To Resect The Diverticulum?"

P100 López, Pedro "Endoscopic Treatment With Deflux For Primary Vesicoureteral Reflux: Same Success Rate In Single And Duplex Systems?"

P101 López, Pedro "Laparoscopic Renal Surgery In Pediatrics: Technical Options And Tips For The Surgeon In The Beginning Of The Learning Curve"

P102 López*, Pedro "Is The Laparoscopic Approach For Impalpable Testis Still The Gold Standard?"

P103 Moldes, Juan "Retroperitoneal Pyeloplasty In Children. The New Gold Standard"

P104 Yagmurlu, Aydin "Laparoscopic Sigmoid Vaginoplasty"

P105 Metzelder, Martin "Laparoscopic Ureterocutaneostomy For Urinary Diversion Is A Feasible Option In Infants"

P106 Khelif, Karim "Splenogonadal Fusion: Case Report"

P107 Gohary, Amin "Laparoscopic 2 Stages Fowler Stephen Procedure For High Abdominal Testes"

P108 Cherian, Abraham "Laparoscopic Peritoneal Dialysis Catheter Placement In Children With Previous Intra-abdominal Problems"

P109 Losin, Marcín "Laparoscopic Adrenalectomy In Children- 2 Centres Experience"

P110 Piaggio, Lisandro "Laparoscopic Colocystoplasty: The Ideal Surgery For The Selected Patient"

P111 Piaggio, Lisandro "Kidney Duplication Presenting As A Pseudotumor: Laparoscopic Diagnosis And Treatment"

P112 Piaggio, Lisandro "Laparoscopic Transureteroureterostomy. A Novel Approach"

P113 Cisek, Lars "Laparoscopic Urachal Excision"

P114 Piaggio, Lisandro "The Minimally Invasive Surgery For The Minimal Patient With Renal Duplication"

THORAX

P115 Bouhadiba, Nordeen "Laparoscopic Excision Of Abdominosrotal Hydrocel. The First Serie"

POSTER ABSTRACTS

P001 A NEW TECHNIQUE FOR PREVENTING WRAP DISRUPTION/MIGRATION AFTER LAPAROSCOPIC NISSEN FUNDOPPLICATION: AN EXPERIMENTAL STUDY

Takashi Doi PhD, Satoko Ichikawa MD, Go Miyano PhD, Atsuyuki Yamataka PhD, Department of Pediatric Surgery, Juntendo University School of Medicine

AIM: Laparoscopic Nissen fundoplication (lap-Nissen) is associated with a wrap disruption/migration rate of 3 to 40%. At reoperation, there is usually a lack of adhesions between the esophagus and the wrap. We report a new technique to overcome this complication.

METHODS: Eighteen pigs weighing 12-24kg underwent lap-Nissen and were divided into 3 groups (n=6 each). In group-A, sandpaper was used to accelerate adhesion formation between the wrap and the esophagus by scraping the serosae of the right and left gastric fundi. In group-B, fibrin glue was injected between the esophagus and the wrap. In group-C, a conventional lap-Nissen was performed. All pigs were sacrificed 3 months later, and en bloc specimens consisting of the lower esophagus, fundic wrap, and diaphragmatic crura were examined macroscopically and microscopically for evidence of adhesions. Azan-Mallory staining was used to see the collagen fibers.

RESULTS: There was no wrap disruption/migration in any pig. In group-A, there were dense adhesions visible macroscopically between the esophagus and the right and left fundi, and the wrap was adhered tightly to the crura. Microscopically, there were many collagen fibers between the esophagus and the wrap present. In groups-B and -C, macroscopic adhesions were absent or minimal between the esophagus and the wrap, and the wrap was less adhered to either crura, compared with group-A. Histologically, the esophagus and both fundi were distinct with no fibers present between them.

CONCLUSION: Our technique is likely to prevent wrap disruption/migration after lap-Nissen.

P002 LAPAROSCOPIC TREATMENT IN CHILDREN WITH DISORDERS OF GREATER OMENTUM

M. Lopez MD, E. Guye MD, M. Pezet MD, H. Steyaert MD, J. Bréaud MD, G. Podevin MD, P. Buisson MD, L. Sapin MD, J.L. Michel MD, M. Demarche MD, F. Varlet PhD, Department of Pediatric Surgery, Nord Hospital, University of Saint Etienne, and GECI French group of endosurgery Pediatric. France.

OBJECTIVE: The pathologies of the greater omentum are an uncommon cause of acute abdomen in childhood. They are found in only 0.07 % of children operated for acute abdominal pain. Ultrasound and CT-scan sometimes allow the diagnosis before surgery, but it is often done during operation. The laparoscopy is able to treat the omental pathologies and we report our experience.

METHODS: A retrospective multicentric study was performed from January 2002 to January 2007 in the GECI (French Pediatric Laparoscopic Group) about the different pathologies of the greater omentum treated by laparoscopy. Seven centers sent us their cases with age, weight, size, body mass index, clinical history, radiological exams, operative report and follow-up.

RESULTS: 17 children with an omental pathology were operated by a laparoscopic approach. The mean age was 6.5 years. The abdominal symptoms were non specific: abdominal pain mimicking cholecystitis and appendicitis, and sometimes abdominal mass. A preoperative diagnosis was made in 10 cases and the pathologies were divided in two categories: 10 ?ischemic? cases (segmental infarction and torsion) and 7 cases of benign tumours. In cases of idiopathic segmental infarction and torsion, the average age was 9 years and the preoperative diagnosis was acute appendicitis in 7 cases. We found an obesity in 4 cases and 1 post-traumatic infarction of the greater omentum. In these ?ischemic? cases, the ultrasound contributed to diagnosis only in 25% of cases. In all children the pathological area were removed easily by laparoscopy. For the omental benign tumours, the average age was 2.5 years and the preoperative diagnosis was done in all cases; but the topographic diagnosis was never correct. All were removed by laparoscopy and only one conversion was necessary due to a large solid tumour; for the large cystic lesions, a puncture was performed. The postoperative diagnosis was 5 cystic lymphangiomas, 1 lipoblastoma and 1 undetermined tumour (necrosis).

CONCLUSION: Under 4 years-old, the lesions of the greater omentum are the most frequent tumours, especially cystic lymphangiomas. Over 4 years-old, it is usually omental torsion or segmental infarction, and mostly in obese

patients. For the omental ?ischemic? pathologies, a conservative treatment or a laparoscopy can be proposed. For the tumoral lesions, a laparoscopic resection can be performed after puncture in case of cystic lesion; a conversion is necessary in case of a large solid tumor.

P003 VIDEO-ASSISTED REPAIR OF DUODENAL DUPLICATION IN AN INFANT - CASE REPORT

Piotr Czauderna PhD, Andrzej Golebiewski MD, Maciej Murawski MD, Department of Surgery and Urology for Children and Adolescents, Medical University of Gdansk, Poland, Department of Pediatric Surgery and Urology, Medical University of Wroclaw, Poland, Department of Pediatric Surgery, Silesian Medical University, Pol

Duodenal duplications are rare congenital anomalies. The case of a 3-month-old baby with duodenal duplication treated in a video-assisted manner is presented. The child was diagnosed after birth with abdominal infrahepatic cyst by US and CT measuring 5cm of diameter. Choledchal cyst was suspected. Laparoscopy revealed duodenal duplication which after dissection required conversion to minilaparotomy due common muscular wall with duodenum. Both structures were dissected under direct vision and the cyst was removed completely. The child was discharged in the 8th postop. day and remains well.

There few reports on laparoscopic treatment of intestinal duplications. Video-assisted approach offers new possibilities in the treatment of duodenal duplications allowing for better cosmesis and more adequate planning of surgical treatment.

P004 WIRELESS OESOPHAGEAL PH MEASUREMENT IN CHILDREN

Anna Gunnarsdóttir MD, Pernilla Stenström MD, Einar Arnbjörnsson PhD, Department of Paediatric Surgery, Lund University Hospital, 221 85 Lund, Sweden

BACKGROUND: pH measurements are important in the diagnosis of gastro-esophageal reflux disease in children. A minimally invasive catheter free measurements with BRAVO? capsule are supposed to be less discomforting and allow less restrained activity during the measurement compared to the usual one with naso-oesophageal catheter. This has though, not been widely studied in children. This is a retrospective study, showing the results of our experience with the catheter-free pH measurements for 24 hours in children, during one year period in Lund, Sweden.

CHILDREN AND METHODS: 29 children with signs of gastro-oesophageal reflux underwent a wireless pH measurement with BRAVO? capsul during the time period of may 2005-june 2006. The median age of the children was 7,9±3,7 (range 1-14), with 20 boys and 9 girls. A diagnostic oesophageal-gastroduodenoscopy was done under general anesthesia and a transoral placement of a radio-transmitting BRAVO? capsule was placed two vertebra columns above the diaphragm. The pH value for 24 hours and symptom of discomfort if any were registered.

RESULTS: In five children the endoscopy showed esophagitis. The pH measuring time was from 18,5-24 hours. The median percent time of pH<4 was 9,2%±12,2 (range 0,2-29,4%) and the total amount of acid refluxes were 57±32 (range 6-121). DeMeester score was abnormally high in 18 children (range 17,3-93,2) and normal in 11 children (range 1,3-13,9). Three children were operated on later with laparoscopic fundoplication. Three children described signs of dysphagia during the measuring time. In two cases we experienced a failure in the contact with the TM receiver and in one case we had technical problem in fastening the capsule.

CONCLUSIONS: A wireless pH measurement in children with the BRAVO? capsule has in our hands worked well. No major complication has occurred and the children seem to tolerate the capsule without problem. We will continue to use the telemetric, wireless pH measurement in our clinic.

P005 LAPAROSCOPIC-ASSISTED COLOSTOMY IN CHILDREN

Claudio De Carli MD, M Bettolli MD, C-C Jackson MD, Brian Sweeney MD, S Rubin MD, The Children's Hospital of Eastern Ontario

BACKGROUND: Colostomy formation requires meticulous technique to minimize morbidity, which has been reported to be as high as 50% using

conventional methods. Laparoscopic-assisted colostomy (LAC) is becoming the preferred method for stoma formation in adults, but has not previously been reported in the pediatric population. We report our initial experience with LAC in children.

MATERIALS AND METHODS: Using a simple 3 (3.5mm) port technique, LAC was performed in two male patients with complicated Hirschsprung's disease and in a female with imperforate anus. Data collected included operative time; time to recover bowel function and morbidity. Duration of follow up was until the stoma was taken down.

RESULTS: The mean operative time was 135 minutes in the HD patients (including concomitant laparoscopic biopsies and a leveling colostomy) and 40 minutes in the imperforate anus patient. Mean time to passage of both flatus and stool was 40 hours (range, 24- 48 hours). Time to commence feeds post op was 40 hours (range, 24- 48 hours). Two of the stomas were closed after 2-3 months and one persists. No complications have occurred to date.

CONCLUSIONS: LAC is safe, simple and effective in children. It facilitates accurate stoma placement and orientation. It also allows easy additional bowel mobilization when indicated. Encouraged by our initial low morbidity rate, a prospective evaluation of this technique is planned.

P006 LAPAROSCOPIC NISSEN FUNDOPLICATION IS TECHNICALLY FEASIBLE IN NEONATES WITH RECENT GASTROSCHISIS REPAIR

Michael D Rollins MD, J. Brent Roaten MD, Tamir H Keshen MD, Division of Pediatric Surgery, St. Louis Children's Hospital, Washington University School of Medicine, St. Louis, MO, USA

BACKGROUND: Gastroesophageal reflux disease frequently occurs in neonates born with gastroschisis. This may contribute significantly to delayed feeding tolerance in these patients who typically suffer from ileus, intestinal dysmotility and malabsorption during the initial postoperative period. When required, antireflux operations are usually performed as an open technique in anticipation of dense adhesions. There have been no reports to date of laparoscopic Nissen fundoplication in infants with a recent gastroschisis repair. We present our initial experience with three patients using the laparoscopic approach as a feasible alternative in neonates who have undergone gastroschisis repair.

METHODS: A retrospective chart review was performed from 2002 through 2006 to examine the technical feasibility and postoperative outcomes of infants born with gastroschisis who subsequently required a laparoscopic Nissen fundoplication for severe gastroesophageal reflux disease.

RESULTS: We performed laparoscopic Nissen funduplications in three neonates who had undergone recent gastroschisis repair. Estimated gestational ages were 37, 37 and 38 weeks. Two patients were managed with an initial silo reduction followed by a primary fascial closure while the third patient had a primary closure performed at birth. Gastroesophageal reflux disease was documented radiographically by upper GI after a prolonged period of clinical reflux. Time from final abdominal wall closure to laparoscopic fundoplication was 40, 78 and 102 days. The density of intraoperative adhesions varied from minimal to severe and the operative times were 123, 133 and 182 minutes. Following laparoscopic adhesiolysis, intraoperative visualization was excellent. Simultaneous laparoscopic gastrostomy button was performed in two patients. Feedings were initiated within the first 2 days postoperatively. Full enteral support was achieved at 2 days, 8 days, and 2 months following fundoplication. No intraoperative bowel injuries occurred, one patient was treated with antibiotics for wound cellulitis postoperatively and there have been no documented disruptions of the funduplications (range 3 months to 15 months).

CONCLUSIONS: We have performed three laparoscopic Nissen funduplications in neonates who have had a recent gastroschisis repair without intraoperative complications and minimal morbidity. Our initial experience demonstrates that this technique is both a safe and feasible alternative to open fundoplication.

P007 LAPAROSCOPIC SINGLE-PORT TECHNIQUE FOR APPENDECOMY IN CHILDREN

Sergio Sesia MD, Rainer Kubiak MD, Johannes Mayr PhD, Dept. of Paediatric Surgery, University Children's Hospital Basle (UKBB), Switzerland

PURPOSE: Traditionally laparoscopic appendectomy is performed using three trocars. In contrast the single-port technique (SPT) requires only one trocar via a subumbilical access. We report our initial experience with this technique, with special emphasis to preoperative ultrasound and additional pathological findings.

METHODS: Between September 2005 and December 2006 90 children were treated by SPT at our institution. SPT was performed using one special 10-mm trocar with an integrated working canal (Auto Suture®, United States Surgical/Tyco Healthcare, OMS-T10BT, Norwalk, USA). After laparoscopic inspection of the abdominal cavity, the appendix was grasped with a 450-mm atraumatic forceps, exteriorised through the umbilical incision and dissected outside the abdomen as in open appendectomy.

RESULTS: There were 50 males and 40 females. Median age was 11.6 years (range, 2-15). All children presented with clinical signs of acute appendicitis. Preoperatively, all patients underwent an abdominal ultrasound scan which showed radiological signs of acute appendicitis (e.g. enlargement >5mm and/or hyperperfusion). Additional pathological findings were detected in 8 children (9%) (ovarian cyst formation (n=2), renal abnormalities (n=3), splenomegaly (n=3)). In 88 children (98%) the operation was carried out with one trocar. In two cases (2%) a second port was required because of severe adhesions. In two cases (2%) adhesions were freed with the forceps of the single-port instrument. There were four conversions (4%) to open surgery because of dense adhesions and/or subhepatic located phlegmonous appendicitis. Median operation time was 55 min. (range, 25-135). The patients remained in hospital for four days (range, 2-8). There were no complications. The histological report revealed appendicitis in 84 (93%) cases (9x acute, 70x ulcerous-phlegmonous and 5x perforated). In six patients (7%) a neurogenic appendicopathy was diagnosed.

CONCLUSIONS: SPT is a safe and simple technique for appendectomy in children with minimal scarring. It allows a good overview of the intra-abdominal cavity, facilitating detection and treatment of additional pathologies. SPT has limited application in cases of abnormal position of the appendix and/or dense adhesions requiring an additional trocar or conversion to open surgery. Pre operative ultrasound can ensure SPT safety as well as detecting additional pathologies.

P008 LAPAROSCOPIC TREATMENT OF CONGENITAL DUODENAL OBSTRUCTIVE DISEASE

Gastón Elmo MD, Aixa Reusmann MD, Mariano Boglione MD, Bailez M María MD, Division of Pediatric Surgery, J. P. Garrahan Hospital. Buenos Aires, Argentina

BACKGROUND: Laparoscopic correction of congenital duodenal obstructive malformations is a well known procedure.

MATERIAL AND METHODS: We present 9 patients treated by a laparoscopic approach. Four had an incomplete membrane, 4 a duodenal atresia and 1 an annular pancreas. Five were newborns, 3 were infants and 1 was a toddler. Procedures were performed using 3 ports. Three and 5 mm instruments were used depending on the size of the patient. Surgery consisted in a longitudinal duodenotomy and partial membrane resection in patients with incomplete atresia and duodeno-duodenum diamond shaped anastomosis in those with a complete atresia or annular pancreas. Either 5/0 PDS running suture or single stitches were used. Monopolar cautery or the bipolar sealer were alternatively used for the resection of membranes.

RESULTS: Mean operative time was 90 minutes including insertion of a transanastomotic tube. Duodenum exposure was excellent and there were no intraoperative complications. Enteral feeding through the transanastomotic tube started on the second postoperative day. Oral feeding began at a mean time of 8 days. Long-term follow up was uneventful with excellent functional and cosmetic results.

CONCLUSIONS: After this preliminary experience laparoscopic approach has become our first choice for the treatment of congenital duodenal obstructive disease in our division.

P009 COMPARATIVE ANALYSIS BETWEEN OPEN (UCO) AND LAPAROSCOPIC (UCL) TREATMENT OF ULCERATIVE COLITIS (UC) IN PEDIATRIC PATIENTS. SINGLE CENTRE EXPERIENCE

Paula Flores MD, Maria M Bailez MD, Carlos Fraire MD, Ana Marin MD, Division of Pediatric Surgery. Garrahan Hospital Buenos Aires Argentina

PURPOSE: The aim of this study is to compare the clinical outcomes of pediatric patients with ulcerative colitis who underwent surgery treated with a laparoscopic or open approach.

METHODS: Between July 1991 and October 2005, 24 consecutive unselected patients with UC have received surgical treatment. The mean age was 11 years and 9 months. Seventeen patients underwent staged subtotal colectomy and proctectomy with ileal anal pouch (11 UCO and 6 UCL).

Seven underwent a single stage proctocolectomy and ileoanal pouch (4 UCO and 3UCL) We divided the procedures into three groups: Group 1: subtotal colectomy + ileocolostomy Group 2: proctectomy +ileoanal pouch; Group 3: Single stage proctocolectomy + ileoanal pouch. Patients undergoing staged ileal ?anal approach were analyzed separately in Group 1 and 2. Operative time, postoperative oral intake, the use of opiates, hospital stay and postoperative morbidity were compared between groups.

RESULTS: The mean operative time was longer in the laparoscopic group. However, the oral intake, the use of narcotics and the hospital stay were shorter. Postoperative morbidity was similar in the two groups, but the open proctectomy and pouch procedures had higher infection complications.

DISCUSSION: Laparoscopic approach is feasible and safe. It allows a quick recovery with improved cosmesis. This study was closed in October 2005 to allow a year follow up morbidity . It represents the laparoscopic learning curve of the procedure in the institution and operative time has decreased in the last year.

P010 ONE TROCAR LAPAROSCOPIC APPENDECTOMY IN CHILDREN

Shin-Yi Lee MD, Chang Gung Memorial Hospital, Kaohsiung, Taiwan

BACKGROUND: Appendectomy is one of the most commonly performed surgical procedures in pediatric surgery. Laparoscopic appendectomy is a feasible and a safe alternative to open appendectomy. Several laparoscopic procedures have been described that use one or more trocars. We report our experience with the treatment of acute appendicitis in children using a true laparoscopic technique by means of only one transumbilical trocar.

METHODS: From January 2005 to December 2006 we performed 108 laparoscopic appendectomies. All children presenting with a preoperative diagnosis of appendicitis were candidates. A 10-mm trocar was placed in the umbilicus. An operative laparoscope was used for mobilizing the appendix. One or two transabdominal suspension suture were for facilitating dissection. The appendix base was ligated with extracorporeal tie. The resected appendix was harvested with an Endobag and was removed through the umbilicus. The umbilical incision was closed and the wound irrigated.

RESULTS: Sixty-one males and 47 females underwent one trocar appendectomy (n = 108. Mean age was 12 years(range, 3months-18 years). Mean operative time was 96 minutes (range, 17-174 minutes) in simple appendectomy and was 108 minutes (range, 55-189 minutes) in complicated(gangrene or perforated) appendectomy. One patient was converted to open because of sub-hepatic appendix. No one needed additional trocar. Appendicitis was classified pathologically as acute (n = 39), gangrenous (n = 12), ruptured (n = 38), congestion (n = 19). Complications included intra-abdominal abscess (n = 3) and intestinal obstruction (n = 1). There was no wound infection.

CONCLUSIONS: One trocar transumbilical appendectomy minimizes equipment needs, thus, potentially reducing cost. Transabdominal suspension sutures eliminate the need for additional trocar. Simple and complex appendectomies can be performed with this technique. Our complication rate was low, and our operating times and length of stay were equate to open appendectomy. One trocar transumbilical appendectomy is a safe and effective technique in children.

P011 THE PACE OF WEIGHT LOSS IN ADOLESCENT LAPAROSCOPIC GASTRIC BANDING: SHORT-TERM RESULTS

Jeffrey L Zitsman MD, Mary Ann Witt, DNSCc, Janet Schauben, CNSD, Morgan Stanley Children's Hospital of NY Presbyterian, Columbia University

Adolescents who undergo laparoscopic gastric banding (LAGB) lose weight at different paces, depending in part upon the phase of treatment (e.g., pre-op, immediately post-op, post adjustment). Early rapid weight loss resulting from pre-op liquid diet and immediate post-op weight loss outpace the gradual weight reduction achieved by most LAGB patients. To quantify these changes, we examined early results in 9 adolescents (ages 13-18) who underwent LAGB.

SUBJECTS: Eleven adolescents (6 female, 5 male) have undergone LAGB at our institution with follow-up ranging from 1-7 months. All patients take a liquid diet for 7-10 days immediately prior to surgery. Liquids are proscribed immediately post-op, then pureed foods, transitioning to solid diet by 4-5 weeks. Initial band adjustments are made at 6 weeks; follow-up visits are scheduled every 2 weeks until 1-1.5 pound/week weight loss is achieved. Monthly visits follow through 6 months.

FINDINGS: While on a liquid diet each pre-op patient lost weight (mean 11.8

lb, range 2.9-36.7). In the 2 weeks immediately following surgery, patients continued to lose weight rapidly (mean 11.4 lb, range 7-18.4). 4 weeks post op the weight loss average dropped to 1.3 lb (7 patients: 3 gained weight (avg. 0.7lb) while 4 lost weight (avg. 7.3 lb). At 6 weeks post-op, 2 patients had gained additional weight (1.4 and 11 lb, respectively) and 5 patients lost an average additional 2.8 lb each (range 1.8 - 4.9). Following initial and/or first subsequent adjustment, 6 of 9 patients had lost weight (avg. 1.2 lb/wk, range 0.7 - 7.2). 1 of 3 who had regained weight subsequently lost 3.9 lb after her 3rd adjustment and has continued to lose weight.

CONCLUSIONS: Adolescents who undergo LAGB undergo rapid weight loss immediately before and after surgery, after which the pace of weight loss slows. This information may be helpful for teens who become discouraged when they lose less or gain weight after the initial rapid weight loss period.

P012 OUTPATIENT LAPAROSCOPIC INTERVAL APPENDECTOMY FOR PERFORATED APPENDICITIS

Monica O Lopez MD, Christine Whyte MD, Burton H Harris MD, Children's Hospital at Montefiore, Albert Einstein College of Medicine, Bronx, NY.

BACKGROUND: Non-operative management of perforated appendicitis is now an accepted treatment option. Many surgeons recommend interval appendectomy for some or all of these patients. We present our experience with laparoscopic interval appendectomy (LIA), and we propose that most patients who have LIA can be discharged on the day of surgery.

MATERIALS AND METHODS: We performed a retrospective review of all children who underwent LIA on our service at a children's hospital between February 2003 and November 2006. The decision to admit patients to hospital after LIA was based mainly on individual surgeon preference and custom. We collected data on postoperative pain, vomiting, diet and fever in the patients observed in hospital after surgery and we searched for complications and emergency department visits in the outpatient group.

RESULTS: 59 children entered a non-operative treatment protocol for perforated appendicitis. This was successful in 37 (62%). 23 have had LIA, including one conversion to open appendectomy. The mean age of LIA patients was 11.7 years (range 3-20 years). The average interval time between the acute episode and LIA was 8.6 weeks (range 4-20 weeks). Of 23 LIA patients, 11 were discharged on the day of surgery. There were no complications and no returns to the emergency department in the same-day surgery patients, and no reported problems at the post-operative visit. Nine were observed for one night after LIA; two of these had short episodes of low-grade fever (max.38.2oC). Three had episodes of moderate pain (score > 5/10 on a standard pain scale). None required narcotic analgesics after leaving the recovery room. All patients tolerated diet and none had vomiting. It is likely that most of these nine could have gone home on the day of surgery. Three patients stayed for more than one night (range 2-3 days), including the one conversion, because of pain, low-grade fever or delayed resumption of diet.

CONCLUSION: From this experience, we conclude that laparoscopic interval appendectomy can be safely performed in most children as an outpatient procedure.

P013 LAPAROSCOPIC ROUX-EN-Y PANCREATICOENTEROSTOMY FOR CONGENITAL PANCREATIC DUCTAL DILATATION IN CHILDREN

Jun Zhang MD, Long Li, Jing-Cheng Deng, the Capital Institution of Pediatrics & #65292; Beijing, China

OBJECTIVE: To share our experience in laparoscopic Roux-en-Y pancreaticoenterostomy for congenital pancreatic ductal dilatation in children.

METHODS: A 2-year-old boy with recurrent episodes of abdominal pain associated with meal. He was investigated & found to have a pancreatic duct dilatation communicated with 4.4 cm cyst at the distal part by pancreaticography. The cyst was excised and pancreaticoenterostomy was undertaken laparoscopically. Operative time was 120 minutes, and minimal blood loss occurred.

RESULTS: The postoperative course was uneventful. Twenty-two months after the operation, clinical follow-up (including assessment of exocrine and endocrine pancreatic function) revealed nothing abnormal. The functional and aesthetic results were satisfactory.

CONCLUSIONS: The technique used for our case is simple and was completed safely within a reasonable operative time, and yielded a good result.

P014 META-ANALYSIS OF LAPAROSCOPIC VERSUS CIRCUMBILICAL PYLOROMYOTOMY

Nordeen M Bouhadiba MD, Sean M Marvin MD, Prasad M Godbole MD, Sheffield Children's Hospital. Sheffield. United Kingdom

BACKGROUND: Laparoscopic pyloromyotomy is common practice after sixteen years of existence. The real benefits were unclear after the initial reports. However these were mainly during the learning curve. We analyse our experience after the laparoscopic learning period is over, in order to compare more appropriately these two techniques

METHODS: We studied our practice during the last two years, comparing between the laparoscopic and circumcumbilical pyloromyotomy performed by experienced laparoscopic surgeons. One hundred and one patients were studied. 50 open and 50 laparoscopic. The open ones were done through circumcumbilical approach. The surgeons have been well over the laparoscopic learning period, using more up to date technique. Local anaesthesia prior to the port insertion, one trocar 5mm in the umbilicus, two instruments of 2.7mm without trocars were introduced for grasping the pylorus and performing the pyloromyotomy using specific spreader.

RESULTS: Operating time was 13mn for the laparoscopic and 25 mn for the open group. No conversion, incomplete myotomy, or redo-pyloromyotomy were observed in the laparoscopic group. Two perforations occurred in the open group. Post-op vomiting, time to full feed was less for the laparoscopic group. Time to discharge was 1.3 days for the laparoscopic group and 2.9 days for the open group.

CONCLUSION: The earlier reports were inconclusive. However these were done within the laparoscopic learning period. The present study was performed well after the learning period and in this case we found that the results are more conclusive and in favour of the laparoscopic group

P015 LAPAROSCOPIC APPROACH OF THE INGUINAL PATHOLOGIES IN CHILDREN

Carlos Garcia Hernandez MD, Lourdes Carvajal MD, Juan Carlos Dueñas, Hospital Infantil Privado

INTRODUCTION: The surgery of the inguinal area in children is one of the most common procedures performed in children. The laparoscopic approach had showed its utility in the treatment of the inguinal hernia, abdominal testicle and varicocele. However this approach could be also useful in almost all the inguinal pathologies in children that including all the cases of cryptorchidism and hydrocele..

METHODS AND PROCEDURES: From January 2004 to December 2006, 247 patients with some type of inguinal pathology were divided into 4 groups.

Group 1.- Inguinal hernia treated with one port approach and closure of the internal inguinal ring with one percutaneous suture.

Group 2.- Patients with hydrocele with one port approach we review the internal inguinal ring and if this conduct does not have communication we just empty the hydrocele through the scrotum.

Group 3.- Patients with inguinal and abdominal cryptorchidism, three ports approach, dissection of the spermatic cord and without the closure of the inguinal ring we put the testicle in the scrotum.

Group 4.- Varicocele patients. Three port approach and ligation of the left spermatic vessels without arterial dissection.

RESULTS: All procedures were completed successfully laparoscopically. Follow-up from 1 to 36 months. Group 1, 128 patients, we closed the inguinal hernia in almost all the patients but occurred recurrence in three patients in whom we used absorbable sutures. Group 2, 24 patients. In all the cases we drained it in a percutaneous way. In 4 children with an open processus vaginalis we closed it by means of one percutaneous suture. Group 3, 68 patients, we found intra-abdominal testicles in 8 children, 4 with testicular atrophy treated with orchiectomy and the other 4 were operated in two surgical times. In the other 60 cases the testicle was collocated in the scrotum. We found an open processus vaginalis only in 14 children and only one recurrence. Group 4, 27 patients three presented hydrocele but just one needed surgical drainage that was performed by means of a percutaneous way.

CONCLUSION: The laparoscopic approach is a safe and effective procedure that could be used in almost all the inguinal pathologies in children with low morbidity. This approach permits to review the abdominal cavity and the contralateral side with a less handled of the spermatic cord

P016 NEW LAPAROSCOPIC FLIP FLAP TECHNIQUE VERSUS CONVENTIONAL INGUINAL HERNIA REPAIR IN CHILDREN. IS IT WORTH IT?

Mohamed E Hassan, BA, Abdelrahim Mustafawi, BA, Pediatric Surgery Department, Alwasl Hospital, Dubai, UAE

BACKGROUND AND OBJECTIVES: Inguinal hernia repair is one of the most frequently performed pediatric surgical operations. several pediatric laparoscopic inguinal hernia repairs were introduced. Still there is unresolved debate regarding the feasibility of laparoscopy for treating pediatric inguinal hernia.

METHODS: A retrospective cohort study enrolled 33 patients who underwent congenital inguinal hernia repair by either new laparoscopic flip flap technique or conventional open repair. Patients were divided into two groups according to the type of surgery, Group A who underwent the new laparoscopic technique and group B who underwent conventional open repair.

RESULTS: Group A included 15 patient (mean age 39 months) while group B 18 patient (mean age 44 months). Mean operative time was 47.5 minutes for Group A versus 27.5 minutes for Group B. Intraoperative complications for group A included 1 case (7%) of vas deference injury, and 3 cases (20%) the flaps were teared during suturing while in Group B no intraoperative complications were encountered. In both groups the mean postoperative hospital stay was 5.5 hours. Postoperative follow up for 3 months revealed recurrence in 4 cases in Group A (27%), while no recurrences in Group B.

CONCLUSION: Our preliminary experience showed unsatisfactory outcome with the laparoscopic flip flap hernia repair in children. In spite the advancement in the application of laparoscopy in pediatric surgery, still conventional open hernia repair is the gold standard for children in our experience. Future studies with more numbers and long term follow up should be conducted.

P017 RECURRENCES AFTER LAPAROSCOPIC INGUINAL HERNIA REPAIR AS RELATED TO TYPE OF CLOSURE OF THE PATENT PROCESSUS VAGINALIS

ES Sablin PhD, LV Proklova MD, DE Sablin MD, IA Turabov PhD, Northern State Medical University, Regional Children's Hospital

PURPOSE: The purpose of this study is to determine the recurrence rate based on the type of the suturing technique used during laparoscopic hernia repair.

METHODS: 497 patients aged from 6 months to 22 years with patent processus vaginalis underwent initial laparoscopic procedures between January 1997 and January 2007. The method we developed was based on the laparoscopic application of the Duhamel's principle, namely injection of the peritoneum with Novocain 0.25% solution in the area of the internal inguinal ring. This injection allowed for safe division of the neck of the hernia sack without spermatic cord injury. The defect in the peritoneum was between 0.5-1.5 cm and was closed by different suturing techniques. Overall, interrupted sutures were placed in the peritoneal edges in 12 cases, ?figure of 8? closure was performed in 111 cases, purse-string closure in 352 cases and multiple combinations of suturing techniques in 22 cases. When recurrence of the hernia occurred, the redo hernia repair was also performed laparoscopically, which allowed us to determine the reason for the recurrence. The retrospective analyses of recurrences were performed by evaluation of the videos of both the initial and repeat operations.

RESULTS: A total of 8 (1.6%) recurrences were noted, that occurred over an average of 59 days after the initial operation (range 2 days - 6 months). In patients in which interrupted sutures were used, there were 2 recurrences (16.5%), in ?figure of 8? closures, 3 recurrences occurred (2.7%). In patients closed with a purse-string suture, 3 recurrences occurred (0.85%). In multiple sutures closures, no recurrences were noted. The main cause of the recurrences was the tearing out of the sutures through the peritoneal edges due to inadequate tightening of the knots in 7 of the 8 cases. In one patient (12%), inadequate closure of the large internal ring resulted in a recurrent hernia.

CONCLUSION: The incidence of disruption or stretching of the peritoneum resulting in the recurrence of hernia was related to the adequacy of closure of the internal ring. Double suture closure seemed to provide the best guarantee of adequate closure.

P018 LAPAROSCOPIC SURGERY AND AIDS

B. Banieghbal MD, University of the Witwatersrand, Johannesburg, South Africa

INTRODUCTION: More than 35% of female South African population is HIV infected, and as the result up to 10% of children are also infected due to vertical transmission. All go on to develop AIDS within 1-10 years. Minimally access surgery has a definite role in treatment of specific surgical ailments in this sub-group of patients.

MATERIAL: Over a 7-year period, the author performed more than 1500 laparoscopic procedures. 32 operations were performed on children with AIDS, with 11 on anti-retroviral treatment at the time of surgery. A variety of procedures were performed. The commonest were Nissen fundoplication (in 8 children for reflux disease due to esophageal shortening secondary to severe candidiasis), thoracoscopic drainage of empyema (in 4 cases) and 3 laparoscopic bowel biopsy for TB.

RESULT: 3 conversions were required, 2 for excision of right upper lobe tuberculomas and one case for CMV perforation of upper rectum requiring a diverting stoma. There was a single mortality, a 2 year-old child with massive empyema died due to overwhelming sepsis 10 days post-operatively. Interestingly there were no wound infections and no other surgery specific complications. All procedures were done as the last case on elective lists and no further laparoscopic cases are done for at least 24 hours.

CONCLUSION: Pediatric surgeons who are familiar with laparoscopic surgery can offer HIV infected and AIDS children a wide range of procedures for appropriate indication. There is no increased risk of complications, as compared to open surgery.

P019 ADVANCES IN PEDIATRIC SURGERY RESIDENT MIS EXPERIENCE

Karen A Diefenbach MD, Suzanne Yoder MD, Milissa McKee MD, Yale School of Medicine

INTRODUCTION: This study compared the minimally invasive surgery (MIS) experience of graduating pediatric surgery residents over the last three academic years to the experience of general surgery residents graduating during the same time period.

METHODS: The Case Log Summary reports of the ACGME for graduating pediatric surgery residents were reviewed for the academic years ending in 2004, 2005, and 2006. For procedures which have a specific code for both ?open? and ?scope? versions of a procedure, the number and proportion of minimally invasive cases per resident was calculated for each year. Comparisons between pediatric surgery resident experience and general surgery resident experience were also compared for those procedures performed in both adults and pediatric patients.

RESULTS: The average number of MIS cases per pediatric surgery resident has increased by 39% from 95 to 132. For procedures with specific MIS codes, the percentage of minimally invasive procedures has increased in almost all categories and now exceeds 50% in lung biopsies, decortication/bleb resection, antireflux procedures, appendectomy, cholecystectomy, and splenectomy. The percentage of minimally invasive antireflux procedures in adults (69%) is still greater than in children (58%). However, the percentage of minimally invasive procedures performed for cholecystectomies, appendectomies, and splenectomies by pediatric surgery residents is equal to or greater than the percentage of the same procedures performed by adult general surgery residents. The high percentage of laparoscopic splenectomies in pediatric patients is most likely due to the higher frequency of elective indications for splenectomies in children.

CONCLUSIONS: The average number of minimally invasive surgical cases for pediatric surgery residents is increasing. We believe it is representative of the trend in the field. For procedures that are performed in both adult and pediatric populations, pediatric surgery residents are approaching or exceeding the percentage of minimally invasive procedures performed by graduating general surgery residents.

P020 A NEW LAPAROSCOPIC INSTRUMENT WITH A CONCEPT OF INTRA-PERITONEAL ASSEMBLY


Toshiki Ohya MD, Kazuyuki Kojima MD, Hideki Akamatsu MD, Naofumi Tanaka MD, Toshio Takayama PhD, Toru Omata PhD, Department of Pediatric Surgery, Surgery, Anesthesiology, Tokyo Medical and Dental University, Department of Mechano-Micro Engineering, Tokyo Institute of Technology, Tokyo, Japan

BACKGROUND: Surgeon's left hand plays an important role in the surgeries to make suitable surgical field. A reason of difficulty in laparoscopic surgeries is that we do not have any satisfactory instrument acting for left hand.

NEW CONCEPT: We already proposed a new pursestring suturing apparatus working in laparoscopic surgeries. Because a pursestring suturing apparatus has T-shape, it could not pass through the port. We made a new pursestring suturing apparatus that assemble 2 pieces in one in the peritoneal cavity. Then we extend this concept to make new laparoscopic instrument acting for left hand. We named it laparoscopic hand.

LAPAROSCOPIC HAND: The laparoscopic hand is composed of a main rod and 3 detachable fingers. Main rod insert through a port, while a finger insert through the other port, and then unite them in the peritoneal cavity. Two other fingers unite with the rod in turn. The fingers can be moved independently, we can manipulate organs, pushing, pulling, and grasping.

CONCLUSIONS: Although, this laparoscopic hand is a prototype and there is much room for further improvement before clinical use, it will be a great help for handling various organs in laparoscopic surgeries.



P021 THE ECONOMICS OF ROBOTIC SURGERY IN CHILDREN

Brice Antao MD, David Jayne MD, Azad Najmaldin MD, Leeds Teaching Hospitals NHS Trust, Leeds, United Kingdom

OBJECTIVE: Robotic surgery is still in its early infancy and its application has largely been impeded by the high cost. We present our experience of robotic surgery in children and highlight its cost effectiveness.

METHODS: Between March and January 2007, 25 children underwent 32 robotic procedures using the da Vinci robotic system. The median age was 11 years (range, 3-18). The procedures included Nissen fundoplication with/without gastrostomy (8), other gastrointestinal procedures (4), pyeloplasty and nephrectomy (13). Data was collected prospectively. We also conducted a cost comparison between robotic and laparoscopic fundoplication based on instrumentation costs provided by the manufactures and theatre overhead costs per hour as supplied by the hospital health economics department.

RESULTS: The procedures were completed in 30 cases and converted in 2 cases. Postoperative complications developed in 2 patients. The median robotic docking time was 22 minutes (range, 15-60) and did not vary significantly with the procedure type. The median operating time was 132 minutes (range, 50-280) and hospital stay was 2 days (range, 1-6). Comparisons between robotic and laparoscopic procedures for Nissen fundoplication are shown in the table below.

| PROCEDURE | OP TIME (mins) | OP COST | CONSUMABLES |
|--------------|----------------|---------|-----------------|
| Robotic | 163 (135-195) | £ 1244 | £ 754 |
| Laparoscopic | 132 (84-180) | £ 1010 | £ 422 (180-737) |

The capital cost of a 3-arm robotic system including 7 year maintenance is £ 1.14 million. In contrast the cost of a laparoscopic system including 5 year maintenance is £ 42000.

CONCLUSIONS: Robotic surgery is safe and applicable to a wide range of paediatric surgical conditions. The technique has the advantages of better vision, dexterity and ergonomics and has a shorter learning curve. However, the costs are significantly higher. With experience, it is possible that saving can be made in terms of shorter operating time and manpower.

P022 ROBOTIC ASSISTED SURGERY IN CHILDREN

CK Sinha MS, C Butler, M Haddad MS, Chelsea & Westminster Hospital, London, UK

INTRODUCTION: In Paediatric Surgery, the experience with Robotic Surgical system is limited. However, with advancement in technology, the horizon of Robotic Paediatric Surgery has rapidly grown. The aim of this study was to analyse the current status of Robotic involvement in Paediatric Surgery.

METHODS: A systematic search of Medline and the Cochrane Database was performed. Data from children, who underwent Robotic assisted procedures, were reviewed retrospectively from all published reports till January 2007.

MAIN RESULTS: Total 24 studies were identified describing 238 patients. Of these, 5 studies were case control comparing with either laparoscopic or open procedures. The other studies were case report / series. The commonest

robotic system used was daVinci (15 studies- 126 cases) followed by Zeus (4 studies ? 52 cases) and AESOP (2 studies- 157 cases). The age range of various operations was 2 months to 18 year (mean 8.3 years). The commonest operation done was fundoplication (200 cases) followed by pyeloplasty (53), and PDA ligation (50). Mean operation times for fundoplication were robotic (144 min), laparoscopic (158 min) and open (121 min). Mean operation times for robotic assisted pyeloplasty was 266 min (open pyeloplasty 214 min). Mean operation time for robotic PDA ligation was 166 min (83 min for open procedure). Other major operations performed successfully were cholecystectomy (6), Morgagni hernia repair (3), splenectomy (2), Heller myotomy (1), choledochal cyst excision & hepaticojejunostomy (1), salpingoophorectomy (1), Mitrofanoff (4), bilateral ureteric reimplantation (1), bilateral heminephroureterectomy (1), vascular ring repair (8). Most of the operation were completed successfully. Great advantage was found in intracorporeal suturing, precise dissection and handling of tissue. Set up time was significantly high in comparison to laparoscopic or open surgery. The learning curve for robotic surgery was steep, but operating time improved significantly in the later part of experience.

CONCLUSION: Robotic surgery enables more refined hand-eye coordination, superior suturing skills, better dexterity and precise dissection. Learning curve may explain for longer operating and set up times, however time decreased during the later part of studies. Initial cost factor is an important hindrance to its widespread use. The ultimate acceptance of this technology depends on issues of learning curve (training), size of machine, efficacy, safety and cost.

P023 DO CHILDREN TOLERATE THORACOSCOPIC SYMPATHECTOMY BETTER THAN ADULTS?

Zvi Steiner MD, Zahavi Cohen MD, Oleg Kleiner MD, Ibrahim Matar MD, Jorge Mogilner MD, Hillel Yaffe, Soroka & Bnai-Zion Medical Centers

BACKGROUND/PURPOSE: Palmar hyperhidrosis (PHH) is a fairly common condition which is treatable by thoracoscopic sympathectomy (TS). Compensatory sweating (CS) is a major side effect of TS. We surveyed post TS patients to determine and compare the procedure's long term success, patient satisfaction and surgical complications in children (<#8804;14 years of age) compared to adolescents and adults (>#61619;15 years of age).

METHODS: A chart review yielded 325 patients with a >24 month follow up who had undergone TS at three medical centers (Hillel Yaffe, Soroka and Bnai-Zion), who could be contacted and who agreed to reply to a detailed telephone questionnaire.

RESULTS: There were 117 children and 208 adults. Most participants (96.3%) reported complete or reasonable symptomatic relief. The long term postoperative satisfaction was high (84.5%): it was significantly higher in children (92.2% v 80.7% in adults, P=0.005). CS appeared within 6 months postoperatively in 81.8% of the patients. It was significantly less prevalent in children (69.8% v 88.5% in adults, P<0.001). CS became exacerbated with time in 10.2% of the entire cohort, but diminished in 17.8% of the children v 9.6% of the adults (P=0.034), usually within the first 2 postoperative years. CS was also less severe in children than in adults: none or mild in 54.3% v 38.0%, moderate in 21.6% v 32.7% and severe in 24.1% v 29.3%, respectively (P=0.004). Fifty one percent of all participants claimed that their quality of life decreased moderately or severely as a result of CS, but only 7.9% of the children and 22.4% of the adults (P=0.001) would not have undergone the operation in retrospect.

CONCLUSIONS: Thoracoscopic sympathectomy relieves PHH in most cases. Most patients prefer relief from PHH even at the cost of moderate or severe CS. The presence of CS and its severity is tolerated better by children, and their postoperative satisfaction is higher. We therefore recommend not postponing TS until adulthood.

P024 TRANSVESICAL THORACOSCOPY: A NATURAL ORIFICES TRANSLUMENAL ENDOSCOPIC APPROACH FOR THE THORAX

Estêvão Lima MD, Tiago Henriques-Coelho MD, Carla Rolanda MD, José M Pêgo MD, David Silva MS, José L Carvalho MD, Jorge Correia-Pinto PhD, Division of Pediatric Surgery, Hospital S João, Porto; Life and Health Sciences Research Institute (ICVS), University of Minho, Braga, Portugal

PURPOSE: Recently there has been an increasing enthusiasm in using natural orifices transluminal endoscopic surgery (NOTES) to perform scarless abdominal procedures. We have previously reported the feasibility

and safety of the transvesical endoscopic peritoneoscopy in a long-term survival porcine model as useful for those purposes. Herein, we report our successful experience performing transvesical and transdiaphragmatic endoscopic approach to the thoracic cavity in a long-term survival study in a porcine model.

MATERIALS AND METHODS: Transvesical and transdiaphragmatic endoscopic thoracoscopy was performed in 6 anesthetized female pigs. A 5 mm transvesical port was created on the bladder wall and an ureteroscope was advanced into the peritoneal cavity. After diaphragm inspection, we introduced through the left diaphragmatic dome a ureteroscope into the left thoracic cavity. In all animals, we performed thoracoscopy as well as peripheral lung biopsy. Animals were sacrificed by day 15 postoperatively.

RESULTS: We easily introduced a 9.8 Fr ureteroscope into the thoracic cavity that allowed us to visualize the pleural cavity and to perform simple surgical procedures such as lung biopsies without complications. There were neither respiratory distress episodes nor surgical complications to report. Postmortem examination revealed complete healing of vesical and diaphragmatic holes, whereas no signs of infection or adhesions were observed in the peritoneal or thoracic cavities.

CONCLUSIONS: This study demonstrates the feasibility and safety of transvesical thoracoscopy in porcine model.

P025 MINIMALLY INVASIVE DIAPHRAGMATIC APPROACH. THE NEW GOLD STANDARD,

Miguel Guelfand MD, Andrea Poblete MD, Juan C. Gallardo MD, Hospital de Niños Dr. Exequiel González Cortés

PURPOSE: To evaluate the results of diaphragmatic surgery with minimally invasive technique in a single institution.

METHODS: Medical records of patients with diagnosis of diaphragmatic anomalies who underwent either laparoscopic or thoracoscopic techniques between October 2002 and March 2006 were revised.

RESULTS: In the study period, 30 children were operated. The pre operating diagnoses were: Congenital diaphragmatic hernia of the newborn (CDHNB) (n = 13); Morgani diaphragmatic hernia (MDH) n =14 and Diaphragmatic relaxation (DR) in 3 cases. In the CDHNB group, all the interventions were made after stabilization of the patient's pulmonary hypertension. Only 3 surgeries were converted to open (2 because of the impossibility of reducing the hernia into the abdominal cavity). In the MDH group, all of them were successfully completed laparoscopically. All the patients in the DR were operated via thoracoscopy. There were 2 intraoperative complications managed successfully without any further problems, one patient had an intestinal serosa lesion (CDHNB) and one patient suffered a pleural opening (MDH). The mean follow up of the group is 18 months (5-44). There were no mortalities in this series.

CONCLUSIONS: The minimally invasive technique for diaphragmatic approach was effective and safe in this series. The author recommend this approach for diaphragmatic anomalies.

INDEX WORDS: Diaphragmatic pathology, laparoscopy, thoracoscopy, pediatric.

P026 THORACOSCOPIC LOBECTOMY FOR SYMPTOMATIC CCAM IN A FIVE MONTH OLD INFANT: A CAUTIONARY TALE FROM THE PATHOLOGIST

Timothy J Bradnock MD, Gordon A MacKinlay MD, Katherine McKenzie MD, The Royal Hospital for Sick Children, Edinburgh, Scotland, UK

Pleuropulmonary blastoma (PPB) can be mistaken clinically and histologically for type 4 CCAM in an area of malformed lung.

A 5-month old girl presented to the emergency department after an episode of respiratory distress and cyanosis around the lips on a flight. Following admission, a CT scan confirmed a 'multicystic expansile air-filled abnormality arising from the left upper lobe'. A radiological and clinical diagnosis of CCAM was made. She proceeded to thoracoscopic lobectomy.

With the patient left side up and conventional endotracheal intubation, 3 ports were used (5mm for the telescope and two 3.5mm working ports) with CO2 insufflated to a pressure of 4mmHg. A plasmakinetic device was used to coagulate and divide the lobar pulmonary vessels in sequence. The upper lobe bronchus was divided distal to two 5mm endoclips. The largest cysts were deflated to facilitate removal of the entire upper lobe after gentle stretching of the 5mm port site with artery forceps. A 20Fr chest drain was left in situ for 3 days. The patient was extubated on day 1 and discharged home on day 5 to complete an uneventful recovery.

The initial pathology report suggested type 4 CCAM. However, in light of recent evidence suggesting histopathological overlap between type 4 CCAM and type 1 pleuropulmonary blastoma (PPB), additional sections were taken. Further histological analysis confirmed type 1 pleuropulmonary blastoma. Since 1977, there have been ten case reports of rhabdomyosarcoma and eight of PPB arising in CCAMs. Unlike bronchioalveolar carcinomas (which are associated with type 1 CCAMs), these intrathoracic malignancies occur almost exclusively in preschool children. Despite karyotypical and p53 status differences between CCAM and PPB, the International Pleuropulmonary Blastoma Registry has suggested that type 4 CCAM may not be biologically distinct from type 1 PPB. The clinical and radiological features of type 1 PPB cannot be distinguished from congenital lung cysts. Thoracoscopic lobectomy has low morbidity in children and offers clear advantages over open thoracotomy including reduced post-op pain and hospitalisation, pulmonary complications and shoulder girdle dysfunction. These benefits coupled with the increasing evidence that congenital cystic lung lesions may harbour occult malignancy or the potential for early malignant transformation, should herald the end for the watch and wait policy in the asymptomatic CCAM group. We suggest that all new patients with cystic lung disease are assessed and treated thoracoscopically.

P027 PARAPNEUMONIC EMPYEMA IN CHILDREN: COMPARATIVE STUDY OF CLINICAL EVOLUTION ACCORDING TO THE INITIAL TREATMENT (VATS VERSUS UROKINASE)

C Marhuenda MD, J L Peiró MD, C Barceló MD, P Soler MD, J Lloret MD, V Martínez Ibáñez PhD, Pediatric Surgery Department. Hospital Vall d'Hebron. Barcelona. Spain.

BACKGROUND: Parapneumonic empyema (PPE) is nowadays a frequent complication of acute bacterial pneumonia in children. Inadequate drainage of loculated empyema may lead to long term hospitalization, increased morbidity due to several drainage attempts and long-lasting ventilation impairment. There is no consensus regarding the ideal treatment of PPE.

AIM: The aim of this study is to compare the effectiveness of two different treatments: video-assisted thoracoscopy (VATS) or drainage with fibrinolytics (urokinase) (DF).

METHODS: Prospective non-randomized study for all the patients admitted to our hospital between January 2001 and March 2006 with a parapneumonic empyema. Loculated empyema was diagnosed by chest sonography and patients were treated with DF or VATS depending on the surgeon preference. Patients with non-loculated empyema were treated with drainage exclusively. We have compared the evolution of both groups (VATS vs DF). Primary variables were the total hospital stay, days of tube thoracostomy, postoperative fever and postoperative stay. Data were compared using one way analysis of variance.

RESULTS: Eighty six patients (4 months to 14 years, mean 4 years) were admitted with a parapneumonic empyema. Twenty were non loculated empyemas and were treated with tube thoracostomy alone, and excluded of the study. Thirty seven (45%) were treated with VATS and 27 (33%), with DF. Primary variables have been compared between groups VATS and DF with no statistically significant differences ($p > 0,05$) for hospital stay (11.6 vs 13.56), duration of tube thoracostomy (4.62 vs 6.44), postoperative fever (3.57 vs 5.63) or postoperative stay (9.7 vs 12.3). One patient of group VATS needed a second drainage procedure and one, a third one. In the group DF, four patients needed a second procedure and one, a third.

CONCLUSIONS: According to our experience, the results of VATS vs DF as an initial treatment for loculated empyema are similar. Nevertheless, it seems to be a higher rate of failure with the need of more procedures in the group of patients treated initially with DF. The lack of randomization is the main limitation of this study, and it could exist a bias in treatment selection for the patients. Anyway, we are now carrying out a multicenter randomized study to confirm or contradict this findings.

P028 ENLARGED NEPHRECTOMY BY LAPAROSCOPY FOR RENAL TUMORS IN CHILDREN: INITIAL EXPERIENCE

François Varlet PhD, Manuel Lopez MD, Emmanuelle Guye MD, Michel François MD, Rene Allary MD, Claire Berger MD, Department of Pediatric Surgery University "Nord Hospital" Saint Etienne -France

PURPOSE: The standard surgical of renal tumors in children is open surgery and the role of laparoscopy approach remains to be defined. We reported our

initial experience in the treatment of enlarged nephrectomy laparoscopic for unilateral renal tumors in children.

METHODS: Four children (two males and two females), with mean age five years old, were operated for unilateral renal tumors by laparoscopic approach in our unit from 2005 until 2006. Three cases were suspected of Wilms tumors and one of them presented bilateral lung metastases; they were preoperatively treated with the SIOP 2001 protocol (vincristine and actinomycin D). The fourth case was a ten year old child, with medulloblastoma history; a percutaneous biopsy was performed in preoperatively. All cases subsequently underwent enlarged laparoscopic nephrectomy. Four trocars of five mm and transperitoneal approach were used in each case. The tumors were placed in an endobag and after was extracted without morcellation through a supra-pubic incision.

RESULTS: All tumors as well as lymph node samples were removed completely by laparoscopy without rupture. No conversion to laparotomy was necessary and there were neither intraoperative bleeding nor perioperative complications. The mean operative time was 90 min. In postoperative, one child presented an intestinal perforation and was treated by laparoscopy; the discharged was at 10 days, and the others were discharged after two or three days. The histologies were : unilateral Wilms tumors in two cases, clear cell sarcoma in one case and juvenile renal adenocarcinoma in one case. None of these patients presented evidence of tumoral recurrences, port-site implantation and long-term complications.

CONCLUSIONS: Enlarged nephrectomy for renal tumors in children is feasible and safe by laparoscopic procedure, with the same oncological strategies that open surgery. A long follow-up and more cases are necessary to evaluate and compare the results of laparoscopic approach with the open procedures.

P029 100 CASES OF TRANSPERITONEAL LAPAROSCOPIC RENAL SURGERY IN INFANTS AND CHILDREN WITHOUT CONVERSIONS OR TRANSFUSION

Amos Nebeman MD, Paul h Noh MD, Ricardo Gonzalez MD, A. I duPont hospital for children

OBJECTIVE: To review our experience with 100 cases of renal laparoscopic surgery in infants and children.

METHODS: Retrospective chart review of all children undergoing laparoscopic renal surgery at our institution between March 2003 and October 2006. Estimated blood loss, operative times, complications, length of hospitalization, follow-up, and pre and postoperative kidney function were recorded.

RESULTS: During the study period, 100 children underwent laparoscopic surgery on one or both kidneys. The median patient age was 19.5 months (range 1.3 to 215). Median follow-up time was 17 months (range 3.5-45). Case distribution was 50 pyeloplasties, 1 excision of a calyceal diverticulum, 27 nephrectomies and 22 partial nephrectomies. There were 2 intraoperative complications: 1 injury to the left renal vein and 1 injury to a lower pole ureter during an upper pole partial nephrectomy. Both injuries were recognized and repaired laparoscopically. There were no injuries to other intraabdominal organs, there were no conversions to an open procedure, and no patient required a blood transfusion. No patient developed bowel obstruction from adhesions during the follow-up period.

CONCLUSION: Laparoscopic surgery of the kidneys is safe and effective and has now become our preferred approach, including small infants.

P030 GROSS PATHOLOGY CLASSIFICATION OF DUPLEX KIDNEY AND LAPAROSCOPY MANAGEMENT

Rongde Wu MD, Rui Ma, Youde Yu, Pediatric Surgery Department of Shandong Provincial Hospital

PURPOSE: To propose gross pathology classification of duplex kidney and key laparoscopy procedures for each type. Methods: 65 patients with 83 duplex kidneys were submitted to 61 laparoscopy. Gross pathology classification of duplex kidney was proposed based on characteristics of upper and lower element found in operation. The key laparoscopy procedure to each type were summarized. Results Duplex kidney could be classified into 5 types: Appendant type:(36/83) The upper element was very small, located on the top of lower element. Mild hydronephrosis in upper element, with shallow ditch between upper and lower elements could be found.; The key laparoscopy procedure was to find the shallow ditch between upper and lower element , then removed upper element by cutting near upper moiety to avoid injuring lower element. Fused Type:£13/83£©Two elements located inside the same capsule with no obvious borderline between them. when the capsule was

cut open, small upper element could be seen wrapped inside the top of lower element. The key laparoscopy procedure was defining resecting location. The ureter and renal pelvis should be firstly dissociated, then the capsule was cut open alone inferior margin of upper renal pelvis, finally upper element was resected alone inferior margin of upper renal pelvis. Hydronephrotic Type: £ 12/83 £ © The upper element, with severe hydronephrosis and thin parenchyma, was as big as lower element, and a border vestige between them could be seen. Two key laparoscopy procedures: To avoid injuring lower renal pedicle. The lower renal pedicle was tend to be dislocated due to compression of hydronephrotic upper element—so when upper and lower element pedicles were dissociated—protecting lower pedicle was more important; Much more attention should be paid to peripheral borderline of resecting line. Dual-Poor Type: £ 2/83 £ © The upper and lower elements were hypoplastic, with ± Y shape ureter and ectopic orifice. Nephrectomy was suitable for this type, it was simple. Dual-Well Type: £ 20/83 £ © The upper element was as lower element in size with normal renal function. No need of surgery except existence of complication, and urethral reimplantation was the common surgery procedure. 59 Laparoscopy were successful, with average 1 hour time—7 ml blood loss, 4 days stay in hospital. Conclusion: Laparoscopy were suitable for management of duplex kidney. It's less invasive, blood loss, compared to conventional open surgery. This classification was helpful for surgery.

P031 LAPAROSCOPIC PYELOPLASTY IN CHILDREN BELOW ONE YEAR OF AGE

Philipp O Szavay MD, Tobias Luthle MD, Joerg Fuchs MD, Department of Pediatric Surgery, Children's Hospital, University of Tuebingen, Tuebingen, Germany

PURPOSE: Up to now, there is only limited experience with laparoscopic pyeloplasty in children below one year of age. Purpose of this study was to evaluate this group of patients in children we operated on, in terms of functional outcome, i.e. renal function.

PATIENTS AND METHODS: Between July 2004 and December 2006 13 of 42 children undergoing laparoscopic pyeloplasty could be identified below one year of age at time of operation. We reviewed operating time, length of hospital stay and differential renal function with diuretic renography before as well as 3 months after operation.

RESULTS: Median age of the 13 patients at operation was 2 months (1-10 months). Median operating time was 135 minutes (100-210 minutes). Median length of hospital stay was 7 days (7-9 days). All children received a transrenal ureteral stent for draining of the anastomosis. No intra- or perioperative complications occurred except for one patient in whom a minor perforation of the colon lead to severe septic peritonitis. Differential renal function could be preserved in all patients except for the one having the complication where a nephrectomy had to be performed in the further course.

CONCLUSION: Laparoscopic pyeloplasty is feasible also in infants. In terms of preservation of differential renal function the laparoscopic approach is competitive when compared with standard open surgery. Operating times are within an acceptable range, when compared to laparoscopic pyeloplasty in older children (median 130 minutes in 42 patients) and compared to standard open surgery (median 115 minutes in 29 patients).

AS described in literature, complications such as perforation of the gut may occur. In our case this lead to severe peritonitis and consecutive loss of the kidney which was operated on. Therefore we conclude that laparoscopic pyeloplasty requests large experience in laparoscopic pediatric urology, as it represents one of the major challenging surgical procedures in minimal invasive pediatric surgery.

P032 TESTICULAR PERFUSION AND GROWTH AFTER LAPAROSCOPIC INGUINAL HERNIA REPAIR IN CHILDREN

Salmi Turial MD, Thomas Hueckstaedt MD, Schwind Martin MD, Ullrich Klein MD, Felix Schier MD, University Medical Center, Department of Paediatric Surgery, Mainz, Germany

PURPOSE: It has been suspected that suturing of the internal inguinal ring during laparoscopic herniorrhaphy in children may compromise testicular blood supply. Recently a new technique was developed which combines light spectroscopy and laser Doppler technique with percutaneous measurement at 8 mm depth (O2C, ?O to see?, LEA Medizintechnik GmbH, Germany).

METHODS: 45 boys underwent laparoscopic inguinal hernia repair for unilateral inguinal hernias (aged 6 weeks to 13 years, median 3.2 years; 24 right-sided, 21 left-sided). One year postoperatively, testicular volume and

echogenic texture were studied ultrasonographically, and testicular perfusion was measured by O2C. An optical probe was placed on the surface of each scrotal pouch for measurements. A linear model was fitted to test changes in O2 saturation of hemoglobin, hemoglobin volume and blood flow. Measurements were compared for the operated side to the contralateral, closed side. Children were excluded with previous incarceration, inflammatory changes, other testicular abnormalities possibly influencing O2 perfusion. Ultrasound studies of the testes and testicular perfusion of other, 25 healthy boys of similar ages served as additional controls.

RESULTS: There was no difference at the >0.0001 p level either in volume and echotexture of the testicles or in the measurements of testicular perfusion and blood supply after one year of surgical intervention. The relative hemoglobin volume of the testes remained unchanged and the capillaries did not change their size after surgery. Blood flow and oxygenation were unrelated to closure of the inguinal internal ring and were identical to the unoperated side. There were no statistically significant differences between the operated and unoperated side in the same individual. Also, there were no differences to the healthy control group.

CONCLUSION: Our results suggest that laparoscopic inguinal hernia repair using suture closure of the internal inguinal ring does neither impair testicular perfusion nor testicular grow in a long term follow up.

P033 EVALUATION AND GUIDANCE OF ENDOSCOPIC TREATMENT OF VESICoureTERAL REFLUX WITH PEROPERATIVE DIRECT CYSTOGRAPHY

Oguz Ates MD, Osman Z Karakus MD, Erdal Karakaya MD, Gulce Hakguder MD, Mustafa Olguner MD, Feza M Akgur MD, Dokuz Eylul University, School of Medicine, Department of Pediatric Surgery, Izmir

INTRODUCTION: Endoscopic subureteric injection is a minimal invasive method for the treatment of vesicoureteral reflux (VUR). The efficacy of the procedure is controlled by postoperative conventional or radionuclide cystograms and with ultrasonography (US) by evaluation of the size of the bulge, formed by the injected material. A prospective clinical study was planned for evaluating the efficacy of subureteric injections by fluoroscopic cystography before and after the endoscopic subureteric injections in the operation room.

MATERIAL AND METHODS: 32 patients, 9 boys and 23 girls (14 bilateral) aging 9 months to 14 years (average 6.6 year old); with a total of 46 ureters were treated. In operating room, the patients were evaluated by fluoroscopic cystography just before and after the subureteric injection. All the patients were controlled by conventional or radionuclide cystograms sixth months later.

RESULTS: VUR had been demonstrated in %98 ureters. We have found grade 2 VUR on the contralateral ureter in two patients with unilateral VUR, during preoperative direct cystography in the operating room. Preoperative direct cystography did not show the left grade one VUR in one patient with a bilateral VUR diagnosed by conventional cystography. VUR had been disappeared in all patients after the subureteric injection. The success rate was decreased from 100% to 85.2% after sixth months postoperatively.

CONCLUSION: VUR can be demonstrated under general anesthesia. Postoperative direct cystography do not affect the efficacy of the treatment. Failure in subureteric injection treatment is due to migration or decreasing supporting properties of the injected material in long term follow up, rather than insufficiency in surgical technique.

P034 THE NEW SURGICAL CONCEPT FOR HYDROCELE OF THE CORD OR SCROTUM IN CHILDREN: BASED ON EXPERIENCE OF 701 LPECs

Hiroo TAKEHARA MD, Yusuke Arakawa MD, Hiroki Ishibashi MD, Department of Pediatric Surgery and Pediatric Endosurgery, Tokushima University Hospital

Hydrocele of the cord or scrotum is a common condition in infancy that usually presents at birth. In most children with hydrocele, the processus vaginalis closes and the hydrocele resolves during the first 12-18 months of life. The recommended management of hydrocele is therefore to observe the patient without surgery for the first 2 years of life. We have performed 701 LPECs (laparoscopic percutaneous extraperitoneal closure method) in 505 children with inguinal lesions (438 cases with inguinal hernia, 67 cases with hydrocele of the cord or scrotum). There were no occurrences of hydrocele after LPECs for 634 hernias. Of these 67 patients, 33 (2-15 years of age) had communicating hydrocele, 34 (1-9 years of age) had noncommunicating hydrocele including 4 with abdominoscrotal hydrocele.

The laparoscopic correction of hydrocele involves high-circuit suturing of the processus vaginalis, as in LPEC for inguinal hernia. The distal part of the noncommunicating hydrocele is left open laparoscopically via the internal inguinal ring, or a percutaneous puncture, or a small incision in the scrotum. No recurrence was observed in 33 communicating hydroceles treated with LPEC. Of 34 noncommunicating hydroceles treated with LPEC and additional drainage, one abdominoscrotal type complicated with thickened wall of hydrocele developed to recurrence because of insufficient celotomy for concealed hydrocele.

These results suggest it is unnecessary to dissect the processus vaginalis and hydrocele from the spermatic cord and vessels via trans-inguinal canal. The advantages of this strategy are not only simple and minimally invasive closure, but also a lower risk of injury to the spermatic duct or vessels and complete closure of the communication between the peritoneal cavity and the hydrocele to a greater or lesser degree.

P035 STENTING IS UNNECESSARY IN LAPAROSCOPIC PYELOPLASTY

Lars J Cisek MD, David R Roth MD, Edmond T Gonzales MD, Eric A Jones MD, Texas Children's Hospital, Baylor College of Medicine

INTRODUCTION: Laparoscopic pyeloplasty typically employs a stent across the anastomosis. Several problems are associated with stents: irritative bladder symptoms, stent pain/colic, migration, and an obligate removal procedure. As stentless open pyeloplasty demonstrates equivalent results to stented procedures, we examine stentless laparoscopic pyeloplasty.

METHODS: For over 3 years we used stentless laparoscopic pyeloplasty in all primary ureteropelvic junction obstruction (UPJO) cases where a stent was not already present. Three 3 to 5 mm ports were used in a transperitoneal approach to the UPJO. 6-0 and 5-0 absorbable monofilament sutures were placed intracorporeally, avoiding handling of the dependent portion of the UPJ (?no touch technique?). A JP drain was placed around the anastomosis and the region was ?retroperitonealized?. The comparison group represents our experience with stented laparoscopic pyeloplasties.

RESULTS: 51 patients, ages 9 months to 64 years (median 8.6), were treated. There were no operative failures, with follow up 3 to 41 months (mean 17m). One patient required stenting for a leak with absent drain output. Another had a stent then a nephrostomy placed for clot colic. In comparison to 54 stented cases, no difference in hospital stay or in hospital narcotics use was noted. 2 stented case had nephrostomy tubes placed ? one for stent migration, one for anuria in a solitary kidney. Stentless cases did not need postoperative anticholinergics, and required less time to resume full activity. There were 8 symptomatic postoperative urinary infections in stented patients despite prophylactic antibiotics. A single stented patient represented with a solitary Deitel's crisis episode at 31 months ? evaluation including diuretic renogram and retrograde pyelogram which failed to define an obstruction, he has stable grade 2 hydronephrosis (originally grade 3), and no history of urolithiasis.

CONCLUSION: Laparoscopic pyeloplasty can be effectively performed without a stent affording reduced postoperative morbidity.

P036 PRONE RETROPERITONOSCOPIC HEMINEPHRECTOMY

Lars J Cisek MD, Edmond T Gonzales MD, David R Roth MD, Eric A Jones MD, Texas Children's Hospital / Baylor College of Medicine

INTRODUCTION: Several minimally invasive approaches are used to access the kidney for heminephrectomy. We have favored a prone retroperitoneoscopic approach. We report our cumulative experience with prone retroperitoneoscopic heminephrectomy.

METHODS: Over the past 6 years prone retroperitoneoscopic heminephrectomy (9) or heminephroureterectomy (61) was employed in 68 patients removing 61 upper poles and 9 lower pole moieties. Indications included non function or limited function in the setting of reflux nephropathy, dysplasia, ureteropelvic junction obstruction, ureterovesical junction obstruction (ureterocele), or ureteral ectopia. For the surgery patients are positioned prone, supported to allow the abdomen to fall anteriorly. Access is gained below the 12th rib, just lateral to the sacrospinalis, using a Visiport. The retroperitoneal space is created under direct vision using a 10mm telescope and insufflation. Two working ports are placed, one above the iliac crest and another in the midflank. The hilum(s) is dissected free to visualize and assign polar vessels; those serving the target moiety are divided. The ischemic demarcation and collecting system are used to guide removal of the dysfunctional pole using a harmonic scalpel. A ureterectomy when performed, uses the same port configuration, stripping all tissue from the appropriate ureter to the posterior aspect of the bladder or a common wall.

RESULTS: Patients ranged from 2 months to 36 years in age. All cases were completed laparoscopically. There were no intraoperative complications. Small peritonotomies were recognized in 16 cases; this did not compromise the procedure though slows distal ureteral dissection. Median operative time was 2hr 5min for heminephrectomy, 2hr 42 min for heminephroureterectomy. Maximum blood loss was 75 cc. Median hospitalization was less than 1 day. Fever delayed discharge in 9 patients beyond day 2. No secondary procedures were required. Routine imaging with an ultrasound was performed at 1 and 6 months for compromise of the remaining moiety and to exclude leak/fluid accumulation. No late complications were identified.

CONCLUSION: The prone retroperitoneoscopic approach to renal surgery offers a reliable efficient approach for heminephrectomy in children.

P041 LAPAROSCOPIC RETRIEVAL OF POST-APPENDECTOMY RETAINED FECALITH IN THE PEDIATRIC POPULATION

Christopher J Abularrage MD, David A Bruno MD, Sara Bloom MD, Anna Goldfarb MS, Joseph J Abularrage MD, A. Alfred Chahine MD, Georgetown University Hospital, New York Hospital Queens, Childrens National Medical Center

BACKGROUND: Appendectomy remains one of the most common operations performed by pediatric surgeons. Since the first report in 1963, retained appendicolith leading to intraabdominal abscess formation after operative management of acute appendicitis has been reported 25 times in the literature. Median time to diagnosis of the retained fecalith was 3 months. Laparoscopic drainage of the abscess and retrieval of the fecalith has been reported 5 times, but none in the pediatric population. We present two children with retained fecaliths which were successfully retrieved laparoscopically.

CASE #1: A healthy 10-year old male presented with two left lower quadrant intraabdominal abscesses and a retained fecalith 7 days after previous open appendectomy. He underwent CT-guided percutaneous drainage of the abscesses and treatment with intravenous antibiotics. One week after discontinuation of antibiotics, he presented with recurrent abscesses around the retained fecalith. The patient underwent laparoscopic exploration revealing an abscess containing a retained portion of the appendix with appendicolith between the anterior abdominal wall and loops of small bowel, as well as the rectum and mesorectum. The abscess was dissected free from the rectum and mesorectum en bloc and excised. The patient was discharged home on oral antibiotics after an uncomplicated hospital course and is doing well fifteen months postoperatively.

CASE #2: A previously healthy 3-year old female presented with right lower quadrant and pelvic abscesses around a retained fecalith 10 days after previous laparoscopic appendectomy. After failed transrectal drainage of the abscesses, the patient was brought back to the operating room for laparoscopic retrieval of the fecalith. After an extensive adhesiolysis, blunt hydrodissection between a confluence of the ileum, cecum, and rectum revealed the fecalith within the abscess cavity. The fecalith was removed with cupped pituitary forceps. After an uncomplicated postoperative course she was discharged on oral antibiotics. One month postoperatively she is without abdominal pain and tolerating a regular diet.

CONCLUSION: Retained fecalith after appendectomy is an uncommon complication frequently associated with intraabdominal abscess. Review of the world literature did not reveal any report of successful treatment without retrieval of the fecalith. Laparoscopic retrieval offers advantages of enhanced visualization of the abdomen, improved cosmesis, and a quicker return to normal daily activities. To our knowledge these are the first two reported cases of laparoscopic retrieval of a retained fecalith in the pediatric population.

P043 LAPAROSCOPIC EVALUATION FOR BILATERAL HERNIA IN CHILDREN

Amir Vejdani MD, Immam Reza's Hospital

BACKGROUND: Near 150 children hernia's operations was performed each year in our ward. One of the major concern is that the hernia unilateral or hidden bilateral? We approach and treat this problem with laparoscopic surgery.

METHODOLOGY: Elective open surgery was performed for 143 patients that suffer from unilateral inguinal hernia. After dissection of Cord and Hernia's sac, we perform diagnostic laparoscopy for the other side simultaneous hidden hernia. If we encounter the open internal ring, then we close it with a simple non-absorbable nylon suture.

RESULTS: In 12% of them, the other side sac was opened. (It doesn't certain that every open sac can produce a real inguinal hernia). After one year conservation, no complication has ever seen.

RECOMMENDATIONS: Laparoscopic diagnosis and treatment of hidden contra-lateral hernia is a good, safe and rapid method for preventing of the future hernia occurrence

P044 RISK FACTORS FOR BILATERALITY OF INGUINAL HERNIA IN CHILDREN AND THE EFFECT OF CHOICE OF LAPAROSCOPIC TECHNIQUE ON BILATERAL REPAIR

R N Haricharan, C J Aprahamian, T L Morgan, K E Georgeson, D C Barnhart, University of Alabama at Birmingham, Birmingham, USA

PURPOSE: The goal of this study was to identify risk factors for bilaterality of inguinal hernia (IH) and to assess if the laparoscopic examination technique affected the occurrence of contralateral repair.

METHODS: All children <2 years who had an IH repair between December 1999 and September 2005 were reviewed. Demographic, operative and follow-up data on metachronous hernia were collected. Chi-square and logistic regression were used.

RESULTS: 678 children were operated by surgeons who used laparoscopic examination for unilateral symptomatic IH. 210 children had clinically apparent bilateral IH. Risk factors associated with bilaterality included: right sided hernia (OR =1.7, 95% CI 1.2-2.4), preterm (<37 weeks) (OR= 3.2, 95% CI 2.3-4.4), and age (OR 0.98 for each additional week, 95% CI 0.97-0.99). 468 (70%) children presented with unilateral IH and underwent laparoscopic examination. Results are summarized below (bilateral exploration, metachronous hernia, odds ratio for bilateral repair). After controlling for preterm birth, age, gender, laterality and surgeon, there was no difference in the occurrence of bilateral exploration or metachronous hernia by laparoscopic technique used. This sample had an 80% chance of detecting a 14% change in prevalence of bilateral repair.

CONCLUSIONS: Preterm birth, younger age, and right-sided unilateral symptomatic hernia are associated with an increased risk of bilaterality. Bilateral hernia repair is not associated with the technique used for laparoscopic examination. Metachronous hernia after prior normal laparoscopic examination occurs infrequently.

| | HERNIA SAC | UMBILICUS | DIRECT VIEW |
|----------------|-------------|-----------------|-----------------|
| N | 194 | 106 | 168 |
| Bilateral | 33%(26-39%) | 29%(21-38%) | 40% (33-47%) |
| Metachronous | 1% (0-2.4%) | 2.8% (0-6%) | 1.2% (0-2.8%) |
| OR Bil. Repair | ref. (OR=1) | 0.87(0.42-1.84) | 1.45(0.55-3.86) |

P045 LAPAROSCOPIC SURGERY FOR CHOLEDOCHAL CYSTS IN CHILDREN

Francisco José Berchi Garcia PhD, Indalecio Cano Novillo MD, Araceli Garcia Vazquez MD, Hospital 12 de Octubre, Madrid, Spain

BACKGROUND: Choledochal cyst resection and hepaticojejunostomy have historically been performed using an open technique. Nowadays, minimally invasive surgery (MIS) has evolved into a safe alternative for the treatment of complex biliary disorders.

METHODS: We present two patients operated of choledochal cyst with laparoscopic excision of a choledochal cyst with Roux-Y-biliary reconstruction. All procedures were performed with 5 trocars using 3- and/or 5 mm ports. Excision of the cyst was performed laparoscopically in all cases. The Roux-Y-limb was created through a 1 cm extension of the umbilical port site in one case and intracorporally in other case.

RESULTS: Mean length of surgery was 260 minutes; hospital stay were 5 and 4 days respectively. There were no postoperative complications. Cosmetics was excellent in all cases. As follow up both patients were anicteric and asymptomatic.

CONCLUSION: Laparoscopic resection of choledochal cysts can be performed safely in pediatric patients with minimal morbidity and good long-term results. It requires advanced skills and expertise for precise dissection and meticulous suturing in restricted spaces.

P046 LAPAROSCOPIC MANAGEMENT OF DUODENAL OBSTRUCTION IN NEWBORN, EXPERIENCE IN 6 CASES AND THEIR OUTCOME

Hossein Allal MD, Rene Carmona-Barba MD, Manuel Lopez- Paredes MD, René B Galifer MD, Hopital Lapeyronie. CHU Montpellier.

METHODS: Newborns from August 2002 to August 2005 with duodenal obstruction were included, with antenatal or postnatal diagnosis, in antenatal cases surgery was done after birth, and in postnatal after the diagnosis. All surgeries were done when the patients were stable, a laparoscopy approach were done, and a duodenum-duodenal anastomosis or duodenum plasty were done, a bowel x ray transit was done at 3 months after surgery, they were followed 1 year after the surgery

RESULTS: Six new born from 1 to 7 days were included; gestation age from 36 to 39 Weeks, mean weight 2400gr; Associated anomalies found: Down syndrome, cardiopathy and esophageal atresia with distal fistula, the diagnosis was antenatal in four newborns and postnatal in two. The Surgery was done by laparoscopy, with 5 trocars, and a 5 mm optic 30 degrees angle, no conversions were done, a mean time of surgery was 140 minutes, Feeding began after 4 days. There were no complications, No signs of obstruction were found clinically one year later

CONCLUSION. Today it is possible to perform a laparoscopic surgery in newborns even with several malformations, we can offer a better approach by laparoscopy in newborns and be awarded with prenatal diagnostic at the moment of deliver. The experience in laparoscopy procedures is necessary with the integration of human sources and infrastructure for develop this technique, and obtain better results. And a better outcome in our patients.

P047 LAPAROSCOPICALLY INSERTED BUTTON COLOSTOMY AS A VENTING STOMA AND ACCESS PORT FOR THE ADMINISTRATION OF ANTEGRADE ENEMAS IN AFRICAN DEGENERATIVE LEIOMYOPATHY

C Lazarus, M Chitnis, V Breckon, M Elsen, I Simango, Eastern Cape Paediatric Surgical Service, East London, South Africa

BACKGROUND: African Degenerative Leiomyopathy, an uncommon condition affecting children of Southern, Eastern and Central Africa, manifests as gross gaseous abdominal distension, an inability to evacuate flatus and faeces, anorexia and malnutrition with death in adolescence or early adult life. Colonic volvulus complicates the clinical picture. The leiomyopathy primarily affects the rectum and colon but the entire GIT is involved.

PATIENTS AND METHODS: We have placed a MIC-KEY skin level device (button) laparoscopically as a colostomy in four children with this disease using a technique similar to that described by Georgeson for the placement of a gastrostomy button. However as the colon is involved, four holding U sutures instead of two are used to secure the colon to the abdominal wall. Having established a pneumoperitoneum, the colon is inspected, volvulus excluded and the four U sutures placed to hold the colon to the upper abdominal wall. An intravenous cannula is then passed through the abdominal wall into the distended transverse colon. A guide wire is passed through the cannula; the cannula is removed, the track progressively dilated before placing a MIC-KEY button (usually 18Fr by 1.2cm) over the guide wire into the colon. Decompression of the colon and the instillation of antegrade enemas through a size 8 feeding tube passed through the button commences on the 4th postoperative day. Decompressions are done as necessary and antegrade enemas or washouts done once a day.

RESULTS: The button colostomy has successfully been placed laparoscopically in all four patients. All have experienced significant symptomatic relief due to their ability to decompress the colon using this technique. All have regained their appetite and have demonstrated nutritional improvement. There have been no operative or post operative complications due to the procedure nor any difficulties in using the button for the purpose intended. Minor peristomal skin excoriation has occurred in one patient.

CONCLUSION: As a means of palliation, the laparoscopic insertion of a button colostomy provides a simple yet effective means of decompressing the colon and of instilling antegrade enemas in patients with African Degenerative Leiomyopathy. The quality of life of the four patients has improved remarkably with minimal morbidity.

P048 PRIOR U-STITCH GASTROSTOMY DOES NOT COMPLICATE SUBSEQUENT LAPAROSCOPIC FUNDOPPLICATION IN PEDIATRIC PATIENTS

O Kleiner, R N Haricharan, T L Morgan, C J Aprahamian, K E Georgeson, D C Barnhart, University of Alabama at Birmingham, AL, USA

PURPOSE: Laparoscopic fundoplication is sometimes undertaken after gastrostomy tube placement in pediatric patients. In such cases, it is a commonly held view that the gastrostomy usually has to be mobilized to facilitate laparoscopic Nissen fundoplication. The purpose of this study was to assess the necessity of such a maneuver during laparoscopic Nissen fundoplication in children with existing laparoscopic U-stitch gastrostomy.

METHODS: After IRB approval, all children with primary laparoscopic U-stitch gastrostomy between January 2000 and October 2006 in a tertiary care children's hospital were reviewed. Demographic, clinical, operative and hospitalization data were collected on all children who subsequently underwent fundoplication.

RESULTS: Laparoscopic U-stitch gastrostomy without fundoplication was performed in 131 children during the study period. Of these, 20 (9 boys) underwent laparoscopic Nissen fundoplication subsequently, at a median age of 1.7 (0.1-14) years. The median duration between gastrostomy and fundoplication was 265 (range 19-755) days. Prior to gastrostomy 17 (85%) had failure to thrive, 16 (80%) had feeding difficulty, 6 (30%) had swallowing dysfunction and 3 (15%) had occasional vomiting. Subsequent fundoplication was prompted by complaints of persistent vomiting (14, 70%), failure to thrive (9, 45%), and pulmonary complications (9, 45%). All fundoplications were completed laparoscopically and none of the gastrostomies were taken down. The overall fundoplication mean(SD) operative time -108(±37) minutes was similar to that for the laparoscopic fundoplication on children without prior gastrostomy performed at our institution (mean -113 minutes). The median length of stay after fundoplication was 3 days (2-11days). The port locations were similar to those in patients without gastrostomy. During a median follow up of 16 months post-fundoplication, only 1 patient underwent gastrostomy revision 5 days after fundoplication secondary to malpositioning of the tube. No other complications requiring operative intervention were noted. No patient required revision of fundoplication. There were no fundoplication related deaths.

CONCLUSIONS: Prior U-stitch gastrostomy does not complicate subsequent laparoscopic fundoplication in pediatric patients. Laparoscopic Nissen fundoplication can be done without routinely taking down the previously placed U-stitch gastrostomy.

P049 WOUND INFECTION AFTER PEDIATRIC LAPAROSCOPIC APPENDECTOMY IS UNRELATED TO METHOD OF SPECIMEN RETRIEVAL

Claudia M Mueller MD, Chad Wiesenauer MD, Anthony de Buys Roessingh MD, Dickens St. Vil MD, Hospital Ste-Justine, Montreal, Quebec, Canada

Wound infection, in particular at the umbilical trocar site, is a well-known complication following laparoscopic appendectomy. In order to reduce the risk of wound infection, retrieval devices, ranging from commercial bags to the fingers of sterile gloves, have been used to extract the inflamed appendix. However, the specimen may also be removed directly via the umbilical trocar. We decided to examine whether the removal of the appendix via the umbilical trocar without the use of a retrieval device would increase the rate of postoperative wound infection at this site. At our institution 144 pediatric patients underwent appendectomy (128 laparoscopic) between June 2006 and January 2007. In the majority of cases (83%), the appendix was removed directly via a 10-mm umbilical trocar without a protective retrieval device; an Endocatch bag was used for specimen retrieval in the remaining cases. 4.1% of patients presented with wound infections at the umbilical trocar site after laparoscopic appendectomy. No significant relationship was noted between the likelihood of wound infection and the method of specimen retrieval (chi square=0.4, p>.05). In addition, perforation of the appendix and length of antibiotic therapy were unrelated to the rate of wound infection. In sum, the removal of an infected appendix via the umbilical trocar without a retrieval device does not appear to increase the rate of wound infection in pediatric patients. We attribute this finding to the fact that sufficient care was taken to avoid contact between the specimen and the skin and subcutaneous tissue during direct extraction.

P050 MODIFIED LAPAROSCOPIC HILL GASTROPEXY IN THE TREATMENT OF GERD IN PEDIATRIC AGE PRELIMINARY REPORT

S.F. Chiarenza MD, L. Costa MD, L. Fasoli MD, MG Scarpa MD, L. Musi, Dept Pediatric Surgery S. Bortolo Hospital Vicenza Italy

INTRODUCTION: The open Hill repair for gastroesophageal reflux disease is an established and effective antireflux procedure used since 1960 (Hill, Ann Surg, 1967) in general surgery. This technique was modified and performed laparoscopically by Snow in 1990. In this paper we report on our preliminary experience on 10 pediatric patients who underwent laparoscopic Hill repair.

AIMS: The aims are: 1) to restore normal anatomical and physiological antireflux mechanism at the gastro-esophageal junction; 2) not to alter the normal cardiac anatomy; 3) to evaluate the feasibility of laparoscopic Hill technique in pediatric age; 4) to minimize, especially in neurologically normal patients, symptoms related to other traditional procedures such as fundoplication (Nissen, Toupet, etc).

METHODS: We performed modified laparoscopic Hill repair in 10 pediatric patients (1-6 years, average and median 3 yrs) requiring antireflux surgery for severe gastroesophageal reflux, associated with hiatal hernia. All patients underwent laparoscopic procedure with: 1) freeing of the abdominal esophagus; 2) retroesophageal cruroplasty; 3) posterior esophagocardiopexy down to the origin of the crura; 4) re-creation of the angle of His. Operative time ranged from 120 to 190 min. No mortality or serious intraoperative or postoperative complications have occurred. Discharge was usually at the 4th p.o. day. Patients re-started to eat solids after 2 weeks, only two patients complained of a mild dysphagia that lasted 15 and 25 days respectively.

RESULTS: Duration of follow up ranges from 6 to 18 months. All patients had an gastroesophageal contrast study 6 months after operation, while 4 patients underwent esophagogastroscopy 1 years after the procedure. No one had recurrence of reflux. At the moment all the patients are symptoms free, none of them has dysphagia, gas bloat syndrome or other related symptoms.

CONCLUSIONS AND DISCUSSION: Authors conclude from these preliminary results that laparoscopic Hill repair, already used in general surgery for gastroesophageal reflux, can be performed safely with excellent functional results in children, since it restores the normal anatomical and physiological antireflux mechanism and especially because it minimizes the risks of dysphagia and/or gas air bloat syndrome or others symptoms related to other procedures such as fundoplication (Nissen, Toupet, Thal etc). The technique is still young and the number of operated patients is limited, so its final evaluation is not possible until long-term results are available

P051 LAPAROSCOPIC ASSISTED ENDO-ANAL PULL-THROUGH FOR HIRSCHSPRUNGS DISEASE

A Numanoglu MD, E Leva MD, D Sidler MD, H Rode MD, AJW Millar MD, Universities of Cape Town and Stellenbosch, Cape Town, South Africa and Buzzi Children's Hospital, Milan, Italy

AIM: The surgical management of Hirschsprung's disease has preferentially changed to a laparoscopically assisted single stage procedure in the neonatal period. We report our experience with laparoscopic assisted endo-anal pull-through with 11 consecutive neonates and infants.

PATIENTS AND METHODS: From 2000 to 2006 6 male and 5 female patients underwent laparoscopically assisted pull through procedure by using 3 ports. Extramucosal biopsies were taken from above the peritoneal reflexion, the transition zone and the proximal dilated segment. Frozen sections confirmed the normal ganglionic level. The harmonic scalpel or hook diathermy was used for dividing the mesentery. Endo-anal pull-through was performed starting at the extramucosal layer at the dentate line with extension to peri-rectal plane 1.5-2cm above the dentate line.

RESULTS: The mean age was 71 days (r=15-197) and the mean weight was 4333 grams (r= 3060-7880) at surgery. Operative time was 155 minutes (r= 107-260) with minimal blood loss. There was 1 conversion early in the series due to mesenterial bleeding. Recovery from surgery was quick and full feeds were established on day 3 (r=2-7). They were discharged from hospital on day 4 (r=2-9). One patient developed enterocolitis before surgery. At 20 months (r=1-72) follow-up 9 patients had established a normal stooling pattern (2-6 stooling /day), 2 patients had temporary stenosis and one patient had constipation. These complications improved on treatment. There was no mortality.

CONCLUSION: Laparoscopic assisted endo-anal pull through resulted in rapid recovery and avoids the need of a 2 stage procedure. The operation is ideally suited for recto-sigmoid Hirschsprung's disease.

P052 COMBINED ENDOSCOPIC AND LAPAROSCOPIC PROCEDURES IN CHILDREN

Olivier Reinberg MD, Faiza Benkebil MD, Andreas Nydegger MD, Department of Pediatric Surgery (1), Pediatric Unit of Gastroenterology, University Hospital of Lausanne (CHUV), Switzerland

AIMS: Several combined laparoscopic and endoscopic procedures have been described in adults but not in children. The aim of this study is to report our experience in children and to assess the usefulness of these procedures.

PATIENTS AND RESULTS: Since 1999, 11 patients ranging from 2.4 to 14.2 years of age were treated by combined endoluminal and endocavitary approaches. They included 2 assisted gastrostomies, the laparoscopy helping the PEG procedure to avoid a colonic perforation; 3 redo laparoscopic Heller procedures to assess by endoscopy the level of the myotomies; 2 endoluminal removals of large jejunal polyps far below the ligament of Treitz and thus inaccessible for conventional endoscopy; 1 localization of bleeding site and treatment of ileal vascular dysplasia; 1 combined laparoscopic coagulation and endoscopic injection of a very severe rectal vascular Klippel-Trenaunay malformation; by combining laparoscopic mobilization of the bowel with colonoscopic polypectomy, previously inaccessible large polyps could be snared in 2 patients. All the combined surgical procedures were performed successfully without conversion. A precise timing of the procedure and the use of long atraumatic clamps is mandatory to avoid bowel distension due to endoluminal insufflation. If a perforation should occur, diagnosis could be immediately done and subsequent suture or resection achieved by laparoscopy.

CONCLUSION: Combined endoluminal and endocavitary approaches to bowel lesions are feasible and appear to have several advantages in children. The described procedure increases the safety of the otherwise difficult polypectomy and also avoids laparotomy with enterotomy or bowel resection as the alternative.

P053 CARDIOMYOTOMY MODIFICATION OF HELLER-DOR PROCEDURE FOR PEDIATRIC ACHALASIA

William A Ross MD, Juan Camps MD, Department of Surgery-University of South Carolina, Palmetto Health Children's Hospital

Achalasia is a rare illness in the pediatric population. Operative interventions have shown great promise for the treatment of this entity. Nonetheless, it is not without complications. Esophageal perforation and reflux are the most feared, which may lead some surgeons to perform inadequate esophagocardiomyotomies and excessively tight wraps. Post-operative dysphagia can occur in as many as 1 in 6 patients in some published series. Many speculate that this is a result of an inadequate esophagocardiomyotomy. We suggest that scarring and subsequent contracture of the esophagocardiomyotomy may contribute to this recurrent dysphagia. In our patients, the margins of the myotomy are affixed to the diaphragmatic crura as are the gastric leaflets of the fundoplication. This technique may keep the myotomy edges apart and prevent reapposition. Of ten patients who received this operation, only 1 has required reoperation (early-within 6 months) for dysphagia symptoms, ascribed to excessive wrap tension and esophageal rotation. The patient responded to a relaxation of the wrap and the symptoms remitted. Another patient had mild GERD, responding to simple dietary modification. Of note, this patient with GERD presented to us for revision of a previous Heller-Dor Procedure. The remaining patients are without reported complications, some having been followed for nearly 4 years. Results are encouraging so far, and it seems intuitive that maneuvers to lessen post-procedure stricturing of the myotomy would tend to prevent recurrent dysphagia. Future directions will include endoscopic and manometric evaluations of these patients.

P054 TEACHING PEDIATRIC LAPAROSCOPIC PYLOROMYOTOMY IN THE SKILLS LAB: A FELINE BOX TRAINER MODEL

Olga Achildi BA, Richard Milner BS, Harsh Grewal MD, Department of Surgery, Section of Pediatric Surgery Temple University School of Medicine and Temple University Children's Medical Center

INTRODUCTION: Hands-on experience in the operating room is an important part of surgical residency training. Limitations set forth by the duty hours requirements manifested in decreased overall time residents spend in the operating room. Hence, there has been a shift of learning to the surgical skills laboratory to increase trainees' familiarity with operative procedures. Such an approach has been particularly useful in learning laparoscopy. Although many models have been described for various laparoscopic procedures in adults, only a few exist for pediatric laparoscopy.

METHODS: We created a box training model for laparoscopic pyloromyotomy in infants using feline (cat) esophagus, stomach and duodenum, which are of similar size to the human infant's organs. A training box was created to match the average size of an infant abdominal cavity. The organs were harvested and secured to the floor of the training box in their correct anatomic positions. A checklist of steps for the procedure was created to simulate a realistic experience of the procedure, beginning with port placement and instrument insertion and concluding with instrument removal at completion of the pyloromyotomy. Surgical faculty and general surgery residents from Temple University Hospital were recruited for preliminary testing of the model.

RESULTS: The preliminary laparoscopic pyloromyotomy model testing was conducted successfully. Although no formal surveying was done, faculty and residents agreed that the model was realistic and helpful in gaining familiarity with the procedure. A structured study of our model's efficacy is to follow in the near future.

CONCLUSION: Surgical skills laboratory is a useful tool in preparing surgical residents for operative procedures. Animal models provide real tissue-handling experience, which is especially important in operative procedures performed on infants. Our laparoscopic pyloromyotomy model provides a good training experience for residents and may help reduce the risk of tissue damage, thus decreasing patient morbidity.

P055 THE LAPAROSCOPIC ABDOMINAL PROCEDURES HAVE A BETTER QUALITY OF RECOVERY THAN OPEN PROCEDURES

Eric Kim, Udaya Samarakkody MD, Department of Paediatric Surgery, Waikato Hospital, Hamilton, New Zealand, University of Auckland, Auckland, New Zealand

AIM: The laparoscopic surgery for elective abdominal procedures has been widely used to minimise post-operative pain and complications. However the literature on the comparison between the open and the laparoscopic procedures in relation to the recovery in children is lacking. The aim of this study is to compare the outcomes of elective paediatric laparoscopic abdominal procedures with age matched open surgery controls to determine the quality of recovery.

METHODS: The patients who received elective laparoscopic abdominal operations during the last seven years (2000-2006) were reviewed and each patient was compared with an age-matched control who received conventional open surgery. The operations that did not have age matched controls during the same period were excluded. ie. Cholecystectomy. The outcome parameters were the type and dose of analgesics, operating time, time to pass urine, time to open bowels, time to oral fluid, time to food, hospital stay and morbidity. The results were analysed using Microsoft Excel. The students t test was applied and a p value of <.05 was considered as statistically significant. The study was approved by the PQAA (Protected quality assurance activity) of the hospital board.

RESULTS: There were 50 laparoscopic operations which included Meckel's diverticulectomy, Freeing of adhesions, Fundoplication, Gastrostomy tube insertion, Pyloromyotomy and Splenectomy etc. There were 50 age matched controls. The operative time was longer in the laparoscopy group with a p value <.05. The need for analgesics were much less specially from 3rd post operative day onwards (p<.05) The time to oral fluids and solids were shorter in the laparoscopy group. The length of hospital stay and morbidity were comparable.

CONCLUSION: Our results suggest that elective laparoscopic abdominal surgery in infants and children have better quality of recovery. The morbidity and hospital stay are the same as conventional surgery. The operative time is longer in laparoscopic surgery. We are still in the learning curve and further experience will improve the outcome of the laparoscopic surgery.

(The authors wish to acknowledge and thank the Surgical Research Trust and Pumpkin Patch Ltd for support and funding for this research)

P056 LAPAROSCOPIC CHOLEDOCHAL CYST RESECTION; PRELIMINARY EXPERIENCE

Arturo Aranda MD, Yigit Guner MD, Nikunj Chokshi MD, Cathy Shin MD, Nam Nguyen MD, Childrens Hospital Los Angeles, University of Southern California and Long Beach Memorial Medical Center, Children's Hospital

BACKGROUND: Choledochal cysts disease is a rare biliary disorder, occurring in 1:100,000 to 150,000 in children. The principal treatment is total excision of the cyst and biliary-enteric reconstruction. Traditionally, the procedure is performed via a large open laparotomy. Recently, a few institutions have reported using minimally invasive techniques. In this study, we report our initial experience with the laparoscopic management of choledochal cysts.

METHODS: Retrospective review of all the patients who underwent laparoscopic excision of choledochal cysts and hepaticojejunostomy. The procedures were done utilizing 4 or 5 trochars. A Roux-en-Y jejunostomy was constructed externally via an umbilical incision for smaller patients and intra-corporeally in older patients. A retrocolic hepaticojejunostomy was established using absorbable monofilament sutures.

RESULTS: Between October 2003 and July 2006, laparoscopic cyst excisions were performed in 8 patients: 7 female, 1 male with a median age of 5 years (8 months to 16 years). Six were type I and two were type IV cysts according to Todani's classification. Average cyst size was 4.5 cm (1.3-8.5 cm). Three patients required conversion to open technique due to dense adhesions. The other 5 were successfully completed laparoscopically. Of these 5 patients, 4 had their Roux-en-Y constructed extra-corporeally and one intra-corporeally. The mean operative time was 4.4 hrs (1-7.5 hrs). There were no intraoperative complications. Average blood loss was 23 mL. Four patients had their cysts completely removed. One patient had an 8.5 cm cyst with dense adhesions that required combined cystectomy and mucosectomy. One patient had a bile leak, resulting in a hepaticojejunostomy revision. The other four had an uneventful recovery. Oral feedings were resumed on an average of 3.5 days (2-9 days). The average time to discharge was 5.8 days (5-12 days). Average follow up time was 1.7 years (4 months-2 years). No further radiographic or laboratory abnormalities were detected in any of the patients.

CONCLUSIONS: Laparoscopic resection of choledochal cysts and Roux-en-Y hepaticojejunostomy in children is feasible and can be a good option. However, it is technically challenging and requires a steep learning curve. More studies are needed to further validate this approach.

P057 POSTCHOLECYSTECTOMY SYNDROME AFTER LAPCHOLE IN CHILDREN

Faiz U Shariff, Haitham Dagash, Edward M Kiely, David P Drake, Agostino Pierro, Joseph Curry, Great Ormond Street Hospital NHS Trust

AIMS: The reported incidence of post cholecystectomy syndrome following laparoscopic cholecystectomy in adults is quoted as high as 30% . Our aim was to investigate the incidence of this phenomenon in children.

METHODS: A retrospective case note study was carried out on all children presenting to our institution for laparoscopic cholecystectomy, from November 1999-March 2006. Demographic data, indication for performing the procedure, operating time, length of hospital stay and overall complications were recorded.

RESULTS: There were a total of 25 children who underwent laparoscopic cholecystectomy (6 also had splenectomy performed) during the study period. There were 14 boys and 11 girls with a mean age of 10.4 years. Twenty four patients had gallstones noted on US and 1 patient had biliary dyskinesia. The underlying diagnoses were cholelithiasis of unknown origin (n=13), hereditary spherocytosis (n=7), congenital enteropathy (n=2) and 1 case each of biliary dyskinesia, sickle cell disease and familial hypercholesterolemia. Mean operating time was 169 minutes. The mean length of stay was 3.5 days. We had no intraoperative complications. There were no conversions. Two patients preoperatively were found to have CBD stones and underwent ERCP. At a mean follow-up of 18.3 weeks, 4 patients complained of mild RUQ pain. In all cases this pain resolved within 3 months.

CONCLUSION: The incidence of post cholecystectomy syndrome is 10% (4/25) but resolves completely within 4 months and this appears different from the adult experience. This information will prove useful when counseling parents.

P058 LAPAROSCOPIC TOTAL COLECTOMY IN CHILDREN

Rahsan Vargun-Yildiz MD, Esra Temeltas MD, Bilal Alper MD, Berkutug Bahadir MD, Gulnur Gollu MD, Aydin Yagmurlu MD, Department of Pediatric Surgery, Ankara University School of Medicine

AIM: Laparoscopic total colectomy is technically challenging and requires advanced minimally invasive surgical skills, technology and expertise. With this presentation, it was aimed to describe technical details, critical steps and results of laparoscopic total colectomy.

PATIENTS AND METHODS: Demographic data, indication of total colectomy, operative time, hospital stay, early and late complications were investigated and technical details and critical steps of the procedure were described.

RESULTS: Laparoscopic total colectomy was performed successfully in three children. Mean age was ten years. Indications of total colectomy were familial polyposis coli (n=1), ulcerative colitis (n=1) and Crohn's disease (n=1). The procedure was completed using five 5mm. trochars. The entire dissection and division of the mesentery was accomplished with the 5-mm laparoscopic

Ultracision (Ethicon Inc.) device. After a transanal mucosectomy, ileum was delivered through anus and ilioanal anastomosis was completed. No preventive ileostomy was performed. Mean operative time was 200 minutes. Mean hospital stay was 12 days. There were no intraoperative and early postoperative complications. Laparoscopic-assisted ileostomy was performed in one child due to refractory perianal dermatitis after two months.

CONCLUSION: Laparoscopic total colectomy is technically feasible in children. The need for a protective ileostomy remains controversial. Construction of a J-pouch is difficult to perform.

P059 IS IT RIGHT TO PLACE ULTRASOUND-BASE DECISION MAKING AT THE FOREFRONT OF THE EVALUATION OF SUSPECTED APPENDICITIS?

Baran Tokar MD, Dilsad Demet MD, Huseyin Ilhan MD, Mahmut Kebapci MD, Ragip Ozkan MD, Eskisehir Osmangazi University, School of Medicine, Department of Pediatric Surgery and Radiology, Eskisehir, Turkey

BACKGROUND: Developing technology and experience made some pediatric surgeons place ultrasound (US) at the forefront of the diagnostic evaluation of suspected appendicitis. In atypical cases, US may help lower the false-negative diagnosis and reduce morbidity. We performed a prospective study in atypical cases of acute abdomen to evaluate US effectiveness to diagnose appendicitis and how US correlates with clinical findings and follow up.

METHODS: Between March 2005-December 2006, 94 children admitted with nonspecific abdominal pain were included in the study. The patients were evaluated according to the history, physical examination, laboratory tests, abdominal plain-X ray and abdominal US. Standardized data-collection forms were collected. On admission, depending on the clinical findings excluding US, patients were placed in one of the three groups. In group I (n=21), patients were only evaluated in emergency department and not hospitalized due to minor findings; in group II (n=51) patients were hospitalized and observed, but not operated; in group III (n=22) patients were hospitalized and laparoscopic exploration performed. In group I and II, US was repeated in all patients to determine the progress of US findings.

RESULTS: In group I, no surgical pathologies were determined and US correlated with other clinical findings. Only significant finding was mesenteric lymph nodes in the right lower quadrant in 9 patients (43%). In group II, US showed mesenteric lymph nodes in the right lower quadrant in 17 (33%), ovarian cysts in 11 (21.6%), renal stones in 2 (4%), spontaneously reduced invagination in 2 (4%), and findings suggestive of appendicitis in 13 patients (25.5%). Since other clinical findings didn't significantly support the diagnosis, none of the patients with positive US findings of appendicitis were operated in this group. US follow up showed a progressive resolution of findings in those patients. In group III, preoperative US and laparoscopic exploration showed simple large cyst in 2 patients, torsion of adnexa in other two. Appendicitis shown by US and supported by clinical findings was confirmed by laparoscopy in 15 patients, negative exploration was in one patient. US missed the diagnosis of phlegmonous appendicitis in one patient.

CONCLUSIONS: Since it is a noninvasive procedure, US could be considered in evaluation of suspected appendicitis, but traditional history, physical examination and laboratory test should be at the forefront of the diagnostic evaluation. In suspected cases, if clinical findings do not significantly support the US, observation and follow up US should be considered.

P060 SAFETY, DIAGNOSTIC YIELD AND THERAPEUTIC POTENTIAL OF DOUBLE BALLOON ENTEROSCOPY IN THE SMALL BOWEL IN CHILDREN

B Antao MD, K Venkatesh MD, M Trotter MD, W Van Der Veer MD, M Mahony MD, R Heuschkel MD, F Torrente MD, R Sidhu MD, DP Hurlstone MD, D Sanders MD, M McAlindon MD, S Hodges MD, C Taylor MD, M Jacobs MD, M Thomson MD, Sheffield Children's NHS Foundation Trust, Sheffield, VU University Medical Center, Amsterdam, Limerick Hospital, Eire, Royal Free Hospital, London, Royal Hallamshire Hospital, Sheffield

BACKGROUND: The advent of flexible fiberoptic endoscopes transformed the diagnosis and management of gastrointestinal disorders in adults and children, allowing direct visualization with targeted mucosal biopsies. However, the small bowel distal to the ligament of Trietz has been to date inaccessible to conventional GI endoscopes. Double balloon endoscopy (DBE) is a recent modality, which enables high resolution endoscopic imaging of the entire small bowel.

METHODS: 8 patients (7 males) with a median age of 12.9 years (range 8.1-16.7) underwent DBE - 3 for Peutz-Jeghers syndrome (PJ syndrome), 2 for chronic abdominal pain, and 3 for obscure gastrointestinal bleeding. 5 patients received general anaesthesia and 3 received deep sedation.

RESULTS: The entire small bowel was examined in 5 patients. The rest had varying lengths of small bowel examined from approximately 200 to 320 cm beyond the pylorus. 3 patients had by both trans-oral and trans-anal routes. 1 had assisted intra-operative DBE. One had trans-oral and trans-ileal via ileal stoma. Polyps were detected in all three patients with PJ syndrome while 1 patient had tubulo-villous adenoma of the duodenum. Increased friability of the mucosa was noted in one patient. No abnormalities were found in 3 patients.

CONCLUSION: Double balloon enteroscopy is a useful diagnostic and therapeutic tool for the investigation of small bowel disease. It is useful in situations where diagnosis has not been reached by other investigative modalities and in those amenable for therapeutic intervention endoscopically but not reachable by the conventional endoscope

P061 LAPAROSCOPICALLY ASSISTED PERITONEAL SHUNT INSERTION IN CHILDREN WITH HYDROCEPHALUS

Mark Weinberg MD, Sergey Keidar MD, Liana Beni-Adani MD, Department of Pediatric Surgery and Neurosurgery, Dana Children Hospital, Sourasky Medical Center, Tel Aviv, Israel

BACKGROUND: Ventriculo-peritoneal shunting is the mainstay in the treatment of hydrocephalus in children. Repeated shunt revision and previous abdominal interventions are considered risk factors for shunt malfunction. Optimal distal shunt positioning may be facilitated by laparoscopic assisted insertion of the catheter.

MATERIALS AND METHODS: The procedure was performed in 14 patients, who underwent 16 operations (age 1-16 years). There were 8 girls and 6 boys. One or two port technique was used. The camera 3 or 5mm was inserted via open technique. Abdominal exploration with shunt insertion was carried out by surgical team including a pediatric neurosurgeon and a general surgeon, both present at the time of exploration. Indications for laparoscopy were: suspected distal shunt malfunction (8), abdominal infection (4), previous surgery (3), recurrent abdominal pain (2) and in 5 more than one indication. Successful insertion of the peritoneal catheter was carried out with visual documentation of site and patency of the distal catheter in all but one case with previously unknown peritoneal infection in a comatous patient. The laparoscopic approach enabled exploration in cases when abdominal collections, adhesions or other pathology were suspected. Five children required lysis of peritoneal adhesions or pseudocyst drainage. Two children were operated twice. The first patient had severe adhesions with multiple infected fluid collections on first operation, therefore temporary ventriculo-atrial (V-A) shunt was inserted. The second laparoscopy was done due to V-A shunt malfunction with successful insertion of distal catheter into abdominal cavity two month later. The other boy had second laparoscopy due to suspected appendicitis. Mean operative time for the laparoscopic procedure was 15 minutes. There were no complications related to laparoscopy.

CONCLUSIONS: Peritoneal shunt insertion using laparoscopic guidance in children after repeated shunting, previous abdominal operations or intraabdominal infection is strongly recommended. The described technique allows direct visualization of catheter insertion with its optimal positioning, lysis of peritoneal adhesions, exclusion of other abdominal pathology, thus providing subsequent shunt functioning.

P062 SINGLE PORT LAPAROSCOPIC APPENDECTOMY CONDUCTED SOLELY INTRACORPOREALLY WITH THE AID OF A TRANSABDOMINAL SLING SUTURE: RESULTS OF THE NEW TECHNIQUE

Oguz Ates MD, Gulce Hakguder MD, Mustafa Olguner MD, Feza M Akgur MD, Department of Pediatric Surgery, Dokuz Eylül University, Medical School, İzmir, Turkey

BACKGROUND/PURPOSE: Laparoscopic appendectomy (LA) is becoming popular for the treatment of acute and perforated appendicitis. Since LA has been described, it has been modified various times. We herein present the results of a new technique of LA conducted through a single port without exteriorizing the appendix to perform the operation.

MATERIALS AND METHODS: Single port LA was attempted in 62 patients (36 boys, 26 girls). Under general anesthesia, an 11 mm port with two 5 mm working channels or an 11 mm port through which 10 mm scope (0o) with a parallel eye piece and 6 mm working channel was inserted

through the umbilicus. The appendix was grasped and dissected from the surrounding tissues with a single dissector or grasper. With a percutaneously inserted suture from right lower quadrant into the peritoneal cavity, appendix was pulled towards the abdominal wall after passing the suture through the mesoappendix. After mesenteric dissection with hook cautery, the base of the appendix was ligated with 2-0 polyglactin using a fisherman knot. The appendix was withdrawn into the trocar and extracted from the abdomen together with the trocar.

RESULTS: Laparoscopic appendectomy was completed in 57 patients through a single port. A second port insertion was required in 5 patients. No perioperative and postoperative complications were encountered. Average duration of the procedure was 37 ± 3.6 minutes.

CONCLUSION: The unique method presented further improves minimal invasiveness of LA as a single port is used. Single port intracorporeal appendectomy procedure is a safe, highly minimal invasive procedure with excellent cosmetic results.

P063 DIAGNOSTIC CRITERIA FOR BILE STONES IN CHILDREN UNDERGOING LAPAROSCOPIC SURGERY

Martina E Pirker MD, Amulya K Saxena MD, Claudia Katschnig, Michael E Höllwarth, Department of Pediatric Surgery, Medical University Graz, Austria

BACKGROUND/PURPOSE: Common bile duct (CBD) stones represent a diagnostic and therapeutic challenge in pediatric age group. The aim of the study was to evaluate our management of children with suspected CBD stones and to develop an algorithm for the rational use of perioperative ERCP, MRCP and intraoperative cholangiography (IOC).

METHODS: Between 1999-2005, 38 children that had undergone laparoscopic cholecystectomy (CHE) were evaluated for preoperative findings suggestive for CBD stones, preoperative use of ERCP or MRCP, use of IOC and findings during surgery. A diagnostic and therapeutic algorithm for CBD stones was developed.

RESULTS: Twelve children (32%) had preoperative findings suggestive for CBD stones. Of the 7 children with elevated liver enzymes AND abnormal ultrasound findings, 6 (86%) were identified to have CBD stones. Five had preoperative ERCP which detected and successfully cleared stones in 3 patients. IOC identified CBD stones in 3 children, including one patient with a preoperative negative ERCP. Of the 5 children with either elevated liver enzymes OR abnormal ultrasound, only one stone in the cystic duct was identified by a gall bladder edema in the preoperative MRCP followed by IOC. Three children received preoperative MRCP and IOC was performed in 4. No retained stones were detected postoperatively.

CONCLUSIONS: Cases with high suspicion for CBD stones should undergo a preoperative ERCP followed by intraoperative cholangiography, if no stones could be found. In case preoperative findings are ambiguous, prevalence of CBD stones is low and we suggest MRCP or IOC as the diagnostic methods of choice.

P064 LAPAROSCOPIC HEMISPLENECTOMY USING RADIOFREQUENCY MONOPOLAR COAGULATION DEVICE

Pawel Nachulewicz PhD, Piotr Kalicinski PhD, Hor Ismail PhD, Dariusz Polnik MD, Weronika Kasprzyk, Adam Kowalski, Marek Szymczak, Department of Pediatric Surgery and Organ Transplantation, Children's Memorial Health Institute, Warsaw, Poland

Radiofrequency monopolar coagulation device is a powerful tool which lets to achieve a very efficient hemostasis during resection of parenchymal organs. The aim of the study is presenting the technique of laparoscopic partial splenectomy using radiofrequency monopolar coagulation device. Since 2005 we have performed 5 laparoscopic partial splenectomies. In all cases indication to surgery were splenic cysts with pole localization. In 3 patients the cysts were located in upper pole in 2 patients in lower pole. In all patients operations were completed laparoscopically. Pneumoperitoneum was induced using the Veress needle. The optic 10 mm port was located in umbilicus and three 10 mm working ports were inserted under the left costal margin. The attachments of the spleen were freed in accordance with the needs. In 2 patients the pole branches of the splenic artery and vein were dissected and divided with Ligasure device before resection. The needle electrode of radiofrequency monopolar coagulation (Cool-Tip -Tyco Healthcare) was introduced directly through the skin into pleural cavity and then the active part of it was inserted into the spleen. The spleen was alternately coagulated

with the needle and cut with harmonic hook in the line of the resection. If the pole artery and vein had been closed before coagulation, the procedure was quickly completed in the line of demarcation. If the circulation in the line of resection hadn't be stopped, the time needed to achieve full hemostasis was much longer. The part of the spleen with cyst was removed in 15mm plastic bag. The surface of the resection was additionally coagulated with the needle and in two patients also the argon beam coagulation was used. The postoperative period in all cases was uncomplicated. Control USG Doppler investigation in all cases revealed a good blood flow through spared spleen parenchyma. There were no long term complications related to operation. The time of observation is from 3 months to two years.

CONCLUSION: The radiofrequency monopolar coagulation device is a very powerful tool which lets for safe and effective partial laparoscopic resection of the spleen. If pathology of the spleen is located in the pole, its partial resection protect the patients, especially children, from short and long term complications of splenectomy.

P065 SURGICAL TREATMENT OF GASTRO-ESOPHAGEAL REFLUX IN CHILDREN

Alexander Razumovsky MD, Manap Alhasov MD, Victor Rachkov MD, Anatoliy Pavlov MD, Zoricto Mitupov MD, Russian State Medical University, Moscow, Russia. Filatov Children's Hospital, Moscow, Russia

The best results of surgical treatment gastro-esophageal reflux (GER) were received with Nissen operation. In last decade Laparoscopic Nissen Fundoplication (LNF) became a procedure of choice in children.

MATERIALS AND METHODS: Since 2001 in Filatov children's Hospital, Moscow, Russia 182 LNF wer performed in 168 children with GER. Meanage has made 4,7 years. 12 children has been previously operated Nissen fundoplication by open approach. In 23 % of cases weight of the child did not exceed 10 kg. Diagnostics GER and its complications carried out on the basis of the clinical data, radiological research, endoscopy and pH-monitoring. Estimation of results of treatment carried out by the following criteria: 1) intraoperation complications; 2) postoperative complication; 3) relapse of disease. Result of treatment counted positive at absence of clinical displays of disease, knocking over a reflux-esophagitis and GER according to pH-monitoring. Results of treatment are appreciated in terms from 6 months till 5 years.

RESULTS: After LNF the positive result that has allowed to achieve social adaptation of the child in a society was received from all children. There were no lethality. Average duration of operation was $68,3 \pm 30,2$ minutes. In 32 % of cases LNF supplemented esophageal hyatoplasty. And in 13 cases at huge hiatal hernias we perform resection of hernial suc and hyatoplasty. In 5 cases one-stage complex operations ? thoracoscopy clipping an open arterial duct and LNF ? were performed. Intraoperation complications were found in 6 (3,2 %) children (perforation of a stomach ? 2, wound of a spleen ? 2, pneumothorax ? 1, oppression of heart activity ? 1). Postoperative complications have developed at 8 (4,3 %) children (mediastinitis ? 1, disphagia ? 4, diarrhea ? 3). Relapse of disease was marked in 10 (5,4 %) patients. Intraoperation complications in 2 cases had demanded conversion to open operation. In all cases of relapse of disease was executed repeated LNF.

CONCLUSION. LNF is a radical method of treatment GER at children which has allowed to receive positive result after primary operation in 95,6 % of cases. Our data shows a possibility to perform LNF: a) in children, irrespective of age and weight of a body; b) in case of difficult defects gastro-esophageal transition, such as a large hiatal hernia; c) in case of relapse of the disease and complex associated anomalies.

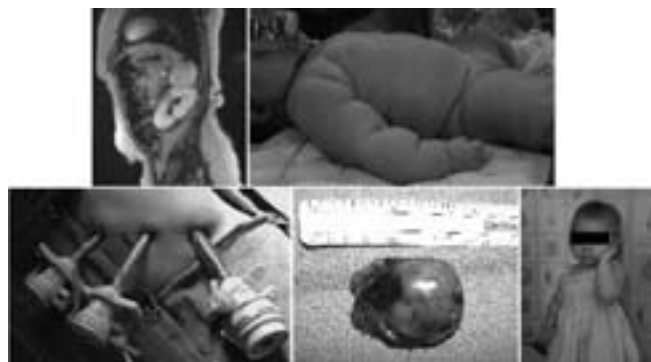EVALUATION & CME CREDIT FORMS

*Please complete the meeting evaluation form
and return to the registration desk.*

P066 LAPAROSCOPIC MANAGEMENT OF INFANTILE CUSHING'S SYNDROME

Philip A Omotosho MD, Kevin P Moriarty MD, Rajeev Prasad MD, Baystate Children's Hospital, Tufts University School of Medicine

Adrenocortical neoplasms are rare in infants, especially when compared to tumors of the adrenal medulla. The treatment of adrenocortical neoplasms is surgical resection. We report the case of a 7-month-old female who presented with cushingoid features, hypertension, and virilization. Laboratory studies demonstrated normal serum electrolytes, an elevated serum cortisol, and a low serum ACTH. Magnetic resonance imaging showed a 2.8 x 2.7 x 2.5cm well-circumscribed, left suprarenal mass. A transperitoneal laparoscopic left adrenalectomy was performed with subsequent resolution of the hypertension and stigmata of Cushing's syndrome. At 12-month follow-up the patient remains asymptomatic. Pathology revealed a 13.5g adrenocortical adenoma. A review of the literature is included.



P067 MIDGUT VOLVULUS AFTER LAPAROSCOPIC APPENDICECTOMY

João Henriques, Filipa Freitas, Paolo Casella, Hospital de Dona Estefânia

INTRODUCTION: A recent meta-analysis comparing laparoscopic appendicectomy (LA) versus open appendicectomy (OA) in children suggests that LA reduces the complication rate, specifically concerning surgical wound infection and postoperative ileus, with a similar operative time but with a significantly shorter postoperative length of stay. Intestinal obstruction, in patients who had previous surgery, is a complication of both approaches. However, the prevalence and mechanisms of intestinal obstruction after laparoscopic surgery are still a matter of debate. Its occurrence is independent of the operation performed, and opposite to common belief, the prevalence can be as high as that found in open surgery. Intestinal obstruction caused by midgut volvulus following LA, in the absence of previous malrotation, is a rare complication, initially described by Caudra in 2002, in an adult patient.

CASE Report - Male, 14 years old, with a previous history of unilateral VUR treated with unilateral reimplantation of the ureter at 12. Admitted with the diagnosis of acute abdomen, characterized by a 6 day long history of pain located to the lower right quadrant, without fever, vomit or change of bowel movements. A laparoscopic appendicectomy was performed following the diagnosis of appendicular abscess. In the first postoperative day the patient presented intermittent abdominal distension and bilious vomit. On the third day, after a period of relative improvement, the situation worsened with the acute onset of persistent intense abdominal pain, tachycardia and pallor, which led to an emergent laparotomy. The surgery revealed a complete 720° midgut volvulus, which was reduced (without the need for resection). The following postoperative period was uneventful.

DISCUSSION: We discuss the factors involved in the occurrence of postoperative intestinal obstruction, and its different forms of presentation, in the scope of LA versus OA.

CONCLUSION: Although rare, midgut volvulus has to be considered as a possible cause of an intestinal obstruction after laparoscopic appendicectomy.

P068 LAPAROSCOPIC DIAGNOSIS AND TREATMENT OF A DOUBLE UTERUS WITH A VAGINAL SEPTUM

Mario Riquelme MD, Arturo Aranda MD, Mario Riquelme-Q MD, Christus-Muguerza Hospital and San Jose Hospital, Monterrey, Mexico

INTRODUCTION: The lack of fusion of the paramesonephric ducts result in a double uterus (uterus didelphys) with a vaginal septum. In the neonatal period, a pelvic mass can be palpated. The majority of the cases are diagnosed

after menarche, with pelvic pain associated to the obstruction of the obstructed hemi-vagina. Most of the cases have renal agenesis or hypoplasia.

MATERIALS: We present two cases with uterus didelphys with a vaginal septum. The first patient of 2 months of age was diagnosed after a UTI. A suprapubic mass is found, therefore a renal US, abdominal/pelvic US, CT scan and VCUG are done, without obtaining a diagnosis. A diagnostic laparoscopy is performed using 3mm ports and a 5mm for the Harmonic scalpel. A didelphy uterus is observed with a posterior bladder mass. A communicating window is performed using the Harmonic scalpel, from the obstructed vagina to the permeable one. Second case is a 6 year old with premature puberty and abdominal US with a cystic suprapubic mass. A diagnostic laparoscopy is performed and a uterus didelphy is encountered. Vaginostomy is performed and a communicating window is done.

RESULTS: Follow up for both patients is 18 months. They are both asymptomatic and without any complication. Abdominal exam is normal and there is no vaginal bleeding report.

CONCLUSION: In cases of pelvic masses, with a high suspicion of uterine or vaginal pathology, diagnostic laparoscopy can clearly identify the anatomy better than imaging studies. Also, complete surgical treatment can be done by this approach.

P069 LAPAROSCOPIC MANAGEMENT OF A RECURRENT PHEOCHROMOCYTOMA IN A PATIENT WITH VON HIPPEL LINDAU SYNDROME

Richard G Weiss MD, Roselle Crombie MD, Connecticut Children's Medical Center, Hartford, CT and University of Connecticut School of Medicine, Farmington, CT

Pheochromocytoma in the pediatric age group is uncommon. Children with this tumor are more likely than adults to present with sustained hypertension, have bilateral disease, extraadrenal sites, familial patterns, and associations with various syndromes involving neural crest abnormalities. Long term follow-up is essential to screen for recurrence.

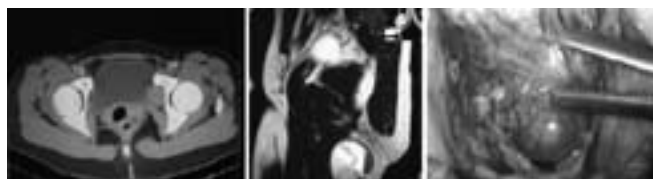
An 11 year old male presented to the emergency department with severe headaches, diaphoresis, and significant hypertension (systolic pressure of 290). Evaluation revealed bilateral adrenal masses, elevated urinary catecholamines, as well as von Hippel Lindau syndrome. After appropriate preoperative management, laparotomy and bilateral adrenalectomies were performed. Five years later, while undergoing routine screening, a recurrent pheochromocytoma was found. The patient underwent successful laparoscopic resection of a 2 cm left suprarenal mass.

Patients with pheochromocytoma should be screened for recurrent disease. Patients with von Hippel Lindau syndrome also require lifelong screening for various tumors. Laparoscopic resection of recurrences is feasible even after an initial large laparotomy incision.

P070 LAPAROSCOPIC RESECTION OF AN OBTURATOR NERVE SCHWANNOMA

Philip A Omotosho MD, David B Tashjian MD, Kevin P Moriarty MD, Baystate Children's Hospital, Tufts University School of Medicine

TUMORS arising from peripheral nerve sheath Schwann cells are rare. These lesions involve the limbs in more than 50% of cases, but have also been reported in the trunk, retroperitoneum and pelvis. Schwannomas are typically benign. We report the case of a 17 year-old female who presented with progressive left hip and leg pain. CT scan demonstrated a 3.4 x 2.5 x 3.7 cm circumscribed, solid mass deep to the left obturator internus muscle and extending into the obturator foramen. MRI aided in further characterization of the lesion. CT guided needle aspiration biopsy was positive for schwannoma. She underwent nerve sparing laparoscopic resection of the mass with resolution of symptoms. She remains without neurologic sequelae and symptom-free 6 months post operatively. Review of the literature is included.



P071 ULTRASOUND-GUIDED INTERVENTIONS IN PEDIATRIC SURGERY: EXPERIENCE IN 136 PATIENTS

Lyudmila V Proklova MD, Maria U Yanitskaya PhD, Kirill U Vorobiov MD, Tatyana I Kirkalova MD, Igor U Savenkov MD, Ivan A Turabov PhD, Northern State Medical University, Regional Children Hospital, Arkhangelsk, Russia

PURPOSE: Traditionally interventional procedures are performed by interventional radiologists with fluoroscopy and computed tomography guidance. But sometimes pediatric surgeons in Russia have no access to such modalities, while the ultrasound devices are available in every hospital. The purpose of this study was to evaluate the efficiency of ultrasound (US)-guided interventional procedures that can be performed by pediatric surgeons trained in ultrasonography.

METHODS: We analyzed the results of 139 US -guided operations that were conducted after the obtaining of the informed consents in the hospital's Division of Surgery from March 2001 to July 2006. The types and number of surgical operations were: transcutaneous nephrostomy ? 17; needle aspiration biopsy of the abdominal and retroperitoneal tumors ? 6; external drainage, sclerosing of the pancreatic cyst ? 1; needle aspiration treatment (NAT) sclerosing of the diaphragm cyst ? 1; NAT of the traumatic liver hematoma ? 3, the kidney abscess ? 1, the adrenal cyst ? 1, the lung abscess ? 1, nonlactational breast abscesses ? 25, deep suppurative lymphadenitis ? 14, Herzenberg parotitis with lymph node abscess ? 4, encysted pleural effusion? 4, acute or tense hydrocele ? 15; soft tissue foreign body removal ? 5; Bulau drainage in pneumothorax ? 1. Neurosurgical: ventriculostomy as part of ventriculoperitoneostomy - 19; external drainage of brain ventricles - 2, chronic subdural hematoma - 5 ; NAT of the intracranial hematoma ? 2. Others ? 12.

RESULTS: Out of 17 nephrostomy tubes inserted, we succeeded in all 17 cases. The kidney function recovered in five children who subsequently underwent reconstructive surgery. The kidney function did not recover in three cases, and nephrectomy was performed. All children suffering from severe urinary outflow obstruction had nephrostomy tubes inserted until the patency of upper urinary tract was restored completely. In all cases of post-traumatic hematomas, cysts of the diaphragm, adrenal gland and pancreas, kidney abscess, the minimally invasive surgery allowed us to avoid more traumatic open or laparoscopic surgery. Positive results were achieved in all children (100%) with nonlactational breast abscesses, suppurative lymphadenitis and Herzenberg parotitis, and no extra surgery was required. The application of US-guided minimally invasive neurosurgery allowed five children with chronic subdural hematomas to avoid craniotomy, and to improve the condition of two children with post-traumatic intracranial hematomas, reducing the need for surgical intervention.

CONCLUSION: Ultrasound-guided minimally invasive interventions in children are highly effective and can be successfully performed by pediatric surgeons trained in ultrasonography.

P072 NURSING ATTITUDES TOWARDS MINIMAL ACCESS SURGERY

L Brocklebank RN, J Hale RN, M Haddad MD, SA Clarke MD, Chelsea & Westminster NHS Foundation Trust, London. UK

Opinion on minimal access surgery (MAS) has focused largely on the surgeon. The success of minimal access techniques is also dependant on the skill and experience of the nursing team. MAS procedures have been established in our institution for more than a decade.

AIMS: To survey nursing attitudes within our own hospital on MAS, the training involved and possible areas of improvement.

METHODS: A questionnaire was sent to over 70 members of the theatre nursing staff in our hospital. Issues explored included experience both as a nurse and in MAS techniques; preferences; observed benefits; equipment issues; surgical training and skill required to carry out MAS.

RESULTS: 51 (73%) completed questionnaires were analysed. 50% were level 6 nurses or above. 96% of those questioned practiced MAS regularly, of whom 54% had had no formal training. 25 % of nurses surveyed worked solely with children though all had regular paediatric experience. 68% preferred scrubbing for open surgery rather than MAS. Most recognised benefits for patient and surgeon though 1 in 4 described an increase in their workload. 25% felt it was the role of the surgeon to be more informed than the nurse in the workings of MAS equipment. The majority (75%) thought MAS should not be carried out at night and never by a trainee without supervision. Increased tolerance from surgeons regarding the setting up of equipment and the training of other members of staff was a frequent observation.

CONCLUSION: Little has focused on what our nurses think regarding MAS. Our study shows open surgery still remains a preference for most nurses in our hospital despite regularly MAS for more than a decade. Increased training and regular updates on advancing technology were called for and has resulted in the setting up of an annual MAS nursing training day. Nurses are a vital and important part of the team and in the development of MAS techniques.

P073 LAPAROSCOPIC GASTRIC BANDING IN ADOLESCENCE OBESE PATIENTS: AN EXTRA HELP

Miguel Guelfand MD, Juan C. Gallardo, Andrea Poblete, Hospital de Niños Dr. Exequiel González Cortés

PURPOSE: Adolescent obese patients are a difficult challenge to both the patient and the multidisciplinary team. The aim of this study is to evaluate the results of gastric banding in adolescence obese patients.

METHODS: All adolescent patients (13 to 19 y.o.) that were operated laparoscopically for gastric banding were retrospectively reviewed. All patients were evaluated and treated by a multidisciplinary group. Surgical treatment, i.e. laparoscopic gastric banding, were offered after medical treatment for reducing weight had failed.

RESULTS: In a 2 years period (2004-2006) 21 patients underwent surgery (15 girls and 6 boys). The mean age was 17 year old (range 13-19 years). The mean body mass index (BMI) was 38.56 (range 31-51), with an average overweight of 44,2 Kg. There were no intra or post-operative complications. The group presented with a wide range of comorbidities being the most common insulin resistance and hyperinsulinemia with 49%, hyperuricemia with 13%, and fatty liver with 11%. The mean follow-up was 36% up to 6 months and 29% up to 12 months. 15 (72%) of the patients improved their comorbidities 6 months after surgery. 12 months post banding, 11 (54%) of the patients had lost 50% of the excess weight. There were no mortalities in this series.

CONCLUSIONS: Treatment for obese adolescent patient is multidisciplinary, therefore Laparoscopic Gastric Banding should be considered in the management of those cases where medical treatment have failed.

INDEX WORDS: obese, adolescent, children, banding, laparoscopically.

P074 INSTITUTIONAL EXPERIENCE WITH LAPAROSCOPIC PARTIAL SPLENECTOMY FOR HEREDITARY SPHEROCYTOSIS

Bethany Slater MD, Sanjeev Dutta MD, Lucile Packard Children's Hospital, Stanford University School of Medicine

INTRODUCTION: Moderate to severe hereditary spherocytosis (HS) is treated with total splenectomy, which compromises immune function. Splenic preservation is postulated as a method to avoid this potentially fatal sequelae, but is mainly performed through laparotomy. We report our experience with a laparoscopic approach to partial splenectomy for hereditary spherocytosis that leaves an upper pole remnant.

METHODS: Retrospective review of five patients that underwent laparoscopic partial splenectomies for HS. Follow-up was from 1 to 8 months. Data included pre- and postoperative Hgb, absolute reticulocyte count, and symptom status, as well as splenic size, operative complications, and length of stay.

RESULTS: All procedures were completed successfully. One patient underwent concurrent laparoscopic cholecystectomy. The mean pre-operative spleen size was 12.7 cm. Table 1 depicts pre and post Hgb. Mean preop absolute reticulocyte count was 401.6 x 10⁹/L and postop was 185.4 x 10⁹/L. Mean hospital stay was 4.6 days (range 4 ? 6 days). All patients noted increased energy levels post-operatively. There was one intra-operative complication (a small bowel tear during spleen extraction) and 2 minor post-operative complications (ileus and wound infection).

| PATIENT | PRE | POST |
|---------|------|------|
| 1 | 9.5 | 10.8 |
| 2 | 9.0 | 10.4 |
| 3 | 11.7 | 11.9 |
| 4 | 9.9 | 11.4 |
| 5 | 10.2 | 11.7 |

CONCLUSION: Laparoscopic partial splenectomy for HS is a feasible and effective procedure that addresses the associated hemolysis and accelerated compensatory erythropoiesis, and potentially retains immune function, while conferring the advantages of laparoscopy. Hospital stay can be longer than that of laparoscopic total splenectomy.

P075 LAPAROSCOPIC MANAGEMENT OF OVARIAN TORSION IN GIRLS IS STRAIGHTFORWARD AND MAY IMPROVE CHANCES OF OVARIAN SALVAGE

Charles J Aprahamian MD, Ramanath N Haricharan MD, Douglas C Barnhart MD, Carroll M Harmon MD, Jacqueline M Saito MD, The University of Alabama at Birmingham

INTRODUCTION: The treatment of ovarian torsion in children has historically been open detorsion often with concomitant salpingo-oophorectomy. The purpose of this study is to describe a laparoscopic management strategy of ovarian torsion in girls.

METHODS: After IRB approval, the charts of children with ovarian torsion treated between July 2004 and December 2006 were reviewed.

RESULTS: Five girls with ovarian torsion were treated during the study period. The median age was 11 (5-14) years. Median time from onset of symptoms to presentation was 2 (1-4) days. The most common presenting symptoms were abdominal pain (100%), nausea/vomiting (80%), and fever (60%). The WBC count was mildly elevated (mean \pm SD, 13 \pm 3 thous/iL). All children underwent preoperative radiographic evaluation with either abdominopelvic CT or pelvic ultrasound that was diagnostic of ovarian torsion. To evaluate for a possible ovarian malignancy, the children had a preoperative serum AFP (1.6 \pm 1.5 ng/mL) and beta-HCG levels drawn (below detectable limits). Laparoscopic detorsion was performed as an emergent procedure in all cases. All children underwent successful laparoscopic detorsion without a pexy procedure. Median operative time was 44 (34-78) minutes. There were no complications and median hospital LOS was 2 (1-2) days. All children underwent a repeat pelvic ultrasound at a median time of 45 (14-63) days. Early in the experience, three children underwent repeat laparoscopy which demonstrated viable ovarian tissue; one of the children underwent resection of a simple ovarian cyst. Median time to repeat laparoscopy was 9 (8-12) weeks. Subsequently children have been followed with serial ultrasounds until complete resolution of mass. None of the girls required oophorectomy or suffered recurrent torsion.

CONCLUSION: Laparoscopic ovarian detorsion in children is safe and technically straightforward. This management strategy evaluates for malignancy and optimizes the chance of salvage of the ovary while affording the postoperative benefits of laparoscopy.

P076 A LESS INVASIVE ALTERNATIVE TO OPEN BIOPSIES: LAPAROSCOPIC BIOPSY

Rahsan Vargun-Yildiz MD, Esra Temeltas MD, Bilal Alper MD, Berkutug Bahadir MD, Gulnur Gollu MD, Aydin Yagmurlu MD, Department of Pediatric Surgery, Ankara University School of Medicine

AIM: Although the gold standard of minimally invasiveness is fine needle aspiration biopsies in terms of histopathological diagnosis, minimally invasive surgical techniques may favorably impact on the work-up and treatment of lymphoma, renal disease, chronic liver disease and intestinal pathology.

PATIENTS AND METHODS: A retrospective chart review was performed in children who underwent laparoscopic biopsy. Demographic data, indication of biopsy, length of hospital stay, early and late complications were investigated.

RESULTS: Twenty nine children had laparoscopic biopsy. Median age was five years (2 months to 16 years). Tissue specimens that were obtained from the following organs; kidney (n=9), liver (n=6), small intestine (Seromuscular) (n=4), lymph nodes (n=2), peritoneum (n=2), intraabdominal mass (n=6). Conversion to open surgery was needed in a child due to uncontrolled bleeding during retroperitoneal renal biopsy. There were no postoperative complications. Adequate tissue was obtained in all patients. Mean length of hospital stay was one day.

CONCLUSION: It seems that extraperitoneal or intraperitoneal laparoscopic biopsy is a safe, reliable and minimally invasive technique in cases where fine needle aspiration could not be performed. The leading advantages were as follows: 100% success rates in obtaining adequate tissue for histopathological evaluation, less postoperative analgesia requirement, early returning back to normal physical activity and good cosmetic outcomes.

P077 A REVIEW OF LAPAROSCOPIC TRAINING IN PAEDIATRIC SURGERY IN THE UK

Emma Stormer, Atul Sabharwal, Royal Hospital for Sick Children, Yorkhill, Glasgow, UK

AIMS: To review the exposure Paediatric Surgery trainees have to laparoscopic surgery in the United Kingdom (UK).

METHODS: A confidential postal questionnaire was sent to all trainees working at registrar level in centres responsible for Paediatric Surgical training in the UK. Questions assessed the number of Consultants with an interest in laparoscopic surgery, types of cases performed laparoscopically and trainees' role in laparoscopic appendicectomy.

RESULTS: Questionnaires were sent to 112 trainees with a 55% response rate (62 replies). At least one response was received from each unit. Based on responses 49 to 67 consultants in 21 training centres have an interest in laparoscopic surgery; 0 to 100% of consultants per unit. Laparoscopic appendicectomy (LA) was offered in 20 out of 21 training centres. There was no significant difference in the proportion of appendicectomies performed laparoscopically by junior (year 1-3) and senior (year 4-6) trainees. A significantly higher proportion of junior trainees had performed none laparoscopically ($p = 0.02$). 73% of trainees were principle operator. For trainees who were principle operator the cameraperson was a consultant in 52% and a junior trainee in 17%. The time of day affected the likelihood of a procedure being carried out laparoscopically in 43 (81%) responses. 90% of trainees who responded intend to offer laparoscopic appendicectomy as a consultant. 48% of respondents have completed a laparoscopic surgery course.

CONCLUSIONS: The majority of trainees' exposure to laparoscopic surgery could be viewed as suboptimal, however, the exposure gained varies significantly between different units throughout the UK. In an age moving in favour of minimal access surgery all units must be in a position to offer paediatric laparoscopic surgical training. Completion of a laparoscopic surgery course should be an essential requirement for all senior trainees.

P078 THE ROLE OF LAPAROSCOPY IN THE EXCISION OF PAEDIATRIC SOLID TUMOURS

Stephanie A Warne MD, Gordon A Mackinlay MD, Fraser D Munro, Royal Hospital For Sick Children, Edinburgh, United Kingdom

AIM: Minimal access techniques are now the most appropriate way to deal with most paediatric surgical conditions. The use of laparoscopy for tumour resection in children remains controversial but it has been the preferred surgical technique in our department in recent years for appropriate abdominal tumours and we aim to describe this experience.

METHODS: Records and radiographs of all oncology patients undergoing laparoscopic procedures from January 1999 ? December 2006 were retrospectively reviewed. All operations were performed by the same 2 surgeons and details of procedure, diagnosis and outcomes were recorded.

RESULTS: Twenty- three oncology patients (10 male 13 female) had Laparoscopic procedures to excise a solid tumour performed at mean 9.2 years (Range 1 week to 12.8 years). They have been followed up for a mean of 2.8 (Range 0.8-7.8) years. Fourteen procedures were for excision of adrenal tumours; six procedures for excision of renal tumours and 3 for excision of pelvic tumours. In the adrenal group the pathology of the tumour was : 7 neuroblastoma, 2 ganglioneuroma, 2 pheochromocytoma and 1 adrenocorticoid-secreting tumour. In 3 of the 14 adrenal tumour resections, although initial mobilisation of the tumour was performed laparoscopically, the procedure was converted to open for safe dissection of the tumour from the inferior vena cava. (All Stage IV neuroblastoma). In the renal group there were nephrectomies for : Wilms' tumour in 4, Renal cell carcinoma in 1 and Mesoblastic nephroma in 1. One of the 6 procedures was converted to open due to difficult access to the renal pedicle. Two pelvic rhabdomyosarcomas and 1 pelvic ganglioneuroblastoma were successfully resected laparoscopically. The one significant post op complication was a delayed colonic perforation following a laparoscopic nephrectomy.

CONCLUSION: Laparoscopic surgery is a useful tool both for biopsy and to resect solid tumours safely in children. The many benefits of minimal access surgery such as reduced postoperative analgesic requirements and shortened length of stay are especially beneficial in the oncology patients who already spend much time in hospital. The rapid recovery also allows earlier resumption of chemotherapy. In units where the surgical expertise is available the laparoscopic approach should be considered in the surgical treatment of abdominal neoplasms in children.

P079 MINIMAL INVASIVE SURGICAL APPROACH IN THE MANAGEMENT OF PEDIATRIC HYDATID DISEASE

Haluk B Guvenc MD, Gulsen Ekingen MD, Bulent Azman MD, Burak Erkus MD, Anadolu Saglik Merkezi, Dept of Pediatric Surgery, Gebze, Kocaeli, Turkey

AIM OF THE STUDY: Surgery has remained the mainstay for the treatment of hydatid disease. Classical surgical approach is enucleation of the cyst by cleavage and capitone of the remaining pericyst via thoracotomy or laparotomy. Resection of the pulmonary or hepatic parenchyma may also be performed. Video assisted intervention is a most valuable tool in the differential diagnosis and treatment of complicated cases.

METHODS: Eight children aged between 5 - 10 years, presenting with hydatid disease of the lung (4), liver (4) and concurrent kidney (1) underwent video assisted surgical approach. Clinical and radiological findings were consistent with a pleural effusion caused by pneumonia in two patients with pulmonary echinococcosis, which led primarily to a wrong diagnosis. The germinative membrane and debris were removed through portholes, followed by repeated irrigation of the cavity. In the hepatic echinococcosis cysts a special suction-irrigation needle was used. Content of the cyst was aspirated initially and the cyst was irrigated using scolicalid agent. The germinative membrane was removed in an endobag following aspiration of the cyst content. The cyst in the kidney was also removed without any complication. Each patient received antihelminthic drug treatment during follow-up period.

MAIN RESULTS: All 8 cases were successfully treated by video-assisted surgery. No conversions to open surgery were required. Postoperative bronchopleural fistula resolved spontaneously under negative pressure in two cases. The long-term postoperative results are considered good, with no recurrences observed.

CONCLUSION: Minimal access surgery is a safe, effective, and viable option for the management of selected pediatric patients with pulmonary and hepatic hydatid cysts. Thoracoscopy and laparoscopy may aid in the correct diagnosis in complicated cases achieving a timely complete remission.

P080 MINIMAL INVASIVE APPROACH IN INFANT AND CHILDHOOD OVARIAN PATHOLOGIES

Haluk B Guvenc MD, Gulsen Ekingen MD, Bulent Azman MD, Burak Erkus MD, Anadolu Saglik Merkezi, Dept of Pediatric Surgery, Gebze, Kocaeli, Turkey

AIM: The frequency of diagnosis of ovarian cystic masses in childhood has relatively increased as a result of the widespread use of ultrasonography from neonate to adolescence. Most of the lesions in this age group are benign but acute abdomen may also be the presenting clinical picture. Minimal invasive approach has become the first choice of treatment in international centers. The technique is feasible with favorable outcomes even in the management of extremely large ovarian cysts.

METHOD: We have treated 11 patients aged 1 month to 15 years (mean 5.7 years) who referred with an ovarian mass from January 1999 ? December 2006. Six cases were older than 10 and 3 were younger than 1 year of age. A prenatal diagnosis of a cystic adnexial lesion was present in only three patients. A successful laparoscopic intervention was performed in all cases. Either a supraumbilical or umbilical camera port was used considering the size of the mass. Two additional 3.5-5.0 mm working ports were inserted along the midclavicular lines at umbilical level. The mass was removed through a very short Pfannenstiel incision following its drainage through the umbilical port when necessary.

RESULTS: Two cases were diagnosed as mature teratomas, five were simple ovarian cysts. One case was reported as having ectopic pregnancy from the biopsy material. Another one was diagnosed as a giant paraovarian cyst, presenting six liters of fluid material. An autoamputated cyst was present in two infants which were diagnosed by prenatal US. There were no operative complications and the mean operative time was 82 minutes.

CONCLUSION: We recommend minimal invasive approach in infant and childhood ovarian pathologies as a safe and feasible method. The size of the ovarian cyst is not necessarily a contraindication for laparoscopic surgery. Laparoscopy also enables the timely diagnosis of an otherwise silent auto amputated ovarian cyst, in neonates presenting with small simple ovarian cysts under 4 cm in diameter.

P081 LAPAROSCOPIC MANAGEMENT OF ADNEXAL PATHOLOGY IN CHILDREN: A GOLD STANDART

Esra Temeltas MD, Rahsan Vargün MD, Meltem Bingöl Kologlu MD, Aydın Yagmurlu MD, Hüseyin Dindar MD, Department of Pediatric Surgery, Ankara University School of Medicine, Ankara TURKEY

AIM: We aimed to investigate the efficiency and results of laparoscopy for adnexal pathology in children.

PATIENTS AND METHODS: A retrospective chart review was performed in children who underwent laparoscopy for adnexal pathology in our unit from 2003 to 2007. Demographic data, radiographic findings, operation time, hospital stay, diagnosis and complications were investigated.

RESULTS: Thirteen girls underwent laparoscopy for adnexal pathology. The mean age was 11 years (5 to 17 years). The most common presenting symptom was acute onset of abdominal pain (n=13) associated with, palpable mass (n=5), and puberty precoc (n=1). Ultrasonography revealed adnexal mass having cystic or solid components with diameters ranging between 7- 20cm in all children. Three trocar technique was used. Adnexal pathologies were simple ovarian cysts (n=11), ovarian torsion (n=1) and dermoid cyst (n=1). All procedures were completed laparoscopically. There were no intraoperative and postoperative complications. The mean operative time was 70 minutes. The mean hospital stay was 1.5 days.

CONCLUSION: Laparoscopic approach to adnexal pathology in childhood is an effective and safe method for diagnosis as well as definitive therapy with excellent results. This minimal invasive approach offers the change to increase adnexal salvage in emergency such as torsion of adnexa. It is a feasible treatment modality even for giant ovarian masses in children.

P082 EVOLUTION OF THE SURGICAL MANAGEMENT OF NEONATAL OVARIAN CYSTS: LAPAROSCOPIC-ASSISTED TRANS-UMBILICAL EXTRA-CORPOREAL OVARIAN CYSTECTOMY (LATEC)

Lucy Schenkman BA, Timothy M Weiner MD, J. Duncan Phillips MD, University of North Carolina School of Medicine

PURPOSE: Laparoscopic management of neonatal ovarian cysts has typically required multiple incisions, specialized equipment, and advanced laparoscopic skills. This study presents our experience with a new, simplified single-incision technique, Laparoscopic-Assisted Transumbilical Extracorporeal Cystectomy (LATEC), and compares outcomes to our other neonatal ovarian cyst patients. **Methods:** Retrospective record review of 20 patients treated surgically from 1992 to 2006. (Student's t-tests used for comparisons, $p < .05$ = significant). **Results:** Means: age 11 dys, weight 3.7 kg, cyst diameter 5.0 cm. 19 patients (pts) were diagnosed prenatally, at mean gestation 33 wks. 12 of 20 (60%) had torsed cysts (1 bilateral). Laparotomies were transverse low incisions. Laparoscopy used 2 incisions (3 pts) or 3 incisions (2 pts). LATEC involved trans-umbilical laparoscopy, percutaneous complete cyst aspiration, and then cyst evisceration through the umbilicus for either ovarian cystectomy (simple cysts) or salpingo-oophorectomy (torsed cysts). LATEC pts had shorter surgical times, more rapid advancement to full feedings and shorter lengths of stay (LOS) when compared to laparoscopy. Narcotic requirements and ovarian preservation were similar in all 3 groups.

| | OR time (mins) | Full feeds (hrs) | Postop LOS (hrs) |
|--|-------------------|---------------------|---------------------|
| Laparotomy:n=8 | 51.8 +/- 17.1 | 36.6 +/- 27.8 | 48.4 +/- 33.8 |
| Laparoscopy:n=5 | 83.0 +/- 42.9 | 38.7 +/- 17.4 | 53.3 +/- 15.5 |
| LATEC: n=7 | 45.6 +/- 14.1* | 20.5 +/- 12.0* | 30.9 +/- 11.5* |
| means+/-SD; * $p < .05$ vs Laparoscopy | | | |

CONCLUSIONS: LATEC is a relatively simple procedure combining laparoscopy and traditional extra-corporeal surgery and appears to offer improved outcomes, with a single umbilical incision.

P083 IS PRIMARY ANASTOMOSIS A VALID OPTION IN NEWBORN <1500 G WITH NECROTIZING ENTEROCOLITIS? - A PROSPECTIVE STUDY

Miguel Gueifand MD, Juan C. Gallardo MD, Andrea Poblete MD, Hospital de niños Dr. Exequiel González Cortés

PURPOSE: To evaluate prospectively if primary anastomosis is an option among newborns less than 1500 g suffering from necrotizing enterocolitis (NEC).

METHODS: Every newborn <1500 g with diagnosis of NEC who required surgery between March 2002 and March 2006 participated in a protocol of intestinal resection with primary anastomosis.

RESULTS: During the 4 year period, 14 newborns met the criteria (5 girls and 9 boys). The average weight was 892 g (range 590 - 1450 g), 2 cases were excluded due to patient's instability intraoperatively and managed with resection and an ostomy. The others 12 patients underwent intestinal resection and primary anastomosis with 2 requiring 2 intestinal anastomosis. 2 patients had peritoneal drainage prior to surgery. There were no surgical complications in this series. 2 patients died due to sepsis 2 and 3 weeks after surgery. The mean follow up was 22 months (range 6 - 42); 1 patient presented with an intestinal obstruction 8 months postoperative that resolved with surgery uneventfully.

CONCLUSIONS: Based on the results of this series we can conclude that intestinal resection with primary anastomosis is a valid option for NEC patients under 1500 g.

INDEX WORDS: necrotizing enterocolitis, very low birth weight, intestinal resection, primary anastomosis, newborn.

P084 IN VIVO REAL TIME COLONOSCOPIC ENDOTHERAPY TARGETED BY CONFOCAL ENDOMICROSCOPY IN COLONIC HETEROTOPIA

B Antao MD, K Venkatesh MD, M Thomson MD, Centre for Paediatric Gastroenterology, Sheffield Children's NHS Foundation Trust, Sheffield, UK

OBJECTIVE: To assess the usefulness and safety of confocal endomicroscopy in the diagnosis and targeted treatment of colonic heterotopia.

METHODS: A 10 year old child with long standing diarrhoea underwent confocal endomicro-colonoscopy using the (Pentax EC3870K) under general anaesthetic. 20% sodium fluorescein was given intravenously at the start of the procedure to facilitate superficial and deep imaging to the lamina propria. Areas of potential mucosal abnormality were identified using conventional video-endoscopy and endo-histological analysis was carried out using confocal endo-microscopy. Targeted endo-microscopic images from the raster scanned colorectal segments were then compared with conventional same-site biopsies read by a blinded histopathologist. The localized lesions were ablated with argon plasma coagulation.

RESULTS: The ano-ileal intubation time was 8 min and the total procedure time was 25 min. Confocal imaging revealed stratified epithelium, gastric-type mucosa, and small bowel villous mucosa in three separate segments of the rectum, sigmoid and transverse colon. Targeted same-site biopsies were then compared after blinded analysis and confocal images were compared to standard histology: an accuracy of (92.1%) (sensitivity 93.5%/specificity 95.3%) ? MN $p = 0.74$. Image quality evaluated subsequently showed of all images taken 65% were satisfactory to good. In vivo ?on-table? assessment of mucosal histology by endo-microscopy allowed decisions regarding appropriate endo-therapy and hence accurately targeted argon plasma ablation of mucosal lesions occurred with good clinical effect. No adverse events occurred.

CONCLUSION: Accurate assessment of heterotopic mucosal type is possible during the ileo-colonoscopy by real-time confocal endo-microscopy and this directed appropriate treatment with argon plasma ablation in this child. This is the first report of confocal endomicroscopy being used to direct colonoscopic endo-therapy in paediatric endoscopy, and this analytical technique shows great potential for the future.

P085 MINIMAL ACCESS SURGERY AS PRIMARY APPROACH FOR REPAIR OF THE LATE PRESENTING CONGENITAL DIAPHRAGMATIC HERNIAS -TWO CENTERS DATA

Dragan Kravarusic MD, Andrew L Wong MD, Enrique Freud MD, Schneider Children's Medical Center and Alberta Children's Hospital

BACKGROUND: Clinical spectrum of late-presenting CDH seems to be conditioned by two factors: timing of herniation and type of intraabdominal viscera displaced into the chest. Dyspnea and vomiting are the most frequent symptoms found in patients with either chronic or acute manifestation.

PURPOSE: The main purpose of the presented series is to gain insight of minimal access surgery into the repair of this variant of CDH.

METHODS: Seven consecutive children with late presenting CDH undergoing MAS repair over the last four years, in two centers, were reviewed. The ages ranged from 1 month to 6 years. One was found incidentally, four presented with sudden onset of dyspnea and two had history of intermittent vomiting. Chest x-ray was diagnostic in all cases and additional contrast study was performed in two cases that presented with obstructive symptoms.

RESULTS: At operation four were found to have Morgagni and three Bochdalek hernia. Six underwent laparoscopic repair and one had combine thoracoscopic/laparoscopic repair. Primary repair was done in six patients and one with large Morgagni-Larrey defect underwent reinforcement with prosthetic mesh. There were no complications and no cases were converted. Follow up chest radiograph demonstrated complete resolution in all cases and ?residual cavity? was present in two of Morgagni cases where hernia sac was not resected. Median time to full diet was 36 hours, narcotics were given only in first 24 hours and median hospital stay was 3 days.

CONCLUSIONS: Primary MAS approach for repair of the late presenting CDH is safe, with rapid recovery, superior cosmetic results and satisfactory outcome.

P086 THORACOSCOPIC LUNG BIOPSY AND WEDGE RESECTION IN COMPROMISED PEDIATRIC PATIENTS

Francesco Fascetti Leon MD, Eleonora Cesca MD, Paola Midrio MD, Giovanni Cecchetto MD, Giovanni Franco Zanon MD, Angelo Barbato MD, Pier Giorgio Gamba, Pediatric Surgery Unit, Department of Pediatrics

OBJECTIVE: video-assisted techniques are widely employed in pediatric patients obtaining prompter recovery than traditional approaches, in particular in those patients who require proceeding the therapeutic program. The study aimed to evaluate the results obtained with thoracoscopy for lung wedge resections and biopsy in severely compromised patients.

METHODS: data of patients who underwent thoracoscopy for lung wedge resections and biopsy at Pediatric Surgery Department of Padua between Jan 2000 and Dec 2006 have been retrospectively reviewed.

RESULTS: twelve patient notes were available, 6 M e 6 F, average age 8.3 years (range 2.5 to 16). Thoracoscopy was carried out using 2 or 3 5mm trocars plus 10mm telescope. At the end of all procedures an Argyle drain (Ch 14-16) was placed through a trocar wound. Six patients underwent lung biopsy. Histological diagnosis was obtained in all cases: 4 autoimmune pneumopathies; 1 Hodgkin lymphoma; 1 scare-tissue lump of the thoracic wall. None required further surgical maneuvers to obtain the correct diagnosis. The other 6 patients underwent lung wedge resections for lung masses: 2 uncertain lung metastases from Wilms? tumor and abdominal Ewing-Pnet sarcoma respectively; 4 fungal lesions in patients waiting for bone marrow transplant. Preoperative CT scan was obtained for all patients. Two received bilateral procedure. Conversion was required for 2/8 procedures due to no rising mass. No postoperative complications occurred. Drain was removed 36 hs after intervention. Average length of stay for patients who received only thoracoscopy was 2 days.

CONCLUSIONS: video-assisted thoracoscopy is safe in both biopsy and wedge resection and always effective in biopsy. However conversion rate in lung wedge resection is low. Video-assisted thoracoscopy reaches a quick recovery and very low morbidity also in compromised pediatric patients.

P087 SPONTANEOUS PNEUMOTHORAX IN THE THORACOSCOPIC ERA

Juan Moldes PhD, Eduardo Ruiz PhD, Marcelo Boer PhD, Francisco de Badiola PhD, Carlos Giusepucci MPH, Marcelo Urquiza Lino MPH, Martin Alarcon MPH, Pablo Lobos PhD, Section of Pediatric Surgery and Pediatric Urology, Department of Pediatrics, Hospital Italiano de Buenos Aires, Buenos Aires, Argentina

PURPOSE: To describe our experience in treatment of spontaneous pneumothorax (SP) with video assisted thoracoscopic surgery (VATS) and discuss the indications for VATS in primary or secondary episode of SP

MATERIALS AND METHODS: Since 1998 we have performed VATS to treat SP. Since then fifteen patients were admitted in our institution with this diagnosis. There were nine males and 6 females with a mean age of 15.7 years (range 12-18). The first episode of SP was managed with conservative treatment or with a chest tube drainage. In the cases where the pneumothorax recurred a VATS was performed. The clinical history were retrospectively reviewed.

RESULTS: The mean follow up was 40 months (range 2-101). In the first SP episode 13 patients received a chest tube drainage and the other 2 received conservative treatment. The chest tube was left in all cases more than three days. 13 patients (86,6 %) presented a recurrent SP and all of them were treated with VATS. The recurrence occurred in a mean time of 4 months (range: 1-11). 1 patient presented a second recurrence and received a new VATS, 2 patients presented a contra lateral asincronic SP and also received a VATS in the first episode because of the previous SP history. In 14 of the 16 surgeries performed, the pulmonary vertex was resected and in the other 2 only pleurodesis was performed. We had 1 intraoperative complication that required conversion due to a technical problem and 4 patients (26%) presented postoperative complications such as atelectasia, contra lateral pneumonia, transitory Claude Bernard Horner Syndrome and recurrence. The histological study referred sub pleural blebs in 13 patients. The patient who recurred after VATS presented blebs in both resections.

CONCLUSIONS: Contrary to what is described in current literature, the chest tube drainage was insufficient treatment for the majority patients. VATS presented good results in achieving pulmonary reexpansion and low recurrence rate. We thought to the high rate of recurrence after the chest tube drainage, VATS should be performed in the first SP episode.

P088 MINIMAL ACCESS SURGERY IN PAEDIATRIC THORACIC PATHOLOGY? A 5 YEAR REVIEW

Stephanie A Warne MD, Gordon A Mackinlay MD, Fraser D Munro MD, William G Manson MD, Royal Hospital For Sick Children, Edinburgh, UK

AIM: To review the experience, role and outcome for minimally invasive thoracic surgery within a regional paediatric surgical unit.

METHODS: The records, operation notes and radiographs for all cases undergoing thoracoscopic procedures during the period January 2002 ? January 2006 were retrospectively reviewed. All procedures were performed by 3 members of the surgical team and details of procedure, diagnosis and outcomes were recorded.

RESULTS: Eighty-one thoracoscopic procedures were performed during the 5 year review period at mean of 1.4 (Range 1 day- 16) years. Thoracoscopically assisted procedures were performed for : intrathoracic malignancy in 13 (3 biopsies & 10 resections) ; resection of cystic Lung disease in 10 ; repair of Oesophageal atresia in 18 ; treatment of empyema in 35 and biopsies for interstitial lung disease in 3, eventeration in 1 and diaphragmatic hernia in 1. The conversion to open procedure was low at 2 % (2 of 81) cases.

CONCLUSION: Minimal Access Surgery is a very useful tool both for diagnosis and treatment in the paediatric thoracic disease. It can be safely performed in all age groups from neonates to adolescence for a wide range of surgical pathology. The benefits include improved cosmesis from wounds, reduced analgesia requirements with early mobilisation and reduced hospital stay. We would advocate that all paediatric patients requiring thoracic surgical procedures should be considered for Minimal Access Surgery.

P089 EFFICACY OF RIGHT THORACOSCOPY IN MINIMAL INVASIVE REPAIR OF PECTUS EXCAVATUM

Amulya K Saxena MD, Johannes Schalamon MD, Christoph Castellani MD, Michael E Höllwarth MD, Department of Pediatric Surgery, Medical University of Graz, Austria

BACKGROUND/PURPOSE: The minimal invasive repair of pectus excavatum (MIRPE) has been established as the preferred technique for the repair of funnel chest deformity. Original techniques of pectus bar placement have undergone modifications to improve the safety of the procedures. The aim of this study is to evaluate the efficacy of right thoracoscopy and to identify factors responsible for complications related to thoracoscopy in MIRPE.

METHODS: Analysis was performed on patients who have had a thoracoscopic assisted MIRPE between 2000 and 2006. The port was inserted through the right lateral chest wall in all patients to obtain visual access for bar insertion.

RESULTS: Charts of 167 patients with age range from 5-38 years were evaluated. Surgical time ranged from 25 to 255 minutes (mean 66 minutes). Complications primarily related to thoracoscopy were found in 16 patients (9.6%). There was one case of the port trocar piercing through the liver. Incomplete gas evacuation caused postoperative pneumothorax in 15 patients; 5 requiring thoracocentesis and 2 chest tubes.

CONCLUSIONS: Insertion of the port in the right lateral chest wall is safe, and provides optimum visual access during the MIRPE procedure. Careful interpretation of chest films can assist in judicious determination of the port

site. Optimum pressures and near complete evacuation of the insufflation gases can drastically reduce complications. Alternative access sites such as port insertion above the level of bar placement or left sided and/or bilateral thoracoscopy may not be necessary.

P090 THORACOSCOPIC LIGATION OF THE THORACIC DUCT FOR CONGENITAL CHYLOTHORAX

Sidney M Johnson MD, Daniel K Robie MD, Kapiolani Medical Center for Women and Children

BACKGROUND: Congenital chylothorax is the most common cause of pleural effusion in the neonatal period. When associated with hydrops fetalis mortality rates as high as 57% have been reported. Treatment modalities ranging from octreotide therapy and chemical pleurodesis to open thoracotomy have been described.

MATERIALS and Methods: We conducted a retrospective review of patients with congenital chylothorax over a 2 year time period. 2 patients were treated with thoracoscopic ligation of the thoracic duct. One had bilateral congenital chylothorax. The other had unilateral chylothorax.

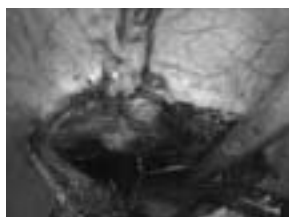
RESULTS: Prior to undergoing surgery, both patients underwent medical therapy including ventilatory manipulation and octreotide over at least a 10 day period. When patients failed medical management they underwent thoracoscopic ligation of the thoracic duct at the level of the diaphragm. In total, 3 thoracoscopic ligations were done to manage the chylothorax (staged treatment of the bilateral congenital chylothoraces). All three chylothoraces were successfully treated with dramatic improvement on the affected "surgical" side in the immediate post-operative period. Both infants survived.

CONCLUSION: Thoracoscopic ligation of the thoracic duct for congenital chylothorax is possible in the neonatal period. In our experience it resulted in the most satisfying results with dramatic improvement in the immediate post operative period.

P091 LAPAROSCOPIC SUBXIPHOID PERICARDIAL EXPLORATION

Jennifer J Garza MD, David Tuggle MD, The University of Oklahoma Health Sciences Center

Blunt cardiac trauma that requires operative intervention is uncommon. We report a case of a 2 year old that sustained a blunt cardiac injury. She underwent CT scanning that showed a pancreatic injury, rib fractures, a frontal lobe contusion, and a pericardial effusion. She also had a significant amount of fluid in the abdomen. A heart echo showed a pericardial effusion and mild cardiac tamponade. Therefore she underwent laparoscopy to evaluate the abdominal fluid with a planned subxiphoid window to explore the pericardium. She was noted to have a tear of the falciform ligament and no intestinal injury. The subxiphoid pericardial window was performed with cautery through the central tendon of the diaphragm. Upon entering the pericardium a large amount of bloody fluid was obtained, contusion could be seen on the pericardium and the epicardium. A blood clot was aspirated from the pericardium. Decompression of the pericardial space improved the patients hemodynamics. Post operatively she was treated for a pneumothorax. She was discharged within 48 hours. Minimally invasive pericardial exploration is uncommon in adults, and has not been described in a child. This technique of pericardial exploration for children can be utilized when pericardial decompression is needed after blunt cardiac trauma. The image shown demonstrates a bruise on the pericardium upon entry:



P092 LAPAROSCOPIC TREATMENT FOR INTRA ABDOMINAL TESTIS

W A Britos MD, R M Berazategui MD, G Gianinni MD, Hospital Pereira Rossell. School of Medicine. Universidad de la Republica, Montevideo. Uruguay

The incidence of non palpable testicles is about 10 to 15% in most series of undescended testicles. Laparoscopy is the only procedure capable of diagnosing and eventually commence a treatment on the same act.

In a period of seven years we have followed a diagnostic algorithm performing a diagnostic laparoscopy to 78 patients for a total of 83 non palpable testicles. We found 45 intra abdominal testicles performing laparoscopic descent in a single act to 4 and 1st stage laparoscopic Fowler ? Stephen to the rest. Of these

45 testicles, 5 underwent opened second stage Fowler ? Stephen procedure while 33 underwent a laparoscopic second stage procedure. Three patients are still awaiting this final stage. Follow up has revealed a success rate of 89%. The 9% incidence of viable cells within testicle nubbins, reported internationally, has taken us to remove all the rests. We also perform counter lateral testicle fixation to protect the remaining gonad. We strongly recommend the use of laparoscopy in the evaluation and treatment of non palpable testis as it is safe, cosmetically acceptable and with a high success rate.

P093 ENDOSCOPIC INTRAURETERIC POSITIVE CHARGED DEXTRANOMER SEPHADEX COPOLYMER INJECTION TO TREAT HIGH GRADE VUR IN ECTOPIC URETERS

Ilhami Surer MD, Cuneyt Atabek MD, Bahadır Caliskan MD, Haluk Ozturk Msc, Gulhane Military Medical Academy, Dept Of Pediatric Surgery

PURPOSE: The treatment of high grade VUR using endoscopic injection with biocompatible and biodegradable microparticles has given various success rates .We conducted a study to determine the efficacy of an recently marketing positive charged bulking agent (Positive charged Dextranomer/HA sephadex-Urodex) for the endoscopic treatment of high grade reflux in ectopic ureters.

MATERIAL AND METHODS: From December 2004 to October 2006 , 12 children (13 ectopic ureters) were treated for high grade reflux endoscopically; 13 ureters with grade IV and V reflux received a single intraureteric injection with Urodex. The mean(range) age was 30 (9- 121) months. The procedure was performed on an out-patient basis. The follow-up assessment consisted of a voiding cysto-urethrogram at 3 ,9 and 18 months after the injection.

RESULTS: At 3-months follow-up 8 of 13 refluxing ureters (61.5%) were cured using Urodex whereas one year after injection success rates slightly decreased to 46.1%. This decrease may be attributed to re-reflux in two grade V cases. Also in 3 cases reflux downgraded while in 2 cases no changes in reflux grading.

CONCLUSIONS: Single intraureteric endoscopic injection with Urodex was found effective to prevent reflux into the ectopic systems. This finding may be attributed to the positive charged particles in Dx/HA. But long term results and larger series are necessary to conclude overall success.

P094 THE ENDOSCOPIC TREATMENT OF HIGH GRADE VUR: SINGLE SURGEON'S EXPERIENCE,

Ilhami Surer MD, Gulhane Military Medical Academy, Dept Of Pediatric Surgery

AIM: To evaluate the efficacy of subureteric injection with a bulking agent in patients with high grade primary VUR.

METHODS: From January 2000 to October 2006 , 94 children (161 ureters) were treated for high grade reflux by subureteric Dextranomer/HA or positive charged Dextranomer/HA injection endoscopically. The median age was 32 months (2-132 mo.). The procedure was administered on an outpatient basis. The follow-up evaluation consisted of a voiding cysto-urethrogram at 3 and 12 months after injection. The mean follow up was 32 (3-70 mo.)months.

RESULTS: After one injection, at the 3-months follow-up 92 of the 161 refluxing units resolved completely. Overall success rate was 57.1 % for all groups(74.2% in grade III, 44.4% in grade IV and 33.3% in grade V). After second and third injection in 19 re-refluxing units, overall success rates increased to 74.5% (87.1% in grade III ,nd 53.7% in grade IV and 50.0% in grade V) at the 1-year follow up. Slightly decreased success rates were achieved at 2-years follow-up program(Overall 70.8%).There was no complication related to the injection.

CONCLUSION: Endoscopic treatment of high- grade VUR seems to be an alternative to other techniques and should be in the surgeon's armamentarium.

P095 CYSTOSCOPIC REMOVAL OF LEECHES

Tahmina Banu MD, Mozammel Hoque, Tanvir K chowdhury, Jafrul M Hannan MS, Department of Pediatric Surgery, Chittagong Medical College & Hospital, Chittagong, Bangladesh

BACKGROUND: Leech infestation is very common in tropical countries especially in rural areas where ponds and swamps are abundant. The leech commonly infests the body surface of the host to suck blood and it has the habit of entering into anatomical orifices such as the urethra, anus, vagina, nose and throat. Traditionally, application of salt at the site of attachment or saline irrigation are used to remove them. However, this often failed, resulting in huge blood loss, severe anaemia, sometimes necessitating open surgery to remove the leeches. This paper presents our experience of cystoscopic removal of leeches from the urinary bladder and urethra.

METHOD: From January 2002 to December 2006, in the Department of Pediatric Surgery, Chittagong Medical College and Hospital, Chittagong, Bangladesh, a total of 81 patients were admitted with a history of leech infestation in the urinary tract, of which 65 were male and 16 were female. All patients underwent saline irrigation through catheter and subsequent cystoscopic (Storz, 10Fr, 0°) examination & removal of leeches by flexible grasping forcep. Follow-up cystoscopic examination was performed two weeks later

RESULT: Spontaneous expulsion occurred after saline irrigation in 36 patients (M = 28, F = 8). Of the expelled leeches, 22 were live and 14 were dead. Cystoscopic removal was performed in 45 patients of which 37 were male (urinary bladder 23, urethra 14) and 8 were female (urinary bladder 5, urethra 3). Of the leeches in the cystoscopic removal group, 29 were dead and 16 were live. All but one of the patients were infested with one leech. One patient (from the cystoscopic group) was infested with 2 leeches (one in urinary bladder and the other in the urethra). No patients needed open surgery.

CONCLUSION: Cystoscopic removal is a safe and preferred way in managing leech infestation of the urethra and urinary bladder

P096 LAPAROSCOPIC VERSUS OPEN ORCHIDOPEXY IN CHILDREN WITH INTRAABDOMINAL TESTES

Hannu Lintula PhD, Hannu Kokki PhD, Matti Eskelinen PhD, Kari Vanamo PhD, Kuopio University Hospital

BACKGROUND: Intraabdominal testis comprises one-tenth of all cases of cryptorchidism. The management of the intraabdominal testis has been controversial but has changed significantly since the introduction of laparoscopic technique. No study has addressed the issue of comparing laparoscopic orchidopexy (LO) with open orchidopexy (OO).

MATERIAL AND METHODS: A total of 355 children with undescended testes were treated between January 1992 and December 2004. A retrospective review was performed of 35 consecutive boys who were operated on for intraabdominal testes during the same period. The outcomes of children undergoing LO were compared with those who had undergone OO.

RESULTS: Sixteen children with 19 intraabdominal testes underwent LO and 18 children underwent OO. One laparoscopic procedure was converted to an open approach. The mean (±SD) operating time was 62 (±30) minutes in the LO group and 43 (12±) minutes in the OO group (mean difference 19 minutes, 95 % CI 2 to 34 minutes, P=0.025). There were no differences in hospital stay between the two groups. There occurred two major complications. One child in the LO group had spermatic vessels torn which lead to a one-stage Fowler-Stevens orchidopexy. One child who underwent conversion from laparoscopic to open procedure had transection of the vas. Acceptable scrotal position on review was noted in 16 of 18 testicles (89%) in the LO group and in 14 of 17 testicles (82%) in the OO group. One child in each group developed testicular atrophy. One child in the LO group and one in the OO group was lost to follow-up.

CONCLUSIONS: Laparoscopic orchidopexy is an alternative to open procedure in children with intraabdominal testes. Laparoscopic orchidopexy without division of the spermatic vessels can be performed in children with high intraabdominal testes (more than 3 cm from the internal inguinal ring).

P097 LAPAROSCOPY NEPHRECTOMY FOR WILMS TUMORS

Manuel Lopez MD, Emmanuelle Guye MD, François Varlet PhD, Department of Pediatric Surgery, University of Saint Etienne, Nord Hospital, France.

PURPOSE: To report our experience in the treatment of laparoscopic Nephrectomy for Wilms tumors, in children who underwent preoperative chemotherapy.

METHODS: Two children with unilateral Wilms tumors: one of them with bilateral lung metastases treated with preoperative chemotherapy. Subsequently underwent an enlarged laparoscopic nephrectomy. The patient was positioned in 30° lateral decubitus with the interest side up; Ports are: camera 5mm 30°, three trocars of five mm. Transperitoneal approach were used in each case. The nephrectomy is initiated by incising the peritoneum at the base of the small bowel mesentery to expose the retroperitoneal structures. The anterior surface of the aorta or vena cava is cleared of overlying lymphatic and adventitial tissue up to the level of the renal vein. The involved renal artery and vein were coagulated with Ligasure® in sequential fashion and the surrounding soft tissue attachments of the kidney are divided. The ureter is isolated as it crosses the pelvic brim and sectioned. The enlarged periaortic lymph nodes are included and adequate sampling of hilar nodes is obtained. The tumors were placed in endobag and after were extracted without morcellation through an supra-pubic incision

RESULTS: The Two tumors as well as the lymph node samples were removed completely by laparoscopy without rupture. No conversion to laparotomy was necessary and there were neither intraoperative bleeding nor perioperative complications. The mean operative time was 90 min. The discharged were at two and three days. None of these patients presented evidence of recurrences Tumors, port-site implantation and no long-term complications were detected.

CONCLUSION: Enlarged nephrectomy for Wilms tumors in children is feasible and safe by laparoscopy procedure after chemotherapy, with the same oncological strategies that open surgery. A Long follow-up and more cases are necessary to evaluate and compare the results of laparoscopic approach with the open procedures.

P098 THE ROLE OF LAPAROSCOPY IN MANAGING THE PEDIATRIC PATIENT WITH NON-PALPABLE TESTES

Harsh Grewal MD, Leo Doumanian MD, Andrew Huang MD, Gregory Dean MD, Section of Pediatric Surgery and Pediatric Urology, Temple University Children's Medical Center, Philadelphia

INTRODUCTION: There is no consensus on the management of the undescended or non-palpable testicle. We have used laparoscopy to diagnose and treat these children. We have utilized a simple algorithm and report our results.

METHODS: We retrospectively collected data on children undergoing laparoscopy for nonpalpable testes during a 7-year period. Children with nonpalpable testis (after induction of general anesthesia) underwent laparoscopy. Intra-abdominal testes (that were not atrophic) underwent laparoscopic orchidopexy; testis distal to the internal ring underwent an inguinal orchidopexy. Atrophic testes were removed either laparoscopically or with a groin or scrotal incision.

RESULTS: Laparoscopy was performed as an ambulatory surgical procedure in 64 children, 2 children were excluded (mixed gonadal dysgenesis-1, androgen insensitivity-1). In the remaining 62 children, 69 testes were evaluated by laparoscopy (L-38, R-31, B/L-7). At laparoscopy, 44 testes were noted to be intra-abdominal (2 atrophic), and 25 testes were found distal to the internal ring (21 of these testes were atrophic). 46 testes (40-normal size, 6-hypotrophic) underwent orchidopexy (42-intra-abdominal testes, 4-distal to the internal ring). Mean age was 42 months. Laparoscopic orchidopexy was performed in 39 of 46 testes (2 of whom underwent a single stage Fowler-Stevens orchidopexy). In 7 testes, inguinal orchidopexy was performed. For the 23 atrophic testes- laparoscopic orchidectomy was performed in 2 intra-abdominal testes, and open orchidectomy in the remaining 21 testes. The internal ring was closed laparoscopically in selected patients. One patient (with intra-abdominal testes) had conversion to an open procedure because of poor visualization. Follow-up was available in all patients; mean follow-up was 46 months. At follow-up, the testicle was hypotrophic in 8, and the testis was in the scrotum in 43 (93%) - (excellent position-35, good position-8) Re-operation for poor testicular position was successfully performed in two.

CONCLUSION: In our experience laparoscopy and laparoscopic orchidopexy for intra-abdominal testes appears to have good results and has become our preferred procedure.

P099 URETHRAL DIVERTICULUM AFTER LAPAROSCOPIC-ASSISTED ANORECTAL PULLTHROUGH (LAARP) FOR ANORECTAL MALFORMATION: IS IT ALWAYS NECESSARY TO RESECT THE DIVERTICULUM?

Pedro Jose López MD, Miguel Guelfand MD, Alessandro Tavares MD, Yair Cadena MD, Jose M Escala MD, M Gabriela Retamal MD, Nelly Letelier MD, Ricardo Zubieta MD, Department of Urology and Pediatric Surgery, Hospital de niños Dr. Exequiel González Cortés, Santiago, Chile

INTRODUCTION: With the increased use of minimally-invasive surgery, the urethral diverticulum after anorectal surgery have become an issue. The few cases reported, have been managed by surgical excision. We report a case of urethral diverticulum after a LAARP with a successful outcome following a period of active surveillance.

CASE DESCRIPTION: A full-term boy who presented with a high anorectal malformation (ARM) and a recto-prostatic fistula underwent a colostomy at 1st day of life. Associated malformations included bilateral low grade reflux, a horseshoe kidney and a thoracic hemi-vertebrae; no signs of spinal cord tethering. Antimicrobial prophylaxis was started. At the age of 3 months,

he underwent a LAARP with a 3 abdominal-port approach. After complete dissection of the distal bowel, the recto-prostatic fistula was identified and ligated with metallic clips. A 10 mm trocar was inserted through the center of the sphincter complex, which was previously identified under laparoscopic view during perineal electrical stimulation. Anorectal pullthrough was accomplished without tension. Bladder remained stented for 14 days. On the 18th postoperative day, a voiding cystometrogram (VC) showed a 15 X 5 mm diverticular image at the level of the membranous urethra. After 6 months, a new VC showed a normal urethra with neither signs of the diverticulum nor strictures; persistence of grade 2 reflux on the right-side and resolution of the reflux on the left. At 1 y.o. the colostomy was closed uneventfully. 2 months later, he has remained UTI free and voiding with a normal flow.

DISCUSSION: This report suggests that LAARP is a feasible approach for ARM, although urethral diverticulum is a major concern. It may evolve without complications, and eventually resolve spontaneously. Active surveillance might be an option in selected asymptomatic patients, however a longer follow-up is advised to constitute better evidence supporting that policy.

KEYWORDS: laparoscopy; pediatrics; anorectal malformations; complications; urethra; diverticulum

P100 ENDOSCOPIC TREATMENT WITH DEFLUX FOR PRIMARY VESICoureTERAL REFLUX: SAME SUCCESS RATE IN SINGLE AND DUPLEX SYSTEMS?

José M. Escala MD, Yair Cadena G. MD, Alessandro Tavares MD, Pedro José López MD, M. Gabriela Retamal MD, Nelly Letelier MD, Ricardo Zubieta MD, Department of Urology, Hospital de Niños. Dr. Exequiel González Cortés, Santiago, Chile

OBJECTIVE: Efficacy of a single endoscopic injection for treatment of primary vesicoureteral reflux (VUR) has been debated and the factors predictive of success are controversial in the literature. In the last 3 years our unit have been using Deflux[®], (dextranomer copolymer in hyaluronic acid) for this pathology. The aim of this study is to analyze the results of our experience for single and duplex systems.

METHODS: Patients who underwent endoscopic treatment with Deflux[®] for primary VUR at our Institution have been prospectively followed. Parameters analyzed included demographic data, preoperative grade of VUR, presence of a duplex system and amount of substance injected. The technique applied was the STING previously described. Follow-up studies included a renal ultrasound 1 month after treatment and a voiding cystography (VC) 3 months after the injection. Times of hospitalization and perioperative complications were noted. Success was defined as absence of VUR on the VC.

RESULTS: Twenty-five patients (21 girls, 4 boys) met the inclusion criteria. Mean age was 6.1 years (range 2-14). There were 12 cases of unilateral and 13 cases of bilateral pathology, adding up to a total of 38 renal units treated. Grades I to V corresponded to 16%, 29%, 47%, 5% and 2% of the ureters, respectively. Six patients had VUR into a duplex system. All procedures were performed on an outpatient basis. There were no perioperative complications. The overall success rate in this series was 73.6%. For single systems, the success rate was 84.3% but for duplex systems it was only 16.7% (p=0.003). The success rate for VUR grades I and II in single systems was 100%. The amount of substance injected (0.3 to 1.0 cc per ureter) was not predictive of success.

CONCLUSIONS: The endoscopic treatment for VUR with Deflux is a safe and effective alternative to treat primary VUR, especially for patients with low grade VUR and single systems. The authors suggest that these patients, who are often left on prolonged medical therapy, can be offered the alternative of this minimally-invasive treatment. Patients with VUR to duplex systems had a poor response to a single injection treatment, although this is a preliminary experience.

KEYWORDS: Endoscopic, vesicoureteral reflux, children

P101 LAPAROSCOPIC RENAL SURGERY IN PEDIATRICS: TECHNICAL OPTIONS AND TIPS FOR THE SURGEON IN THE BEGINNING OF THE LEARNING CURVE

Pedro José López MD, Alessandro Tavares MD, Yair Cadena G. MD, Vanessa Muñoz MD, José M. Escala MD, M. Gabriela Retamal MD, Nelly Letelier MD, Ricardo Zubieta MD, Department of Urology, Hospital de Niños Dr. Exequiel González Cortés, Santiago, Chile

OBJECTIVE: To compare the safety and efficacy of technical alternatives that can be used in the beginning learning curve for laparoscopic renal surgery.

METHODS: Charts of all patients who underwent a laparoscopic renal procedure at our institution were reviewed (Jan 2001-Dec 2006). Demographic data, surgery performed and outcomes were analyzed. Transperitoneal access (TPA) and retroperitoneal access (RPA) were compared to identify if at the beginning of the learning curve there is a safer access.

RESULTS: Thirty-nine out of 44 patients had data available. (23 boys, 19 girls). Mean age was 5.7 years (range 8 months to 14 years-old). The TPA was used in 29 (74%) cases and the RPA in 10 (26%) cases. Demographic data, distribution of procedures performed and postoperative outcomes for patients were similar for both types of access (p>0.05). There was no difference in the frequency of conversions or complications despite the approach method; however, RPA was performed by a surgeon trained in RPA overseas. Ablative procedures consisted of nephrectomies (17), nephroureterectomies (12) and upper pole heminephroureterectomy (1), making up 77% of the procedures performed. Reconstructive procedures consisted of pyeloplasties (9), corresponding to 23% of the number of procedures. Pyeloplasty techniques included; video-assisted pyeloplasty (anastomosis is performed extracorporeally) (n=5), intracorporeal Fenger pyeloplasty (n=2) and 2 recent cases of dismembered pyeloplasties with intracorporeal suturing. After a mean follow-up of 28.4 months (range 2-70), the 9 patients show clinical and radiological signs of success.

CONCLUSIONS: In this series, safety of both TPA and RPA seemed to be similar, regarding frequency of conversions and incidence of perioperative complications. It seems that once the surgeon has received training for a specific type of access, both the TPA and the RPA appear to be good options to start with. In this series ablative procedure were the most commonly performed (77%) and starting with them may be a logical choice at the beginning of the laparoscopy practice. When starting with reconstructive procedures, the video-assisted pyeloplasty may be an attractive option, especially for smaller children; although a larger number of patients is warranted.

KEYWORDS: laparoscopy, pediatrics, kidney, learning curve, teaching

P102 IS THE LAPAROSCOPIC APPROACH FOR IMPALPABLE TESTIS STILL THE GOLD STANDARD?

Pedro José López MD, Lorena Angel MD, Jorge Rodríguez MD, Danielle Reyes MD, José M. Escala MD, M. Gabriela Retamal MD, Nelly Letelier MD, Ricardo Zubieta MD, Department of Urology, Hospital de Niños Dr. Exequiel González Cortés. Hospital Luis Calvo Mackena. Santiago, Chile

OBJECTIVE: To assess if the laparoscopic approach, as a first procedure for the impalpable testes (IPT), is still the gold standard investigation.

METHODS: A case note review of boys with a diagnosis of IPT who underwent laparoscopy between January 2000 and December 2005 was conducted. Details of the laparoscopic findings and subsequent surgery were documented.

RESULTS: Sixty-three patients with 74 IPT were identified; 25 were not palpable at the left side, 26 at the right side and 12 bilaterally. The mean age at diagnosis was 3.6 years (1m-13y). Thirty-seven cases had a pre-op US: in 29 (78%) the testis was not found; in 7 the testis was intra-canalicular. All were impalpable at EUA. The mean age at surgery was 4.9 years (2m-17y). Under laparoscopic view, 38/74 the vas and vessels entered the deep ring, therefore an open exploration was performed; 13 were atrophic / vanishing and 23 underwent an orchidopexy (2/23 described as small testis). Of the 36 intra-abdominal testes, 12 were vanishing; 8 underwent a laparoscopic-assisted single stage orchidopexy. The other 16 underwent a 1st stage F-S. There were 3 atrophic testicles; 2 after a 2nd stage F-S and 1 after a failed single stage orchidopexy.

CONCLUSIONS: Of 74 IPT, 38 (51%) were in the inguinal canal, despite that ultrasound and EUA failed to pick them up (13/38 were atrophic / vanishing). Therefore, in 66% (49/74) of the children in this series laparoscopic exploration was critical in determining the localization of the testis. The authors suggest that the laparoscopic approach is still the first procedure needed for IPT.

KEYWORDS: Laparoscopy, Nonpalpable testis, Orchiopexy, Atrophy

P103 RETROPERITONEAL PYELOPLASTY IN CHILDREN. THE NEW GOLD STANDARD

Juan Moldes PhD, Maria Ormaechea MPH, Carlos Giusepucci MPH, Marcelo Urquiza Lino MPH, Martin Alarcon MPH, Francisco de Badiola PhD, Eduardo Ruiz PhD, Section of Pediatric Urology, Department of Pediatrics, Hospital Italiano de Buenos Aires, Buenos Aires, Argentina

PURPOSE: Ureteropyelic junction obstruction (UPJO) is the most common congenital urinary obstructive pathology in children. We present and compare our experience with Transperitoneal and retroperitoneal pyeloplasty in children.

MATERIALS AND METHODS: Between January 1999 and May 2003 a laparoscopic trans abdominal dismembered pyeloplasty (TDP) was performed in 14 patients with confirmed UPJO (Group 1). The mean age at surgery was 13,6 years (range 9-17) and mean weight of 51,6 kg (range 28-69). Between June 2003 and March 2006, 13 patients with UPJO underwent a laparoscopic retroperitoneal dismembered pyeloplasty (RDP) (Group 2). The mean age at surgery was 11,5 years (range 5-27) and mean weight of 37 kg (range 20-80). Only 2 patients in both groups (7%) had prenatal diagnosis. Ultrasound showed hydronephrosis in all patients and an obstructive pattern in the DTPA scan. The presenting symptoms were similar in both groups being lumbar pain the most frequent (87 % patients in Group 1 and 70 % in Group 2). 97 % of the patients required some type of internal or external stent. Double J stent was used in 57 % of patients in Group 1 and 92% of patients in Group 2. The average operating time was 207 minutes in Group 1 (range 150-290) and 150 minutes in Group 2 (range 100-180). There were no intraoperative complications in Group 1. In Group 2 there were 2 rupture of the peritoneum due to the insertion of the second trocar. In both cases the UPJ was mobilized and the anastomosis performed through the 10 mm trocar incision. Mean hospital stay in Group 1 was 1,9 days (range 1-4) and 1,2 days in Group 2 (range 1-2). Media follow up was 62 months (range 36-96) in TDP group and 17 months (range 8-26) in RDP group.

RESULTS: All patients in both groups, except one in Group 2, decreased the hydronephrosis on the ultrasound. No patients referred symptoms until now.

CONCLUSIONS: Both transperitoneal and retroperitoneal approaches show similar advantages when compared with one another. Nevertheless, the dissection of the pyeloureteral union by a retroperitoneal approach is sensibly more direct and faster. This fact along with the theoretical advantage of managing a potential complication in the retroperitoneal space make us electively choose the retroperitoneal approach for our cases.

P104 LAPAROSCOPIC SIGMOID VAGINOPLASTY

Rahsan Vargun-Yildiz MD, Esra Temeltas MD, Bilal Alper MD, Berkutug Bahadir MD, Gulnur Gollu MD, Aydin Yagmurlu MD, Department of Pediatric Surgery, Ankara University School of Medicine

AIM: To demonstrate the possibility of laparoscopic reconstruction of vagina using pedicled sigmoid autograft and provide a new procedure of vaginoplasty.

METHODS: Laparoscopic sigmoid colovaginoplasty was performed in a 14 year old, complete androgen resistance syndrome child. A twelve centimeters segment of the sigmoid colon on its vascular pedicle was selected and isolated using an ultrasonic dissector and staplers. Sigmoid colon continuity was restored via a circular stapler. Meanwhile, a neovaginal tract was formed with blunt dissection under perineal and laparoscopic vision. The neovagina from sigmoid colon was reversed to reach the perineum through the peritoneal incision at the top of the neovaginal tract. Distal end of the neovagina was sutured to the distal 1/3 rd. of the vagina.

RESULTS: There were no intraoperative or postoperative complications. The whole procedure was completed in 90 minutes. Neovaginal calibration was adequate with mucus and moistness.

CONCLUSION: The advantages of laparoscopic sigmoid vaginoplasty are as follows (1) satisfactory neovaginal function similar to a normal vagina with mucus and moistness, (2) minimal scarring in abdominal wall (3) no need for frequent dilation or stent wearing to the reconstructed vagina. Hence, laparoscopic vaginoplasty must be the preferred alternative for vaginal reconstruction in children with no native vagina.

P105 LAPAROSCOPIC URETEROCUTANEOSTOMY FOR URINARY DIVERSION IS A FEASIBLE OPTION IN INFANTS

Martin L Metzelder MD, Claus Petersen PhD, Benno M Ure PhD, Hannover Medical School, Department of Pediatric Surgery, Hannover, Germany

BACKGROUND: Obstructive or refluxive uropathy may obviate the need of temporary urinary diversion. However, stenosis and retraction are frequently associated with this technique. We report on our experience with laparoscopic ureterocutaneostomy in infants, which has not been described yet.

PATIENTS AND METHODS: Four infants underwent laparoscopic loop ureterocutaneostomy (4 male, mean age 7 months, range: 1 to 13). The indication was megaureter with deterioration of kidney function due to primary obstructive megaureter in 2, posterior urethral valves in 1, and refluxive uropathy of a dysplastic single-kidney in another case. A transabdominal 3 trocar technique was used. The ureter was identified upper to the crossing the iliac vessels and a loop was placed around the ureter. The ureter was then exteriorized under videoscopic guidance through a widened trocar incision and a loop ureterocutaneostomy was performed in 3, an end ureterocutaneostomy in 1 patient.

RESULTS: Laparoscopic ureterocutaneostomy was feasible and technically easy to perform. The mean operation duration was 111 min. (range: 85 to 145 min.) without complications. There was no revision for stenosis or retraction. The patient with a single kidney and end ureterocutaneostomy required kidney transplantation due to progressing renal failure.

CONCLUSIONS: The feasibility of laparoscopic ureterocutaneostomy in infants is excellent. We postulate that complications such as stenosis and retraction can be avoided by the atraumatic approach and less scarring. Thus, in cases with the need of temporary ureteral diversion, the laparoscopic technique should be preferred.

P106 SPLENOGONADAL FUSION: CASE REPORT

Karim Khelif MD, Sebastian Ralea MD, Frank Collier MD, University Children's Hospital Queen Fabiola / Brussels - Belgium

INTRODUCTION: Splenogonadal fusion is a rare congenital malformation resulting from fusion of the spleen and the gonad anlage, with about 150 cases reported in the literature. Even more uncommon is splenic ectopic tissue discovered in the epididymis or spermatic cord.

CASE REPORT: We report the case of a continuous splenotesticular fusion in a 1-year-old child with an intra-abdominal left testis, a normal right testis and penoscrotal hypospadias. At laparoscopy, a beaded-type splenogonadal fusion was identified and resected en bloc. The resection decision was based upon 2 uncommon findings: Firstly, the splenogonadal tissue was entirely supplied by a branch of the splenic artery, with a non existing spermatic pedicle, rendering testicular conservation technically impossible. Secondly, a splenic nodule was tightly fused with the epididymis, in a way to be interposed between the latter and the testis. This anatomical presentation suggested a compromised exocrine function and would have left no possibility to separating structures without damaging the remaining testis. Histopathological examination revealed testicular obstructive features e.g. dilated seminiferous tubules, and intraluminal calcifications.

DISCUSSION: Testicle salvage is the recommended approach in these uncommon anomalies. However, various anatomical and physiological specific characteristics should be taken into account when establishing treatment strategy in these rare cases.

P107 LAPAROSCOPIC 2 STAGES FOWLER STEPHEN PROCEDURE FOR HIGH ABDOMINAL TESTES

Amin Gohary MD, Mafrag Hopsital

Between 1996 and 2006 both diagnostic and operative laparoscopy was used in the management of 189 impalpable testes. 66 were either vanishing or atrophied, 17 were found in the inguinal canal, 19 in the groin and 87 intra-abdominal of which 37 were high abdominal testes. 33 of the later were managed by laparoscopic 2 stage Fowler ? Stephen (FS) procedure, in which the vessels were clipped during the 1st stage and 3-6 months later the testes are brought down to the scrotum based on the established collaterals and artery to the Vas. 26 of our patients (79%) achieved good scrotal position and 23 in mid scrotal position and 4 became atrophied. Most of the bad result were during the early learning curve. We believe that Laparoscopic 2 stage FS operation is the procedure of the choice for high abdominal testes as it saved the patient 2 exploratory open procedure whose result are no better than the laparoscopic technique.

P108 LAPAROSCOPIC PERITONEAL DIALYSIS CATHETER PLACEMENT IN CHILDREN WITH PREVIOUS INTRA-ABDOMINAL PROBLEMS

Abraham Cherian MD, Manoj U Shenoy MD, Alun R Williams MS, Department of Paediatric Urology, Nottingham University Hospital (City Hospital Campus), Nottingham, UK

AIM: To assess the safety and appropriateness of laparoscopic placement of peritoneal dialysis (PD) catheters in abdomens with previous intra-abdominal pathology.

METHODS: A retrospective case note review of patients who needed peritoneal dialysis with previous intra-abdominal surgery or complications was undertaken. These were patients from a single centre over a period of 18 months.

RESULTS: There were a total of ten patients (six females and four males) with previous intra-abdominal surgery or complications. Age ranged from 1.5 to 14 years with a mean of 10.3 years. Follow up ranged from one to 18 months. The details of problems with additional procedures carried out are summarised in the table below. Successful placement of catheters was achieved in all except patient-9 (complicated by bleeding tract). In patient-10 dialysis was unsuccessful 10 days after insertion.

CONCLUSION: Laparoscopic placement of peritoneal dialysis catheters is safe and is the preferred technique as they can be placed in the best possible recess under direct endoscopic vision and is also a tool to diagnose and deal with previously failed catheters.

| Patient No | No of previous PD placements | Previous intra-abdominal problem | Additional procedures performed at the time of catheter placement |
|------------|------------------------------|--|---|
| 1 | 2 | Peritonitis - 2 episodes | None |
| 2 | 3 | PD catheter encased by omentum and small bowel | Successful dissection, excision of omentum and placement of new catheter |
| 3 | 2 | Peritonitis - 2 episodes | None |
| 4 | 2 | Peritonitis with complex mass formation | Successful dissection and removal followed by placement of a new catheter 10 months later |
| 5 | 0 | 2 Liver transplants 10 years prior | None |
| 6 | 1 | Peritonitis - 5 episodes | Nephrectomy and gonadectomy |
| 7 | 0 | Mitraloff 8 years prior | None |
| 8 | 0 | Nissen Fundoplication 4 months prior | None |
| 9 | 1 | Peritonitis - 3 episodes with Pseudomonas | None |
| 10 | 2 | Peritonitis - 1 episode, Open gastrotomy | Extensive adhesiolysis required |

P109 LAPAROSCOPIC ADRENALECTOMY IN CHILDREN- 2 CENTRES EXPERIENCE

Marcin Losin MD, Ireneusz Dauksza PhD, Przemyslaw Mankowski PhD, Piotr Czauderna PhD, Andrzej Jankowski PhD, 1. Department of Surgery and Urology for Children and Adolescents, Medical University of Gdansk 2. Department of Pediatric Surgery and Traumatology, Medical University of Poznan

BACKGROUND: Since 1992, when laparoscopic adrenalectomy (LA) has been first described, it has become a treatment of choice in benign and malignant adrenal lesions. Most of reports of laparoscopic adrenalectomy deals with adult, while experience with pediatric LA is still somehow limited, especially the role of LA in malignancy in pediatric population is still not well defined. We reviewed retrospectively our two centre experience with laparoscopic adrenalectomy in children.

METHODS: This retrospective two centre study included eight children (two boys, six girls), aged from 2 weeks to 15 years (mean 7 years) treated between May 2005 to January 2007. There were 5 cases of neuroblastoma, one of adrenal haematoma, 1- pheochromocytoma and 1 - lymphangioma. All lesions were detected postnatally.

RESULTS: All adrenal lesions were resected completely by transperitoneal approach. Three to six trockars were used and intraabdominal CO2 pressure was 10-12 mm Hg during procedures. In one case conversion to open procedure was necessary due to technical problems. There were no postoperative complications. Blood transfusion was not required. Mean operative time was 120 minutes. Mean hospital stay was 6 days. All children are alive. Postoperative follow-up ranged from 2 to 15 months (mean 4 month). In all neuroblastoma cases no metastases or local recurrence occurred.

CONCLUSION: Laparoscopic adrenalectomy in children, even in neuroblastoma, is safe and feasible, albeit to assess its role within the frames of multidisciplinary oncological approach collection of further multicenter experience is necessary.

P110 LAPAROSCOPIC COLOCYSTOPLASTY: THE IDEAL SURGERY FOR THE SELECTED PATIENT

Lisandro A Piaggio MD, Nestor H Piaggio MD, Pablo Long MD, Gustavo Sofia MD, Hospital Italiano Regional del Sur, Bahia Blanca, Bs. As. ARGENTINA

INTRODUCTION: bladder augmentation with different tissues is the standard of care for neurogenic bladder with failed medical treatment

MATERIAL AND METHODS: We present a video demonstrating our technique of laparoscopic colocolocystoplasty. The patient is a 12-year-old boy with neurogenic bladder secondary to myelomeningocele with a hypertonic noncompliant bladder despite maximum dose of anticholinergic medication. The patient catheterizes through urethra and is dry between catheterization. He is continent of stool, ambulates and has no VP shunt. We performed a transperitoneal approach with five ports: 18mm, 10mm (2) and 5mm (2). The bladder was extensively exposed. A 20 cm segment of sigmoid colon was isolated between two 60mm endostaplers. Bowel continuity was established with a 19mm circular stapler exposing the proximal colon through the belly bottom for anvil head placement. Bowel reconfiguration was performed exposing the isolated segment through the belly bottom. The bladder was extensively opened and colocolocystoplasty performed with two running sutures of polydioxane 3-0. A suprapubic tube was placed and exteriorized through one of the port sites.

RESULTS: The procedure was successfully performed with minimal blood loss. Bowel function was recovered in 36 hs. Patient was discharged home on postoperative day 4. Intravenous narcotic requirement was minimal. The suprapubic tube was discontinued at three weeks and patient resumed intermittent catheterization remaining dry. Serum creatinine level at 1 month postoperative decreased from baseline.

CONCLUSION: Laparoscopic colocolocystoplasty is a promising technique for selected patients with neurogenic bladder.

P111 KIDNEY DUPLICATION PRESENTING AS A PSEUDOTUMOR: LAPAROSCOPIC DIAGNOSIS AND TREATMENT

Lisandro A Piaggio BA, Ricardo Gonzalez BA, A I DuPont Hospital for Children, Wilmington, DE and Hospital Italiano Regional del Sur, Bahia Blanca, BA, Argentina

INTRODUCTION: Suprarenal tumors in the newborn present a variety of diagnosis, from benign lesions such as adrenal hemorrhage, sequestration or kidney duplication to potentially lethal tumors like neuroblastoma. We present a video, which demonstrates the laparoscopic diagnosis and treatment of a dysplastic upper pole of a duplicated kidney.

MATERIAL AND METHODS: a 2-month-old baby with a history of antenatal diagnosis of cystic tumor in relation to the right kidney presented with persistence of a suprarenal mass with increased solid component and internal doppler sign. The urinary tract was normal by ultrasonography and voiding cystourethrography. There was no ureteral dilatation. With presumed diagnosis of adrenal tumor an exploratory laparoscopy was performed.

RESULTS: Urethrocystoscopy at the beginning of the case revealed no abnormalities. On laparoscopic exploration the adrenal gland was normal. The right kidney was duplicated, with a dysplastic upper pole, which was excised laparoscopically. Blood loss was minimal and postoperative outcome uneventful.

CONCLUSIONS: laparoscopic exploration may be a useful tool for suprarenal masses that persist beyond the neonatal period.

P112 LAPAROSCOPIC TRANSURETEROURETEROSTOMY. A NOVEL APPROACH

Lisandro A Piaggio MD, Ricardo González MD, Division of Urology, A I duPont Hospital for Children, Wilmington, DE and Department of Urology Hospital Italiano Regional del Sur, Bahía Blanca, BA, Argentina

INTRODUCTION: Transureterooureterostomy (TUU) has become an indispensable part of the armamentarium for reconstructive urologic surgery. We present a video demonstrating a novel laparoscopic approach for TUU and our initial experience with this surgery in children.

METHODS: We performed a transperitoneal laparoscopic transureterooureterostomy (LTUU) with a 4-trocar technique: 5mm (1), 3 mm (3) in 3 children. Mean age (range) was 63 months (18-105). Diagnoses were unilateral ureteral obstruction after cross-trigonal reimplantation for vesicoureteral reflux, unilateral refluxing megaureter and ureteral injury after bladder diverticulectomy, one each. Cystoscopy, retrograde pyelogram and

stent placement in the recipient ureter were performed at the beginning of the case. The table was turned to elevate the side of the ureter to work. The donor ureter is dissected distally as close to the bladder as possible and ligated. The recipient ureter was exposed and a longitudinal ureterotomy on the medial aspect of the recipient ureter was performed to match the lumen of the donor ureter. A tunnel under the rectosigmoid mesentery was created to bridge the two peritoneal windows and the donor ureter transposed. The anastomoses were carried out with running 6-0 reabsorbable sutures at the level of the pelvic bream. An abdominal drain and Foley catheter were kept for 1-3 days.

RESULTS: All cases were performed successfully. Mean operative time including cystoscopy (range) was 260 (200-313) minutes. Mean estimated blood loss and difference in pre and postoperative hemoglobin were 47 ml and 0.3 gr/dl respectively. Mean postoperative morphine and ketorolac requirement were 0.2 mg/kg and 1.5 mg/kg respectively. Postoperative course was uneventful except for a transient urinary leak and patients were discharged home on postoperative day 2-4. At a mean follow up of 9 months all patients were clinically well with normal kidney function, blood pressure and no significant hydronephrosis.

CONCLUSIONS: In our initial experience LTUU was safe and effective and was associated with little blood loss, minimal analgesia requirement, fast recovery and excellent cosmetic results. We believe that in selected cases in which a transureteroureterostomy is the chosen technique, a laparoscopic approach is advantageous.

P113 LAPAROSCOPIC URACHAL EXCISION

Lars J Cisek MD, Texas Children's Hospital / Baylor College of Medicine

INTRODUCTION: Urachal anomalies represent persistence of part or all of the embryonic connection between the bladder and allantois. The presentation can include umbilical drainage (persistent urachus), infection, pain and hematuria. The natural history of symptomatic urachal anomalies is that of recurrent problems and excision is warranted.

METHODS: Patients presented as noted above. Preoperative imaging included ultrasonography and a voiding cystourethrogram. In patients with periumbilical inflammatory mass presentations, a 2mm port was placed laterally to confirm the diagnosis (eg. urachal vs GI process) following a course of antibiotics to address the acute infection. For excision three 5mm ports were typically placed - upper midline, anterior axillary line above the umbilicus (replacing the prior 2 mm port if used), and at the midpoint between the ports to form a triangle. The urachus is mobilized starting at the umbilicus by opening the anterior peritoneum and freeing the urachus to the contour of the bladder. The lateral aspects of the bladder are tagged with stay sutures and the urachus excised. The bladder is closed in two layers with absorbable running suture. A foley catheter is left indwelling briefly.

RESULTS: 7 patient have undergone excision. All procedures were completed without incident. One 7 year old patient with intermittent gross hematuria had had a previous umbilical hernia repair a urachal hernia repair. In this case secondary ports were shifted inferiorly as the urachus had been released from the anterior abdominal wall and was found on the posterior aspect of the bladder. He had inflammatory pathology only. Specimen extraction was through a port site with enlargement if needed. There were no complications.

CONCLUSION: Laparoscopy affords access to urachal pathology and the ability to define the nature of the tissue found at the umbilicus by direct inspection simplifies evaluation in those patients with inflammatory presentations.

P114 THE MINIMALLY INVASIVE SURGERY FOR THE MINIMAL PATIENT WITH RENAL DUPLICATION

Lisandro A Piaggio MD, Paul H Noh MD, Mark Wehry MD, Amos Nehman MD, Ricardo Gonzalez, A I DuPont Hospital for Children, Wilmington, DE and Hospital Italiano Regional del Sur, Bahia Blanca, BA, Argentina

INTRODUCTION: Duplication anomalies of the urinary tract (DAUT) are commonly diagnosed with antenatal ultrasonography and present a variety of treatment modalities depending on the postnatal workup. We present a video demonstrating two different approaches: a laparoscopic partial nephrectomy (PN) and an uretero-ureterostomy (UU) performed in infants younger than 2 months.

MATERIAL AND METHODS: Patients were evaluated with postnatal ultrasound, voiding cystourethrogram and nuclear medicine renal scans. The surgeries were performed transperitoneally with three ports: 5mm (1) and 3 mm (2). PN was started at the pelvic bream with dissection and transection of the upper pole ureter that was followed proximally up to the renal hilum. It was then dragged from the upper pole of the kidney without dissecting the hilum and use as a handle for parenchymal cut. UU was performed with a running suture of 6-0 polydioxanone at the level of the pelvic bream.

RESULTS: postoperative outcome was uneventful with a fast recovery, minimal analgesia requirement and a short hospitalization. At mean follow up of 12 months all remaining moieties are functional with no hydronephrosis.

CONCLUSION: Laparoscopic PN and UU are safe and effective treatment modalities for DAUT. The treatment should be individualized for each patient and can be performed early in life.

P115 LAPAROSCOPIC EXCISION OF ABDOMINOSCROTAL HYDROCEL. THE FIRST SERIE

Nordeen M Bouhadiba MD, Sean M Marven MD, Prasad M Godbole MD, J S M Valla MD, Sheffield Children's Hospital United Kingdom . Hopital Lenval Nice France

BACKGROUND: Abdominoscrotal hydrocele is increasingly encountered form of congenital hydrocele. There are significant risks, including the pressure effect on uropelvic structures, rupture, haemorrhage and malignant transformation. The best cure is complete excision. There is no report of laparoscopic excision. We present the first series including the practice of two centres.

METHOD: we collected the data of five patients in two centres. Two were excluded as in the first patient the abdominoscrotal hydrocele was recognized during open surgery. In the second patient the diagnosis was confirmed by hernioscopy. however the cure was done primarily by open surgery. A total of three patients were treated in the first intention by laparoscopy

RESULTS: two patients from the first centre and two from the second centre were operated on primarily by laparoscopy. Three ports were used. The intra-abdominal component was completely dissected by laparoscopy. A short inguinal incision allowed the dissection of the scrotal part and the intact delivery of a dumbbell shaped abdominoscrotal hydrocele.

CONCLUSION: laparoscopic excision of ASH is more advantageous than the open approach. It is safe, easier and offer excellent visualisation with magnification. There is a limited dissection and a good preservation of the inguinal canal anatomy. Based on our experience we advocate this new technique in the treatment of ASH

EVALUATION & CME CREDIT FORMS

*Please complete the meeting evaluation form
and return to the registration desk.*