LOVE FOR CHILDREN
THROUGH TECHNOLOGY

IPEG's
14TH Annual Congress for Endosurgery in Children

June 1 - 4, 2005

VENICE LIDO, ITALY

(PALAZZO DEL CINEMA & PALAZZO DEL CASINO)

Joint Meeting with EAES

Important Dates:

Opening Ceremony & Welcoming Reception: June 1, 2005
Postgraduate Courses: June 1, 2005
Closing: June 4, 2005

SIVI Participation (6th Congress)

Designed With Children In Mind

Karl Storz Pediatric Laparoscopic Instrumentation



STORZ

60 YEARS KARL STORZ – ENDOSCOPY

1945 – 2005

KARL STORZ Endoscopy-America, Inc., 600 Corporate Pointe, Culver City, CA 90230-7600, USA, Phone: (310) 338-8100, Fax: (310) 410-5530, E-Mail: info@ksea.com
KARL STORZ GmbH & Co. KG, Mittelstraße 8, D-78532 Tuttlingen/Germany, Phone: + 49 7461 / 70 80, Fax: 07461 / 70 81 05, E-Mail: karlstorz-marketing@karlstorz.de
KARL STORZ Endoscopy-Canada, Ltd., 2345 Argentia Road, Suite 100, Mississauga, Ontario, Canada L5N 8K4, Phone: (800) 268-4880, Fax: (905) 858-0933
KARL STORZ Endoscopia, Latino-America, 815 NW 57 Ave, Suite #480, Miami, Florida 33126-2042, USA, Telefono: (305) 262-8980, Telefax: (305) 262-8986

www.karlstorz.com

EN-SUR 54/E/3/03/A

© 2004 Karl Storz Endoscopy-America, Inc.

Registration Hours

Wednesday, June 1, 2005:	13:30 – 17:30
Thursday, June 2, 2005:	07:30 – 16:30
Friday, June 3, 2005:	07:30 – 16:30
Saturday, June 4, 2005:	07:30 – 12:30

Exhibit Hall Hours

Wednesday, June 1, 2005: (Welcome Reception)	19:00 – 21:00
Thursday, June 2, 2005:	09:30 – 17:00
Friday, June 3, 2005:	09:30 – 17:00
Saturday, June 4, 2005:	09:30 – 13:00

General Business Meeting Announcement:

Saturday, June 4, 2005, 12:30 - 13:30
Location: Teatro Perla, Room 6, Palazzo del Casino

All IPEG members are invited to attend the annual IPEG business meeting, at which the committee chairs will update the membership on business conducted during the past year. Additionally, the new slate of officers will be presented for approval.

Table of Contents

1. Registration Hours
3. Meeting at a Glance
4. IPEG Meeting Leaders and Executive Committee
4. General Information
4. Corporate Sponsors
5. Hands-On Suturing Techniques Course
7. Bariatric Satellite Symposium
9. Societá Italiana di Videochirurgia Infantile
9. Opening Ceremony
9. Welcome Reception
11. IPEG Scientific Sessions
13. Presidential Lecture
15. Keynote Lecture – Error Management in Aviation
16. Membership Information
18. Karl Storz State of Art Lecture – New Developments in Virtual Reality and Advanced Surgical Technology
20. IPEG Faculty
23. Disclosures
26. SIVI Abstracts
34. Oral Program Abstracts
58. Poster Abstracts
97. Video Abstracts
99. Meeting Venues Floor Plan
100. Exhibitor Information

stryker®

One Company,
One Solution

i-Suite® Operating Rooms

integration – One point of contact to intergrate multiple technologies

innovation – Connectivity to all areas of the hospital and the world

information – The right support through every phase

Please visit the Stryker booth for more information regarding our i-Suite® OR technology.

IPEG 2005 Meeting at a Glance

Wednesday, June 1, 2005

08:00 - 12:00 **Hands-on Suturing Techniques Course**
IPEG Chairperson(s): Gordon A. MacKinlay, MD; Henri Steyaert,MD; David van der Zee, MD;
EAES Chairperson: K.H. Fuchs, MD

12:00 - 13:00 **Lunch Break**

13:00 - 16:00 **Bariatric Satellite Symposium**
Chairperson: Thomas H.Inge, MD

12:00 - 16:30 **6th Congress of the Societá Italiana di Video Chirurgia Italiana (SIVI)**
Chairperson: Mario Lima, MD

18:00 - 19:00 **Opening Ceremony EAES/IPEG**

19:00 - 21:00 **Exhibition Reception**

Thursday, June 2, 2005

08:00 - 09:00 **Breakfast – Video Session** *Chairperson(s): Munther Haddad, MD; Celeste Hollands, MD*

09:15 - 09:20 **Welcome Address** *Speaker(s): Klaas (N) M.A.Bax, MD; Benno M.Ure, MD*

09:20 - 10:20 **Scientific Session – Esophagael Atresia Panel**
Chairperson(s): Marcelo H. Martinez-Ferro, MD; Thom E. Lobe, MD

10:20 - 10:50 **Coffee Break**

10:50 - 11:35 **Best rated papers** *Chairperson(s): C.K.Yeung, MD; Carroll M. Harmon, MD*

11:35 - 13:00 **Scientific Session – Free Papers** *Chairperson(s): Felix Schier, MD; Francois Becmeur, MD*

13:00 - 14:30 **Lunch Break**

14:30 - 15:00 **Presidential Lecture** *Speaker: Klaas (N) M.A.Bax, MD*

15:00 - 16:30 **Scientific Session –** *Chairperson(s): Chris Kimber, MD; Jean-Stéphane Valla, MD*

16:30 - 17:00 **Coffee Break**

17:00 - 18:00 **Scientific Session – Short Papers/Posters** *Chairperson(s): Craig Albanese, MD; Marc A. Levitt, MD*

Friday, June 3, 2005

08:00 - 09:00 **Breakfast – Video Session** *Chairperson(s): Thom Lobe, MD; Behrouz Banieghbal, MD*

09:00 - 09:30 **Keynote Lecture – Error Management in Aviation** *Speaker: Manfred Müller, MD*

09:30 - 10:00 **Coffee Break**

10:00 - 11:45 **Joint Session IPEG-EAES on Gastroesophageal Reflux**
Chairperson(s): Keith E. Georgeson, MD; K.H. Fuchs, MD; Girolamo Mattioli, MD

11:45 - 13:15 **Scientific Session – Free Papers** *Chairperson(s): Mark L. Wulkan, MD; Philippe Montupet, MD*

17:45 - 23:00 **An Evening Tour to Torcello with dinner at Locando Cipriani**

Saturday, June 4, 2005

08:00 - 09:00 **Scientific Session – Short Papers/Posters** *Chairperson(s): John H.T. Waldhausen, MD; Hock L. Tan, MD*

09:15 - 11:00 **Scientific Session – Oncology Panel** *Chairperson(s): Benno M.Ure, MD; Steven S. Rothenberg, MD*

11:00 - 11:30 **Coffee Break**

11:30 - 12:00 **Karl Storz State of the Art Lecture –**
New Development In Virtual Reality and Advanced Surgical Technology
Speaker: Jacques Marescaux, MD

12:00 - 12:30 **IPEG General Assembly**

12:30 - 13:30 **Scientific Session – Free Papers** *Chairperson(s): Azad S. Najmaldin, MD; Jürgen Schleef, MD*

13:30 - 13:40 **Closing Remarks and Presentation of 2006 President**
Speaker(s): Klaas (N) M.A.Bax, MD; Keith E. Georgeson, MD

13:40 - 15:00 **Farewell Lunch**

AFTERNOON & EVENING FREE

IPEG General Information

Administrative Office:

International Pediatric Endosurgery Group (IPEG)
11300 West Olympic Blvd., Suite 600
Los Angeles, CA 90064 USA
Phone: +1 310-437-0553 Ext. 120 or 122
Fax: +1 310-437-0585
Email: admin@ipeg.org Website: www.ipeg.org
Joyce Hasper – Executive Director

Meeting Location:

Venice Lido, Italy, Palazzo Del Cinema & Palazzo Del Casino
Liodo Lungomare G. Marconi 30, 30127 Venice
Phone: +39 041 24 20 330 Fax: +39 041 52 62 233
E-mail: info@veniceconvention.com
Website: www.veniceconvention.com

The venue consists of two buildings adjacent to each other located on the Lido, one of the islands of Venice, about a 10 minute ferry ride from the old Town of Venice. The buildings are exquisite, portraying some of the finest in Italian Architecture and breath the atmosphere of ageless grandeur.

One building is called the Palazzo del Casino, which holds the main IPEG Auditorium and will host the main exhibition. The Casino will house the EAES poster area and the surgical skills centre. The other building is called the Palazzo del Cinema; it is here where the main EAES Auditorium and some of the session's rooms will be. In addition the IPEG posters and some exhibits will be in this area.

Both buildings will be connected together by means of a tunnel of pagoda temporary structures and a central registration area.

Goals for IPEG's 14th Annual Congress for Endosurgery in Children:

- To advance the use of minimally invasive endoscopic surgical procedures in children.
- To explore the value of new minimally invasive surgical concepts and new endoscopic surgical techniques for use in children.
- To discuss controversial topics in pediatric endosurgery and the future role of endosurgery in children.
- To provide opportunity for younger surgeons to acquire a knowledge of endoscopic surgical procedures in children through exposure to experts in the field.
- To provide workshops to disseminate practical skills.

IPEG 2005 Corporate Support

IPEG gratefully acknowledges generous unrestricted educational grants in support of this meeting

Platinum Support

AutoSuture/Valleylab and Tyco Healthcare International
Ethicon Endo-Surgery
Fleet Pharmaceuticals
Karl Storz Endoscopy, Inc.
Stryker Endoscopy

Bronze support

Taut, Inc.

IPEG Meeting Leaders

Program Chairman: Benno M. Ure, MD
Co-Chairmen: Mark L. Wulkan, MD & C.K. Yeung, MD

Video Sessions Chairman: Munther Haddad, MD
Co-Chairman: Girolamo Mattioli, MD

Hands-On Course Chairman: Gordon A. MacKinlay, MD
Co-Chairmen: IPEG-Henri Steyaert, MD & David C. van der Zee, MD; EAES-Karl-Hermann Fuchs, MD

Bariatric Symposium Chairman: Thomas H. Inge, MD

Executive Committee

President – Klaas (N) M.A. Bax, MD
President Elect – Keith E. Georgeson, MD
Vice President – Atsuyuki Yamataka, MD – Asia/Africa
Jean-Stéphane Valla, MD – Europe
Secretary – Marcelo H. Martinez-Ferro, MD
Treasurer – Steven S. Rothenberg, MD
Editor (PEIT) – Thom E. Lobe, MD
Past President – C. K. Yeung, MD

Representatives:

Asia/Africa – Behrouz Banieghbal, MD
Europe – Gordon A. MacKinlay, MD
Americas – George W. Holcomb III, MD

Program Committee

Craig T. Albanese, MD – *Stanford,* California, USA
Klaas (N) M.A. Bax, MD – *Utrecht,* THE NETHERLANDS
Peter A. Borzi, MD – *Woolloongabba,* Brisbane, AUSTRALIA
Ciro Esposito, MD – *Naples,* ITALY
Keith E. Georgeson, MD – *Birmingham,* Alabama, USA
Munther Haddad, MD – *London,* U.K.
Carroll M. Harmon, MD – *Birmingham,* Alabama, USA
George W. Holcomb III, MD – *Kansas City,* Missouri, USA
Thomas H. Inge, MD – *Cincinnati,* Ohio, USA
Marc A. Levitt, MD – *New Hyde Park,* New York, USA
Mario Lima, MD – *Bologna,* ITALY
Thom E. Lobe, MD – *Des Moines,* Iowa, USA
Gordon A. MacKinlay, MD – *Edinburgh,* Scotland, U.K.
Marcelo H. Martinez-Ferro, MD – *Olivos,* Buenos Aires, ARGENTINA
Girolamo Mattioli, MD – *Genoa,* ITALY
Olivier Reinberg, MD – *Lausanne,* SWITZERLAND
Steven S. Rothenberg, MD – *Denver,* Colorado, USA
Felix Schier, MD – *Mainz,* GERMANY
Jürgen Schleef, MD – *Trieste,* ITALY
Henri Steyaert, MD – *Nice,* FRANCE
Hock L. Tan, MD – *North Adelaide,* SOUTH AUSTRALIA
Benno M. Ure, MD – *Hannover,* GERMANY
Jean-Stéphane Valla, MD – *Nice,* FRANCE
David C. van der Zee, MD – *Utrecht,* THE NETHERLANDS
John H.T. Waldhausen, MD – *Seattle,* Washington, USA
Mark L. Wulkan, MD – *Atlanta,* Georgia, USA
C.K. Yeung, MD – *Hong Kong,* CHINA

HANDS-ON SUTURING TECHNIQUES COURSE

08:00 - 12:00 Location: Room 7 Amici, Palazzo del Casino

Course Directors: Gordon A. MacKinlay, MD; IPEG Co-Directors: Henri Steyaert, MD, David C. van der Zee, MD, Mark L. Wulkan, MD; EAES Co-Director: Karl-Hermann Fuchs, MD; Cushieri Skill Center Co-Director: Graeme D. Adamson, MD

Course Objectives:

Suturing and intracorporeal knotting are considered to be the most difficult endoscopic surgical tasks to perform. After this course, the participants should have mastered these tasks.

- Master the art of intracorporeal suturing
- Perform intracorporeal suturing under tension using the tumbled square knot
- Practice techniques with the aid of
  - Tissue models in Endoscopic simulators
  - Virtual reality trainers
- Have confidence to use the acquired techniques safely in patients

Course Description:

This half-day course provides participants with the practical knowledge and technical skills required during the performance of surgical suturing. Faculty will focus on both lecture and demonstration including video as well as post-course assessments. Using inanimate material, attendees will practice intracorporeal and continuous suturing on either virtual or open-box trainers. Participants will be requested to fill in a questionnaire prior to the course.

Course Outline:

08:00 - 08:05	Introduction and welcome	Gordon A. MacKinlay, MD
08:05 - 08:15	Course pre-assessment and instruction	David van der Zee, MD
08:15 - 08:30	Intra-corporeal suturing lecture	Graeme Adamson, MD
08:30 - 09:00	Individual 3-D suturing practical/ VRT	
09:00 - 09:30	Individual 2-D suturing practical/ VRT	
09:30 - 09:40	Tumbled square knot lecture	Gordon A. MacKinlay, MD
09:40 - 10:00	Individual 2-D suturing practical/ VRT	
10:00 - 10:10	Continuous suturing lecture	Gordon A. MacKinlay, MD
10:10 - 10:30	Individual 3-D suturing practical/ VRT	
10:30 - 11:00	Individual 2-D suturing practical/ VRT	
11:00 - 11:10	Continuous suturing lecture-French knot	Henri Steyaert, MD
11:10 - 11:45	Individual 2-D suturing practical/ Test	
11:45 - 11:55	Course post-assessment	David van der Zee, MD
11:55 - 12:00	Closing remarks	Gordon A. MacKinlay, MD

IPEG gratefully acknowledges a generous educational grant in support of this course from Karl Storz Endoscopy. IPEG also acknowledges in-kind support from Ethicon Endosurgery, Inc, Surgical Science AB and Karl Storz Endoscopy

I BUILD RELATIONSHIPS THROUGH BARIATRICEDGE℠

DEVELOPED BY YOUR TRUSTED PROVIDER OF STATE-OF-THE-ART BARIATRIC SURGICAL TOOLS AND DEVICES, ETHICON ENDO-SURGERY BARIATRICEDGE℠ DELIVERS PREMIER BARIATRIC SERVICE SOLUTIONS WITH A VISION OF DRAMATICALLY IMPROVED HEALTH FOR BARIATRIC PATIENTS AND AN UNMATCHED FOCUS ON PATIENT OUTCOMES AND CARE.

THROUGH BARIATRICEDGE℠, I OFFER PASSION AND EXPERTISE IN BARIATRIC SURGERY, ONGOING TREATMENT AND CARE, PRACTICE SUPPORT, AND PATIENT EDUCATION.

> TODD DAWSON
Bariatric Account Manager

ETHICON ENDO-SURGERY, INC
a Johnson & Johnson company

BARIATRICEDGE℠

©2005 Ethicon Endo-Surgery, Inc.

BARIATRIC SATELLITE SYMPOSIUM

13:00 - 16:00 Location: Sala Zorzi Room 4, Palazzo del Cinema

Course Director: Thomas H. Inge, MD

Course Objectives:

- Understand the scope of the problem and health risks associated with of pediatric severe obesity
- Understand the indications and contraindications for weight loss procedures in adolescents
- Be familiar with the pros and cons of various surgical weight loss options for adolescents
- Be familiar with facility / personnel issues which may impact implementation of a surgical weight loss program
- within a children's hospital

Course Description:

This course will provide the participant with an understanding of the rapidly evolving epidemiology of childhood severe obesity and the considerable health risks once thought to be "adult" diseases that are now being seen in greater frequency in children. The immediate, intermediate and long term risks of adolescent severe obesity will be highlighted. The efficacy of medical and behavioral interventions for childhood severe obesity will be briefly reviewed, and indications and contraindications for adolescent bariatric surgery will be presented. An appreciation for the types of surgical intervention and the rationale for surgical therapy will be presented. The participant will be brought completely current with the latest thinking for weight loss interventions which may be appropriate for the adolescent. Finally, practical considerations for the surgeon who plans to implement a surgical weight loss program in a children's hospital setting will be reviewed.

Course Outline:

13:00 - 13:20	**Introductory remarks**	Thomas H. Inge, MD, PhD
13:20 - 14:00	**The problem of pediatric morbid obesity**	Richard Strauss, MD
	A. Epidemiology	
	B. Comorbidity	
	C. Pediatrician's concerns about surgical weight loss	
14:00 - 14:40	**Laparoscopic Gastric Bypass; Gastric Sleeve; Outcomes**	Michel Gagner, MD
	A. Technique	
	B. Morbidity Resolution	
	C. Adolescent Experience	
14:40 - 15:20	**Laparoscopic Adjustable Gastric Banding and Gastric Pacing**	Scott Shikora, MD
	A. Technique	
	B. Morbidity resolution	
	C. Adolescent experience	
15:20 - 16:00	**Safely Offering Bariatric Surgery in a Children's Hospital Setting**	Thomas H. Inge, MD
	A. Team approach, management protocols	
	B. Facility infrastructure	
	C. What pediatric ER and radiology doctors need to be taught?	

IPEG gratefully acknowledges a generous educational grant in support of this course from Ethicon Endosurgery, Inc

For effective relief of occasional constipation

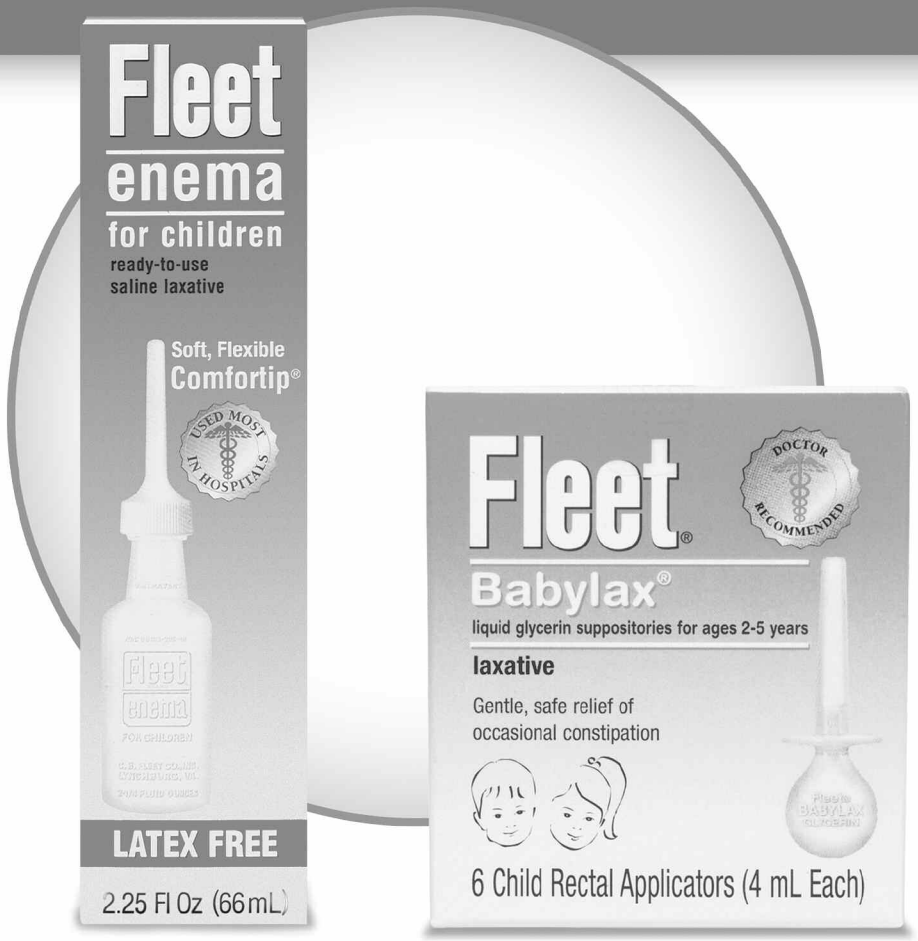

Fleet® enema for children

- Effectively relieves occasional constipation and cleanses the lower bowel.
- Fast acting and predictable – usually works in 2 - 5 minutes.
- Soft, flexible Comfortip®: pre-lubricated for ease of insertion.

Fleet® Babylax®

- A gentle, safe way to relieve occasional constipation.
- Non-systemic, affecting only the rectum, sigmoid and descending colon.
- Takes seconds to use and works in minutes.
- Delivers doctor recommended glycerin quickly, easily and without the mess.

Fleet Pharmaceuticals

Fleet® BRAND pharmaceuticals

SOCIETÁ ITALIANA DI VIDEOCHIRURGIA INFANTILE (SIVI)

12:00 - 16:30 Location: Teatro Perla Room 6, Palazzo del Casino

6th Congress Chairman: Mario Lima, MD

Abstracts and complete program for SIVI on page 26.

12.00	Assembly of SIVI members
13:00	Opening and Lectures of Mario Lima, MD, President of SIVI and Klaas (N) M.A. Bax, MD President of IPEG
13:30	**PANEL "UROLOGY"** Chair: G. Amici, MD; G.Riccipetitoni, MD Discussants: M. Lima, MD; G. Cobellis, MD; M. Cimador, MD ORAL PRESENTATIONS
14:30	**PANEL "COLORECTAL SURGERY"** Chair: V. Jasonni, MD; M. Lima, MD Discussants: G. Riccipetitoni, MD; G. Monguzzi, MD; L. Mastroianni, MD ORAL PRESENTATIONS
15:30	**PANEL "OESOPHAGEAL SURGERY"** Chair: G. Esposito, MD; G. Mattioli, MD Discussants: A. Garzi, MD; A. Papparella, MD; C. Esposito, MD ORAL PRESENTATIONS
16:30	**CLINICAL CASES** Chair: A. Settimi, MD Discussants: N. Pappalepore, MD; M. Dòmini, MD

GENERAL INFORMATION

OFFICIAL LANGUAGE

Italian will be the official language

Continuous Medical Education

C.M.E. accreditation for paediatric surgeons has been requested

Organizing Secretariat

H.T. Congressi srl

Via Benedetto Marcello 1 - 40141 Bologna, Italy
Tel. +39 051 480826 Fax +39 051 480582
E-mail: clara.congrex@virgilio.it

OPENING CEREMONY EAES/IPEG

18:00 – 19:00 Location: Grande Main Auditorium Room 1

WELCOME RECEPTION EAES/IPEG

19:00 – 21:00 Location: Exhibit Hall, Palazzo del Casino

Fee: **No Fee for Registrants & registered guests**

Note: **Children under the age of 14 will not be permitted in the Exhibit Hall due to safety considerations.**

She doesn't understand the choices you make.

Reduce the most frequent operative complications from sharp, conventional trocar entry with the **VersaStep™ Plus Access System.**

tyco Healthcare

autosuture™

©2005 United States Surgical, a division of Tyco Healthcare Group LP. All Rights Reserved. **www.autosuture.com**

IPEG SCIENTIFIC SESSIONS

All IPEG Scientific Sessions will be held at Teatro Perla Room 6, Palazzo del Casino

Scientific Sessions Description:

This section of the IPEG Meeting includes:

- Panel on specific topics
- A joint session with the EAES on GERD
- Oral and video presentations of abstracts
- Poster sessions
- Information of the panels and joint session with the EAES is listed below.

What Is Included?

Fee includes entrance to the session room & poster room on Thursday, Friday and Saturday, a copy of the Final Program, Gastroesophageal Reflux Course with EAES, entrance to the Exhibit Hall, Exhibit Reception, coffee breaks, box lunch (2 days), the Main IPEG Social Event and farewell luncheon.

Scientific Session Objectives:

At the end of this session, participants will understand the current and emerging practices and procedures in minimal access surgery and other developing applications.

Participants will acquire information which relates to indications, contraindications, diagnosis, technique, prevention and management of complications, and results of minimal access surgery, endoscopic, and general surgical procedures.

Participants will recognize the scientific and physiologic basis of minimal access surgery, endoscopy and emerging surgical technology (e.g. robotics).

BREAKFAST VIDEO SESSION I

08:00 - 09:00

Chairperson(s): Munther Haddad, MD; Celeste Hollands, MD

V001 TOTALLY STAPLED LAPAROSCOPIC ROUX-EN-Y GASTRIC BYPASS: PEARLS AND PITFALLS Sanjeev Dutta, MD, Lucile Packard Children's Hospital, Stanford University

V002 LAPAROSCOPIC ADJUSTABLE GASTRIC BANDING IN TEENAGERS: LESS IS BETTER Atul K Madan, MD, Minimally Invasive Surgery Section, Department of Surgery, University of Tennessee, Memphis

V003 ROBOTIC KASAI John J Meehan, MD, University of Iowa Hospitals and Clinics

V004 LAPAROSCOPIC PARTIAL EXTERNAL BILIARY DIVERSION PROCEDURE IN PROGRESSIVE FAMILIAL INTRAHEPATIC CHOLESTASIS M. Bottländer (1), MD, Departments of Pediatric Surgery (1) and Pediatric Gastroenterology (2), Hannover Medical School, Hannover, Germany

V005 LAPAROSCOPIC ROUX-EN-Y PANCREATICOJEJUNOSTOMY Nam X Nguyen, MD, UCI School of Medicine

V006 THORACOSCOPIC REPAIR OF LEFT- AND RIGHT-SIDED CDH Philipp O Szavay, MD, Dept. of Pediatric Surgery, Children's Hospital, University of Tuebingen, Germany

IPEG gratefully acknowledges generous support of this Video Session by Stryker Endoscopy

WELCOME ADDRESS

09:15 - 09:20

Klaas (N) M. Bax, MD
President of IPEG

Benno M. Ure, MD
Program Chairman

SCIENTIFIC SESSION - ESOPHAGEAL ATRESIA PANEL
09:20 - 10:20

Chairperson(s): Marcelo H. Martinez-Ferro, MD & Thom E. Lobe, MD

09:20 - 09:30	Thoracoscopic TEF repair: How to do it	David van der Zee, MD
09:30 - 09:40	Results after thoracoscopic TEF repair	Steven S. Rothenberg, MD
09:40 - 09:50	Thoracoscopy for esophageal atresia without fistula	Marcelo Martinez-Ferro, MD
09:50 - 10:00	Aortopexy	Timothy D. Kane, MD
10:00 - 10:05	Laparoscopic gastric pull-up	Benno M. Ure, MD
10:05 - 10:20	Panel Discussion	

IPEG gratefully acknowledges a generous educational grant in support of this panel by Stryker Endoscopy

THURSDAY

COFFEE BREAK
10:20 - 10:50 Location: Exhibit Hall

IPEG gratefully acknowledges support of all coffee breaks by our Bronze Level sponsor: Taut, Inc.

BEST RATED PAPERS SS01
10:50 - 11:30

Chairperson(s): C.K. Yeung, MD & Carroll M. Harmon, MD

S001 VIDEO-ASSISTED THORACOSCOPY FOR DIAPHRAGMATIC PLICATION. EXPERIMENTAL STUDY IN A CANINE MODEL José F González-Zamora, MSc, Instituto Nacional de Pediatría – SSA, Universidad Nacional Autónoma de México

S002 CO2 ALTERS THE INFLAMMATORY RESPONSE OF MACROPHAGES: ALTERATIONS OF THE CYTOKINE AND SUPEROXYDE ANION RELEASE AND INSIGHTS IN THE UNDERLYING MECHANISM. J F Kuebler, MD, Medical University of Hannover

S003 PNEUMOPERITONEUM TOLERANCE DURING LAPAROSCOPIC PYLORIC STENOSIS CURE: A PROSPECTIVE RANDOMIZED CONTROLED TRIAL Guillaume Podevin, MD, Pediatric Surgery Department. Hôpital Mère-Enfant. NANTES. FRANCE.

BEST BASIC SCIENCE ABSTRACT AWARD
11:30 - 11:35

Presented by: Benno M. Ure, MD – Program Chair

IPEG gratefully acknowledges a generous educational grant in support of this award by Ethicon Endo-Surgery, Inc.

SCIENTIFIC SESSION - FREE PAPERS SS02
11:35 - 13:00

Chairperson(s): Felix Schier, MD; Francois Becmeur, MD

S004 MINIMAL INVASIVE FLUORESCENCE DIAGNOSIS: LAPAROSCOPIC DETECTION OF PERITONEAL METASTASES FROM HUMAN HEPATOBLASTOMA IN NUDE RATS Holger K Till, MD, The Chinese University of Hong Kong

S005 IMPACT OF CARBON DIOXIDE VERSUS AIR PNEUMOPERITONEUM ON NEUTROPHIL RECRUITMENT AND APOPTOSIS Ueli Moehrlen, MD, Dept. of Pediatric Surgery, University Children's Hospital Zurich, Switzerland

S006 THE ADDITION OF O2 TO THE CO2 DOES NOT PREVENT THE SYSTEMIC EFFECTS OF THE CO2-PNEUMOPERITONEUM IN A RABBIT MODEL Suzi DEMIRBAG, MD, *Department of Pediatric Surgery and *Research Centre of Gulhane Military Medical Academy, Ankara, Turkey

S007 LAPAROSCOPY BUT NOT FULL- AND MINI-LAPAROTOMY PRESERVES HEPATIC AND CIRCULATORY MACROPHAGE RESPONSE IN A RAT MODEL Joachim F Kuebler, MD, Department of Pediatric Surgery and Department of Functional and Applied Anatomy, Hannover Medical School, Hannover, Germany

S008 IMPACT OF MINIMAL INVASIVE SURGERY ON ACUTE PHASE RESPONSE AND RISK OF INFECTIOUS COMPLICATIONS IN PAEDIATRIC PATIENTS. Mariano Barbalace, MD, Madonna della Consolazione" Policlini Hospital, Reggio Calabria - Italy

S009 HOW RELIABLE IS YOUR LAPAROSCOPIC KNOT TYING? Pedro-Jose Lopez*, MD, Paediatric Surgery * and Biomedical Engineering Department°, Great Ormond Street Hospital and University College of London, London

S010 THE EFFECT OF ORAL INSULIN ON INTESTINAL RECOVERY FOLLOWING ISCHEMIA-REPERFUSION INJURY IN RAT Jorge G Mogilner, MD, Rappaport Faculty of Medicine, Technion, Dept of Pediatric Surgery, Bnai Zion Medical Center, Dept of Surgery Carmel Medical Center, Dept of Pediatrics and Pediatric Gastroenterology, Meyer Children's Hospital, Rambam Medical Center, Haifa, Israel

S011 CELL INJECTION: A NEW APPROACH FOR THE TREATMENT OF GASTROESOPHAGEAL REFLUX. PRELIMINARY EXPERIENCE IN ANIMALS. Francesco Fascetti Leon, MD, Division of Pediatric Surgery & Institute of Biology University of Padoua, Italy

S012 NOVEL BLADDER TISSUE ENGINEERING WITH STEM CELLS IMPROVES MORPHOLOGIC AND MOLECULAR COMPOSITION OF RECONSTITUTED BLADDERS Steve Y Chung, MD, Cedars-Sinai Medical Center, USA

S013 FETOSCOPIC TRACHEAL OCCLUSION IN THE HUMAN FETUS WITH SEVERE CONGENITAL DIAPHRAGMATIC HERNIA. Jose L Peiró, MD, Fetal Surgery Program. Hospital Vall d'Hebrón. Barcelona. Spain. + Fetal Medicine Units of the Departments of Obstetrics and Gynaecology of the *University Hospital Gasthuisberg, Leuven, Belgium, and **King's College Hospital, London, UK

S014 FETOSCOPIC DIVISION OF LIMB AMNIOTIC BANDS Peter Z Borzi, MD, Mater Hospital Brisbane and Monash Medical Centre Melbourne, Australia

IPEG gratefully acknowledges a generous educational grant in support of this session by Ethicon Endo-Surgery, Inc.

LUNCH BREAK

13:00 - 14:30 **Box lunch will be provided for registered attendees.**

PRESIDENTIAL LECTURE – KLAAS (N) M. BAX, MD

14:30 - 15:00

THURSDAY

SCIENTIFIC SESSION SS03

15:00 - 16:30

Chairperson(s): Chris Kimber, MD; Jean-Stéphane Valla, MD

S015 OPTIMISATION OF LAPAROSCOPIC VARIX LIGATION IN CHILDREN Igor V Poddoubnyi, MD, Moscow State Medico-Stomatologic University, Russia

S016 ADOLESCENT VARICOCELE: PREOPERATIVE LYMPHOGRAPHY WITH PATENT BLU TO PREVENT HYDROCELE AFTER LAPAROSCOPIC PALOMO PROCEDURE S. F. Chiarenza, MD, Dept. Pediatric Surgery, S. Bortolo Hospital Vicenza, Italy

S017 HYDROCELE AS A COMPLICATION FOLLOWING LAPAROSCOPIC VARICOCELECTOMY IN CHILDREN AND ADOLESCENTS Nenad Janic, PhD, University Childrens Hospital, Belgrade, Serbia & Montenegro

S018 WHICH APPROACH? TRANSPERITONEAL OR RETROPERITONEAL, FOR PAEDIATRIC LAPAROSCOPIC NEPHRECTOMY – 100 CONSECUTIVE CASES Mohan S Gundeti, MS, Great Ormond Street Hospital, Guy's Hospital and Middlesex Hospital Institute of Urology, London, UK

S019 ENDOSCOPIC EXTRAPERITONEAL RENAL SURGERY: THE ANTERIOR APPROACH TRUST A Najmaldin, MD, The Leeds Teaching Hospitals NHS, UK

S020 LAPAROSCOPIC VERSUS OPEN NEPHRECTOMY IN CHILDREN WAEL MAGDY EL-SAIFY, MSc, FRCS / Mr, Department of Paediatric Surgery, Norfolk and Norwich University Hopital, UK

S021 BILATERAL SYNCHRONOUS RETROPERTONESCOPIC NEPHRECTOMY (RPN) WITH SIMULTANEOUS PERITONEAL DIALYSIS (P.D.): A NEW ERA IN MANAGEMENT OF THE PAEDIATRIC ESRD Mohan S Gundeti, MS, Guy's & Great Ormond Street Hospital,London, UK

S022 LAPAROSCOPIC TRANSPOSITION OF LOWER POLE VESSELS- THE 'VASCULAR HITCH': AN ALTERNATIVE FOR PELVIURETERIC JUNCTION OBSTRUCTION IN CHILDREN P Godbole, MD, Great Ormond Street Hospital for Children, London, UK

S023 INITIAL EXPERIENCE WITH ROBOTIC ASSISTED LAPAROSCOPIC PYELOPLASTY IN CHILDREN, COMPARISON OF SIMILAR AGE GROUPED OPEN PROCEDURES TO ROBOTIC ASSISTED LAPAROSCOPIC PROCEDURES Allan M Shanberg, MD, University of California, Irvine, Antoci Center for Pediatric Urology and Nephrology, USA

S024 OUR EXPERIENCE IN LAPAROSCOPIC EXTRAVESICAL TRANSPERITONEAL APPROACH FOR VESICOURETERAL REFLUX (VUR). Mario Riquelme, MD, Hospital San Jose Tec de Monterrey, Mexico

S025 COLLATERAL CIRCULATION AFTER SPERMATIC VESSELS LIGATION FOR ABDOMINAL TESTIS AND ITS IMPACT ON STAGED LAPAROSCOPIC ASSISTED ORCHIOPLEXY Sameh Abdel Hay, MD, Pediatric surgery unit Ain Shams University Cairo Egypt

S026 LAPAROSCOPIC TREATMENT OF NONPLAPABLE TESTIS. A MULTI-INSTITUTIONAL ANALYSIS ON 1017 TESTICLES Ciro Esposito 1, MD, 1Chairs of Pediatric Surgery Magna Graecia University of Catanzaro , Via Tommaso Campanella 115, 88100 Catanzaro, Italy; 2 Uthrecht, the Netherland; 3 Genova, Italy; 4Nice, France; 5 Meintz, Germany; 6 Lausanne, Switzerland; 7 Bologna, Italy; 8 Naples Fe

IPEG gratefully acknowledges a generous educational grant in support of this session by AutoSuture, Valleylab and TycoHealthcare International

COFFEE BREAK

16:30 - 17:00 **Location: Exhibit Hall**

IPEG gratefully acknowledges support of all coffee breaks by our Bronze Level sponsor: Taut, Inc.

SCIENTIFIC SESSION – SHORT PAPERS/POSTERS SS04
17:00 - 18:00

Chairperson(s): Craig T. Albanese, MD; Marc A. Levitt, MD

S027 TECHNICAL CONSIDERATIONS WHEN PLANNING LAPAROSCOPIC ADRENALECTOMY IN PEDIATRIC PATIENTS Patrick M McEnaney, MD, University of Massachusetts Medical School,USA

S028 LAPAROSCOPIC INTERVAL APPENDICECTOMY Anthony D Owen, Mr, Paediatric Surgical Unit, Sheffield Children's Hospital

S030 SELF-CLOSING U-CLIPS ARE SAFE AND EFFECTIVE FOR MINIMALLY INVASIVE PEDIATRIC BOWEL ANASTOMOSIS Adrien J Kant, MD, Children's Hospital of Michigan, Wayne State University

S031 BILATERAL THORACOSCOPIC SPLANCHNICECTOMY IN CHRONIC INTESTINAL PSEUDO-OBSTRUCTION K Khelif, MD, Queen Fabiola University children's Hospital Brussels and Laboratory of Neurophysiology Faculty of Medicine, Université Libre de Bruxelles, Brussels, Belgium

S032 LAPAROSCOPIC TOTAL PROCTOCOLECTOMY (TPC) AND ILEAL J POUCH (IJP) IN PEDIATRICS Maria M Bailez, MD, J. P. Garrahan. Htal Bs. As. Argentina.

S033 MINIMAL INVASIVE GASTROSTOMY: ROUTINE LAPAROSCOPIC ASSISTED. YES OR NO? Marcos Bettolli, MD, Department of Surgery, Children's Hospital of Eastern Ontario, Canada

S034 INTRA-OPERATIVE COMPLICATIONS OF LAPAROSCOPIC NISSEN FUNDOPLICATION B. Banieghbal, MD, Division of peditaric surgery, University of The Witwatersrand, Johannesburg, South Africa

S035 COMPLICATIONS AFTER LAPAROSCOPIC FUNDOPLICATION: 8 YEAR INSTITUTIONAL EXPERIENCE Karen Bailey, MD, Children's Hospital of Eastern Ontario, Canada

S036 THE TREATMENT OF BENIGN ESOPHAGEAL STRICTURES USING REMOVABLE SILICONE STENTS Theodore H Stathos, MD, The Mother and Child Hospital at Presbyterian/St. Luke's Medical Center, Denver, CO, USA

S037 LAPAROSCOPIC RESECTION OF OESOPHAGEAL STRICTURE WITH RETROGASTRIC STAPLED ANASTOMOSIS IN A 2-YEAR-OLD AIDS PATIENT Daniel Sidler, MD, Department of General Surgery/Paediatric Surgery, Tygerberg Children's Hospital, Stellenbosch University, South Africa

S038 PRELIMINARY RESULTS OF A NEW MINIMAL INVASIVE LAPAROSCOPIC REPAIR OF INGUINAL HERNIAS IN CHILDREN Martin Michael Kaiser, MD, Department of Paediatric Surgery, Campus Luebeck, University of Schleswig-Holstein, Germany

S039 INTRACORPOREAL TAUTLINE KNOT: A FAST METHOD TO SECURE A LAPAROSCOPIC CONTINUOUS SUTURING Peter KF Yip, , Department of Surgery, Pamela Youde Nethersole Eastern Hospital, *Division of Paediatric Surgery, Department of Surgery, Queen Mary Hospital, Hong Kong, China

S040 VIDEO-ASSISTED LAPAROSCOPIC PROCEDURES IN PERITONEAL DIALYSIS CATHETER MALFUNCTION Eleonora Cesca, MD, Division of Pediatric Surgery and Department of Pediatrics, University of Padoua, Italy

S041 A SURVEY OF STERILIZATION TECHNIQUES FOR RE-USABLE LAPAROSCOPIC INSTRUMENTS B. Banieghbal, MD, CH Baragwanath Hospital, Johannesburg, South Africa

S042 Nd:YAG LASER ENDOSCOPIC TREATMENT FOR RECURRENT TRACHEOESOPHAGEAL FISTULA: PROMISING RESULTS. Jose L Peiró, MD, Department of Pediatric Surgery. Hospital Vall d'Hebrón. Barcelona. Spain.

S043 LAPAROSCOPIC CUTDOWN TO THE INFERIOR EPIGASTRIC VEIN : ANOTHER ACCESS TO THE CENTRAL VENOUS SYSTEM IN A PARENTERAL NUTRITION DEPENDANT PATIENT Paul PHILIPPE, MD, Paediatric Surgery, Centre Hospitalier de Luxembourg, Luxembourg

S044 LAPAROSCOPIC REPAIR OF CONGENITAL DIAPHRAGMATIC DEFECTS IN CHILDREN Nabil M Dessouky, BS, Pediatric Surgical Division, the Specialized Children's University Hospital, Egypt

S045 LARGE THORACOSCOPIC PERICARDECTOMY FOR PURULENT PERICARDITIS: EXPERIENCE WITH 20 CASES Liem T Nguyen, PhD, National Hospital of Pediatrics, Hanoi, Vietnam

IPEG gratefully acknowledges a generous educational grant in support of this session by Fleet Pharmaceuticals

BREAKFAST VIDEO SESSION II

08:00 - 09:00

Chairperson(s): George W. Holcomb, MD; Behrouz Banieghbal, MD

V007 ROBOTIC ASSISTED REPAIR OF UPJ OBSTRUCTION 2' TO CROSSING GONADAL VESSEL IN A 6 YEAR OLD BOY Allan M Shanberg, MD, Antoci Center for Pediatric Urology and Nephrology, University of California, Irvine, USA

V008 RETROPERITONEOSCOPIC SURGERY FOR THE TREATMENT OF UPPER URINARY TRACT STONES IN CHILDREN. Janusz Sulislawski, MD, Department of Pediatric Urology, Jagiellonian University, Cracow, Poland.

V009 LAPAROSCOPIC PARTIAL NEPHRECTOMY IN A 6 MONTH OLD GIRL WITH 5 MM. LIGASURE DEVICE—NO SUTURING Allan Shanberg, MD, Antoci Center for Pediatric Urology & Nephrology, University of California, Irvine, USA

V010 LAPAROSCOPIC RESECTION OF A PROSTATIC UTRICLE Michael V Tirabassi, MD, Baystate Medical Center Children's Hospital, Tufts University School of Medicine, USA

V011 ROBOTIC-ASSISTED RESECTION OF RECURRENT BRONCHOGENIC CYST Michael S Irish, MD, Blank Children's Hospital, Des Moines, Iowa, USA

V012 THORACOSCOPIC TREATMENT OF CONGENITAL ESOPHAGEAL STENOSIS Marcelo Martinez-Ferro, MD, National Children's Hospital J.P.Garrahan. Buenos Aires, Argentina

IPEG gratefully acknowledges generous support of this Video Session by Stryker Endoscopy

KEYNOTE LECTURE
ERROR MANAGEMENT IN AVIATION

09:00 - 09:30

Manfred H. Müller, Mr

Training-Captain Boeing 737, General Manager Flight Safety Lufthansa

Mr. Müller began his study at Ludwig Maximilian University, Munich, after which he began pilot training at the Lufthansa Pilot School in Bremen and Phoenix, Arizona. He served for 12 years as First Officer on Boeing B737, Boeing B747 and Airbus A340. Since 1988 he has been Instructor for High Technology Airplanes. Mr. Müller's education also incudes an Accident Investigation Course at the University of Southern California USC, Los Angeles. Mr. Müller has served as Captain on Boeing B737, Training-Captain on Boeing B737 and since 2001 General Manager Flight Safety, Lufthansa. Beginning 1995 he has done Risk Management in Medicine and since 2004 been Lecturer on Risk Management at the University of Bremen (Master Course in Aviation Management).

Mr. Müller's present main working topics are: Evidence based Risk Management, cultural effects affecting Safety, strategies for Pilot Selection and Training, measuring Safety using Statistical Methods, conducting Risk Management Seminars for Medical Doctors.

IPEG gratefully acknowledges support of this lecture by Stryker Endoscopy

COFFEE BREAK

09:30 - 10:00 Location: Exhibit Hall

IPEG gratefully acknowledges support of all coffee breaks by our Bronze Level sponsor: Taut, Inc.

JOINT PANEL IPEG-EAES ON GASTROESOPHAGEAL REFLUX

10:00 - 11:45

Chairperson(s): Keith E. Georgeson, MD; Karl-Hermann Fuchs, MD; Girolamo Mattioli, MD

10:15 - 10:25	Evidence-based Criteria In The Management of GERD In The Adult	Karl-Hermann Fuchs, MD
10:25 - 10:35	Reflux and Aspiration	Rudolph Pointner, MD
10:35 - 10:45	The Problem of Short Esophagus	Giovanni Zaninotto, MD
10:45 - 10:55	Modern Diagnostic Concepts for GERD in Children	Yvan van de Plas, MD
10:55 - 11:05	GERD and PEG In Neurologically Impaired Children	Ciro Esposito, MD
11:05 - 11:15	Therapeutic Strategies for GERD in Children	Keith E. Georgeson, MD
11:15 - 11:45	Panel Discussion	

SCIENTIFIC SESSION - FREE PAPERS SS05

11:45 - 13:15

Chairperson(s): Mark L. Wulkan, MD; Philippe Montupet, MD

S047 EXPERIENCE WITH 125 CONSECUTIVE PEDIATRIC THORACOSCOPIC LOBECTOMIES Craig T Albanese, MD, Lucile Packard Children's Hospital; Stanford, California and Presbyterian/St. Luke's Hospital, Denver, Colorado, USA

S048 THORACOSCOPIC REPAIR FOR CONGENITAL DIAPHRAGMATIC HERNIA: EXPERIENCE WITH 45 CASES Liem T Nguyen, PhD, National Hospital of Pediatrics, Hanoi, Vietnam

S049 THORACOSCOPIC REPAIR OF OESOPHAGEAL ATRESIA-THE UK EXPERIENCE Gordon A MacKinlay, MD, The Royal Hospital for Sick Children, Edinburgh, The Radcliffe Infirmary, Oxford and The Royal Belfast Hospital for Sick Children

S050 ADRENALECTOMY IN CHILDREN: THE ROLE OF MINIMALLY INVASIVE SURGERY Piero Romano, MD, Department of Pediatric Surgery, IRCCS Policlinico San Matteo, Pavia, Italy - Fondation Lenval pour Enfants, Nice, France

S051 VIDEO-ASSISTED SURGERY OF ABDOMINAL CAVITY IN PAEDIATRIC ONCOLOGY. Przemyslaw Mankowski, MD, Dept. of Paediatric Surgery, Traumatology and Urology, Poland

S052 MINIMALLY INVASIVE VIDEO-ASSISTED THYROIDECTOMY IN YOUNG PATIENTS: REPORT OF 24 CASES Claudio Spinelli, MD, Cattedra di Chirurgia Pediatrica, Università di Pisa, Italy

S053 COMPLETE SUBCUTANEOSCOPIC HARVEST AND TRANSPOSITION OF LATISSIMUS DORSI MUSCLE FOR THE TREATMENT OF POLAND'S SYNDROME.- A SURGICAL FIRST Marcelo Martinez-Ferro, MD, National Children's Hospital J.P.Garrahan". Buenos Aires, Argentina

S054 AN INNOVATIVE MINIMALLY INVASIVE TREATMENT FOR SCOLIOSIS IN CHILDREN: VERTEBRAL BODY STAPLING USING SHAPE MEMORY ALLOY (NITINOL) Harsh Grewal, MD, Section of Pediatric Surgery, Temple University Children's Medical Center and Orthopedic Surgery, Shriners Hospitals for Children, Philadelphia, PA, USA

S055 INTRACORPOREAL, ROBOTICALLY-ASSISTED MANAGEMENT OF CHOLEDOCHAL CYST: ANALYSIS AND DEMONSTRATION OF TECHNIQUE FROM THE LAB TO THE OPERATING ROOM Michael S Irish, MD, Blank Children's Hospital, Des Moines, IA & Presbyterian-St. Luke's Hospital, Denver, CO, USA

S056 ROBOTIC SURGERY IN INFANTS AND NEONATES John J Meehan, MD, The University of Iowa Hospitals and Clinics - Children's Hospital of Iowa, USA

S057 ROBOTICALLY-ASSISTED THORACIC PROCEDURES IN INFANTS AND CHILDREN Dra. Natalia E Tamburi, , Blank Children's Hospital, Des Moines, Iowa, USA

S058 EXPERIENCE WITH DA VINCI ROBOT-ASSISTED PROCEDURES IN CHILDREN Aayed R Alqahtani, MD, College of medicine & King Khalid university Hospital, Riyadh, Saudi Arabia

IPEG gratefully acknowledges a generous educational grant in support of this session by Karl Storz Endoscopy, Inc.

AN EVENING TOUR TO TORCELLO (WITH DINNER AT LOCANDO CIPRIANI)

17:45 - 23:00

17:45 Boat tour departure from Casino Pier and Saint Mark Square Pier to Torcello

23:00 Return to the Caisno Pier and Saint Mark Square Pier

* For registered attendees and guests with tickets, please pick-up detail instruction at the IPEG Desk.

IPEG gratefully acknowledges support of this event by our Platinum Level sponsors:

AutoSuture/Valleylab and Tyco Healthcare International

Ethicon Endo-Surgery

Fleet Pharmaceuticals

Karl Storz Endoscopy, Inc.

Stryker Endoscopy

Submitting a membership application to IPEG makes good sense!

REASON 1: You can save the equivalent of one year's dues by registering at the member rate if you attend more than one course.

REASON 2: The benefits of membership extend throughout the year, including journal subscriptions, content-rich websites, electronic newsletters, etc.

Applications are available on-line or by contacting the administrative office.

IPEG Office: 310-437-0553 or www.ipeg.org/whyjoin.html

SCIENTIFIC SESSION – SHORT PAPERS/POSTERS SS06

08:00 - 09:00

Chairperson(s): John H.T. Waldhausen, MD; Hock L. Tan, MD

S059 THE SINGLE INSTRUMENT PORT LAPAROSCOPIC (S.I.M.P.L.) Imran Mushtaq, MD, Great Ormond Street Hospital and Guys Hospital

S060 RETROPERITONEOSCOPIC ADRENALECTOMY: AN EARLY INSTITUTIONAL EXPERIENCE. Pedro-Jose Lopez, MD, Departments of Paediatric Urology and Paediatric Surgery, Great Ormond Street Hospital, London, UK

S061 URACHAL REMNANTS, LAPAROSCOPIC APPROACH: A CONSECUTIVE SERIES OF 24 CHILDREN Salmai Turial, MD, Pediatric Surgery University medical centre Mainz, Germany

S062 LAPAROSCOPY IN MANAGEMENT OF INTERSEX PATIENTS Nabil M Dessouky, BA, Division Of Pediatric Surgery, Cairo University, Egypt

S063 PNEUMOVEICOSCOPIC URETERIC REIMPLANTATION IN CHILDREN WITH VESICOURETERAL REFLUX AND PARAURETERAL (HUCTH) DIVERTICULUM HOLGER Till, MD, Dept. of Surgery, Div. of Pediatric Surgery and Pediatric Urology, Hong Kong, China

S064 GUIDELINES FOR EXPLORATORY ENDOSURGERY IN CONSTANT URINARY DAMPNESS Chris Z Kimber, MD, Department of Paediatric Urology Royal Childrens Hospital, Melbourne , Monash Medical Centre Melbourne and Mater Hospital Brisbane, Austalia

S065 LAPAROSCOPIC EXCISION OF MÜLLERIAN DUCT DERIVATIVES IN INTERSEX PATIENTS Mohamed M Elbarbary, MD, Cairo University Specialized Pediatric Hospital, Tanta University Children Hospital, Egypt

S066 THE LAPAROSCOPIC TWO-STAGE FOWLER-STEPHENS ORCHIDOPEXY : PRESERVATION OF THE GUBERNACULAR VESSELS AND A PURELY LAPAROSCOPIC 2ND STAGE TECHNIQUE Stuart A Robertson, MD, Department of Surgery, Royal Hospital for Sick Children, Sciennes Place, Edinburgh, UK

S067 LAPAROSCOPIC SALVAGE OF MALFUNCTIONING PERITONEAL DIALYSIS CATHETERS A Numanoglu, MD, Departments of Paediatric Surgery and Paediatric Nephrology, Red Cross Children's Hospital and University of Cape Town, Rondebosch, 7700, South Africa

S068 VESICOURETERIC REFLUX AND RECURRENT URINARY TRACT INFECTION Edwin Chan, MS, Div. of Pediatric Surgery and Pediatric Urology, Chinese University of Hong Kong, Prince of Wales Hospital, Shati, Hong Kong, China

S069 VESICOSCOPIC URETERAL REIMPLANTATION IN CHILDREN WITH VESICOURETERIC REFLUX. ANY ASSOCIATION WITH BLADDER SPASM? EdwinKW Chan, MS, Division of Paediatric Surgery & Paediatric Urology, Department of Surgery, The Chinese University of Hong Kong, Prince of Wales Hospital, Hong Kong SAR, China

S070 THE ROLE OF LAPAROSCOPY IN THE MANAGEMENT OF PATIENTS WITH AMBIGUOS GENITALIA Marìa M Bailez, MD, Pediatric Surgery . J. P. Garrahan Hospital . Buenos Aires . Argentina.

S071 USE OF THE LIGASURE DEVICE IN LAPAROSCOPIC VARICOCELE LIGATION IN CHILDREN AND ADOLESCENT Antonio Marte, MD, Second University of Naples, Italy

S072 ACTUAL PRACTICE OF LAPAROSCOPY AND THORACOSCOPY IN NEONATES: A GECI STUDY OVER 10 YEARS. N Kalfa, MD, GECI Groupe d'Etude en Coeliochirurgie Infantile - Service de Chirurgie Viscérale Pédiatrique, Hôpital Lapeyronie, CHU, Monpellier, France

S073 LAPAROSCOPIC PARTIAL SPLENECTOMY FOR A NONPARASITIC SPLENIC CYST USING RADIOFREQUENCY ABLATION K Khelif, MD, Department of surgery Queen Fabiola Children's University Hospital, Université Libre de Bruxelles, Brussels / Belgium and Auvelais

S074 LAPAROSCOPIC PROCEDURES FOR BENIGN ABDOMINAL AND RETROPERITONEAL CYSTS IN PEDIATRIC PATIENTS. Igor V Poddoubnyi, MD, Moscow State Medico-Stomatologic University, Russia

S075 OPTIMIZING OUTCOMES IN THE THORACOSCOPIC MANAGEMENT OF COMPLICATED PARAPNEUMONIC EFFUSION IN CHILDREN Jeffrey C Pence, MD, Brody School of Medicine at East Carolina University, Greenville, NC, USA

S076 THORACOSCOPIC PULMONARY ARTERY BANDING Yuri A Kozlov, MD, Department of Newborn Surgery, Pediatric Hospital, Irkutsk, Russia

S077 THORASCOPIC VERSUS THORACATOMY FOR CORRECTION OF SEVERE SPINAL DEFORMITY Robert E Eilert, MD, The Children´s Hospital, Denver, CO, USA

S078 THORACOSCOPIC THORACIC DUCT THERMOFUSION WITH THE LIGASURE DEVICE FOR PERSISTENT POSTOPERATIVE CHYLOTHORAX IN 2 CHILDREN. K Khelif, MD, Queen Fabiola Children's University Hospital , Université Libre de Bruxelles, Brussels / Belgium and Auvelais Hospital / Belgium

IPEG gratefully acknowledges a generous educational grant in support of this session by Fleet Pharmaceuticals

IPEG gratefully acknowledges support of this meeting by our sponsors:

Platinum Level:

AutoSuture/Valleylab and Tyco Healthcare International · Ethicon Endo-Surgery

Fleet Pharmaceuticals · Karl Storz Endoscopy, Inc. · Stryker Endoscopy

Bronze Level: Taut, Inc.

SCIENTIFIC SESSION – ONCOLOGY PANEL
09:15 - 11:00

Chairperson(s): Benno M. Ure, MD; Steven S. Rothberg, MD

09:15 - 09:25 CO2 Pneumoperitoneum and Tumor Behavior
Speaker: Benno M. Ure, MD

09:00 - 09:35 Minimally Invasive Biopsy of Childhood Tumors
Speaker: Lambert Skoog, MD

09:35 - 09:45 Laparoscopy for Abdominal Neuroblatoma
Speaker: Tadashi Iwanaka, MD

09:45 - 09:55 Thoracoscopy for Solid Tumors
Speaker: Steven S. Rothenberg, MD

09:55 - 10:05 Thoracoscopy for Thoracic Metastasis
Speaker: Mark L. Wulkan, M

10:05 - 11:00 Panel Discussion

IPEG gratefully acknowledges a generous educational grant in support of this panel by Stryker Endoscopy

COFFEE BREAK
11:00 - 11:30 Location: Exhibit Hall

IPEG gratefully acknowledges support of all coffee breaks by our Bronze Level sponsor: Taut, Inc.

KARL STORZ STATE OF ART LECTURE
NEW DEVELOPMENTS IN VIRTUAL REALITY AND ADVANCED SURGICAL TECHNOLOGY
11:30 - 12:00

Speaker: Professor Jacques Marescaux

President and Founder of IRCAD and EITS, Head of Digestive and Endocrine Surgery Department, Strasbourg University Hospitals

In June 1994 IRCAD (Institut de Recherche contre les Cancers de l'Appareil Digestif — Institute for Research into Cancer of the Digestive System) and EITS (European Institute of Telesurgery) came to fruition. Here, basic science researchers, technicians, computer engineers and teachers from around the world could work together to drive advances.

Professor Jacques Marescaux has since 1989 been Head of Digestive and Endocrine Surgery Department at Strasbourg University Hospitals. He is also a fellow of numerous scholarly societies.

IPEG gratefully acknowledges a generous educational grant in support of this lecture by Karl Storz Endoscopy

SATURDAY

IPEG GENERAL ASSEMBLY
12:00 - 12:30

All IPEG members are invited to attend the annual IPEG business meeting, at which the committee chairs will update the membership on business conducted during the past year. Additionally, the new slate of officers will be presented for approval.

SCIENTIFIC SESSION - FREE PAPERS SS07

12:30 - 13:30

Chairperson(s): Azad S. Najmaldin, MD; Jürgen Schleef, MD

S079 LAPAROSCOPIC REDO-NISSEN IN CHILDREN: EXPERIENCE OF MONPELLIER M Lopez, MD, Department of Pediatric Surgery, Lapeyronie Hospital, Montpellier, France

S080 CAN FAILURE OF LAPAROSCOPIC NISSEN FUNDOPLICATIONS IN PEDIATRIC PATIENTS BE PREDICTED? Curt S Koontz, MD, Division of Pediatric Surgery, Joseph B Whitehead Department of Surgery, Atlanta, GA, USA

S081 THORACOSCOPIC-ASSISTED ESOPHAGECTOMY AND LAPAROSCOPIC GASTRIC PULL-UP FOR LYE INJURIES IN CHILDREN-EARLY RESULTS AND FOLLOW-UP Timothy D Kane, MD, UPMC and Children's Hospital of Pittsburgh, Pittsburgh, PA., U.S.A.

S082 EXPERIENCE WITH GASTRIC TUBE CARDIOPLASTY IN TREATMENT OF GER B. Haluk Guvenc, MD, Kocaeli University, School of Medicine, Dept. of Pediatric Surgery, Kocaeli, Turkey, Istanbul University, Istanbul School of Medicine, Dept. of Surgery, Istanbul, Turkey

S083 BARIATRIC SURGERY FOR MORBIDLY OBESE ADOLESCENTS: EARLY RESOLUTION OF OBESITY RELATED COMORBID CONDITIONS Carroll M Harmon, MD, PhD, University of Alabama Hospital, Birmingham, AL, Children's Hospital of Alabama, Birmingham, AL, USA

S084 NON ENDOCRINE CYSTIC SOLID PANCREATIC TUMORS. PLACE OF LAPAROSCOPIC MANAGEMENT IN CHILDREN AND ADOLESCENTS Jean Stephane VALLA, MD, Fondation LENVAL Pediatric Surgery, Nice, France

S085 LAPAROSCOPIC MANAGEMENT OF PANCREATIC DISEASE IN INFANTS AND CHILDREN Steven S Rothenberg, MD, The Mother and Child Hospital at Presbyterian/St Lukes Hospital, Denver, CO, USA

S086 LAPAROSCOPIC APPROACH IN TREATMENT OF APPENDICEAL GENERALIZED PERITONITIS IN CHILDREN: COMPARATIVE, PROSPECTIVE, RANDOMIZED STUDY Vladimir Igorevich Kotlobovsky, MD, Department of Laparoscopic Surgery, Pediatric Hospital, Aktobe, Kazakhstan; Department of Pediatric Surgery, Russian Medical University, Moscow, Russia

S087 LAPAROSCOPIC "LEAK-FREE" TECHNIQUE FOR THE TREATMENT OF CHOLEDOCHAL CYSTS Pablo Laje, MD, Division of Pediatric Surgery, National Pediatric Hospital "JP Garrahan", Buenos Aires, Argentina

S088 LAPAROSCOPIC ANTEGRADE CONTINENCE ENEMA USING A TWO PORT TECHNIQUE Brice Antao, MD, Paediatric Surgical Unit, Sheffield Children's Hospital, Western Bank, Sheffield S10 2TH, UK

S089 THE LAPAROSCOPIC ASSISTED TRANS-ANAL PULL-THROUGH FOR HIRSCHSPRUNG: A MULTICENTRIC EXPERIENCE IN THE LAST FIVE YEARS M. Lima, MD, Dept. Of Ped. Surgery – "Alma Mater Studiorum" University of Bologna,Dept. Of Ped. Surgery – Annunziata Hospital – Cosenza ,Dept. Of Ped. Surgery – "G. Salesi" Hospital – Ancona ,Dept. Of Ped. Surgery– "G. Gaslini" Hospital – Genova, Italy

S090 LAPAROSCOPIC APPROACH TO PEDIATRIC EMERGENCIES -11 YEARS SINGLE SURGEON EXPERIENCE Igor V Poddoubnyi, MD, Moscow State Medico-Stomatologic University, Russia

IPEG gratefully acknowledges a generous educational grant in support of this session by Strkyer Endoscopy, Inc.

CLOSING REMARKS AND PRESENTATION OF 2006 PRESIDENT

13:30 - 13:40

Klaas (N) M. Bax, MD
Departing President
Utrecht, THE NETHERLANDS

Keith E. Georgeson, MD
Incoming 2006 President
Birmingham, Alabama, USA

SATURDAY

FAREWELL LUNCH

13:40 - 15:00 Location: TBA

Please join Dr. Bax and the IPEG leadership for an informal luncheon which provides delegates an opportunity to interact with IPEG leadership, spend time with new and old friends and say farewell to the beautiful island of Lido, Venice.

SAVE THE DATE!

Join us in Dallas for the 15th Annual Congress for Endosurgery in Children.
Held in conjunction with SAGES • April 26 - 29, 2006 • Dallas, Texas

IPEG Faculty

Craig T. Albanese, MD: Stanford University School of Medicine, Department of Surgery, Division of Pediatric General Surgery, Stanford, California, USA

Behrouz Banieghbal, MD: Senior Lecturer in Paediatric Surgery, University of the Witwatersrand, CH Baragwanath Hospital, Johannesburg, REPUBLIC OF SOUTH AFRICA

Klaas (N) M.A. Bax, MD: Professor of Pediatric Surgery, Head of the Department of Pediatric Surgery, Wilhelmina Children's Hospital, University Medical Center Utrecht, Utrecht, THE NETHERLANDS

François Becmeur, MD: Professeur des Universités, Praticien Hospitalier, Hopitaux Universitaires de Strasbourg, Strasbourg, FRANCE

Ciro Esposito, MD: Associate Professor of Pediatric Surgery, Department of Clinical and Experimental Medicine, Chair of Pediatric Surgery, "Magna Graecia" University of Catanzaro, Naples, ITALY

Karl-Hermann Fuchs, MD: Frankfurt, GERMANY [EAES]

Michel Gagner, MD: Professor of Surgery, Chief of Bariatric & Laparoscopic Surgery, Weill College of Medicine of Cornell University, New York, USA

Keith E. Georgeson, MD: Professor of Surgery, Surgeon-in-Chief, The University of Alabama at Birmingham, Children's Hospital of Alabama, Birmingham, Alabama, USA

Munther Haddad, MD: Honorary Senior Lecturer, Consultant Paediatric Surgeon, Chelsea & Westminster Hospital, London, UNITED KINGDOM

Carroll M. Harmon, MD: Associate Professor of Surgery, Surgical Director, Children's Weight Management Center, University of Alabama at Birmingham, Children's Hospital, Birmingham, Alabama, USA

George W. Holcomb III, MD: Katharine Berry Richardson Professor of Surgery, University of Missouri at Kansas City School of Medicine, Surgeon-In-Chief, Children's Mercy Hospitals and Clinics, Kansas City, Missouri, USA

Celeste Hollands, MD: Associate Professor Surgery, University at Buffalo, Clinical Director Miniature Access Surgery Center, Women's and Children's Hospital of Buffalo, Buffalo, New York, USA

Thomas H. Inge, MD: Assistant Professor of Surgery and Pediatrics, Surgical Director, Comprehensive Weight Management Center, Cincinnati Children's Hospital Medical Center, Cincinnati, Ohio, USA

Tadashi Iwanaka, MD: Director, Department of Surgery, Saitama Children's Medical Center, Iwatsuki, Saitama, JAPAN

Timothy D. Kane, MD: Assistant Professor of Surgery, Attending Surgeon; Director, Minimally Invasive Surgery, Children's Hospital of Pittsburgh, Pittsburgh, Pennsylvania, USA

IPEG Faculty

Chris Kimber, MD: Glen Iris, Victoria, AUSTRALIA

Marc A. Levitt, MD: Division of Pediatric Surgery, Cincinnati Children's Hospital Medical Center, Cincinnati, Ohio, USA

No photo available

Mario Lima, MD: Bologna, ITALY



Thom E. Lobe, MD: Pediatric Surgery, Blank Children's Hospital, Des Moines, Iowa, USA

Gordon A. MacKinlay, MD: Senior Lecturer, The Royal Hospital for Sick Children, University of Edinburgh, Edinburgh, Scotland, UNITED KINGDOM

Jacques Marescaux, MD: Professor, Chairman Department Digestive & Endocrine Surgery, University Hospital of Strasbourg, Strasbourg, FRANCE

Marcelo H. Martinez-Ferro, MD: Professor of Surgery & Pediatrics, National Children's Hospital "Garrahan", Olivos, Buenos Aires, ARGENTINA

Girolamo Mattioli, MD: Professor of Surgery, Consultant, Gaslini Institute, University of Genoa, Genoa, ITALY

Philippe Montupet, MD: Chargé D'Enseignement University Paris XI, Senior Consultant, CHU Bicêtre, Paris, FRANCE

Manfred H. Müller, MD: Academy for Risk Management, Munich, GERMANY



Azad S. Najmaldin, MD: Consultant Paediatric Surgeon, St. Jame's University Hospital, The Leeds Teaching Hospital, Leeds, UNITED KINGDOM

Rudolph Pointer, MD: Zell am See, AUSTRIA [EAES]



Olivier Reinberg, MD: Department of Pediatric Surgery, University Hospital of Lausanne – CHUV, Lausanne, SWITZERLAND

Steven S. Rothenberg, MD: Associate Clinical Professor of Surgery, University of Colorado, Chief of Pediatric Surgery, Vice Chair of Surgery, Presbyterian/ St. Lukes Medical Center, Denver, Colorado, USA

Felix Schier, MD: Professor and Head, Department of Pediatric Surgery, University Medical Centre Mainz Germany, Mainz, GERMANY

Jürgen Schleef, MD: Director of the Department of Surgery, Children's Hospital Trieste IRCCS Burlo Garofolo, Trieste, ITALY

IPEG Faculty

Scott A. Shikora, MD: Associate Professor of Surgery, Chief, Bariatric Surgery, Tufts-New England Medical Center, Sharon, Massachusetts, USA

Lambert Skoog, MD: Professor, Department Pathology & Cytology, Karolinska Hospital, Stockholm, GERMANY

Henri Steyaert, MD: Senior Consultant Paediatric Surgery, Fondation Lenval for Children, Nice, FRANCE

Richard Strauss, MD: Director, Endocrinology, Metabolism, Gastroenterology, Johnson & Johnson Pharmaceutical Research, Princeton, New Jersey, USA

Hock Lim Tan, MD: Inaugural Professor of Surgery, Director, Department of Pediatric Surgery, Women's & Children's Hospital, North Adelaide, SOUTH AUSTRALIA

Benno M. Ure, MD: Professor, Medical University Hannover, Department of Pediatric, Hannover, GERMANY

Jean-Stéphane Valla, MD: Professor, Head of Department, Fondation Lenval – Hopital Pour Enfants, Nice, FRANCE

Yvan van de Plas, MD: Chair of Pediatrics, Head, Department of Pediatrics, AZ – Vrije Universiteit Brussel, Brussels, BELGIUM

David C. van der Zee, MD: Department of Pediatric Surgery, University Medical Center Utrecht, Wilhelmina Children's Hospital, Utrecht, The NETHERLANDS



John H.T. Waldhausen, MD: Associate Professor of Surgery, Director of Surgical Education, Children's Hospital & Regional Medical Center, University of Washington, Seattle, Washington, USA

Mark L. Wulkan, MD: Assistant Professor of Surgery & Pediatrics, Director, Minimally Invasive Surgery Center, Emory University, Atlanta, Georgia, USA

C.K. Yeung, MD: Chair Professor of Surgery, Chief of Paediatric Surgery & Paediatric Urology, Consultant, Chinese University of Hong Kong, Hong Kong, CHINA

No photo available

Giovanni Zaninotto, MD: Padova, ITALY [EAES]

SAVE THE DATE!

Join us in Dallas for the 15th Annual Congress for Endosurgery in Children.

Held in conjunction with SAGES

April 26 - 29, 2006

Dallas, Texas

Disclosures

In the spirit of full disclosure, the faculty members listed below have voluntarily disclosed that they have a professional affiliation with the following companies who are either sponsors or exhibitors at the 14th Annual Congress for Endosurgery in Children, or whose products may relate to their presentation. The affiliations are not necessary financial but may also include research grants, volunteer input, etc. IPEG requires speakers who have such affiliations to disclose this verbally prior to their presentation if it is not disclosed in writing. IPEG also requires that speakers disclose if a product is not labeled for the use under discussion or if the product is still investigational.

Sameh Abdel Hay, MD: Nothing to Disclose
Craig T. Albanese, MD: Nothing to Disclose
S. Alhindi, MD: Nothing to Disclose
H. Allal, MD: Nothing to Disclose
Hamdi Almaramhi, MD: Nothing to Disclose
Saad I. Almulhim, MD: Nothing to Disclose
Aayed R Alqahtani, MD: Nothing to Disclose
Tariq Altokhais, MD: Nothing to Disclose
Brice Antao, MD: Nothing to Disclose
A. Aranda, MD: Nothing to Disclose
Georges Azzie, MD: Nothing to Disclose
Karen Bailey, MD: Nothing to Disclose
Marìa M. Bailez, MD: Nothing to Disclose
Maria M. Bailez, MD: Nothing to Disclose
Behrouz Banieghbal, MD: Nothing to Disclose
Mariano Barbalace, MD: Nothing to Disclose
Klaas (N) M.A. Bax, MD: Nothing to Disclose
Francois Becmeur, MD: Nothing to Disclose
Raimundo Beltrà, MD: Nothing to Disclose
Thomas Benkoe, MD: Nothing to Disclose
Francisco José Berchi-Garcia, PhD: Nothing to Disclose
Marcos Bettolli, MD: Nothing to Disclose
Stefan Beyerlein, MD: Nothing to Disclose
Thane A. Blinman, MD: Nothing to Disclose
Peter Z. Borzi, MD: Nothing to Disclose
M. Bottländer (1), MD: Nothing to Disclose
N. Bouhadiba, MD, MRCS: Nothing to Disclose
Ulf Buehligen, MD: Nothing to Disclose
Mark S. Burke, MD: Nothing to Disclose
Juan I. Camps, MD: Nothing to Disclose
DAN Catana, PhD: Failed To Disclose
Antonella Centonze, MD: Nothing to Disclose
Eleonora Cesca, MD: Nothing to Disclose
Job K. Chacko, MD: Nothing to Disclose
S. Chan, MD: Nothing to Disclose
EdwinKW Chan, MS: Nothing to Disclose
Edwin Chan, MS: Nothing to Disclose
S. F. Chiarenza, MD: Nothing to Disclose
D. Cholewa, MD: Nothing to Disclose
Steve Y. Chung, MD: Nothing to Disclose
Melanie C. Clarke, MBChB MRCS/Miss: Nothing to Disclose
Giovanni Cobellis, Dr: Nothing to Disclose
Monica Contador, MD: Nothing to Disclose
Alba Cruccetti, Dr: Nothing to Disclose
Piotr S. Czauderna, PhD: Nothing to Disclose
Haitham I Dagash, Mr: Nothing to Disclose
Pascal De Lagausie, PhD: Nothing to Disclose
Suzi Demirbag, MD: Nothing to Disclose
Nabil M, Dessouky, BA: Nothing to Disclose
Brian Duffy, MD: Nothing to Disclose
Sanjeev Dutta, MD: Nothing to Disclose
Robert E. Eilert, MD: Nothing to Disclose
Mohamed M. Elbarbary, MD: Nothing to Disclose
WAEL MAGDY El-Saify, MSc, FRCS/Mr: Nothing to Disclose
Ciro Esposito, MD: Nothing to Disclose
D. Falchetti, MD: Nothing to Disclose
R Fartachek, MD: Nothing to Disclose
F. Fascetti Leon, MD: Nothing to Disclose
Ettayebi Fouad: Nothing to Disclose
Michel Gagner, MD: Karl Storz, Tyco, Gore, GI Dynamics
Jorge A. García Andrade, MD: Nothing to Disclose
S. Geiss, MD: Nothing to Disclose
Keith E. Georgeson, MD: Nothing to Disclose
Christopher A. Gitzelmann, MD: Nothing to Disclose
Li Voti Giuseppe, MD: Nothing to Disclose
P. Godbole, MD: Nothing to Disclose
José F. González-Zamora MSc: Nothing to Disclose
Harsh Grewal, MD: Nothing to Disclose
Miguel Guelfand, MD: Nothing to Disclose
Mohan S. Gundeti, MS: Nothing to Disclose
B Haluk Guvenc, MD: Nothing to Disclose
Munther Haddad, MD: Nothing to Disclose
Jerzy Harasymczuk, PhD: Nothing to Disclose
Carroll M. Harmon, MD: Nothing to Disclose
Iain A. Hennessey, MD: Nothing to Disclose
George W. Holcomb III, MD: Nothing to Disclose
Celeste Hollands, MD: Ethicon, Stryker
Thomas H. Inge, MD: Ethicon
Michael S. Irish, MD: Nothing to Disclose
Svetlana Yrevna Ishkova, DO: Nothing to Disclose
Tadashi Iwanaka, MD: Nothing to Disclose
Nenad Janic, PhD: Nothing to Disclose

Disclosures

Martin Michael Kaiser, MD: Nothing to Disclose
N. Kalfa, MD: Nothing to Disclose
Timothy D. Kane, MD: Nothing to Disclose
Adrien J. Kant, MD: Coalescent Surgical-Grants/research support
Doug Katz, MD: Nothing to Disclose
Mendez Keimari, MS: Nothing to Disclose
K. Khelif, MD: Nothing to Disclose
Chris Z. Kimber, MD: Nothing to Disclose
Oleg Kleiner, MD: Nothing to Disclose
Curt S. Koontz, MD: Nothing to Disclose
Vladimir Igorevich Kotlobovsky, MD: Nothing to Disclose
Yuri A. Kozlov, MD: Nothing to Disclose
Karel Krafka, MD: Nothing to Disclose
J. F. Kuebler, MD: Nothing to Disclose
Joachim F. Kuebler, MD: Storck- Grants/research support
Pablo Laje, MD: Nothing to Disclose
Vinh T. Lam, MD: Nothing to Disclose
Francesco FascettiLeon, MD: Nothing to Disclose
Marc A. Levitt, MD: Nothing to Disclose
Charles M. Leys, MD: Nothing to Disclose
Chengchang Li, MD: Nothing to Disclose
M. Lima, MD: Nothing to Disclose
Thom E. Lobe, MD: Nothing to Disclose
Pedro-Jose Lopez, MD: Nothing to Disclose
M. Lopez, MD: Nothing to Disclose
Pedro-Jose Lopez*, MD: Nothing to Disclose
Yee Low, MD: Nothing to Disclose
Gordon A. MacKinlay, MD: Nothing to Disclose
Atul K. Madan, MD: Nothing to Disclose
Przemyslaw Mankowski, MD: Failed To Disclose
Jacques Marcescaux, MD: Nothing to Disclose
Antonio Marte, BA: Nothing to Disclose
Marcelo Martinez-Ferro, MD: Nothing to Disclose
Lucas E .M. Matthyssens, MD: Nothing to Disclose
Giolamo Mattioli, MD: Nothing to Disclose
Patrick M. McEnaney, MD: Nothing to Disclose
Elizabeth J. McLeod, MD: Nothing to Disclose
John J. Meehan, MD: Nothing to Disclose
Antonio Messineo, MD: Nothing to Disclose
Ueli Moehrlen, MD: Nothing to Disclose
Jorge G. Mogilner, MD: Nothing to Disclose
Philippe Montupet, MD: Nothing to Disclose
Edgar Morales-Juvera, PhD: Nothing to Disclose
H. Morgado, BA: Nothing to Disclose
Manfred H. Muller, MD: Nothing to Disclose
F. D. Munro, MD: Nothing to Disclose
Imran Mushtaq, MD: Nothing to Disclose
Ramanujam T. Muthurangam, MD: Nothing to Disclose
P. Nachulewicz, PhD: Nothing to Disclose
AZAD S. Najmaldin, MD: Nothing to Disclose
Nam X. Nguyen, MD: Nothing to Disclose
Liem T. Nguyen, PhD: Nothing to Disclose
Peter F. Nichol, MD: Nothing to Disclose
A. Numanoglu, MD: Nothing to Disclose
M.W.N. Oomen, MD: Nothing to Disclose
Anthony D. Owen, Mr: Failed To Disclose
Alfonso Papparella, MD: Nothing to Disclose
David A. Partrick, MD: Nothing to Disclose
Dariusz Patkowski, PhD: Nothing to Disclose
Jose Luis Peiro, MD: Nothing to Disclose
Jose L Peiró, MD: Nothing to Disclose
Jeffrey C. Pence, MD: Nothing to Disclose
Paul Philippe, MD: Nothing to Disclose
J. Duncan Phillips, MD: Nothing to Disclose
Lisandro A. Piaggio, MD: Nothing to Disclose
Igor V. Poddoubnyi, MD: Nothing to Disclose
Guillaume Podevin, MD: Nothing to Disclose
Rudolph Pointer, MD: Nothing to Disclose
A. Porreca, MD: Nothing to Disclose
Sai Prasad TR, MD: Nothing to Disclose
Sun Qinglin: Failed To Disclose
Branka Radojcic, MSc: Nothing to Disclose
Olivier Reinberg, MD: Nothing to Disclose
Mario Riquelme, MD: Nothing to Disclose
Stuart A. Robertson, MD: Nothing to Disclose
Piero Romano, MD: Nothing to Disclose
Steven S. Rothenberg, MD: Valleylab, Karl Storz
Jun Sakamoto, PhD: Nothing to Disclose
Amulya K. Saxena, MD: Baxter- Other
Felix Schier, MD: Nothing to Disclose
Jurgen Schleef, MD: Nothing to Disclose
Allan M. Shanberg, MD: Nothing to Disclose
Rasheed A. O. Shidi, MD: Nothing to Disclose
Scott A. Shikora, MD: U.S. Surgical, Synovis, Surgical Innovations, Transneuronix, Inc.
Akihiro Shimotakahara, PhD: Nothing to Disclose
Edward Shlasko, MD: Nothing to Disclose
Daniel Sidler, MD: Nothing to Disclose
Lambert Skoog, MD: Nothing to Disclose
Claudio Spinelli, MD: Nothing to Disclose
S. B. Spyrakos, MD: Nothing to Disclose

Disclosures

Theodore H. Stathos, MD: Nothing to Disclose
Henri Steyaert, MD: Nothing to Disclose
Richard Strauss, MD: Johnson & Johnson, Ethicon
Lutz Stroedter, MD: Nothing to Disclose
Janusz Sulislawski, MD: Nothing to Disclose
Makoto Suzuki, MD: Nothing to Disclose
Philipp O. Szavay, MD: Nothing to Disclose
Barbara Tadini, MD: Nothing to Disclose
Dra. Natalia E. Tamburi, RN: Nothing to Disclose
Hock L. Tan, MD: Ethicon, Karl Storz
Burak Tander, MD: Nothing to Disclose
Holger K. Till, MD: Nothing to Disclose
Michael V. Tirabassi, MD: Nothing to Disclose
Salmai Turial, MD: Nothing to Disclose
Benno M. Ure, MD: Nothing to Disclose
Juan P. Valdivieso, MD: Nothing to Disclose
Laura Valfrè, MD: Nothing to Disclose
Jean stephane M. Valla, MD: Nothing to Disclose
Yvan van de Plas, MD: Nothing to Disclose
David C. van der Zee, MD: Nothing to Disclose
Cornelia Van Tuil, MD: Nothing to Disclose
Ricardo Villalpando C, PhD: Nothing to Disclose
S. Vinardi: Nothing to Disclose
John H.T. Waldhausen, MD: Nothing to Disclose
J. Waldschmidt, PhD: Nothing to Disclose
Gregor M. Walker, MD: Nothing to Disclose
Robert Weil, MD: Nothing to Disclose
Alexandra Weltzien, MD: Nothing to Disclose
Barbara E. Wildhaber, MD: Nothing to Disclose
James Wood, MD: Nothing to Disclose
Mark L. Wulkan, MD: Nothing to Disclose
Aydin Yagmurlu, MD: Nothing to Disclose
Atsuyuki Yamataka, MD: Nothing to Disclose
Dani Yardeni, MD: Nothing to Disclose
C.K. Yeung, MD: Nothing to Disclose
Peter K.F. Yip: Nothing to Disclose
Garret Zallen, MD: Nothing to Disclose
Jeffrey L. Zitsman, MD: Nothing to Disclose

6° Congresso Nazionale della Società Italiana di Videochirurgia Infantile

WEDNESDAY

Venezia Lido, 1 Giugno 2005

Programma Scientifico

12.00 Riunione Assemblea dei Soci

13.00 Inaugurazione e Lettura introduttiva del Presidente della SIVI e IPEG

13.30 PANEL "UROLOGIA E GINECOLOGIA"
Moderano: G. Amici, G. Riccipetitoni
Discussants: M. Lima, G. Cobellis, M. Cimador

NEFRECTOMIA RETRO E VIDEO LAPAROSCOPICA: L'ESPERIENZA DELLA S.I.V.I. G. Riccipetitoni, M. Lima, L. Mastroianni, C. Esposito, A. Settimi, A. Garzi, A. Papparella, A. Marte, G. Monguzzi, M. Cimador (Cosenza, Bologna, Ancona, Napoli, Siena, Milano, Palermo)

Scopo: La nefrectomia e l'eminefrectomia, tradizionalmente eseguite nel bambino per via antero-laterale con una conseguente debolezza della parete muscolare, trovano oggi una eccellente soluzione nella chirurgia mininvasiva e, in modo particolare, nell'approccio retroperitoneoscopico.

Riportiamo l'esperienza di un gruppo di chirurghi della SIVI relativa a 74 procedure retro e videolaparoscopiche.

Materiali e metodi: sono stati trattati con tecnica mininvasiva 74 pazienti: in 70 di essi è stata eseguita una nefrectomia, in 4 un' eminefrectomia. L'approccio laparoscopico, con l'impiego da 3 a 5 trocars, è stato eseguito in 7 pazienti: 6 con un rene normotopico, 1 con rene ectopico pelvico. Nei restanti 67 pazienti è stato preferito l'approccio retroperitoneoscopico (63 nefrectomie e 4 eminefrectomie) posizionando il paziente in decubito laterale ed utilizzando tre trocars operativi; si trattava di: 40 casi di rene multicistico, 5 casi di sindrome del giunto pielo ureterale, 9 casi di displasia renale (2 ipoplasia, 3 ureterocele, 3 ureteri ectopici, 1 ureterocele in rene ectopico), 12 casi di rene grinzo, 1 caso di calcolosi renale.

L'età variava tra 12 mesi e 18 anni (l'età inferiore ha interessato soprattutto pazienti con rene multicistico). La durata media delle procedure è stata di 130' (range compreso tra 70' e 180').

In 6 casi di retroperitoneoscopia è stato accidentalmente determinato un pneumoperitoneo, risolto in 2 casi con desufflazione con ago; in 4 casi con conversione. Un altro paziente (caso di calcolosi renale) ha richiesto la conversione per difficoltà tecniche. In totale si sono rese necessarie 5/67 conversioni (7.4%) nella serie retroperitoneoscopica. Non si è manifestato nessun caso di sanguinamento intra o post operatorio e la degenza media è stata di circa tre giorni.

Conclusioni: La nefrectomia con tecnica mininvasiva rappresenta una soluzione sicura ed efficace. L'approccio retroperitoneoscopico rispetto a quello laparoscopico offre il vantaggio di evitare la manipolazione e la dissezione colica e, in alcuni casi, il rischio di inquinamento del cavo peritoneale permettendo, inoltre, un approccio diretto al rene ed una buona esposizione dell'ilo renale.La tecnica miinvasiva offre, inoltre, il vantaggio di praticare un'exeresi completa dell'uretere nei casi di uretere ectopico prevenendo la sindrome del moncone ureterale residuo. Nella nostra serie non ci sono state complicanze maggiori, né sanguinamenti, la procedura è stata completata con successo in 68/74 pazienti (91.8%) con evidenti vantaggi che hanno portato ad una rapida dimissione, ad una rapida ripresa dell'attività fisica ed ad un buon risultato estetico con integrità della parete muscolare..

LAPAROSCOPIA IN GINECOLOGIA PEDIATRICA. ESPERIENZA DI 4 ANNI Falchetti D, Torri F, De Previde D, Milianti S, Ubertazzi M, Specchia C*, Ekema G., Clinica chirurgica pediatrica, *Clinica ostetrica e ginecologica, Spedali Civili, Brescia

L'approccio laparoscopico al trattamento dei problemi ginecologici è consolidato anche in età pediatrica. In questo lavoro viene proposta la nostra esperienza degli ultimi quattro anni in questo campo.

Tra il 2000 e il 2004 20 bambine tra gli 11 mesi ed i 14 anni (media 11 anni) sono state ricoverate per massa ovarica. Tutte le pazienti sono state sottoposte a studio ecografico, e in casi selezionati a TC o RMN.

L'intervento laparoscopico è stato eseguito in urgenza in caso di sospetta torsione ovarica.

La procedura è stata sempre iniziata con scopo diagnostico attraverso il posizionamento di un singolo trocar in posizione subombelicale, con un'ottica operativa. I reperti intraoperatori hanno dimostrato: cisti ovarica semplice (7 casi), torsione ovarica (6 casi), teratoma (3 casi), cisti della teca luteinica, idrosalpinge, cisti della salpinge, idatide ovarica (1 caso ciascuno).

In 3 casi è stata necessaria l'annessiectomia, in uno la salpingectomia, mentre in 17 è stata possibile una procedura conservativa con il risparmio dell'ovaio.

Tutti gli interventi sono stati eseguiti con 2 o 3 accessi. Motivi prudenziali o difficoltà tecniche hanno indotto in 4 casi ad una conversione laparotomica.

Il decorso postoperatorio è stato regolare in tutte le pazienti. Il controllo ecografico a breve termine delle ovaie preservate non ha evidenziato significative differenze rispetto alla gonade controlaterale.

La chirurgia laparoscopica si conferma di grande utilità nelle problematiche ginecologiche anche in età pediatrica: consente di migliorare l'accuratezza diagnostica, è meno traumatica e permette anche l'esecuzione di procedure altamente conservative.

«PALOMO LAPAROSCOPICA». UTILIZZO DELLA LINFOGRAFIA CON BLU PER LA PREVENZIONE DELL'IDROCELE POST-OPERATORIO : DUE TECNICHE A CONFRONTO Chiarenza S.F., CheliM.*, Musi L., Locatelli G.* U.O. di Chirurgia Pediatrica "Ospedale S. Bortolo Vicenza", Vicenza, *U.O. di Chirurgia Pediatrica Azienda ospedaliera Ospedali Riuniti di Bergamo

OBIETTIVI - L'idrocele testicolare sembra essere la maggiore complicanza dopo l'intervento di «Palomo» per via laparoscopica. Per prevenire tale complicanza la U.O. di Chirurgia Pediatrica di Vicenza e la U.O. di Chirurgia Pediatrica di Bergamo utilizzano la linfografia perioperatoria mediante iniezione di colorante blu rispettivamente in sede intradartoica e intraalbuginea. Questa tecnica permette di colorare i vasi linfatici perifunicolari e quindi di risparmiarli al fine di ridurre l'incidenza dell'idrocele post-chirurgico. Questo lavoro preliminare si si prefigge di comparare l'efficacia e la fattibilità delle 2 tecniche linfografiche nella prevenzione dell'idrocele testicolare .

PAZIENTI METODI E RISULTATI - Il totale dei pazienti studiati nelle due U.O dal luglio del 2002 al giugno 2004 è stato di 45 con età media di 12,5 anni (7-17). Il grado di varicocele era il III secondo la classificazione di Steno ed il lato interessato sempre il sinistro . In entrambi i centri è stata eseguita la legatura alta delle vene spermatiche (Palomo) per via laparoscopica con la preservazione quando visualizzati dei vasi linfatici.

Le tecniche linfografiche applicate sono state diverse, infatti in un centro è stata eseguita la linfografia per via intradartoica nell'altro la linfografia per via intraalbuginea. Le tecniche ed i risultati sono riportati nella tabella sottostante .

	CHIRURGIA PEDIATRICA DI VICENZA (gruppo I)	CHIRURGIA PEDIATRICA DI BERGAMO (gruppoII)	TOTALE
NUMERO DI PAZIENTI TRATTATI CON PALOMO LAPAROSCOPICA	27	18	45
TECNICA LINFOGRAFICA	Iniezione di 2-3 ml di blu patent i n sede intradartoica durante l'induzione	Iniezione di 0,3 ml di blu di metilene sede intraalbuginea durante l'induzione	
VISUALIZZAZIONE INTRAOPERATORIA DEI VASI LINFATICI	17 pazienti (63%)	16 pazienti (88,8%)	33(73%)
COMPLICANZE INTRA O POST-OPERATORIE	Nessuna	Nessuna	nessuna
IDROCELE TESTICOLARE (follow-up min 6-max 24 mesi)	Nessuno *	Nessuno	nessuno
VARICOCELE RECIDIVO	Nessuno	nessuno	nessuno

* 1 caso di idrocele di grado medio a 12 mesi in paziente in cui non sono stati visualizzati i vasi linfatici

CONCLUSIONI E DISCUSSIONE - Il follow-up è stato minimo di 6 e massimo di 24 mesi ; in entrambi i gruppi di pazienti non vi è stata recidiva di varicocele nè presenza di idrocele testicolare post-varicocelectomia ; dei pazienti in cui la linfografia non è stata positiva 1 ha riportato a distanza di 12 mesi dall'intervento un idrocele testicolare di grado medio .

Alla luce dei positivi risultati preliminari, la linfografia perioperatoria (

in corso di varicocelectomia laparoscopica sec palomo) , appare una tecnica relativamente semplice, ripetibile ed efficace nella prevenzione dell'idrocele testicolare post-operatorio. I dati emersi evidenziano come la efficacia di visualizzazione dei vasi linfatici sia complessivamente del 73% e che la iniezione intraalbuginea sia più efficace rispetto a quella intradartoica. Rimane tuttavia ancora controverso l'effetto di un eventuale contatto del blu di metilene con le cellule germinali del testicolo.

L'INTERVENTO DI PALOMO PER VIA LAPAROSCOPICA vs L'APPROCCIO INGUINALE CON "BLU VENOGRAPHY" NEL TRATTAMENTO DEL VARICOCELE IN ETÁ PEDIATRICA Ciro Esposito2, Aurelie Chiappinelli1, Antonio Savanelli1, Francesca Alicchio1, Antonella Centonze2, Rossana Tucciarelli2, Alessandro Settimi1

1- Cattedra di Chirurgia Pediatrica, Università di Napoli "Federico II"
2 -Cattedra di Chirurgia Pediatrica, Università di Catanzaro "Magna Grecia"

Introduzione: Lo scopo di questo studio è di confrontare i risultati e le complicanze di due tecniche mini-invasive utilizzate nel trattamento dei pazienti pediatrici con varicocele monolaterale sinistro.

Materiali e Metodi: In un periodo di 4 anni dal gennaio 1998 al dicembre 2001, 61 pazienti pediatrici portatori di varicocele sinistro sono stati sottoposti ad intervento chirurgico. Nei pazienti, che avevano un'età variabile tra i 10 ed i 17 anni (13.5 media), l'indicazione all'intervento è stata: in 2 casi un varicocele di I grado; in 7 casi di II grado; in 30 di III grado; ed in 22 di IV grado. In 54/61 (88.5%) casi é stato realizzato un ecocolor doppler pre-operatorio, in 7 casi solo l'esame clinico. In 3 casi é stato realizzato uno spermiogramma.In 33 casi (54 %) è stato realizzato un intervento di Palomo per via laparoscopica, in 28 casi (46%)è stato realizzato un approccio inguinale open con l'uso di una venografia al blu di metilene per-operatoria, ed in tutti i casi l'arteria è stata risparmiata. In 6/33 (18.1%) casi per via laparoscopica è stata realizzata una procedura addizionale, in 5 casi è stato chiuso un dpv controlaterale pervio ma silente clinicamente, ed in un caso è stata realizzata una lisi di aderenze.

Risultati: La durata media d'intervento è stata di 25 minuti per via laparoscopica e di 50 minuti per via inguinale. La degenza ospedaliera è stata equivalente nelle due tecniche in media 2 giorni. Il dolore post-operatorio è stato nettamente inferiore per via laparoscopica. Abbiamo avuto 2 complicanze intraoperatorie uno spandimento del blu di metilene per via open ed un sanguinamento di un vaso parietale per via laparoscopica. Al follow-up medio di 36 mesi abbiano riscontrato una sola recidiva nel gruppo open (1/28; 3.5%) e nessuna recidiva per via laparoscopica. Al contrario abbiamo avuto 1/28 (3.5%) idroceli per via open e 6/33 (18.1%) idroceli per via laparoscopica.

Conclusioni: Le due tecniche analizzate sembrano ugualmente valide nel trattamento del varicocele monolaterale sinistro, con un bassa incidenza di recidive. La via laparoscopica mostra un'alta incidenza di idroceli nel post-operatorio anche se permette di realizzare dei gesti chirurgici associati, come la chiusura del dpv o la lisi di aderenze.

VIDEOLAPAROSCOPIA: GOLD STANDARD NEL TRATTAMENTO DELLA PATOLOGIA GINECOLOGICA PEDIATRICA M.G.R. Aceti, M.G. Sicilia, A. La Riccia, G. Riccipetitoni, U.O. di Chirurgia Pediatrica - Azienda Ospedaliera di Cosenza

Scopo del lavoro. Evidenziare il ruolo della laparoscopia come gold standard diagnostico-terapeutico nel trattamento della patologia ginecologica pediatrica.

Materiali e Metodi. 33 pazienti (età 1 gg – 18 aa) con patologia ginecologica sono state sottoposte a laparoscopia diagnostica e/o operativa: 22 cisti ovariche, 3 masse ovariche, 7 malformazioni utero-vaginali, 1 stato intersessuale.

Delle 22 cisti ovariche (10 casi di età < 2 mesi; peso minimo 2,5 Kg): 15 erano cisti semplici (diametro > 5 cm) e 7 presentavano una torsione; tutte sono state trattate con puntura transparietale ed asportate per via transombelicale in 19 casi e nei restanti 3 attraverso il trocar operativo di destra.

Nelle 3 masse ovariche (1 tecoma sinistro; 1 teratoma sinistro; 1 cistoma sinistro del diametro di 23 cm) la laparoscopia è stata terapeutica solo nel 3° caso e diagnostica nei primi due.

Nelle malformazioni utero-vaginali (2 sindromi di Rokitansky; 1 atresia vaginale; 1 duplicità vaginale con utero bicorne; 1 vagina con setto traverso medio-basso ed utero bicorne e bicolle; 1 duplicità uterina con atresia vaginale destra, 1 utero bicorne con rene destro ectopico displasico ed ureterocele) la laparoscopia è stata fondamentale al completamento dell'iter diagnostico ed ha guidato la correzione chirurgica della malformazione. Nel caso di stato intersessuale (sindrome di femminilizzazione testicolare) è stata, per ora, solamente diagnostica.

Risultati. In 30/33 pazienti (90,9%) la laparoscopia è stata di utilità non solo diagnostica, ma prevalentemente terapeutica; la metodica è risultata facilmente praticabile in epoca neonatale ed in pazienti di basso peso; non sono state rilevate complicanze intraoperatorie; 1 sola complicanza infettiva post-operatoria (3%), né complicanze a distanza.

Il ricorso alla puntura transparietale delle cisti ha permesso l'asportazione anche di masse cistiche estremamente voluminose attraverso l'accesso ombelicale, ricorrendo spesso alla tecnica one trocar.

Conclusioni. In ginecologia pediatrica la laparoscopia, procedura indispensabile alla fase diagnostica è divenuta il gold standard terapeutico in ogni range di età, con costo estetico veramente minimo, spesso circoscritto al solo accesso ombelicale.

Le uniche limitazioni sono rappresentate dalle masse tumorali in cui è, comunque, proponibile un accesso videoassistito.

ONE TROCAR ASSISTED PYELOPLASTY (OTAP): INITIAL EXPERIENCE AND CODIFICATION OF A TECHNIQUE

M. Lima, G. Ruggeri, S. Tursini, P. Messina, L. De Biagi, U.O. di Chirurgia Pediatrica - Policlinico S.Orsola-Malpighi Bologna

Introduction: The Anderson-Hynes pyeloplasty is still considered the gold standard for the surgical treatment of the ureteropelvic junction obstruction (UPJO). However the muscular trauma and the skin incision can be considerable. Laparoscopic and retroperitoneoscopic pyeloplasty have been proposed but concerns have been expressed regarding those techniques. In case of retroperitoneal approach in children, the small operative space and the technical difficulties have limited the application of this technique, while in case of laparoscopy, a transperitoneal technique is used to treat a retroperitoneal disease. We report our initial experience with a videoassisted retroperitoneoscopic approach, the "one trocar assisted pyeloplasty" (OTAP) in the treatment of UPJO in children.

Materials and methods: Three males children, respectively 2, 5 and 8months old, with impaired left renal function underwent surgical treatment for UPJO. They were positioned in a lateral kidney position and the Gerota's fascia was bluntly reached and opened via a flank 12 mm incision. The renal pelvis was anteriorly approached using a 10 mm operative telescope. The UPJ was exteriorized and a dismembered pyeloplasty performed. Nor transanastomotic tutor either pyelic drain was left. The bladder catheter was removed after 24 hours.

Results. The patients were discharged after four days without early complications. The cosmetic results are excellent. No complication is seen at the clinical and US follow-up after 1 and 3 months.

Discussion. In our opinion the OTAP could be considered as a safe and feasible alternative to the laparoscopic or retroperitoneoscopic pyeloplasty. Nevertheless more experience and a longer follow-up are needed.

RUOLO DELLA LAPAROSCOPIA NEL TRATTAMENTO DELLA COMPONENTE DEFERENZIALE NEL VARICOCELE DI TIPO MISTO (DI 3° TIPO SEC. COOLSAET) NEI BAMBINI E NEGLI ADOLESCENTI

Cimador M, Di Pace MR, Sergio M, Castagnetti M, De Grazia E., Cattedra di Chirurgia Pediatrica, Università di Palermo

Introduzione. La terapia chirurgica del varicocele è tuttora alla ricerca di una tecnica gold-standard che sia in grado di correggere senza recidive, preservare la funzione testicolare, ridurre al minimo la morbilità post-operatoria precoce e tardiva, contenere i costi di gestione. L'uso dell'eco-color Doppler ha consentito nella nostra esperienza di porre diagnosi differenziale tra i diversi tipi di varicocele, identificando le forme miste (reflusso reno-spermatico associato al reflusso iliaco-deferenziale, 3° tipo sec.Coolsaet), da quelle reno-spermatiche isolate (1° tipo sec. Coolaset). Mentre in precedenza il nostro orientamento era stato di trattare il varicocele di 1° tipo con la tecnica di Palomo per via transperitoneale laparoscopica e le forme di 2° tipo con la legatura subinguinale sec. Goldstein, vogliamo proporre in questa sede la correzione laparoscopica anche delle forme associate a reflusso iliaco-deferenziale.

Note di tecnica Sulla scorta dell'eco-colorDoppler preoperatorio, si identificano le forme di varicocele di 3° tipo mettendo in evidenza la presenza di un reflusso iliaco-deferenziale durante la manovra di Valsalva. Si procede quindi all'esplorazione laparoscopica con tecnica a 3 trocars da 5 mm (ombelicale, fianco sinistro, fossa iliaca destra) ed accesso open dell'ombelico. Dopo aver provocato lo pneumoperitoneo ad una pressione di 12 mmHg, si esplora le regione inguinale sinistra e si identificano il fascio vascolare spermatico e la vena deferenziale, che, quando dilatata e refluente, è facilmente visibile, decorrendo parallelamente al dotto deferente, in una posizione a cavaliere sul fascio vascolare iliaco. Dopo la legatura in blocco del fascio spermatico (non-artery sparing) con applicazione di clips e la sua sezione, si procede con la scheletrizzazione della vena deferenziale dal dotto deferente. La vena viene quindi coagulata a caldo e sezionata.

Risultati Al momento non è possibile presentare dei dati statisticamente validi, in quanto abbiamo applicato la tecnica solo su 11 pazienti. Purtuttavia, l'esame eco-colorDoppler eseguito nel postoperatorio in 15^ giornata ha evidenziato l'assenza di vene refluenti con la manovra di Valsalva.

Conclusioni La tecnica da noi proposta consente di unificare l'approccio al varicocele, utilizzando la via laparoscopica sia nelle forme reno-spermatiche isolate che nelle forme miste iliaco-deferenziali. Come evidenziato dalla più recente letteratura, il numero di recidive (o meglio di persistenza) del varicocele si è significativamente ridotto e la tecnica di Palomo si è rivelata molto efficace. Purtuttavia è altresì dimostrato che esiste una quota di varicoceli, associato a circoli collaterali refluenti diversi, che non possono essere trattati con la sola tecnica di Palomo; è per questa ragione che già in passato abbiamo affermato la superiorità della tecnica della legatura subinguinale. Con l'approccio da noi proposto in questa sede si auspica di riuscire a ridurre ulteriormente sia la quota di persistenza del varicocele che il ricorso alla chirurgia tradizionale per trattare quei varicoceli complessi, di cui la componente refluente iliaco-deferenziale rappresenta una quota non trascurabile.

Coolsaet BL. The varicocele syndrome: venography determining the optimal level for surgical management. J Urol. 1980 Dec;124(6):833-9.

Sarteschi LM et al Lo studio del varicocele con eco-color-Doppler. Giornale Italiano di Ultrasonologia 4:43,1993

Cimador M et al Sub-inguinal interruption of dilated veins in adolescent varicocele: it is to be considered a gold standard technique? Minerva Pediatr. 2003 Dec; 55(6): 599-605.

LA VARICOCELECTOMIA RETROPERITONEOSCOPICA NEL BAMBINO E NELL'ADOLESCENTE: NOTE DI TECNICA

G. Cobellis, L. Mastroianni, A. Cruccetti, G. Amici, A. Martino, S.C di Chirurgia Pediatrica - A.O.U. - Ospedali Riuniti - Presidio Materno-Infantile "G.Salesi"

Introduzione: La tecnica di sezione dei vasi spermatici per via retroperitoneoscopica per il trattamento del varicocele è stata introdotta da Gaur nel 1994 e successivamente applicata da Valla nel bambino utilizzando un approccio con trocar unico. Presso la nostra Unità Operativa la tecnica di Valla è stata adottata a partire dal 1999. Da una precedente revisione di 97 pazienti trattati tra gennaio 1999 e luglio 2003 è risultata non trascurabile l'incidenza di conversioni (17,6%). Tali conversioni sono state dovute ad una perdita di orientamento nello spazio retroperitoneale e difficoltà nell'identificazione dei vasi spermatici, in taluni casi a causa dell'apertura del peritoneo posteriore. Scopo di questo lavoro è puntualizzare i dettagli tecnici della varicocelectomia per via retroperitoneoscopica sottolineando quelli che nella nostra esperienza riteniamo essere i tempi fondamentali di questa tecnica al fine di limitare la possibilità di conversione.

Metodi: Il paziente viene posto in decubito laterale destro. Un'incisione trasversa di circa 1,5 entimetri viene condotta immediatamente al di sotto dell' apice della lla o 12a costa.Si orocede quindi alla dissezione delle fibre muscolari parietali ed all'apertura sotto visione della fascia di Gerota. Si introduce un trocar di Hasson con palloncino ed si induce il pneumoretroperitoneo fino alla pressione di 15 mmHg. Attraverso un'ottica operativa a 0° si introduce un batuffolo dissettore che consente di creare una camera di lavoro sotto visione endoscopica. Il primo repere anatomico è il muscolo psoas la cui esposizione è fondamentale per il mantenimento dell'orientamento nello spazio retroperitoneale. La dissezione retroperitoneale prosegue seguendo il muscolo psoas fino ad evidenziare l'uretere. I vasi spermatici, localizzati medialmente all'uretere, durante la dissezione si distaccano dai piani posteriori seguendo il peritoneo; essi vengono quindi separati dal peritoneo, isolati per un tratto sufficientemente lungo, coagulati con bipolare e sezionati.

Nei casi in cui non vengono identificati i vasi spermatici preferiamo procedere alla conversione laparoscopica transperitoneale piuttosto che continuare nella dissezione retroperitoneale a più trocar o convertire in laparotomia.

Risultati: Nel periodo gennaio 1999- gennaio 2005 121 pazienti di età compresa tra 6 e 16 anni (mediana 12,5 anni) sono stati sottoposti a varicelectomia sinistra con approccio retroperitoneoscopico. L'incidenza di conversione laparoscopica transperitoneale è stata pari al 15,7% (19 pazienti) nella casistica complessiva ed al 7,5% (3 pazienti) negli ultimi 40 pazienti trattati.

Conclusioni: La tecnica di sezione dei vasi spermatici per via retroperitoneoscopica richiede una comprovata esperienza di chirurgia laparoscopica ed è comunque gravata da una discreta incidenza di conversioni. Da un punto di vista tecnico, sulla base della nostra esperienza, riteniamo importante eseguire sempre l'apertura della fascia di Gerota sotto visione prima dell'introduzione del trocar e 1' identificazione in successione dei reperi anatomici retroperitoneoscopici, muscolo psoas ed uretere al fine di mantenere l'orientamento nello spazio retroperitoneale, necessario per l'identificazione dei vasi spermatici.

14.30 PANEL "CHIRURGIA COLICA, SPLENICA E BILIARE"
Moderano: V. Jasonni, M. Lima
Discussants: G. Riccipetitoni, G. Monguzzi, L. Mastroianni

LAPAROSCOPIC CHOLECYSTECTOMY FOR CHOLELITHIASIS IN INFANTS AND CHILDREN: EXPERIENCE FROM THE FIRST 52 CONSECUTIVE CASES Maurizio Cheli,MD; Daniele Alberti,MD; Mara Colusso,MD; Alessandro Lucianetti,MD; and Giuseppe Locatelli,MD, Dept. of Pediatric Surgery-Ospedali Riuniti di Bergamo

BACKGROUND/PURPOSE - Laparoscopic cholecystectomy (LC) is today the standard of care for children with symptomatic gallstones disease. The technique is performed with increasing frequency and is rapidly gaining popularity among pediatric surgeons. This is a retrospective review focused on our experience in laparoscopic cholecystectomy in a group of 52 patients with a miscellaneous diseases (tab. 1) leading to cholelitiasis. The purpose of the study is to evaluate surgical technique, related complications of LC and results.

PATIENTS AND METHODS - Between January 1999 and June 2004 52 children with symptomatic gallstones disease underwent LC at our Department. Patients characteristics and indications for surgery was sumarized in the tab.2. All the procedures was performed by the same team of two surgeons with experience in the field of hepatobiliary surgery. LC was performed using a four trocars technique and access to the abdominal cavity realized with the open technique. No intraoperative cholangiography was realized. Mean operative time was 90.6 minutes (range 45-130). Associated procedures were realized in 9 patients. All gallbladers showed pathological evidence of acute or chronic cholelithiasis.

RESULTS - There were no major complications or mortality. It was two conversions to open procedure at the beginning of the experience for bleeding and for extensive adesions for previous surgery. Shoulder pain was documented in 12 patients (23%). The duration of parenteral analgesia was limited for the first 48 hours in all patients. All patients were fed on the 1st postoperative day and discharged at a mean of 3 postoperative days (range, 2- 4).

CONCLUSIONS - In the light of our experience the risk of complications from LC is low. Complications are overall rare and the techinique seems to be as effective as open procedure. Experience in hepatobiliary surgery is strongly recommended and according to all authors, a learning curve must be passed through: proficiency and operative time become more consistent after the first 20 patients. A clear identification of the structures of the triangle of Calot is mandatory before clipping and division. Early conversion to open surgery is recommended if identification of the anatomy or control of bleeding are inadequate. We concluded that LC may be recommended in infants and children for treatment of symptomatic gallstones disease and for patients with asymptomatic gallstones associated with hemolytic disease in whom a laparoscopic

splenectomy is required.

Tab 1 Indications for surgery

N° of Patients	Indications
11	Hereditary spherocytosis
1	Sickle cell anemia
1	Long term TPN
39	Symptomatic gallstones disease

Tab2 Characteristics of the patients

Characteristics	
N° of patients	52
Sex (M:F)	20:32
Average Age (years)	7.6 (range 1-14)
Weight (kg)	24 (range 12-28)
Previous surgery	4
Associated procedures	9 (splenectomy)
Operating time (minutes)	90.6 (range 45-180)
Conversion	2
Analgesia p.o. (days)	2 (1-3)
Follow-up (months)	18-60

TRATTAMENTO VIDEOASSISTITO DELLA AGANGLIOSI COLICA. ESPERIENZA IN 22 CASI A. Porreca, G. Gaglione, A. Capobianco, A. Tramontano, Divisione di Chirurgia Pediatrica e Pronto Soccorso, A.O. Santobono-Pausilipon, Napoli

Dal marzo 2003 al marzo 2005 sono stati operati nel nostro reparto di pull-through videoassistito secondo Georgeson per m. di Hirschsprung 22 pazienti. In 11 casi l'età era uguale o inferiore a due mesi.

Abbiamo utilizzato tre trocar da 5mm (ombelico, ipocondrio destro, fianco destro) ed uno da 3mm in ipocondrio sinistro. Come strumento di dissezione abbiamo preferenzialmente utilizzato il bisturi armonico.

In un caso è stata necessaria la conversione per la presenza di una stenosi organicacon flogosi periviscerale sul tratto di transizione localizzato al discendente. In due casi di 13 e 40gg con zona di transizione alla flessura splenica si è aggiunta una minilaparotomia (fianco dx e fianco sx). Nei rimanenti casi la zona di transizione era al sigma. Il tempo perineale è stato effettuato secondo la tecnica descritta da Georgeson.

Non si sono verificate complicanze.

Il decorso postoperatorio è stato caratterizzato da assenza di dolore e da canalizzazione in prima giornata.

Il breve follow-up ha dimostrato un andamento clinico sovrapponibile a quello dei pazienti operati con tecnica open

LAPAROSCOPIC ASSISTED ANORECTAL PULL-THROUGH FOR HIGH IMPERFORATE ANUS: THREE YEARS EXPERIENCE M. Lima, G. Ruggeri, S. Tursini, C. Antonellini, T. Gargano, U.O. di Chirurgia Pediatrica – Policlinico S.Orsola-Malpighi Bologna

Background/Purpose: The aim of this report is to describe our three years experience with the Laparoscopic Assisted Anorectal Pull-through for High Imperforate Anus (LAARP) using the laparoscopic muscle electrostimulation.

Methods: In the Dept of Pediatric Surgery of the University of Bologna, from: March 2001 to March 2004 eight patients, with a diagnosis of high anorectal malformations underwent a LAARP. The patients, all males and aged from 4 to 9 months (mean age 5.8 months), presented a recto-urethral fistula.The following associated malformations were described: sacrai malformation, laryngeal stenosis, urethral duplication, multicystic kidney, non palpable testis and esophageal atresia. All were treated with a colostomy in the newborn period followed by a delayed LAARP. The laparoscopic step was characterized by the stimulation of the puborectal muscle, using a modified Peña electrostimulator introduced via a trocar. All patients underwent a post operative period of anal dilatations.

Results: In seven cases the LAARP was succesful while in one case, due to a strong tension from the colostomy, a conversion to open technique, was needed.

Conclusion: Although an evaluation regarding the continence is to be followed up, we consider the LAARP the treatment of choice for the high imperforate anus. It offers the advantage of a good visualization of the fistula and of the surrounding structures and minimally invasive abdominal and perineal wounds.With the laparoscopic Peña stimulator the direct observation of the puborectal slings contraction allows an evaluation of the functional contractility and an accurate colonic pull through in the centre of the muscle complex.

THE LAPAROSCOPIC ASSISTED TRANS-ANAL PULL-THROUGH FOR HIRSCHSPRUNG: A MULTICENTRIC EXPERIENCE IN THE LAST FIVE YEARS Lima M, Ruggeri G, Tursini S, De Biagi L, Gargano T, *Cobellis G, * Amici G, °Aceti MGR, ° Riccipetitoni G, § Mattioli G, § Jasonni V

Department of Pediatric Surgery – "Alma Mater Studiorum" University of Bologna (Italy)

°Department of Pediatric Surgery – Annunziata Hospital – Cosenza (Italy)
*Department of Pediatric Surgery – "G. Salesi" Hospital – Ancona (Italy)
§Department of Pediatric Surgery – "G. Gaslini" Hospital – Genova (Italy)

Introduction: Advances in laparoscopy determinates very important modifications in the treatment of Hirschsprung disease. The aim of this study is analyse the results, of four different centres, in the treatment of Hirschsprung disease, according to Georgeson's primary laparoscopic pull-through.

Materials and Methods: In the last 4 years 74 cases of HD, in four different centres of pediatric surgery, were submitted to primary laparoscopic pull-through (LPT) according to Georgeson's technique. The age ranged between 20 days and 15 years. All were investigated by rectal suction biopsy, barium enema and anorectal manometry. No diverting colostomy was performed and the patients were managed with preoperative bowel nursing. Surgery required 3 operative ports as described by Georgeson. The colon was examined and several biopsies were performed at different proximal levels to precisely define the normoganglionic colon. Surgery was postponed after the results of the intraoperative histochemical studies. The definitive diagnosis were: 27 ultra short segment (US), 37 recto sigmoid segment (RS), 6 long segment (LS), 1 total colonic aganglia (CA) and 3 rectosigmoid segment associated to IND extended to the left flexure. The mesocolon was divided using ligasure, bipolar or monopolar hook. After the transanal dissection was completed, the videoassisted pull-through was carried out making attention to the placement of the pedicle and of the sieromuscular cuff. The operative time ranged from 180' and 540'

Results: There were 2 conversions to open technique, while in 1 case a postoperative colostomy;no addictional intraoperative complication was found. The patients had analgesics for 24 hours. Bowel movements were observed at 24-48 hours , the oral feeding started after 48 hours, the median hospital stay was 7 days. At follow-up 3 patients had grade I enterocolitis in the first months; 2 cases of LS and one case of RS had about 4 toilets/day. In one case of US soiling was present for 5 months postoperatively.

Conclusion: The laparoscopic pulll-through is a safe operation for almost ali cases of HD. It allow to obtain several biopsies necessary to define the precise diagnosis of the disease and to perform a correct surgery. Moreover the laparoscopy permits to avoid the torsion of the vascular pedicle during the trans anal pull-through.

LAPAROSCOPY SPLENECTOMY: POSTERO-LATERAL APPROACH Molinaro F., Garzi A., Amato G., Roggi A, Di Maggio G., Zagordo L.., Messina M., Department of Pediatrics, Obstetrics and Reproduction Medicine, University of Siena – Italy Section of Pediatric Surgery Director: Prof. Mario Messina

Introduction: The development of videolaparoscopic technique has allowed to treat splenic pathologies with minium-invasive technique, with therapeutic outcomes like the opened surgery and good aesthetic ones. This technique has allowed to gain the favor of the patients and their relatives, fundamental aspect in pediatric age. Postero-lateral approach, also feasible with laparoscopic technique, concurs a better visualization of the splenic hilum regarding front or lateral access, with minimal traction of the splenic parenchyma and the adjacent structures, previa the disposition of the patient in right lateral decubitus, with bending of the log and hyperextension of the left flank.

Materials and methods: In the last three years, near the Section of Pediatric Surgery of the Department of Pediatrics, Obstetrics and Medicine of the Reproduction of Siena University, six cases of splenomegaly have been treated by postero-lateral videolaparoscopic splenectomy (4 males and 2 females, with medium age of 10,5 years); four cases of hereditary spherocytosys, one thrombocytopenia and one infect epidermoid cysts; in three cases colecystectomy with laparoscopic technique has been associated; in one case it has been necessary to convert via open. In the males, spleen extraction has been carried out

through an inguinal access, while in the females by means of minium-laparotomy of Pfanniestiel. The medium dimension of the milza has been 14X9 cms with a range from (14-19)X(7-11).

Conclusions: Our experience demonstrates that postero-lateral approach has a good technique because it allows an optimal exposition of the splenic hilum, a best aesthetic outcome, a smaller post-operative pain. The splenectomy, above all with postero-lateral access, represents a good indication for a videolaparoscopic approach, even if it previews a complex training and a complete "learning curves".

15.30 PANEL "CHIRURGIA DELL'ESOFAGO E DIGESTIVA"
Moderano: G. Esposito, G. Mattioli
Discussants: A. Garzi, A. Papparella, C. Esposito

RISULTATI DELLA TECNICA DI HELLER-DOR LAPAROSCOPICA PER IL TRATTAMENTO DELLA ACALASIA ESOFAGEA IN ETA' PEDIATRICA

Pini Prato Alessio, Mattioli Girolamo, Caponcelli Enrica, Buluggiu Anna, Avanzini Stefano, Jasonni Vincenzo, Dipartimento di Chirurgia Pediatrica – Istituto Giannina Gaslini, Genova

INTRODUZIONE - L'Acalasia Esofagea è un disordine neuromotorio esofageo che si presenta nel 5% dei casi in età pediatrica e che configura il quadro clinico del megaesofago. La chirurgia rappresenta il trattamento di scelta dell'affezione in questione. Lo scopo di questo studio è descrivere i risultati della cardiomiotomia extramucosa + fundoplicatio anteriore a 180° eseguita per via laparoscopica.

MATERIALI E METODI - Sono stati inclusi nello studio solo i pazienti di età inferiore ai 14 anni, per i quali la diagnosi di Acalasia Esofagea è stata ottenuta mediante uno studio combinato radiologico, funzionale manometrico e pHmetrico ed endoscopico. Per l'approccio laparoscopico sono stati utilizzati trocars da 5 mm ed una telecamera a 30°. L'estensione della miotomia anteriore è stata basata inizialmente sui dati della manometria intraoperatoria e quindi rispettando specifici punti di riferimento quali l'esofago dilatato, prossimalmente, ed i vasi esofagei trasversali a livello della giunzione gastroesofagea, distalmente. L'integrità della mucosa al termine della miotomia è stata confermata insufflando aria tramite un sondino nasogastrico. Al fine di proteggere la mucosa erniata ed evitare il reflusso postoperatorio è stata sempre confezionata una fundoplicatio anteriore secondo Dor fissata ad entrambi i margini della miotomia. L'alimentazione è stata reintrodotta in prima giornata postoperatoria a seguito di controllo radiologico contrastografico. Il follow-up dei pazienti ha incluso valutazione clinica e controlli specifici sulla base dei sintomi eventuali; a 12 mesi dall'intervento chirurgico è stato eseguito un controllo radiologico, eventualmente anticipato in caso di necessità (Visick score maggiore di 1).

RISULTATI – Sono stati inclusi 15 pazienti. La disfagia è stato sintomo costante mentre infezioni respiratorie ricorrenti correlabili ad eventi di microaspirazione sono state descritte in 4 pazienti. In tutti i casi è stato possibile portare a termine la chirurgia per via laparoscopica. Non si sono verificate perforazioni esofagee mentre si è verificato il sanguinamento di un vaso esofageo che ha richiesto il posizionamento di clip. Il follow up ha avuto una durata media di 40 mesi con Visick score 1 in 12 e 2 in 2 pazienti, 3 in 1 paziente, per il quale si è reso necessario il reintervento

CONCLUSIONI – Data la bassissima incidenza di complicanze e ricorrenza dei sintomi, consideriamo la tecnica di Heller-Dor condotta per via laparoscopica come gold standard per il trattamento chirurgico dell'acalasia esofagea nella popolazione pediatrica.

REFLUSSO GASTRO-ESOFAGEO: NOSTRA ESPERIENZA GLOBALE

Amato G, Garzi A, Nardi N, Molinaro F, Abate V, Meucci D, Messina M., Università degli Studi di Siena, Dipartimento di Pediatria, Ostetricia e Medicina della Riproduzione, Sezione di Chirurgia Pediatrica, Direttore: Prof. Mario Messina

Introduzione Il reflusso gastro-esofageo (RGE) è un evento estremamente comune nel bambino, soprattutto, nel primo anno di vita tanto che risulta particolarmente difficile discriminare la condizione fisiologica da quella patologica. Al determinismo della malattia da reflusso gastro-esofageo (MRGE), concorrono numerosi fattori tra i quali, oltre alle anomalie anatomiche del giunto gastro-esofageo, l'insufficienza dello sfintere esofageo inferiore (LES) gioca il ruolo determinante nell'età pediatrica. La pH-metria nelle 24 ore è considerata il gold-standard per la valutazione quali-quantitativa dell'esposizione acida esofagea e per correlare i sintomi all'evento reflusso ed è generalmente accettata come l'indagine più sensibile e specifica per la diagnosi della malattia da reflusso gastro-esofageo. L'approccio videolaparoscopico ha consentito di allargare l'indicazione chirurgica anche a quei pazienti con gravi deficit neuropsicomotori, che abitualmente non venivano operati per l'elevata morbilità postoperatoria. L'impiego della chirurgia mininvasiva nel trattamento dei pazienti con MRGE ha consentito di ridurre il trauma postoperatorio del piccolo paziente sia sul piano fisico che psicologico e di ridurre considerevolmente i tempi di degenza.

Materiali e metodi Presso la cattedra di Chirurgia Pediatrica dell'Università degli Studi di Siena, dal 1° gennaio 1998 al 1 febbraio 2005, 36 bambini (22 maschi e 14 femmine) affetti da MRGE diagnosticata mediante indagini radiologiche, endoscopiche e pH-metriche, sono stati sottoposti ad intervento chirurgico di plastica antireflusso in videolaparoscopia. Il protocollo ha previsto un primo controllo morfologico del LES ad un mese dall'intervento, tramite esame Rx digerente prossimale a doppio contrasto, e una valutazione funzionale con pH-metria esofagea a 3 mesi. 3 pazienti non sono stati ancora valutati poichè non rientrano nei tempi del follow-up. Mediante l'esame pH-metrico esofageo di controllo sono stati ricavati i sei parametri classici di Johnson e DeMeester (DMSC) e l'area sotto la curva H+ (AUH+) e sono stati confrontati con i valori di riferimento preoperatori.

Conclusioni L'area sotto la curva H+, considerato come il valore più sensibile e specifico per la valutazione funzionale del LES, ha mostrato la totale assenza di reflusso acido nei pazienti trattati chirurgicamente. Si può affermare che l'esame pH-metrico nelle 24h rappresenti il gold standard sia nella diagnosi che nel follow-up dei pazienti trattati chirurgicamente per MRGE.

THORACOSCOPIC REMOVAL OF RESIDUAL BURNED ESOPHAGUS

M.Lima, G.Ruggeri, S.Tursini, L. De Biagi, T.Gargano, U.O. di Chirurgia Pediatrica - Policlinico S.Orsola-Malpighi Bologna

Introduction: The most frequent cause of esophagectomy in children is the presence of strictures related to the ingestion of corrosive agents. When dilatations of burned esophagus are not feasible due to high risk of rupture or when those are unsuccessful, surgical treatment is mandatory. Operative strategy is controversial regarding esophageal substitution and timing of surgery, while the need for esophagectomy to avoid risk of cancer is internationally recognised.We report one case of thoracoscopic esophagectomy as a delayed intervention after open esophagocolonplasty in a child with a burned esophagus.

Materials and methods: A two years old child with a severe esophageal stenosis for accidental ingestion of liquid caustic soda, reached our institution from Mali. A retrosternal isoperistaltic esofagocolonplasty was realised without removing the esophagus. 11 months later the child underwent a complete right thoracoscopic esophagectomy. The patient was positioned in a left lateral decubitus and five trocars were used. A 5 mm for the telescope was positioned at the seventh intercostal space on the midaxillary line. Two 5 mm operative trocars were placed at the fifth and nineth intercostal space posteriorly to the optic, while two 3 mm trocars were positioned anteriorly to the optic to retract the lung.A single lung ventilation was used. The azigos vein was sectioned and the residual esophagus dissected with a monopolar hook and his lower tract was separated from the stomach with a stapler. The defunctioned esophagus was removed from a 5 mm port.

Results: The toracid drain was removed after 24 h and no respiratory problem was seen. The patient was discharged after 11 days and came back to his country in a good condition.

Discussion: Open esophagectomy can be associated with high morbidity and delayed return to routine activities. Thoracoscopic esophagectomy have been proposed both for benign and malignant pathology in adults, while in children the esperience is still poor. In case of caustic burned esophagus, the intense fibrosis and adherences can lead to accidental lesions of the mediastinal structures. Laparoscopic magnification can allow a secure controll of the situation. In our opinion thoracoscopic esophagectomy, in expert hands, can be performed avoiding the risk of long term morbidity of scoliosis, shoulder muscle girdle weakness, and chest wall deformities.

FUNDOPLICATIO LAPAROSCOPICA E GASTROSTOMIA NEI PAZIENTI CON GRAVE DEFICIT NEUROLOGICO

D. Falchetti MD, F. Torri MD, P. Orizio MD, P. Salucci, G Boroni MD, G. Ekema MD, Clinica Chirurgica Pediatrica, Spedali Civili, Brescia

La fundoplicatio gastrica sec. Nissen eseguita con tecnica laparoscopica

(FNL) è il più diffuso trattamento chirurgico della malattia da reflusso gastroesofageo ma nei pazienti con deficit neurologici (DN) è gravato da un elevato tasso di complicanze. Scopo del presente lavoro è la verifica della sicurezza e dell'efficacia della procedura a lungo termine e la valutazione del ruolo della gastrostomia (GS) associata.

Materiali e metodi Dal Settembre 1995 all'Aprile 2004 24 pazienti con DN (M/F 15/9; età 3 mesi-16 anni; peso 2,2-40 kg) sono stati sottoposti nel nostro reparto a FNL. Indicazione all'intervento sono stati: disfagia (65%), vomito (52%), sanguinamento gastrointestinale (39%), polmoniti ricorrenti (39%). La diagnosi si è basata su esofagogastroscopia (71%), istologia (63%), pHmetria esofago-gastrica 24 ore (50%), Rx prime vie digerenti con m.d.c. (13%) e, in casi selezionati, studio dello svuotamento gastrico. In 9 pazienti è stata eseguita una FNL associata a GS; 6 erano già portatori di GS (PEG). Nel postoperatorio la GS è stata utilizzata sia a scopo nutrizionale che decompressivo.

Risultati Non vi sono state complicanze intraoperatorie né conversioni laparotomiche, né si è dovuto procedere alla preventiva soppressione della GS nei casi sottoposti in precedenza a PEG. Tutti i pazienti hanno presentato canalizzazione intestinale in 1° giornata. La degenza media è stata di 7 giorni; il follow up medio di 55 mesi (9-112).

La sintomatologia è regredita in tutti i pazienti tranne 4 (3 polmoniti ricorrenti, 1 sanguinamento intestinale cronico). L'esofagite è guarita in 13/14 pazienti, la pHmetria si è normalizzata in 11/13 ed è migliorata in 2.

Si sono verificate complicanze maggiori in 8 pazienti, 5 dei quali senza GS: 6 casi di ernia paraesofagea senza recidiva di reflusso, e 2 casi di parziale disgregazione della fundoplicatio. Un paziente è deceduto prima del reintervento; in un altro l'uso più corretto della GS ha risolto la recidiva ed evitato l'ulteriore trattamento chirurgico. I pazienti con ernia paraesofagea sono stati rioperati per via laparoscopica e una GS è stata aggiunta in tre casi. Due bambini hanno presentato ulteriore recidiva (in 1 caso 3 volte) e gli interventi successivi sono stati eseguiti per via laparotomica. Tre pazienti sono deceduti per complicanze respiratorie, 3 per cause non correlate al reflusso. Complessivamente il tasso di complicanze è stato del 13%nei 15 pazienti con GS, e del 67% dei 9 pazienti senza GS.

Conclusioni Nei pazienti con grave DN la FNL è associata ad un'elevata percentuale di complicanze. Il trattamento della malattia da reflusso gastro-esofageo nei bambini con DN richiede una approfondita conoscenza delle problematiche specifiche alla loro condizione e può necessitare di procedure diagnostiche e terapeutiche aggiuntive e di un più stretto follow up. La GS può essere utile sia a scopo nutrizionale che decompressivo, contribuendo a migliorare l'efficacia della procedura antireflusso e a diminuirne le complicanze.

REGRESSIONE DELLA METAPLASIA DI BARRETT DOPO CORREZIONE CHIRURGICA DEL REFLUSO GASTROESOFAGEO CON TECNICA VIDEOLAPAROSCOPICA Nardi N., Garzi A., Cerigioni E, Abate V., Meucci D, Messina M., Università degli Studi di Siena, Dipartimento di Pediatria, Ostetricia e Medicina della Riproduzione, Sezione di Chirurgia Pediatrica, Direttore: Prof. Mario Messina

L'endobrachiesofago o epitelio di Barrett (EBE) è stato definito nel 1957, contemporaneamente da Lortat-Jacob e da Barrett; la maggior parte degli Autori definiscono l'EBE come una mucosa ghiandolare ectopica disposta circonferenzialmente e su almeno 3 cm di altezza, nella parte bassa dell'esofago al di sopra della giunzione anatomica esofago-gastrica. La presenza di EBE aumenta il rischio di degenerazione neoplastica della mucosa ghiandolare ectopica, sia in presenza di una disposizione circonferenziale o no, sia che misuri più o meno di 3 cm. Anche se in un numero ristretto di casi sembra essere di origine congenita, esso è, molto spesso, acquisito ed in rapporto con la malattia da reflusso gastroesofageo (MRGE). In età adulta la prevalenza di adenocarcinoma (ADK) insorto su di un esofago di Barrett varia dal 2.5% al 46% e l'incidenza, intesa come rischio di insorgenza di ADK durante il follow-up di pazienti portatori di EBE varia da 1/72 a 1/440 soggetti/anno. Il più importante fattore di rischio di comparsa di ADK è rappresentato dalla presenza di displasia nell'EBE; tuttavia, la classificazione delle displasie, nonchè la loro individuazione, è complessa e resta tuttora controversa.

Presso la Sezione di Chirurgia Pediatrica del Dipartimento di Pediatria, Ostetricia e Medicina della Riproduzione dell'Università degli Studi di Siena, negli ultimi due anni, due pazienti con MRGE ed EBE, diagnosticata mediante esame endoscopico, sono stati trattati mediante plastica antireflusso sec. Toupet in videolaparoscopia. L'impiego della chirurgia mininvasiva ha consentito di ridurre il trauma postoperatorio dei pazienti sia sul piano fisico che psicologico e di ridurre considerevolmente i tempi di degenza. Il follow-up a sei mesi ha dimostrato una normalizzazione dei parametri pH-metrici (score di DeMeester, AUH+) con regressione completa del reflusso gastroesofageo e della sintomatologia. Al follow-up ad un anno, un ulteriore esame endoscopico ha dimostrato la riduzione dell'ampiezza dell'area metaplasica di circa il 30%, rispetto al reperto preoperatorio. Al follow-up due anni, l' esame microscopico su prelievo endoscopico ha dimostrato la riduzione dell'ampiezza dell'area metaplasica di circa l'80%, rispetto al reperto preoperatoria.

Tali risultati suggeriscono che il trattamento precoce del RGE può creare i presupposti per una progressiva regressione dell'epitelio di Barrett; in aggiunta la possibilità di effettuare il trattamento chirurgico con tecnica mininvasiva consente di ottenere ottimi risultati anche in termini di riduzione del trauma postoperatorio e del tempo di degenza del paziente pediatrico.

16.30 CASI CLINICI
Modera: A. Settimi
Discussants: N. Pappalepore, M. Dòmini

RUOLO DELLA LAPAROSCOPIA NELLA DIAGNOSI DI FUSIONE SPLENOGONADICA: CASO CLINICO C. Noviello, A. Papparella, M. Romano, P. Parmeggiani. Seconda Università di Napoli, Istituto di Chirurgia Pediatrica, Dir. Prof. P. Parmeggiani

Introduzione: la fusione splenogonadica è una rara anomalia congenita nella quale la milza è connessa alla gonade. Questa malformazione è stata riportata per la prima volta nel 1883 da Boestrom (1). Ad oggi vi sono circa 150 casi descritti in letteratura. Si presenta per la maggior parte dei casi a sinistra (98%) e nei maschi (95%) (2, 3). Il reperto è stato descritto a tutte le età (3) e viene classificato in due tipi (fusione continua e discontinua) (4) che ricorrono con la stessa frequenza. Si associa frequentemente ad anomalie dello sviluppo facciali o degli arti. L'eziologia rimane sconosciuta, probabilmente la vicinanza tra le due strutture tra la 5° e 8° settimana di sviluppo embrionale è la causa del difetto. La presentazione clinica varia in base alla posizione della milza e della gonade.

Caso clinico: R. M., 6 anni, venuto alla nostra osservazione con una massa paratesticolare sinistra che presentava all'esame obiettivo le stesse caratteristiche parenchimatosa de testicolo senza apparenti connessioni con esso. Nessuna tara ereditaria. Non erano presenti altre malformazioni né altre patologie a carico dell'apparato uro-genitale. Il paziente viene sottoposto ad esame ecografico che evidenzia una struttura ovale ipoecogena di 12 x 6 mm, al di sotto del testicolo sinistro, che riproduceva la struttura del testicolo e presentava una propria vascolarizzazione come da gonade sopranumeraria. L'esame color doppler evidenziava una vascolarizzazione con presenza di piccola arteria polare associata a vena e con flusso sovrapponibile a quello delle arterie spermatiche.i dosaggi ormonali dimostravano normali valori di testosterone (1 ng/dl), alfa-fetoproteina (0,5 ng/ml) e beta-HCG (0,1 IU/ml). Il bambino veniva sottoposto a laparoscopia. L'esplorazione miniinvasiva, eseguita con approccio open trans ombelicale, evidenziava normale reperto a destra, mentre a sinistra l'anello inguinale interno appariva pervio con vasi e deferente normoposizionati e con una formazione, entrante nel canale, di aspetto parenchimatoso connessa alla milza da un asse vascolare. Previa pressione sull'emiscroto sinistro tale massa si evidenziava in addome insieme al testicolo cui era in stretta connessione. Si procedeva ad intervento chirurgico attraverso un'incisione inguinale sinistra, dopo isolamento degli elementi del funicolo spermatico, la formazione connessa al polo inferiore del testicolo veniva asportata ed inviata all'anatomopatologo. L'esame istologico ha riconosciuto tale formazione come milza accessoria per cui la diagnosi è stata di fusione splenogonadica di tipo discontinuo a sinistra.

Conclusioni: il caso clinico presentato mostra la superiorità della tecnica miniinvasiva rispetto alle altre indagini diagnostiche per immagini, infatti benché tutte avessero indirizzato la diagnosi verso un poliorchidismo solo la visione diretta dell'anello inguinale interno, resa possibile dall'esplorazione laparoscopica, ha consentito di diagnosticare il raro difetto congenito.

Bibliografia:

Boestrom E. Gellschaft deutscher Naturforscher und Artze Verhandlungen der 56 Versammlung, Freiburg. 1883; 149

Carragher AM. One hundred years of splenogonadal fusion. Urology 1990; 35:471-75

Diebold J, Le Blaye. Rate surnameraire intrascrotale. Un cas longtemps silencieus de fusion spleno-gonadique discontinue. Ann. Path. 1990; 10: 174-76

Putschar WGJ. Splenic-gonadal fusion: Am J Path. 1956; 32: 15-33

LAPAROSCOPIC JEJUNOSTOMY IN A CHILD WITH CHRONIC INTESTINAL PSEUDO-OBSTRUCTION

G. Li Voti Paediatric Surgery Unity – "Casa del Sole" Hospital – University Palermo

Objective of the study: chronic intestinal pseudo-obstruction (CIP) is a severe condition characterized by recurrent symptoms of bowel obstruction, in the absence of lumen-occluding lesions. Because of motility disorders, since neonatal age these children show failure to thrive,vomiting, constipation and malnutrition. Long term enteral nutritional support, by gastrostomy or jejunostomy, appears the gold treatment. We performed a laparoscopy-assisted jejunostomy in a patient with CIP. Our technique is described and results discussed.

Methods and procedures: a 14 years old male child, affected by CIP, was admitted to our Unity with severe malnutrition. He had undergone, two years before, a duodeno-jejunal anastomosis because of a diagnosis of duodenal compression by superior mesenteric artery. He had no improovement from this operation. Xray study demonstrated a persistent Gastroparesis. A short term trial of nasojejunal feeding was effective in weight gain. Because of the special anatomical pattern determined from the previous operation we performed a laparoscopy-assisted jejunostomy and inserted a mic key button for feeding.

A 5 mm laparoscopic camera port was placed through the umbilicus, by an open access. Two further 5 mm ports were placed in the left lower quadrant and in the cross-point of umbilical transverse line and left breast midline.The camera was moved to the inferior port site. Avoiding adhesions we managed to find the first jejunal loop. A bowel segment, approximately 10 cm distal to the ligament of Treitz, was softly grasped and brought up to the abdominal wall at the left upper port site. Bowel was secured to abdominal wall by few unabsorbable sutures and minimally ostomy was done in order to insert a the jejunostomy button. We correct position of the botton was checked by laparoscopy.Enteral nutrition restarted via nasojejunal tube 3 days postoperatively and via jejunostomy 8 days later. We observed no intraoperative complications or difficulties because of previous surgery adhesions.

Conclusions: laparoscopy-assisted jejunostomy is a safe and effective procedure to achieving enteral access in patients with CIP.

CISTI SPLENICA IN WANDERING SPLEEN: TRATTAMENTO LAPAROSCOPICO Falchetti D, Torri F, Dughi S *, Porto C §, Benvenuti S, Manciana A, Cappellaro E, Ekema G., Department of Pediatric Surgery, Spedali Civili
* Unit of Pediatric Radiology, Spedali Civili
§ Department of Anaesthesiology, Spedali Civili

Il lavoro descrive il trattamento laparoscopico di una insolita e complessa patologia della milza: una cisti splenica (CS) in una wandering spleen (WS)

Una ragazza di 14 anni, amante delle arti marziali, venne alla nostra osservazione per una massa addominale in fossa iliaca sinistra. Gli accertamenti consentirono di porre diagnosi di WS contenente una CS non parassitaria.

La strategia di trattamento fu conservativa, con il programma di evitare la splenectomia e di ripristinare sia l'anatomia che la posizione della milza. Attraverso 4 accessi venne eseguita una cistectomia subtotale con ampia decapsulazione della cisti, quindi la milza aperta venne avvolta da una rete di vycril che fu fissata alla parete addominale in ipocondrio sinistro, in seguito ricoperta da una tasca di omento.

Non vi furono problemi durante né dopo l'intervento, e dalla dimissione la ragazza ha potuto riprendere tutte le abituali attività senza restrizioni. I controlli ecografici eseguiti durante un follow-up di 6 mesi hanno sempre confermato la corretta posizione della milza, deforme per la pregressa cavità al suo interno, senza segni di recidiva della cisti.

La CS e la WS sono condizioni congenite benigne ma entrambe possono causare gravi complicanze vascolari; sotto questo punto di vista la loro associazione può aggravare i rischi di torsione ed è quindi potenzialmente ancora più pericolosa. La nostra esperienza dimostra, per la prima volta, che tale insolita e complessa patologia splenica è trattabile per via laparoscopica senza il sacrificio della milza.

TRATTAMENTO VIDEOASSISTITO DI NEOFORMAZIONI CISTICHE NON OVARICHE. ESPERIENZA IN 3 CASI

A. Porreca, C. Terracciano, A. Tramontano

Divisione di Chirurgia Pediatrica e Pronto Soccorso, A.O. Santobono-Pausilipon, Napoli

Viene riportato il trattamento laparoscopico di una cisti mesenterica, una cisti omentale ed una cisti retroperitoneale.

La cisti omentale, di notevoli dimensioni, è stata estrinsecata intatta attraverso l'ombelico e d escissa in toto. La cisti mesenterica è stata aspirata ed estrinsecata con l'ansa ileale attraverso l'ombelico, è stata quindi asportata con un breve tratto di intestino.

La cisti retroperitoneale, adesa all'emidiaframma destro, è stata escissa in laparoscopia. Nel corso della rimozione si è creata una soluzione di continuo del diaframma che ne ha richiesto la sutura.

Il follow-up, variabile da tre ad un anno non ha evidenziato recidive.

RISOLUZIONE LAPAROSCOPICA DI UNA COMPLICANZA DI UNA COMPLICANZA IN CHIRURGIA A CIELO APERTO

Ciro Esposito2, Francesca Alicchio1, Aurelie Chiappinelli1, Antonella Centonze2, Rossana Tucciarelli2, Alessandro Settimi1
1- Cattedra di Chirurgia Pediatrica, Università di Napoli "Federico II"
2 -Cattedra di Chirurgia Pediatrica, Università di Catanzaro "Magna Grecia"

Generalmente quando si parla di "conversione" s'intende il passaggio da una procedura laparoscopica ad una di chirurgia open, per risolvere complicanze occorse durante la laparoscopia. In questo lavoro, riportiamo il caso di una conversione da una procedura open ad una laparoscopica per trattare una complicanza vascolare occorsa durante un'orchiectomia per via tradizionale. Un bambino di 2 anni , giunto alla nostra osservazione per una cripotorchidia dx, presentava all'E.O. un testicolo dx palpabile al III medio del canale inguinale, ipotrofico, reperto confermato anche dall'ecografia. Uno dei nostri A.I.F. eseguì una orchiectomia per via open con approccio inguinale . Dopo la rimozione del testicolo e prima di legare i vasi spermatici interni a livello dell'anello inguinale interno, il klamp che teneva i vasi fu innavertitamente aperto, causando la retrazione dei vasi spermatici. Risultando difficile identificare i vasi ed effettuare l'emostasi per via inguinale, si decise di effettuare una laparoscopia. Si inserì un trocar ombelicale di 10-mm con un'ottica di 0° e si evidenziò un ampio ematoma retroperitoneale lungo i vasi spermatici interni ed il deferente, a circa 3-4 cm dall'anello inguinale interno. Si posizionarono quindi due trocars da 5-mm in triangolazione con quello ombelicale; l'emostasi fu effettuata posizionando clips sui vasi, a livello dell'anello inguinale interno e prossimalmente all'ematoma. La durata del primo tempo chirurgico è stata di un'ora, quella della laparoscopia di 25 min. Il bambino è stato dimesso due giorni dopo l'intervento. Al follow-up di 9 mesi l'aspetto, clinico ed ecografico, era normale. Questo caso mostra chiaramente l'utilità della laparoscopia nella chirurgia pediatrica, anche per risolvere le complicanze di un intervento a cielo aperto.

TRATTAMENTO VIDEOASSISTITO DI CORPI ESTRANEI INSOLITI

A. Porreca C. Terracciano, R. Campanile, A. Tramontano, Divisione di Chirurgia Pediatrica e Pronto Soccorso, A. O. Santobono-Pausilipon, Napoli

Vengono riportati due casi di ingestione ed uno di inalazione di corpi estranei trattati con tecnica videoassistita.

Sette segmenti metallici calamitati erano stati ingeriti da una bambina di 3 anni. La asportazione endoscopica si è giovata della collaborazione di una pinza da presa laparoscopica che ha spinto nello stomaco i frammenti che avevano superato il piloro.

Un frammento di ferula da apparecchio ortodontico aveva perforato l'ileo di un ragazzo di 14 anni. Il frammento lungo circa 2cm ancora parzialmente infisso nell'intestino è stato rimosso in laparoscopia e la perforazione suturata.

Uno spillo è stato inalato da un bambino artistico di 7 anni. Alla broncoscopia non è stato possibile asportare il corpo estraneo che ad un mese dell'inalazione era situato molto perifericamente nel parenchima polmonare. Alla toracoscopia lo spillo è stato agevolmente individuato

ed asportato.

TRATTAMENTO LAPAROSCOPICO DI CISTI EPATICA SEMPLICE: CASO CLINICO. G. Cobellis, A. Cruccetti, L. Mastroianni, A. Martino, S.C. di Chirurgia Pediatrica - A.O.U. - Ospedali Riuniti - Presidio Materno Infantile "G. Salesi"

Il trattamento delle cisti epatiche semplici è ancora controverso. In un bambino di 7 anni viene riscontrata ad un'ecografia addominale una formazione anecogena a carico del lobo destro del fegato, rotondeggiante, di 6 cm di diametro, priva di caratteristiche riferibili a cisti da echinococco con restante parenchima epatico regolare. Vengono effettuati i markers tumorali e gli anticorpi anti echinococco, che risultano negativi. La risonanza magnetica dell'addome mostra formazione rotondeggiante del diametro traverso di circa 6 cm, a carico del VII ed VIII segmento epatico, a contorni regolari, a parete virtuale, priva di sedimentazioni o formazioni aggettanti nel suo lume; la formazione si presenta ipointensa nelle immagini T1 e spiccatamente ed omogeneamente iperintensa nelle sequenze T2. Viene posta la diagnosi di cisti epatica semplice e per le cospicue dimensioni e la localizzazione superficiale si decide per il trattamento chirurgico laparoscopico. Il bambino viene sottoposto a fenestrazione della cisti per via laparoscopica: viene effettuata un'incisione intraombelicale con introduzione di trocar di Hasson da 10 mm ed induzione del pneumoperitoneo fino 12 mmHg; a livello dell'VIII segmento si rileva formazione cistica; l'aspirazione della cisti per via percutanea sotto visione laparoscopica dà esito a liquido limpido. Dopo l'introduzione di 2 trocar da 5 mm, in sede epigastrica ed al quadrante superiore destro, si sospende la parete della cisti con punto transfisso transparietale e si procede all'asportazione del tetto della cisti ai limiti del parenchima epatico con uncino monopolare. Non si sono verificate complicanze intra-operatorie e post-operatorie. Il drenaggio è stato rimosso in 3a giornata ed il bambino dimesso in 5a giornata post-operatoria. La fenestrazione laparoscopica delle cisti epatiche semplici, a localizzazione superficiale, anche nei segmenti meno accessibili è agevolmente fattibile, tanto da poter rappresentare il trattamento di scelta.

1. Weber T, Sendt W, Scheele J.

Laparoscopic unroofing of nonparasitic liver cysts within segments VII and VIII: technical considerations.

J Laparoendosc Adv Surg Tech A. 2004 Feb;14(1):37-42

2. Zalaba Z, Tihanyi TF, Winternitz T, Nehez L, Flautner L.

The laparoscopic treatment of non-parasitic liver cysts. Five years experience.

Acta Chir Hung. 1999;38(2):221-3.

SURGICAL TREATMENT OF THORACO-ABDOMINAL TERATOMA DIAGNOSED IN UTERO, APPROACHED WITH MINI-INVASIVE TECHNIQUE: A CASE REPORT G.Monguzzi; E.Leva; A.Pansini;Dept. of Pediatric Surgery Children's Hospital of Milan, Italy , Chief: Dott. L. Pansini

Introduction: thoracic tumours of childhood arise either in the mediastinum, or from the chest wall and rarely from the lung parenchyma. Mediastinal teratoma occur in the anterior mediastinum and are usually very large at presentation; initial treatment is under discussion, but it appears that surgical excision and histological examination are the treatments of choice and it will determine whether the lesion is benign or malignant.

Material: authors report a case of thoracic-abdominal teratoma, diagnosed in utero, and treated successfully with thoracoscopy and laparoscopy. No complication was described in short follow up, and the child was discharged in day 8th post op.

Result: histology showed mature teratoma.

Follow up at 1 year: no evidence of recurrence.

Discussion: due to the rarity of multifocal teratoma in newborns, author believe that mini-invasive technique was useful to stage histological the mass, giving the opportunity to plans a second stage in treatment of the patient. Day of hospitalisation resulted shorter in both surgical approaches, and discomfort less for the thoracic approach.

This staging must be anyway planned, in the way of prenatal counselling and in the perinatal period, with the team involved in the procedure, that include anaesthetists, oncology staff, obstetricians, neonatologists and pediatric surgeons.

S001

VIDEO-ASSISTED THORACOSCOPY FOR DIAPHRAGMATIC PLICATION. EXPERIMENTAL STUDY IN A CANINE MODEL, José F González-Zamora MSc, Fernando Villegas-Alvarez MD,Beatriz Pérez-Guillé MSc,Rosa E Soriano-Rosales MSc,Miguel A Jiménez-Bravo-Luna MD,Pedro Gutiérrez-Castrellón MSc, Instituto Nacional de Pediatría ? SSA, Universidad Nacional Autónoma de México

Background: Plication of a non-functional hemidiaphragm usually restitutes altered ventilatory mechanics; the surgical procedure may be performed through diverse techniques. The aim of this experiment was to compare two techniques in performing diaphragmatic plication (DP): video-assisted thoracoscopy (A) vs. thoracotomy (B). Methods: twenty dogs with right hemidiaphragm induced paralysis were included and randomly assigned to one of the two maneuvers. Evaluations were performed before and after plication according to respiratory frequency (f) and lung area (LA) of the affected side. Time required for surgery and period for resumption of walking, solid food and fluid ingestion, pain intensity and postoperative complications were measured. Results: Group A presented less pain in after the surgery ($p< 0.0001$), fluid ingestion was faster ($p<0.05$) and resumption of walking was earlier ($p<0.019$). Four weeks after the procedures, similar LA was observed in both groups, while a significant decrease in f was recorded in group A ($p<0.02$). The remaining evaluated variables showed no differences. Conclusions: Both approaches were effective. Pain recorded in the postoperative period was less and recovery was faster in the group A. Complications and surgical times were similar. The video-assisted thoracoscopy is a safe and efficient option to perform a DP in dogs.

S002

CO2 ALTERS THE INFLAMMATORY RESPONSE OF MACROPHAGES: ALTERATIONS OF THE CYTOKINE AND SUPEROXYDE ANION RELEASE AND INSIGHTS IN THE UNDERLYING MECHANISM., J F Kuebler MD, M Kos MD,R Busche PhD,N K Jesch MD,N M Bax MD,D C van der Zee MD,G Vieten PhD,B M Ure MD, Medical University of Hannover

Aim: Beneficial effects of laparoscopic surgery are related to a modulation of macrophage functions by CO2 pneumoperitoneum. The alterations of the inflammatory response of macrophages have been attributed to cellular acidification, direct effects of CO2 and/or lack of air contamination. We aimed to describe the effects of CO2 on the inflammatory response of macrophages to LPS and to investigate the mechanism of CO2 action.
Methods: Two rat macrophage cell lines were used (R2 and NR 8383) in 3 sets of experiments: 1. Incubation in 100% CO2, 5% CO2, and room air for 2h. 2. Incubation in extracellular pH 7.4, 6.5 and 5.5 for 2h in 5%CO2. 3. Incubation in 100% CO2, 5% CO2 and room air in fixed ph 6.5. The release of IL-6 (ELISA) and NO (Griess reaction) after LPS stimulation, mitochondrial activity (MTT conversion assay) and vitality (trypan blue) were determined. In NR 8383 cells the release of superoxide anions was also measured. In separate experiments, the extracellular pH was monitored during incubation. Moreover, using fluorescence microscopy we determined the alteration of intracellular pH in cells subjected to extracellular acidification.
Main Results: The extracellular pH decreased to 6.3 during 100% CO2 incubation. Incubation in CO2, or but not room air significantly altered the release of IL-6. This effect was mimicked by incubation in pH 6.5 and blocked if the extracellular pH change during incubation was inhibited. CO2 incubation decreased superoxide anion release only directly following the incubation. Only severe acidification (pH 5.5) affected this parameter. We observed no significant alteration in vitality, but reversible inhibition of mitochondrial activity during and following incubation in CO2 or acidic pH. Intracellular pH decreased rapidly during incubation in acidic medium, with no difference between the cell lines.
Conclusion: CO2 incubation selectively modulates the cytokine release of macrophages following a subsequent stimulation. This alterations is triggered by the change of the extracellular pH and correlates with changes in mitochondrial acitivity. The free radical production is reduced only directly after incubation and no effects on the NO release were observed. Thus, alteration of the extracellular pH during CO2 incubation triggers a selective modulation of macrophage functions which could help to understand the improved inflammatory response following laparoscopic surgery.

S003

PNEUMOPERITONEUM TOLERANCE DURING LAPAROSCOPIC PYLORIC STENOSIS CURE: A PROSPECTIVE RANDOMIZED CONTROLED TRIAL, Guillaume Podevin MD, Corine Lejus MD,Marc David Leclair MD,Valérie Plattner MD,Yves Heloury MD, Pediatric Surgery Department. Hôpital Mère-Enfant. NANTES. FRANCE.

Purpose: Laparoscopy has been proposed for the surgical treatment of hypertrophic pyloric stenosis. We conducted a prospective randomised study to compare laparoscopy (LC) to laparotomy (OL). We have recently demonstrated (IPEG 2004) that LC does not improve postoperative recovery (vomiting and pain). The purpose of this second step was to compare hemodynamic and respiratory tolerance of both surgical techniques.
Methods: 102 infants [age = 34 (26, 42) days] were included after ethical Committee and parental written informed consent. Preoperative management, crush induction and maintenance of anaesthesia were standardized in both groups. Heart rate, mean arterial pressure, pulse oxymetry (SpO2) and end tidal CO2 were analysed every 3 mn. Data were expressed as medians (25-75 %) and compared with non-parametric tests.
Results: Demographic data were similar in both groups. Operative time was longer in LC group [29 (24 - 35) mn] than in the OL group [24 (21 - 28) mn]. Median time of pneumoperitoneum at 7 mmHg was 17 (12-20) mn with a maximal increase of 4 (2 - 6) mmHg for CO2. Selective tracheal intubation occurred during pneumoperitoneum in one case. Incidence of hypotension and heart rate variations were not different between groups. Mean arterial pressure was slightly higher at time of closure in LC [41 (37, 46)] than in LP [38 (31, 43 mmHg] group ($p < 0.05$). Incidence of infants with at least one SpO2 measure less than 95 % was higher in LC group. During peritoneum, respectively 25, 7 and 2 % of infants had at least one SpO2 measure respectively between 95 and 90 %, 90 and 85 % or below 85 %.
Conclusion: Laparoscopy for pyloric stenosis seems hemodynamically well tolerated but is associated with a higher incidence of peroperative hypoxemia than laparotomy, without benefit for surgical outcome. Then, open laparotomy should be preferred for standard cases.

S004

MINIMAL INVASIVE FLUORESCENCE DIAGNOSIS: LAPAROSCOPIC DETECTION OF PERITONEAL METASTASES FROM HUMAN HEPATOBLASTOMA IN NUDE RATS, Holger K Till MD, Florian Bergmann MD,Dietrich von Schweinitz MD,Ruediger Prosst, The Chinese University of Hong Kong

Aim: Since the introduction of modern photo sensitizers like 5-amino-levulinic acid (ALA), fluorescence diagnosis (FD) is gaining clinical importance for the detection of malignancies in various medical disciplines. Basically the technique relies on the specific metabolic capacity of a lesion to metabolize a photosensitiser like ALA into a fluorescent compound like protoporphyrin IX (PpIX), which illuminates red, in a blue excitation light (375 to 440 nm). Today it is still unknown, whether pediatric tumors like hepatoblastoma (HB) respond to ALA-FD during laparoscopy.
Methods: Step 1 (in-vitro): Human hepatoblastoma cells (HuH6) were cultured in RPMI-1640 medium (10% FCS, 37°C, 5% CO2) and incubated with ALA to asses illumination characteristics during fluorescence microscopy.
Step 2 (in-vivo): HuH6 cells (3x106) were laparoscopically injected (4mm scope, 18G needle) underneath the peritoneum of 7 nude rats (mean weight 198g). Tumor growth was allowed for 7 weeks. Then photosensitization was induced by peritoneal lavage with ALA (4ml, 3%). After 3 hours the animals were investigated by white light laparoscopy (WL) and laparoscopic fluorescence diagnosis (LFD), applying the Storz PDD-system. Suspicious lesions were harvested for spectrometry (SM) and histology.
Results: Step 1: HuH6 demonstrated specific fluorescence for PpIX.
Step 2: During laparoscopy, every tumor seen in WL also illuminated during LFD (100%). Especially one micro metastasis, almost invisible in WL was revealed in LFD (video). SM of tumors depicted the specific peak of PpIX at 635 nm and a 6,34 fold increase of the fluorescence intensity. Histology showed HB in all specimens. Conclusion: Human HB can be detected by ALA-induced LFD in a rat model. Considering the success of ALA-FD in other medical fields, this finding opens a promising spectrum of further investigations to evaluate the impact of FD for pediatric oncology.

S005

IMPACT OF CARBON DIOXIDE VERSUS AIR PNEUMOPERITONEUM ON NEUTROPHIL RECRUITMENT AND APOPTOSIS, Ueli Moehrlen MD, Urs Ziegler PhD,Eva Boneberg PhD,Ernst Reichmann PhD,Martin Meuli MD,Juerg Hamacher MD, Dept. of Pediatric Surgery, University Children's Hospital Zurich, Switzerland

Introduction - Local immune function is impaired after abdominal surgery. Minimally invasive abdominal surgery seems to better preserve the local immune function than open abdominal surgery. We recently demonstrated that the spontaneous peritoneal macrophage's ex vivo- TNF-alpha release was lower when CO2 rather than air was used for insufflation. We therefore aimed to compare both neutrophil (PMN) recruitment and apoptosis under those conditions. Methods and Procedures - Female mice (30±4g) were randomly assigned to a CO2 insufflation, air insufflation and the control group (anaesthesia only). Intravasal cells with phagocytic capabilities were selectively stained by i.v. injection of the fluorescent dye PKH26 24h before surgery. Gas was insufflated into the peritoneal cavity through a catheter and the pneumoperitoneum was maintained for 30 min. Peritoneal lavage was performed 1, 3, 8 or 24h after surgery. Cells were assessed by flow cytometry, using D2R- Rhodamine as an apoptosis marker reflecting caspase activity. Results - The count of PMN differed significantly over time (p=0.015) and between the CO2 insufflation, air insufflation, and the control group (p=0.0004; see graph 1). The ratio of PKH26 positive PMN was significantly lower after CO2 insufflation compared to air insufflation (p=0.03; see graph 2). The caspase activity of PMN was doubled at each point of time after CO2 insufflation compared to air insufflation (p=0.015).

Conclusions - In the peritoneal cavity, recruitment, migration and survival of PMN after CO2 insufflation is less than after air insufflation. This result is in line with other findings that CO2 leads to a moderate, and potentially more appropriate immune stimulation in the context of minimally invasive surgery.

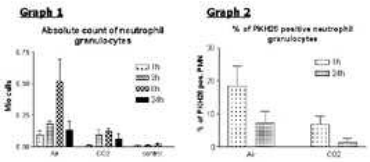

S006

THE ADDITION OF O2 TO THE CO2 DOES NOT PREVENT THE SYSTEMIC EFFECTS OF THE CO2-PNEUMOPERITONEUM IN A RABBIT MODEL, Suzi DEMIRBAG MD, Narter YESILDAGLAR MD,Ilhami SURER MD,Haluk OZTURK MD,Salih CETINKURSUN MD, *Department of Pediatric Surgery and *Research Centre of Gulhane Military Medical Academy, Ankara, Turkey

BACKGROUND: CO2-pneumoperitoneum used in endoscopic surgery induces systemic effects by CO2 absorption. It was claimed that a reduction in CO2-pneumoperitoneum-induced metabolic hypoxaemia was achieved by the addition of small amounts of O2 to the CO2 in a rabbit ventilated model. We re-evaluated the effects of the addition of O2 to the CO2-pneumoperitoneum upon CO2 absorption in a rabbit model. METHODS: The effects of a pneumoperitoneum using 100% CO2, 90% CO2 + 10% O2, 95% CO2 + 5% O2 or 100% O2 upon arterial blood gases, acid base and O2 homeostasis were evaluated in non-intubated rabbits. A pneumoperitoneum pressure of 10 cmH2O (approximately 7.35 mmHg) was used. RESULTS: CO2-pneumoperitoneum of 120 minutes affected blood gases and acid base homeostasis. While partial pressure of CO2 and HCO3 increased ($P < 0.001$) during pneumoperitoneum, pH and partial pressure of O2 decreased ($P < 0.001$). Similar results were obtained in O2-CO2-pneumoperitoneum ($P > 0.05$). CONCLUSION: CO2-pneumoperitoneum profoundly affected blood gases and acid base homeostasis resulting in metabolic hypoxaemia. The addition of O2 to the CO2 did not prevent the systemic effects of CO2-pneumoperitoneum.

S007

LAPAROSCOPY BUT NOT FULL- AND MINI-LAPAROTOMY PRESERVES HEPATIC AND CIRCULATORY MACROPHAGE RESPONSE IN A RAT MODEL, Natalie K Jesch MD,Gertrud Vieten PhD, Joachim F Kuebler MD, Thomas Tschernig PhD,Benno M Ure MD, Department of Pediatric Surgery and Department of Functional and Applied Anatomy, Hannover Medical School, Hannover, Germany

Introduction: The aim was to investigate peritoneal, hepatic, and systemic monocyte/macrophage responses to mini- vs. full laparotomy vs. laparoscopy.
Methods and Procedures: Male Lewis rats (250g) received a central venous catheter and were randomized into four groups (each n=6): anesthesia, mini-laparotomy (1cm), full laparotomy (7cm), or laparoscopy for 60min. Blood was collected at 6h and 24h. Endpoints were: 1. production of nitric oxide and superoxide anions by peritoneal macrophages and blood monocytes, 2. IL-6 in plasma at 6h, 3. ED-1 for recruited monocytes, ED-2 for Kupffer cells, and OX-6 for macrophage activation in the liver,
Results: The release of nitric oxide by peritoneal macrophages was enhanced significantly after full laparotomy and laparoscopy. The release of superoxide anions by monocytes was significantly elevated after mini-laparotomy and full laparotomy compared to laparoscopy. Only full laparotomy significantly increased plasma levels of IL-6. Only full laparotomy caused a significant enhancement in hepatic ED-1-positive monocytes. Mini-laparotomy and full laparotomy led to a significant increase in ED-2-positive Kupffer cells. Laparoscopy did not alter the number of monocytes/macrophages in the liver. Expression of OX-6 was not stimulated in either group. No change in the cellular composition of the periportal fields was observed.
Conclusions: Peritoneal macrophage responses are similar after laparoscopy and laparotomy. In the liver, laparoscopy, in contrast to mini-laparotomy and full laparotomy, prevents the hepatic macrophage population from expanding and preserves a normal cell distribution. The regulating hepatic pathway to surgery differs from other immunologic challenges, i.e. sepsis, which causes cell accumulation and stimulation in the periportal fields. Systemically, the immune function is preserved better after laparoscopy, irrespective of the incision size of laparotomy.

S008

IMPACT OF MINIMAL INVASIVE SURGERY ON ACUTE PHASE RESPONSE AND RISK OF INFECTIOUS COMPLICATIONS IN PAEDIATRIC PATIENTS., Mariano Barbalace MD, Gordon A MacKinlay MD,Giovanna Riccipetitoni MD, Madonna della Consolazione? Policlini Hospital, Reggio Calabria - Italy

Introduction: Open Laparotomy is followed by changes in defence mechanisms which may be important for the development of post-operative infections. Laparoscopic surgery is believed to lessen surgical trauma and cause less distress on immune function. The mechanisms which permits to laparoscopic surgery to be associated with reduced post-operative complications, are unclear. In adults laparoscopic surgery appears to be associated with similar metabolic responses compared with open surgery. On the other hand there is a great variability of immune properties between both groups. In the paediatric population the data available are poor. Abnormal release of inflammatory mediators, following surgical injury, is associated with immunological changes which may predispose to sepsis. Aim of our study is to determine the peri-operative IL-1, IL-6, TNF and CRP level in children undergoing minimal invasive surgery compared with open surgery.
Methods and Procedures: Sixty patients with a mean age of 9.9 ± 2.99 years agreed to enter the study and were prospectively investigated. Twenty-five (group I) of them were submitted to both laparoscopic and retroperitoneoscopic procedures and twenty-five (group II) underwent open surgical operations. A blood sample (2ml) was taken just before induction (T0), at the end of the procedure (T1) and day 1 post-operative (T2). Plasma was obtained by centrifugation and kept frozen until required for essay. To determine the acute phase response IL-1, IL-6, TNF and CRP levels were investigated and compared among groups.
Results: Comparing the two groups of patients in the post-operative period (T1-T2) the plasma level of TNF ranged 192 ± 99 pg/ml and 271 ± 99 respectively in the group I versus 280 ± 99 and 422 ± 99 in the group II; IL-1: 188 ± 99 pg/ml and 244,7 ± 99 versus 301 ± 99 and 404 ± 99; IL-6: 194 ± 99 pg/ml and 205,11 ± 99 in group I versus 295 ± 99 and 322 ± 99 in the group II respectively and CRP: 51 ± 20 mg/ml and 78 ± 99 in the group I versus 220 ± 99 and 288 ± 99 in the group II.
Conclusions: These values were higher in both groups, but significantly lower in the patients in group I. Laparoscopy in children seems to cause less surgical trauma and so less immunological changes. This results in a decreased incidence of infectious complications. These preliminary data

could explain the better post-operative results in terms of recovery, also indicate an additional benefit of much reduced post operative pain.

S009

HOW RELIABLE IS YOUR LAPAROSCOPIC KNOT TYING?, Pedro-Jose Lopez* MD, John Vesses° BS,Andrew Wojcik° BS,Joe Curry* MD, Paediatric Surgery * and Biomedical Engineering Department°, Great Ormond Street Hospital and University College of London, London

INTRODUCTION: The skills for laparoscopic knot tying take time and patience to acquire. Once a surgeon is happy he or she has mastered the technique, what proof does the surgeon have that the knots they have tied are as reliable as those performed in open surgery? The aim of our study was to try to answer this question.
METHOD: Using a standardised knotting technique, one senior laparoscopic consultant surgeon (JC) tied three different suture materials (Vicryl?, Prolene?, Ethilon?) using 3 methods of knotting; hand, instrument (needle holder) and laparoscopic (5mm laparoscopic instruments and camera in a training box). The tension produced in the knots was measured using a custom made electronic tension gauge at both the time of knotting and five minutes after. The surgeon was blinded to the value of the tension. The experiment was repeated 4 times. The 36 sutures were then analysed using a Hounsfield H5K-S materials testing machine, until they broke. The maximum force achieved prior to breakage, the maximum extension and the breaking points were recorded. The scientist was blinded as to the method of tying and tensions produced. Data was analysed using Graphpad Prism? software.
RESULTS: The greatest fall in suture tension at five minutes was seen with Prolene although this was not statistically significant (p= 0.49). There was no significant difference in tension at five minutes with the other suture materials or method of knot tying.
On strain testing the final mean extension achieved prior to breakage for 33 sutures was 29.71 mm (19.3-43.9) with a final force of 16.09 Newtons (range 11.18-21.33). In the other 3 sutures the knot slipped completely while tension was being increased, thus no measure of breakage force could be obtained. These 3 sutures were all monofilament and were all tied laparoscopically.
CONCLUSION: There were no significant changes in suture tension after five minutes regardless of material or method of knot tying. 3 of the 12 knots tied laparoscopically (25%) came undone under strain testing. These 3 knots were all monofilament suture. This may have important implications for the laparoscopic surgeon when choosing suture material. Further studies are planned to expand the analysis of different knotting techniques with different suture materials to establish safe criteria for knots tied laparoscopically.

S010

THE EFFECT OF ORAL INSULIN ON INTESTINAL RECOVERY FOLLOWING ISCHEMIA-REPERFUSION INJURY IN RAT, Igor Sukhotnik MD,Eitan Shiloni MD,Naim Shehadeh MD,Raanan Shamir MD,Habib Helou MD, Jorge G Mogilner MD, Rappaport Faculty of Medicine, Technion, Dept of Pediatric Surgery, Bnai Zion Medical Center, Dept of Surgery Carmel Medical Center, Dept of Pediatrics and Pediatric Gastroenterology, Meyer Children's Hospital, Rambam Medical Center Haifa, Israel

Background. It has been reported that oral insulin has a trophic effect on intestinal mucosa, but the precise mechanism of its action is still unclear. The purpose of the present study was to investigate the effect of oral insulin on ischemia and reperfusion (IR) intestinal mucosal injury in rat.
Materials and methods. Male Sprague-Dawley rats underwent laparotomy (Sham) or IR-intestinal damage by clamping both the superior mesenteric artery and the portal vein for 30 min followed by 24 hours reperfusion. IR-INS rats were treated with oral insulin given in drinking water (1U/ml) 48 hours before and following IR. Intestinal structural changes, enterocyte proliferation and enterocyte apoptosis were determined 24 hours following IR. Park's score was used for the quantitative assessment of histological change. A non-parametric Kruskal-Wallis ANOVA test was used for statistical analysis with P less than 0.05 considered statistically significant.
Results. IR- injury resulted in a significant decrease in bowel weight in duodenum and jejunum, mucosal weight in jejunum and ileum, villus height in jejunum and ileum, cell proliferation index in jejunum and ileum compared to sham animals. IR-INS animals demonstrated greater duodenal and jejunal bowel weight, duodenal, jejunal and ileal mucosal weight, jejunal mucosal DNA, jejunal and ileal mucosal protein, jejunal and ileal villus height and crypt depth, jejunal and ileal proliferation index compared to IR-animals. Oral insulin administration induced also a significant decrease in apoptotic index in ileum (1.2±0.4 vs 2.8±0.7 TUNEL positive cells/10 villi, $p<0.05$) compared to IR-untreated animals.
Conclusions. Oral insulin improves intestinal recovery following IR- injury in rat.

S011

CELL INJECTION: A NEW APPROACH FOR THE TREATMENT OF GASTROESOPHAGEAL REFLUX. PRELIMINARY EXPERIENCE IN ANIMALS., Paolo De Coppi MD, Francesco Fascetti Leon MD, Luisa Boldrin,Alberto Malerba MD,Pietro Betalli MD,Giovanni F Zanon MD,Libero Viteillo MD,Piergiorgio Gamba MD, University of Padoua, Italy-*Division of Pediatric Surgery, § Institute of Biological

OBJECTIVE:Promising endoscopic therapies for gastroesophageal reflux disease (GERD), including suturing and stapling techniques and injections of inert implantable materials, are emerging in both clinical practice and clinical investigations. However, there are still some disadvantages due to the poor long term results.
We describe in experimental animals the possibility of stem cell injections for improving of sphinteric function.
METHODS: Following this propose, we have isolated single muscle fibres with associated satellite cells according to the procedure described previously by Rosenblatt et al. The flexor digitorum brevis (FDB) muscles of the hind feet of adult GFP positive mice were carefully removed from tendon to tendon with the help of surgical microscope to avoid damage to the fibres. Then single muscle fibres, obtained with enzymatic digestion, were plated in Petri dishes coated with matrigel. Consequently, we cultured in vitro satellite cells to obtain a great number of myogenic precursors that were injected intramusclarly in the gastroesophageal junction after laparotomy. At different time points the animals have been sacrificed and serial sections of the gastroesophageal junction have been analyzed at the fluorescence microscope.
RESULTS: All the animals survived with no significant complications. Histological examination of the gastroesophageal region demonstrated new muscle formation without evidence of inflammation and/or fibrosis.
CONCLUSIONS: Autologous satellite cells can be readily harvested, expanded in vitro and injected in the gastroesophageal junction. This system could be a good option for the treatment of gastroesophageal reflux.

S012

NOVEL BLADDER TISSUE ENGINEERING WITH STEM CELLS IMPROVES MORPHOLOGIC AND MOLECULAR COMPOSITION OF RECONSTITUTED BLADDERS, Steve Y Chung MD, Nikola P Krivorov MD,Veronica Rausei MD,Christopher S Ng MD,Gerhard J Fuchs, Cedars-Sinai Medical Center

Purpose: Tissue engineering has been used for bladder augmentations with small intestinal submucosa (SIS). Although favorable short-term outcomes have been reported, long-term followup in porcine models has been poor. Recently, SIS seeded with smooth muscle and urothelial cells has shown favorable results. We investigate whether tissue engineering with stem cells improves morphologic and genetic composition.
Materials and Methods: Thirty-three Lewis rats were used to investigate bladder augmentations with SIS in the following groups: control (CG, sham operation), partial cystectomy with oversewn defect (OG), augmentation with unseeded SIS (USG), and augmentation with stem cell seeded SIS (SSG). Bladders from 4 rats in each group were harvested at 1 and 3 month(s) post-surgery. Morphologic analyses were performed using Masson trichrome and immunohistochemical staining (cytokeratin AE1/AE3, smooth muscle ¥á-actin, S100), and gene expression was evaluated using quantitative real-time reverse transcriptase-polymerase chain reaction (RT-PCR) for collagens I and III, cytokeratins 8 and 19, and smooth muscle myosin heavy chain (MHC).
Results: At 1 month post-surgery, Masson trichrome staining revealed collagen admixed with indiscrete cells and morphology similar to controls in USG and SSG groups, respectively. Discrete smooth muscles fascicles and S100 staining were found in all groups except in USG. Organized urothelium with increased basal cell layer staining was present in controls and SSG only. At 3 months followup, trichrome staining showed increased collagen formation in both OG and USG. Immunostaining showed hyperplasia of the urothelium with increased staining of the basal cell layer, discrete muscle fascicles, and positive nerve staining in all groups. Using quantitative RT-PCR, expression levels in SSG were more improved than USG, especially for collagens I and III and MHC. This was

further evident at 3 months post-surgery when collagens I and III were overexpressed in OG and USG but not in CG and SSG. Furthermore, quantitative evaluation showed cytokeratins 8 and 19 and MHC to have greater expression levels in SSG than seen in USG.
Conclusions: Morphologic and molecular reconstitution of bladders occurs more rapidly using stem cell seeded SIS. Although USG and SSG appear to develop all three cellular constituents by 3 months, only SSG had gene expression levels similar to controls.

S013

FETOSCOPIC TRACHEAL OCCLUSION IN THE HUMAN FETUS WITH SEVERE CONGENITAL DIAPHRAGMATIC HERNIA., Jose L Peiró MD, Eduard Gratacós MD,Elena Carreras MD,Nuria Torán MD,Goya Enriquez MD,Josep Lloret MD,Salvador Salcedo MD,Jan Deprest * MD,Kipros Nikolaides ** MD,Vicen Martinez-Ibáñez MD, Fetal Surgery Program. Hospital Vall d?Hebrón. Barcelona. Spain. + Fetal Medicine Units of the Departments of Obstetrics and Gynaecology of the *University Hospital Gasthuisberg, Leuven, Belgium, and **King's College Hospital, London, UK.

BACKGROUND / PURPOSE: Pulmonary hypoplasia degree in congenital diaphragmatic hernia (CDH) will condition mortality rate. Sonographic prenatal diagnosis allows to estimate the lung hypoplasia within lung-head ratio (LHR). When LHR < 1 associated with hepatic herniation is present, a near 100 % mortality rate could be predicted. Tracheal occlusion (TO) has been proposed to stimulate fetal lung growth. Presently, we are performing fetoscopic TO for treatment of severe CDH. Our aim is demonstrate feasibility of this percutaneous technique and fetal lung growth after TO in these patients.
METHODS: Percutaneous fetoscopic tracheal occlusion (FETO) with a detachable balloon, were carried out in 21 consecutive fetuses with severe CDH, at 3 institutions in Leuven, London and Barcelona. Eight cases of prenatally diagnosed CDH were treated since October 2002 at our center. All of them had sonographic criteria of severity, LHR<1 and liver-up. Percutaneous fetoscopic TO with endotracheal balloon at 26 weeks of gestational age (GA) was performed. Fetal lung response was evaluated after TO within ultrasound scanning (US) and fetal MRI-pulmonary volumetry. EXIT procedure was performed, in the first cases, for balloon removal. A second approach with other fetoscopy at 34 weeks to retrieve the balloon is prefered.
RESULTS: Endotracheal placement of the balloon was successfully performed in all 21 cases and the mean duration of the operation was 20 min. Lung growth was patent in the LHR increase and MRI-pulmonary volumetry. After birth, in the second approach cases, all presented a good pulmonary fields at plain x-rays, and after an initial ventilatory support, lungs showed competent. Survival was 63.6% in this second group of 11 fetuses. Histologic study of lungs showed a saccular phase lung with normal development of airway architecture and vascular structure.
CONCLUSIONS: Percutaneous fetoscopy for fetal TO is a feasible minimally invasive technique. Patient selection is important to treat severe CDH cases. Tracheal occlusion at 26 weeks GA in human cases of severe CDH reverse fetal pulmonary hypoplasia with an evident lung growth from the sonographic, radiological, histological and functional point of view.

S014

FETOSCOPIC DIVISION OF LIMB AMNIOTIC BANDS, Peter Z Borzi MD, Chris Z Kimber MD, Mater Hospital Brisbane and Monash Medical Centre Melbourne
Isolated limb amniotic bands are rare. The timing of fetal surgery and outcome is unknown. Few isolated cases have been previously reported.
Methods: Three fetuses underwent detailed ultrasound assessment and karotyping for amniotic band syndrome. All three fetuses had isolated leg bands with gross distal oedema and compromised doppler flow. This was worsening in all cases over a four week period. Fetal surgery was offered and accepted by all 3 mothers after informed consent.
A double port technique was necessary for 2 operations whilst the final procedure was performed with a single 2mm operating fetoscope. A combination of scissor dissection,laser, grasping and electrosurgery was required. Radially dilating ports were used to access the uterine cavity. All operations were performed between 26 and 27 weeks gestation.
Results: No maternal or fetal complications occurred. All babies delivered spontaneously at term. Two additional toe amniotic bands were missed in 1 fetus.
There was marked improvement in foot oedema, doppler flow and movement in all 3 feet. All neonates required closure of the fetoscopicaly created wound.
Conclusions: Fetoscopic amniotic band division for threatened limbs is feasible. Isolated cases have demonstrated signifigant reduction in limb swelling and improved doppler flow. Large international series are required to determine the appropriate timing of intervention and outcome data.

S015

OPTIMISATION OF LAPAROSCOPIC VARIX LIGATION IN CHILDREN, Igor V Poddoubnyi MD, Anatolyi F Dronov MD,Andrei A Isaev MD,Namir A Al-Mashat MD, Moscow State Medico-Stomatologic University

Laparoscopic procedures were performed in 1400 boys (6-14 years) with left-side idiopathic varicoceles during the period between 1993 and 2004.
Three variants of technique were used:
Group 1 (520 patients)- artery-saving procedure with contrasting (indigocarmine injected under tunica albuginea) and preservation of lymphatic vessels;
Group 2 (110)- ligation of the whole vascular bundle without any dissection of the artery or lymphatic vessels;
Group 3 (770)- ligation of veins and artery with thorough visualization and preservation of lymphatic vessels without any contrasting.
Three 5,5 mm trocars were used in all cases.
Results:
Group 1? recurrence rate was 0.8% (4 cases). Four cases of orchitis (0.8%) were the result of indigocarmine injection.
Group 2? no cases of recurrence and 6 cases of hydrocele (5.5%) occurred.
Group 3? there were no cases of recurrence and other postoperative complications in this group.
Postoperative Doppler examination revealed no difference in testis blood circulation in the artery-saving group 1 and group 3 where the artery was ligated together with veins.
Thus we consider the method used in Group 3 optimal for the treatment of pediatric varicocele, providing excellent results and excluding even the reasons of possible complications.

S016

ADOLESCENT VARICOCELE: PREOPERATIVE LYMPHOGRAPHY WITH PATENT BLU TO PREVENT HYDROCELE AFTER LAPAROSCOPIC PALOMO PROCEDURE, S. F. CHIARENZA MD, S. D'AGOSTINO MD,M.A. FABBRO MD,L. COSTA MD,M.G. SCARPA MD,L. MUSI MD, DEPT PEDIATRIC SURGERY S.BORTOLO HOSPITAL VICENZA

OBJECTIVE
Objective is to verify the reduction of post-operative testicular hydrocele in patients that underwent high laparoscopic Palomo operation for adolescent varicocele. We report our experience with peri-operative limphography in order to identify and preserve during laparoscopic procedure ligature of lymphatic vessels.
MATERIALS AND METHOD
Pre operative limphography was applied in 27 consecutive patients affected from adolescent varicocele. The mean age was 13,5 (8-18) years, the grade of varicocele was III (according to Steno) and the side was always left. In 2001 Oswald and Korner describes a modification of open Palomo technique with preoperative limphography in order to prevent ligation of lymphatic vessel; In September 2002 we started with preoperative blu patent lymphography performing Palomo procedure by laparoscopy. Fifteen minutes before operation we inject on left hemiscrotum (intradartoic) 2,5-3 ml of Patent Blue at 2,5% in order to identify and preserve from ligature perifunicolar lymphatic vessels. Laparoscopic Palomo procedure was successfully carried out in all the patient.
RESULTS
Only in 17 patients on 27 (63%) identification and conservation of lymphatic vessels by lymphography was possible; in the remaining we made Palomo operation trying to preserve perivascular fat tissue (probably containing lymphatic vessels). Mean follow up was 9,5 (6-24) month. None of 27 patient that underwent laparoscopic Palomo procedure have relapse; none of 17 patient with positive limphography have testicular hydrocele; one of the 10 remaining patient develop a medium hydrocele at 10 months of operation.

CONCLUSION
This is a preliminary report because the low number of patients and relatively short follow-up not sufficient to grant a sufficient accuracy. In addition only in 17 patient on 27 (63%) we have clearly identified and preserved lymphatic vessels. We think that preoperative limphography in laparoscopic Palomo procedure is a simple and feasible method to prevent post-operative testicular hydrocele. However to increase positive results is necessary to standardize the method identifying the exact side the correct level of injection and the time of limphography before operation.

S017

HYDROCELE AS A COMPLICATION FOLLOWING LAPAROSCOPIC VARICOCELECTOMY IN CHILDREN AND ADOLESCENTS, Nenad Janic PhD, Sanja Sindjic MSc,Ana Asanin MD, University Childrens Hospital, Belgrade, Serbia & Montenegro

HYDROCELE AS A COMPLICATION FOLLOWING LAPAROSCOPIC VARICOCELECTOMY IN CHILDREN AND ADOLESCENTS
N. Janic, S. Sindjic, A. A?anin
University Childrens Hospital, Belgrade, Serbia
Aim: Hydrocele seems to be the most frequent complication in children who underwent laparoscopic surgery for varicocele treatment. The aim of this study was to evaluate the results and complications of laparoscopic varicocelectomy in children.
Methods: During 13 years period (June 1991 - June 2004), 121 patients aged 9 to 17 years (mean 14 years), underwent laparoscopic ligation of unilateral (112 patients) or bilateral (9) varicoceles. In 9 patients, vas-associated veins were laparoscopicaly identified and ligated in addition to the main testicular vessels. Eight patients had recurrent varicocele after previous surgical treatments. A difference in testicular size - growth arrest (more than 10%) was the most common indication for varicocelectomy. For ligation in the first 73 patients we used Titanium clips, and in last 48 cases Laparosonic Coagulating Shears (Ultracision).
Results: Average operation time was 18 minutes (range, 12 to 35) and hospitalization about 8 hours (range, 6 to 24). Follow-up information were available in 103 (85%) cases. At a mean of 5,5 years follow up (range 6 months ? 13 years), in 13 patients (10,7%) hydrocele appeared between 10 days and 4 years (median 2,5 months). Postoperative recurrence occurred in 2 boys (1,7%). Hydroceles were treated with scrotal puncture (1-4 punctures) under local anesthesia in 4 cases. Spontaneously, hydrocele reduced in 7 children, and 2 boys underwent open surgery (one successfully, while another had recurrent hydrocele after surgical repair).Testicular atrophy and severe intra or postoperative complication did not occur in any patient of this series.
Conclusion: Hydrocele seems to be the most frequent postoperative complication and a potential problem, especially in children with laparoscopicaly ligated veins and artery (Palomo procedure). Surgery or scrotal punctures are not always successful method for solution of the varicocele problem after laparoscopic varicocelectomy.

S018

WHICH APPROACH? TRANSPERITONEAL OR RETROPERITONEAL, FOR PAEDIATRIC LAPAROSCOPIC NEPHRECTOMY ? 100 CONSECUTIVE CASES, Mohan S Gundeti MS, Y atin Patel,Peter Cuckow MD,PAtric Duffy MD,Duncan Wilcox MD,Imran Mushtaq MD, Great Ormond street Hospital,Guy's Hospital and MIddlesex Hospital Institute of Urology

Objective
To evaluate the outcome of l100 consecutive laparoscopic nephrectomies in children ,and to determine the best approach for this procedure.
Patients & Methods
97 consecutive children laparoscopic nephrectomy over a 36-month's period were reviewed.
Laparoscopy was performed by either, the transperitoneal (TP) or posterior prone retroperitoneal (PPR) approach, based upon the preference of the operating surgeon.
Results
A total of 100 procedures were successfully completed laparoscopically, including 5 children who underwent bilateral synchronous nephrectomy. The median age at surgery was 5 .5 yrs (range, 7m-17 yr.)The indications for nephrectomy were ; dysplasia/hypoplasia(n= 15), multicystic dysplastic kidney (n=23), obstructive uropathy (n=14), reflux nephropathy (n=31), end stage renal failure(n=14) and duplex kidney(n=3).The median renal length was, 6cm(range2-19). A near complete ureterectomy was carried out in the refluxing kidneys with both approaches. The retroperitoneal approach (n=49) had a lower operative time (92min) than the transperitoneal approach (114min). Median opiate analgesic requirement was significantly greater in the transperitoneal group than in the retroperitoneal group (p=0.02).
The Median length of postoperative hospital stay was 48 hours, regardless of the approach utilised. The complications were minimal (6%) and was equal with both approaches.
Conclusions
Laparoscopic nephrectomy is a safe and well-established procedure in children. There appears to be no major technical advantage of one approach over the other. The PPR approach has advantageous when performing bilateral nephrectomy in ESRD, as it allows for immediate peritoneal dialysis.

S019

ENDOSCOPIC EXTRAPERITONEAL RENAL SURGERY: THE ANTERIOR APPROACH, A NAJMALDIN MD, THE LEEDS TEACHING HOSPITALS NHS TRUST

Introduction/Aims
In paediatric endoscopic extraperitoneal renal surgery, the kidney is approached posteriorly in a lateral or prone position which has technical disadvantages. The author presents the application of the anterior approach as an alterative.
Methods
The patients were positioned supine with the affected side raised 15-35 degrees using pads and strappings. The primary cannula was placed at or anterior to the anterior axillary line using an open technique. The extraperitoneal space was developed and two 3.5mm working cannulae were placed, one behind and above, and the other anterior and below the primary cannula. Occasionally a third working cannula anteriorly or posteriorly proved helpful. A pneumoperitoneum was maintained at 0.5 litres/minute flow and 8-10mmHg pressure.
Results
There were 44 procedures (44 children, age 7 months - 15 years) including nephrectomy, or nephroureterectomy 16, partial nephrectomy 6 and Anderson-Hynes pyeloplasty 22. In three children the procedure was converted because of failure to create adequate space due to pertioneal tear in 2 and very large kidney in 1. The average operating time was 205 minutes - pyeloplasty and 115 minutes - nephrectomy/partial nephrectomy. There were no perioperative complications. Epidural or intravenous analgesia for 12-18 hours and/or oral analgesia provided adequate postoperative pain relief. The patients were discharged home at 12-24 hours postoperative - nephrectomies, and 24-48 hours - pyeloplasties. At follow up (3 weeks - 3 years) one patient developed signs of persistent pelviureteric obstruction and the remainder appeared asymptomatic and improved on ultrasound scans.
Conclusions
Anterior extraperitoneal approach provides easy, safe and effective space for laparoscopic renal surgery. The technique may provide advantages over the conventional posterior and posteriolateral approaches.

S020

LAPAROSCOPIC VERSUS OPEN NEPHRECTOMY IN CHILDREN:, WAEL M EL-SAIFY MSc, M KULKARNI,A B MATHUR, Department of Paediatric Surgery, Norfolk and Norwich University Hopital, UK

Introduction:
Laparoscopic nephrectomy (LN) has been reported with encouraging results in adults. We report our institution's experience with (LN) in children with benign renal diseases.
Methods:
A total of 13 children underwent (LN) were compared to additional 13 consecutive children underwent similar open procedure. Medical records were reviewed retrospectively for relevant clinical data; operative time, morbidity, length of analgesic use and postoperative hospital stay
Results:
Planned laparoscopic surgery was completed in 12 cases, conversion to open surgery because of extensive adhesions occurred in one case. Mean operative time was 148 versus 119 minutes (p=0.12) and mean postoperative hospital stay was 1.8 versus 3.6 days in the laparoscopic and open nephrectomy groups, respectively. Narcotic analgesia requirement was significantly less in laparoscopic group (p=0.0007). Blood loss

was not statistically significant. No major perioperative complications in both groups.
Conclusions:
Laparoscopic nephrectomy compares favorably with open renal surgery in paediatric population with all the potential benefits of minimal invasive surgery.

S021

BILATERAL SYNCHRONOUS RETROPERTONESCOPIC NEPHRECTOMY (RPN) WITH SIMULTANEOUS PERITONEAL DIALYSIS (P.D.): A NEW ERA IN MANAGEMENT OF THE PAEDIATRIC ESRD, Mohan S Gundeti MS, Imran MUshtaq MD,Arash Taghizadeh MD, Guy's & Great Ormond Street Hospital,London

Introduction
Peritoneal dialysis (PD) is the treatment of choice in children with end stage renal failure who are awaiting renal transplantation. Traditionally patients requiring bilateral nephrectomy required a period on haemodialysis prior to being converted to PD at a later stage.
Patients and Methods
Bilateral synchronous retropertonescopic nephrectomy (RPN) with initiation of or return to PD in the immediate postoperative period was performed in 13 children between May 2001 and August 2004.The mean age at the Surgery was8.5 yrs (6m-17y). Indications for nephrectomy included steroid resistant persistent protenuria (n=8), drug resistant hypertension (n=3), combined indication (n=1) and one posttransplant intractable polyuria due to the native dysplastic kidney. The mean size of the kidney was 7.5 cm (2-14). Bilateral RPN was performed in the prone position with a standard two ports or single port (S I M P L) approach. Five children were repositioned supine and a tunneled PD catheter was inserted in the standard open fashion.
Results
Bilateral synchronous RPN was successfully completed in 12 children. One procedure was complicated by a peritoneal tear and needed open conversion. There were no major complications and no major blood loss needing transfusion.
The mean operative time was 160min(110-280). The PD was established in immediate postoperative period in all except one who required haemodialysis for a persistent leak and other was on haemodialysis already.
Conclusion
In those children who require bilateral native nephrectomy prior to transplantation our technique maintains the integrity of the peritoneum, allowing for immediate postoperative PD.The technique has the added benefit of an earlier return to normal activity, reduced postoperative pain and an improved cosmetic outcome.

S022

LAPAROSCOPIC TRANSPOSITION OF LOWER POLE VESSELS- THE ?VASCULAR HITCH?: AN ALTERNATIVE FOR PELVIURETERIC JUNCTION OBSTRUCTION IN CHILDREN, P Godbole MD, I Mushtaq,D T Wilcox,P G Duffy, Great Ormond Street Hospital for Children

Objective:
Dismembered pyeloplasty has been the traditional technique in the management of ureterovascular pelviureteric junction obstruction (PUJO) in children. Endopyelotomy and concomitant laparoscopic transposition of lower pole vessels for PUJO has been described in adults. We describe our experience and technique of laparoscopic transposition of lower pole vessels in children with PUJO.
Patients and Methods:
Ten patients (7 boys and 3 girls) with a mean age of 15.4 years (14-16) underwent laparoscopic transposition of lower pole vessels. Surgery was indicated on the basis of recurrent symptoms of intermittent PUJO and ultrasound and MAG3 appearances of obstruction with or without reduced function. This technique was only utilised where clinically there was a high index of suspicion of lower pole vessels. If lower pole vessels were not found, the patients proceeded to a laparoscopic dismembered pyeloplasty. The technique of laparoscopic transposition of lower pole vessels involved transperitoneal mobilisation of the lower pole vessels off the renal pelvis thereby freeing the PUJ and transposing them superiorly where they were anchored by approximating the pelvis around the vessels by 2-3 absorbable sutures through the adventia of the pelvis, well clear of the PUJ. The main outcome measures were relief of symptoms, and improvement in the ultrasound appearances or in drainage parameters on a postoperative MAG3 renogram performed within 4-6 weeks following surgery.
Results:
The mean operating time was 92 minutes . All patients were discharged within 36 hours following surgery. All patients remain symptom free at a mean of 5.2 m(4-6). 9/10 patients showed good drainage on the postoperative MAG3 renogram and improvement in ultrasound appearances. One patient had recurrent symptoms requiring insertion of a JJ stent and is awaiting further investigations and follow up.
Conclusion:
Our early experience of laparoscopic transposition of lower pole vessels suggests it to be a useful minimally invasive alternative to standard open or laparoscopic dismembered pyeloplasty in older children with symptoms of intermittent PUJO and a high index of suspicion of lower pole vessels as the underlying aetiology.

S023

INITIAL EXPERIENCE WITH ROBOTIC ASSISTED LAPAROSCOPIC PYELOPLASTY IN CHILDREN, COMPARISON OF SIMILAR AGE GROUPED OPEN PROCEDURES TO ROBOTIC ASSISTED LAPAROSCOPIC PROCEDURES, Allan M Shanberg MD, D. Yee MD,Barry Duel MD,Eseqiel Rodriguez MD,Deepak Rajpoot MD, University of California, Irvine, Antoci Center for Pediatric Urology and Nephrology

INTRODUCTION AND OBJECTIVE: Laparoscopic pyeloplasty has been performed in children with ureteropelvic junction obstruction (UPJO). The ureteropelvic anastomosis however, is time-consuming and technically challenging. We describe the use of the da Vinci robotic system in performing laparoscopic Anderson-Hynes pyeloplasty in children and provide an initial comparison of robot assisted laparoscopic pyeloplasty versus open pyeloplasty.
METHODS: From June 2002 until July 2004, 8 pediatric patients underwent robotic assisted laparoscopic pyeloplasty and were matched by age group to patients undergoing conventional open pyeloplasty. The mean age was 11.5 years (range 6.4 to 16.5) in the robot group and 9.8 years (range 6.0 to 15.6) in the open group. The technique for da Vinci-assisted Anderson-Hynes pyeloplasty followed the same steps as for conventional surgery. Three transperitoneal laparoscopic ports were required for the robotic system, and a fourth laparoscopic port was placed for suction, and introduction of suture by the assistant.
RESULTS: Perioperative outcomes evaluated were operative time, estimated blood loss (EBL), hospital stay, pain medication usage, complications, and success rates. The mean operative time and EBL was 363 minutes (range 255 to 522) and 13.1 mL (range 5 to 25) in the robot group versus 248 minutes (range 144 to 375) and 53.8 mL (range 5 to 200) in the open group. The mean length of hospitalization and pain medication usage was 2.4 days (range 1 to 5) and 7.4 mg (range 0 to 23) morphine in the robot group as compared to 3.3 days (range 1 to 8) and 22.0 mg (range 0 to 100) morphine in the open group. The robot group had one perioperative complication as opposed to none in the open group. At a mean follow-up of 14.7 months (range 2 to 24), all robotic procedures were successful on the basis of subjective data using pain scales and radiologic data as determined by renal scan and/or ultrasound.
CONCLUSIONS: Robotic assisted laparoscopic pyeloplasty appears to decrease the length of hospitalization and pain in children.

S024

OUR EXPERIENCE IN LAPAROSCOPIC EXTRAVESICAL TRANSPERITONEAL APPROACH FOR VESICOURETERAL REFLUX (VUR)., Mario Riquelme MD, A Aranda MD,M Hinojosa MD,F Lozano MD,E Candanosa MD, Hospital San Jose Tec de Monterrey, Mexico

Background
There are a few papers about laparoscopic techniques for VUR. Cohen ureteral reimplantation is an effective treatment for primary vesicoureteral reflux and is the most frequently used technique, however it is associated with postoperative morbidity and long stay in hospital. Extravesical technique is less invasive because the bladder remains intact.
Methods
Between January 2001 and February 2004, 9 children (19 units) with primary VUR were treated with extravesical reimplantation with a transperitoneal laparoscopic approach four patients with unilateral and five with bilateral VUR. Two units had double collector system.
Patients average age was 48.2 months.

We used 4 ports for 3 to 5 mm instruments, and a 30° 4 mm lens in all cases. Transperitoneally, the distal portion of the ureter was dissected and a 2.5-3 cm detrusor tunnel were created. After the mucosa was exposed, the ureter was embedded and the detrusor reapproximated; no patient was left with drainage.
Cystography was made at the end of each surgical procedure in order to confirm it was successful and reflux was corrected.
Most of the patients were discharged at the second postoperative day with a vesical catheter and two diapers technique. No ureteral indwelling catheter were used in unilateral cases.
Results
The average surgical time was 110 minutes in unilateral and 180 in bilateral VUR. All procedures were successfully completed laparoscopically and the reflux was corrected in all the patients but one with grade lll VUR that changed to grade l. We had 3 mucosal perforations, which were not sutured. We found microscopic hematuria without vesical spasms. One patient had transitory pyelectasy in the ultrasound follow up.
After a 15 to 49 months period of follow up, only one patient had urinary tract infection.
Conclusion
Cohen reimplantation is the most successful and world wide used surgical technique to resolve VUR. However, is associated with hematuria, vesical spasms and longer hospital stays, because is needed to dissect the ureters toward open bladder. Extravesical laparoscopic reimplantation is a minimal invasive surgery, with minimal bleeding and almost absent vesical spasms, because in not required to open the bladder. It is successful in most cases with maximal hospital stay of 72 hours.

S025

COLLATERAL CIRCULATION AFTER SPERMATIC VESSELS LIGATION FOR ABDOMINAL TESTIS AND ITS IMPACT ON STAGED LAPAROSCOPIC ASSISTED ORCHIOPEXY., Sameh Abdel Hay MD, Pediatric surgery unit Ain Shams University Cairo Egypt

Background: Staged laparoscopic assisted orchiopexy for abdominal testis entails initial spermatic vessels ligation followed by mobilisation of the testis preserving the vas and its vessels as a sole source of testicular blood supply. This mobilisation includes all peritoneal attachments of the testis including the gubernaculum that may carry collateral circulation to the testis that may affect the viability of the testis leading to atrophy. The study of collateral circulation after spermatic vessels ligation and possibility for preservation of the gubernaculum will be the basis of this study.
Materials and methods: The anatomy of the gubernaculum and the effect of spermatic vessels ligation on the collateral circulation were studied in 90 boys with 100 abdominal testes with short pedicle. All patients with vanishing testis or those not needing ligation of the spermatic vessels were excluded from the study. The anatomy and the vascularity of the testis, gubernaculum and the vas were studied at initial laparoscopy and 6 weeks later after spermatic vessels ligation and based on these findings the technique for laparoscopic assisted orchiopexy were modified preserving the gubernaculum whenever possible once showing prominent collaterals.
Results: Initial evaluation showed 2groups of patients: group1 with gubernaculum passing through an open internal ring having inguinal attachment in 46 testicles out of them 20 had tough and short gubernaculum. Group 2 showed fifty four testes with soft gubernaculum attached to a closed internal ring with prominent vessels in 40 testes.
Subsequent laparoscopy done after 6 weeks showed prominent collateral circulation around the gubernaculum in 26 out of 46 testes in the first group with open internal ring. The second group with closed internal ring all patients (56 testis) showed vascular gubernaculum. Preservation of the gubernaculum was possible in 12 testicles (26%)of patient in group 1 and in 50 testicles (90%) of patient in group 2.
Conclusion: the routine cutting of the gubernaculum is not necessary for proper mobilization of the abdominal testis and collateral circulation is variable from patient to another and once the gubernaculum shows prominent blood supply its preservation is mandatory whenever possible. The decision to cut the gubernaculum, better to be taken while performing initial spermatic vessels ligation not during the second stage to avoid compromise of the settled collateral circulation.

S026

LAPAROSCOPIC TREATMENT OF NONPLAPABLE TESTIS. A MULTI-INSTITUTIONAL ANALYSIS ON 1017 TESTICLES, Ciro Esposito 1 MD, Nicholas Bax 2 MD,Vincenzo Jasonni 3 MD,Jeff Valla 4 MD,Felix Shier 5 MD,Olivier Reinberg 6 MD,Mario Lima 7 MD,Alessandro Settimi 8 MD,Francois Becmeur 9 MD,Girolamo Mattioli 3 MD,Alfonso Papparella 10 MD,M Endo 11 MD,Jurgen Shleef 12 MD,Luciano Mastroianni 13 MD,W Urbanowicz 14,Antonella Centonze 1 MD,IPEG GROUP 15, 1Chairs of Pediatric Surgery Magna Graecia University of Catanzaro , Via Tommaso Campanella 115, 88100 Catanzaro, Italy; 2 Uthrecht, the Netherland; 3 Genova, Italy; 4Nice, France; 5 Meintz, Germany; 6 Lausanne, Switzerland; 7 Bologna, Italy; 8 Naples Fe

AIM: The objective of this study was to evaluate the results of laparoscopy in the therapeutic management of intraabdominal testes.
METHODS: A questionnaire was distributed to 50 pediatric surgeons, members of the IPEG. Each contributor retrospectively reviewed his experience in this field in a 3-years period.
We collected the data of 880 patients with 1017 non palpable testes.
RESULTS: We found in laparoscopy an intrabdominal testis in 384 cases , of normal size in 317, hyptrophic in 67. As for therapeutic management: in the 67 cases a laparoscopic orchiectomy was performed. In the 317 testes located in the intrabdominal position, six different techniques of orchidopexy were adopted: open orchidopexy in 98 testes (group 1); microsurgery in 18 (group 2); laparoscopic assisted orchidopexy (LAO) in 80 (group 3); Fowler ?Stephens in only one stage in 18 (group 4); 2 stages F-S procedure (1st lap-2nd open) in 42 (group 5); 2 stages F-S procedure (both steps in laparoscopy) in 61 (group 6).
The success rate for all groups was: group 1 (77.5%); group 2 (66.6%); group 3 (93.7 %); group 4 (72.2%) ; group 5 (78.5 %); group 6 (81.9 %). The data were analysed with the unpaired t-test and LAO gave results statistically significant better compared to the other procedures (p= 0.0151)
CONCLUSIONS: LAO seems to have a success rate higher than other procedures and this result is statistically significant. Despite the weaknesses inherent in a retrospective unrandomized study, we conclude that laparoscopic is a successful approach for therapeutic management of intraabdominal testes.

S027 Short Poster

TECHNICAL CONSIDERATIONS WHEN PLANNING LAPAROSCOPIC ADRENALECTOMY IN PEDIATRIC PATIENTS, Patrick M McEnaney MD, Demetrius Litwin MD,Andras Sandor MD,Liam Haveran DO,Michael P Hirsh MD,Paul D Danielson MD, University of Massachusetts Medical School

Purpose: Laparoscopic adrenalectomy can be safely performed in pediatric patients; however, several techniques have been described. We report a series of cases in which the different laparoscopic approaches were employed based upon preoperative diagnosis and imaging studies.
Methods: The charts of four pediatric patients who underwent laparoscopic adrenalectomy were reviewed for operative length, trocar use, estimated blood loss, postoperative length of stay, need for transfusion, and preoperative and postoperative diagnoses.
Results: Three patients (age: 1 month-16 months) had disease localized to the adrenal gland (1R, 2L) noted on imaging studies. They were approached transabdominally utilizing 3 subcostal trocars with the patient in a full lateral position. The mean operative time was 101 min (range: 80-137 minutes). These three patients were discharged within 48 hours of the operation. Two patients were diagnosed pathologically with neuroblastoma whereas one patient, who underwent a partial adrenalectomy, had an organizing hematoma. Estimated blood loss in all cases was minimal (less than 25 ml), and no patients in this group required transfusion. In contrast, the fourth patient (age: 2 yr 9 moss) had a preoperative diagnosis of Stage IV neuroblastoma for which he underwent multiple rounds of preoperative chemotherapy. Preoperative imaging demonstrated extensive residual disease in the right suprarenal and periaortic region. This patient was placed in a semi-lateral position and a 5 trocar, transabdominal technique was employed. Operative time was 208 minutes with an estimated blood loss of 150 ml, thus requiring transfusion of 150 ml of packed red blood cells. Intraoperatively, the tumor was noted to be densely adherent to the IVC, and as such, final pathological margins were positive. This patient had remained intubated in the ICU postoperatively for 12 days and was ultimately discharged home on postoperative day 17.

Conclusions: We advocate two different minimally invasive, transabdominal techniques for adrenalectomy in children. For isolated lesions, a 3 trocar technique with the patient in a full lateral position is used. With more complex lesions, the use of a 5 trocar technique with the patient in a semi-lateral position is utilized in order to complete the more extensive dissection.

S028 Short Poster

LAPAROSCOPIC INTERVAL APPENDICECTOMY, Anthony Owen MD, Olivia C Moore,Julian P Roberts MD,Jenny Walker MD,S S Marven MD, Paediatric Surgical Unit, Sheffield Children's Hospital

AIM: Conservative management of advanced complicated appendicitis in children is becoming more common. The formation of a phlegmonous mass or abscess mitigates against emergency laparoscopic appendicectomy. Subsequent Laparoscopic Interval Appendicectomy (LIA) may reduce the risk of acute septic complications. We have evaluated our experience with this management approach. METHODS: Thirty six Patients offered LIA following conservative management of advanced complicated appendicitis were identified between January 2000 to December 2004 identified from hospital records. Notes were reviewed retrospectively. RESULTS: Two patients were found to have completely excised small carcinoid tumours on histology. One patient's mother refused LIA but the patient presented less than a year later with recurrent appendicitis and had an open appendicectomy. The median number of nights in hospital was 1 (range 1-3). Median age was 8 years (range 1-15 years). Fourteen (40%) of patients were not given morphine post operatively. No patients developed wound sepsis or post operative intra-abdominal abscesses. CONCLUSIONS: Laparoscopic Interval Appendicectomy should be performed following conservative management of advanced appendicitis complicated by phlegmonous mass or abscess. This will eliminate the risk of recurrent appendicitis and to excise undiagnosed carcinoid tumours. The procedure is associated with minimal morbidity. More than a third of patients did not require morphine. One night in hospital was arranged for all patients but daycase surgery may be possible with increasing experience.

S030 Short Poster

SELF-CLOSING U-CLIPS ARE SAFE AND EFFECTIVE FOR MINIMALLY INVASIVE PEDIATRIC BOWEL ANASTOMOSIS, Adrien J Kant MD, Joseph L Lelli MD, Karen M Forman BAA, Elizabeth J Dawe DVM, Raja Rabah, MD, Michael D Klein MD, Scott E Langenburg MD, Children's Hospital of Michigan, Wayne State University

Introduction: Minimally invasive pediatric bowel reconstruction is primarily limited by intracorporeal suturing techniques. Self-closing U-clips may be a safe and effective alternative to intracorporeal sutures. We compared the functional healing of intestinal anastomoses created with U-clips to those done with running suture in an infant-sized porcine model.
Methods: We divided the proximal small bowel of 8 pigs (3.8 - 6.4 kg) and performed minimally invasive robotic reconstruction. Four anastomoses were created with running 4-0 polyglactin sutures; four were created using S60 nitinol U-clips. Pigs were fed the same night, survived for two weeks, then were euthanized and weighed. Diameters of harvested anastomoses were calibrated with dilators, and bursting pressures were obtained by manometry. Gross and histologic examinations of anastomoses were performed.
Results: There was no significant time difference in performing clipped or sutured anastomoses (71 ± 17 minutes vs. 52 ± 5 minutes, P = NS). All pigs tolerated diet and gained weight. There were no anastomotic leaks. Diameters ranged from 8-10 mm clipped and 8-11 mm sutured. Adhesions were similar in both groups, and all but two specimens (both sutured) burst away from the anastomosis. Bursting pressures averaged 168 ± 45 mm Hg (range, 132-232) for clips and 180 ± 53 mm Hg (120-250, P = NS) for running suture. Histologic examination showed similar healing with good mucosal alignment in clipped specimens.
Conclusions: U-clips can simply and reliably create minimally invasive bowel anastomoses equivalent to running suture. Clipped anastomoses are as strong as running suture, with similar healing characteristics.

S031 Short Poster

BILATERAL THORACOSCOPIC SPLANCHNICECTOMY IN CHRONIC INTESTINAL PSEUDO-OBSTRUCTION, K Khelif MD, M Scaillon MD,MJM Govaerts MD,JM Vanderwinden PhD,MH De Laet MD, Queen Fabiola University children's Hospital Brussels and Laboratory of Neurophysiology Faculty of Medicine, Université Libre de Bruxelles, Brussels, Belgium

Objective :
Chronic intestinal pseudo-obstruction (CIPO) is an uncommon, highly morbid gut motility disorder. Its management remains challenging. This study evaluated the safety and efficiency of bilateral thoracoscopic splanchnicectomy in 2 children with severe CIPO, whose debilitating chronic abdominal pain and poor quality of life had been transiently alleviated by iterative bilateral celiac anaesthetic blocks.
Methods and procedures :
Two boys aged 7 years with CIPO (Hyperganglionosis) are reported. One, who was mentally retarded and had underwent a Ladd procedure and a laparotomy for bowel obstruction, presented with chronic severe abdominal pain, anorexia, vomiting and aggressive behaviour with self-mutilation.
The other, who had underwent a Ladd procedure, an ileostomy, and a subtotal colectomy, presented with chronic severe constipation, abdominal pain and vomiting.
Both patients were refractory to any form of therapy.
Iterative bilateral celiac blocks performed in both patients alleviated the pain and improved their bowel habits, well-being and behaviour for periods of up to 6 weeks.
After 26 successful celiac blocks in the first patient and 9 in the second, a bilateral thoracoscopic splanchnicectomy was performed in both patients in less than 30 min in a semi prone position with a two 5mm trocar technique. The greater and the lesser splanchnic nerves were coagulated and divided on both sides in both patients.
The postoperative course was uneventful and patients were discharged on day 3 and day 2, respectively.
Results:
Both patients presented a resolution of all complaints with lasting improvement of clinical signs, over a follow-up period of respectively 30 and 25 months, including a dramatic psychomotor and social amelioration in the mentally retarded boy.
Conclusions :
Bilateral thoracoscopic splanchnicectomy is a safe and effective procedure for the treatment of refractory CIPO in children alleviated by iterative celiac anaesthetic blocks.

S032 Short Poster

LAPAROSCOPIC TOTAL PROCTOCOLECTOMY (TPC) AND ILEAL J POUCH (IJP) IN PEDIATRICS, Maria M Bailez MD, Carlos Fraire MD,Ana M Marin MD,Lisandro Piaggio MD, J. P. Garrahan. Htal Bs. As. Argentina.

TPC and IJP are our first choice for surgical treatment of patients with ulcerative colitis(CU) and poliposis (P) These procedures are done primarily or staged depending on the patients clinical status .The advent of advance minimal access equipment and techniques allowed us to perform the same operations with decreased operative pain and improved cosmetic appearance.
Aim.: Show and discuss alternative techniques used in our first 12 patients treated laparoscopically
Material & Methods Starting Setember /02 a total of 19 procedures were done in 12 patients with a mediam age of 11 years(4-18y).Procedures were : TPC & IJP: 3 subtotal colectomy (STC) & ileocolostomy : 9 ; proctectomy & IJP : 7 We use 4 ports (umbilicus ;suprapubic and both lower quadrants) .We start with the left colon . The monitor is moved to the head of the patient to continue with the transverse and rigth colon. Vessels are divided using ultrasonic or bipolar sealing devices. In STC we leave an ileocolostomy in the left lower quadrant We use a Pffannestiel incision in 1 pt with a P treated with a TPC&IJP .Proctectomy is carried as a full thickness procedure , Everting the rectum through the anus and transecting above the dental line with a linear stappler. The pouch is performed outside the abdomen .Anastomosis is done under laparoscopic vission using a circular stappler inserted through the perineum.
Results :Mean operative time was 6,5 hours in TPC& IJP; ?,3,5 hours in proctectomy & pouch and decreased from 5 hours to 3,2 hours in STC. Intraoperative bleeding in 3 patients after dividing vessels with the ultrasonic device was treated with loops.Inmediate postoperative complica

tions were :intestinal obstruction in 2, mild anal stenosis in 2 and transient pouch isquemia in 1.Long term functional results were evaluated in 8/12 which underwent ileostomy take down.With a mean follow up of 7 months (6-17m) ;1 has a pouch diverticulum and 1 a recurrent pouchitis . Frequency of stools is 4 to 5 a day.
Discusión:We learned that : 1) TPC is feasable using 4 ports and an instrument of devascularization 2) Extracorporeal pouch is a quick and safe procedure.3) The colon is removed through the same incision 4)Cephalic traction of the pouch is required during the use of the circular stapler to prevent damage of the vascular supply.
Laparoscopic PCT ; CST and PIJ are feasible and safe procedures. A comparative study with open procedures is being held in our institution now.

S033 Short Poster

MINIMAL INVASIVE GASTROSTOMY: ROUTINE LAPAROSCOPIC ASSISTED. YES OR NO?, Marcos Bettolli MD, Juan Bass MD,Steven Rubin MD, Department of Surgery, Children's Hospital of Eastern Ontario

Introduction: Although percutaneous endoscopic gastrostomy (PEG) is the most common method of gastrostomy insertion, laparoscopic assisted PEG (LAPEG) may eliminate major complications related to PEGs. This study compares the result of PEG and LAPEG.
Method: Operation and long-term postoperative follow-up notes of 59 PEGs and 31 LAPEGs done at th Children's Hospital of Eastern Ontario over the past 4 years were reviewed. Gastrostomies performed concomitantly with fundoplication were excluded.
Results: The operating room time for PEG ranged from 6 to 54 minutes (mean =17.5 minutes), and for LAPEG from 24 to 60 minutes (mean = 39.9 minutes), (student T-test- no stastistical difference). The incidence of G-tube site infection, G-tube dislodgement, GERD and peristomal granulation tissue formation was similar in both methods (Fisher exact test). Two infants with PEG developed colocutaneous fistulas after long-term use.
Conclusions: Laparoscopy during PEG placement avoids iatrogenic intestinal injury and permits accurate gastric location of the PEG tube. LAPEG is particularly advantageous when abdominal transillumination is unreliable such us in infancy, obesity, and prior laparotomy, and where the gastric anatomy is unusual.

S034 Short Poster

INTRA-OPERATIVE COMPLICATIONS OF LAPAROSCOPIC NISSEN FUNDOPLICATION, B. Banieghbal MD, G. Pitcher MD,PG Beale MD, Division of peditaric surgery, University of The Witwatersrand, Johannesburg, South Africa

AIM: Laparoscopic Nissen fundoplication has become of the most commonly performed procedures in paediatric surgery. Many are performed in conjunction with gastrostomy placement for neurologically impaired (NI) children, with a reported intra-operative complication of 5-6% in other series. This is a relatively large series with detailed report of intra-operative complications.
METHOD: All procedures were performed by or under direct supervision of the first author over a 3 year period.
The procedure was performed utilizing a 3-trocar approach as well as a percutanous liver retractor. Harmonic scalpel was used extensively for dissection and control of short gastric vessels.
RESULTS: 128 patients had fundoplication in this period. 82 were classified as NI (all but 2 required laparoscopically-assisted gastrostomy insertion at the time of surgery).
Intra-operative complications occured in 20 children (15.6%), 15 in NI children (18.3%):
1.Respiratory complications requiring prolonged unexpected ward or intensive care unit (ICU) admission in 8 patients*, all but 2 were in NI children.
2.Significant bleeding requiring transfusion in 4 patients, all in NI children.
3.Significant bleeding requiring conversion in one patient.
4.Umbilical wound dehiscence in 2 patients, both in NI children.
5.Delayed colonic perforation in one patient*, Gastric perforation in one case and esophageal perforation in another patient. The first two occurred in NI children.
6.Diaphragmatic injury requiring repair in one case
7.Extensive breakdown of laparoscopically placed gastrostomy* in one patient, this was in a NI child with advance HIV infection.
Three of the above patients (2.3%), marked with *, died directly as the result of their complications.
Bleeding and perforations occurred despite liberal usage of Harmonic scalpel.
CONCLUSION: Laparoscopic Nissen fundopliaction is not without its problems, and many of the above complications are also inherent to all laparoscopic surgery.
Newer and safer energy devices are needed to decrease complications associated with these instruments.
NI children frequently required ICU management post-operatively and arrangements should be made for this possibility.

S035 Short Poster

COMPLICATIONS AFTER LAPAROSCOPIC FUNDOPLICATION: 8 YEAR INSTITUTIONAL EXPERIENCE, Michelle Jackman MD, Karen Bailey MD, Steven Rubin MD,Juan Bass MD, Children's Hospital of Eastern Ontario

Background/Purpose: Laparoscopic fundoplication has become the mainstay of surgical care in children refractory to medical management of gastroesophageal reflux disease (GERD). We report the postoperative complications associated with laparoscopic fundoplication in children.
Materials and Method: From 1996-2003, 80 consecutive laparoscopic fundoplications performed in children with GERD, were retrospectively reviewed. Ages ranged from 7 months to 17 years (mean 5.9). There were 57 boys, 23 girls including 47 patients (59%) with underlying neurological disease. Indications for surgery included failure to thrive (20), regurgitation (65), aspiration (28) and recurrent pneumonia (31).
Operative times ranged from 45 to 385 minutes (mean 154 minutes). At the time of surgery 1 pyloromyotomy, 3 pyloroplasties and 34 new gastrostomies were done. 8 patients required conversion to an open procedure.
Results: Hospitalization was 1-28 days (mean 6.8 days). Ten patients required an ICU admission of 1-16 days (mean 3.3 days). Early postoperative (within 28 days) complications occurred in 13 individuals, including 4 pneumonias, 2 urinary infections, 2 wound infections, and 3 infected g-tube sites. One patient with a dislodged g-tube required re-operation. Follow-up ranged from 1 month to 57 months (mean 16 months). A redo fundoplication was required in 4 patients. Five patients in the series have died with problems unrelated to their surgery.
Conclusions: Laparoscopic fundoplication can be safely performed by skilled surgeons in children. The complication rate is significant in the early postoperative period. An experienced medical team providing acute care, in addition to regular follow up can minimize problems.

S036 Short Poster

THE TREATMENT OF BENIGN ESOPHAGEAL STRICTURES USING REMOVABLE SILICONE STENTS, Theodore H Stathos MD, Saundra Kay MD,Steven S Rothenberg MD, The Mother and Child Hospital at Presbyterian/St. Luke's Medical Center, Denver, USA

Esophageal strictures are a common problem in the pediatric population. Common causes include damage and subsequent scaring from caustic ingestions or severe GERD, post-operative scaring from the repair of esophageal atresia (EA) and tracheoesophageal fistula (TEF). Up to 90% of strictures are readily treatable using common esophageal dilation techniques. Others remain refractory to dilatation and typically require surgical resection or frequent repeated dilatation. Silicone stents have successfully been used in adults for the treatment of patients with refractory strictures. We suggest that the use of silicone stents in children with refractory strictures should be safe and successful.
Six children with refractory esophageal strictures were selected based on the recurrence rate of re-stricturing of the esophageal lumen following dilatation. All the children were otherwise in good health. The Polyflex® Esophageal Stent (Boston Scientific) diameter and length were chosen based on the diameter and length of the stricture, in addition to the age and size of the child. The same physician placed all of the stents endoscopically with fluoroscopic guidance while the patient was under general anesthesia. All patients were observed for 24 hours in the hospital and had daily chest x-rays for two days following the stent placement. Weekly chest x-rays were then obtained. After 4-6 months the stents were endoscopically removed and a larger diameter stent was placed (phase 2). The second stent was left in place for another 4-6 months.
Six children have successfully had stents placed. All swallow without difficulty. Three of the six patients have successfully had the stent removed and no longer require dilatations. Three patients are in phase 1 of the

treatment and continue to tolerate the stents well. Migration of a stent was observed in only 1 of the patients and endoscopic removal with subsequent replacement was easily accomplished. The same patient initially complained of right-sided chest pain but the symptom eased without any treatment. All 4 of the verbal patients had minor complaints of dysphagia in the first few post placement days.
The treatment of benign esophageal strictures using silicone removable stents is both safe and effective in some children. The Polyflex esophageal stents are easily used with minimal invasiveness in patients that previously required multiple frequent dilatations and faced significantly more invasive surgical treatments.

S037 Short Poster

LAPAROSCOPIC RESECTION OF OESOPHAGEAL STRICTURE WITH RETROGASTRIC STAPLED ANASTOMOSIS IN A 2-YEAR-OLD AIDS PATIENT,
Daniel Sidler MD, Jonathan Juzi MD,Sam W Moore MD, Department of General Surgery/Paediatric Surgery, Tygerberg Children's Hospital, Stellenbosch University

Introduction
Oesophageal strictures in childhood occur most commonly after caustic ingestion, are related to gastro-oesophageal reflux disease or are seen after the repair of a congenital oesophageal atresia. In the immuno-compromised child, infective aetiologies may result in oesophageal ulceration and stricture formation Strictures unresponsive to repeated dilatation attempts are usually managed surgically. Treatment options include partial oesophagectomy and esophageal replacement. Due to increased life expectancy of children on anti-viral therapy surgical options are being considered in HIV infected children and minimally invasive techniques have considerable benefit especially in the immunocompromised children.
Aim and Methods
We are reporting and reviewing the first case of a laparoscopic resection and stapled anastomosis of an oesophageal stricture in a child with AIDS on HAART
Results
We report a laparoscopic assisted transgastric resection of a distal oesophageal stricture in a 2-year-old child suffering from advanced oesophageal scarring and stricture following infective conditions associated with clinical AIDS (CDC stage 3). Following the failure of a second dilatation attempt, a gastrostomy was inserted and HAART treatment commenced. Follow-up contrast studies showed a near complete obstruction of the distal oesophagus. Subsequently a laparoscopic assisted resection of the oesophageal stricture with a primary transgastric stapled anastomosis was successfully performed. . The early outcome appears promising: Two months postoperatively the child is tolerating feeds well, is thriving and gaining weight.
Conclusion
This report describes the successful use of a laparoscopic technique for the resection and anastomosis of a distal oesophageal stricture in a child suffering from AIDS being on anti-retroviral therapy The specific indications for minimally invasive (laparoscopic) approach has not been explored in infants with AIDS. Our case report shows that a laparoscopic assisted procedure in a patient suffering from AIDS is feasible. The patient's ability to gain weight and thrive after the surgical intervention indicates that even in poor prognostic AIDS patient, surgical treatment offers a reasonable option.

S038 Short Poster

PRELIMINARY RESULTS OF A NEW MINIMAL INVASIVE LAPAROSCOPIC REPAIR OF INGUINAL HERNIAS IN CHILDREN,
Martin M Kaiser MD, Fritz O Kahl MD,Lucas M Wessel PhD, Department of Paediatric Surgery, Campus Luebeck, University of Schleswig-Holstein

Objective of the study:
Laparoscopic repair of inguinal hernia reduces scar formation and pain; repair of a contralateral open processus vaginalis prevents children from a possible second operation and anaesthesia. We investigate preliminary results of our new modified minimal invasive laparoscopic approach.
Methods and procedures:
We performed inguinal hernia repair by closing the inner inguinal ring percutaneously under laparoscopic control. With a umbilical 2mm-laparoscop both sides are checked and the inner inguinal ring is closed with one or two U-shaped 3-0 polyglyconate absorbable sutures brought in via a 14 gauge needle. An open contralateral processus vaginalis is always closed. A new developed 1-mm-forceps brought in through a 1.5-mm-self-cutting trocar (Fa. Karl Storz, Germany) allows to define the setting of the suture very precisely and minimizes risk of affecting the vessels and the vas deferens.
(short Video-demonstration of technique)
Results:
We operated on 29 patients (26 boys and 3 girls) with 44 hernias, age 2 weeks to 35 months. Weight was between 2000 g and 14 kg (average 5.860 g). There were 16 bilateral, 4 left- / 8 right-sided hernias. In 8 cases a contralateral open processus vaginalis was found and closed. Duration of operation was 13 to 40 minutes (average 20 minutes) for one side and 20 to 80 minutes (average 37 minutes) for both sides and correlated with growing experience and weight of the children. There were no perioperative complications.
The procedure was very well tolerated by patients and parents.
Our approach leaves almost ?invisible? scars (two dot-like scars in the upper abdomen and the umbilical 2mm-approach).
Conclusions:
Our very first results show excellent cosmetic results and a safe repair of inguinal hernia. Follow-up will show rate of recurrence clinically and in ultrasound examination. It will also verify the cosmetic results rated by parents and us. Testicular volume and perfusion will be examined by ultrasound.
Whether laparoscopic is as safe as a conventional repair has to be answered in a further prospective study.

S039 Short Poster

INTRACORPOREAL TAUTLINE KNOT: A FAST METHOD TO SECURE A LAPAROSCOPIC CONTINUOUS SUTURING,
Peter KF Yip,* Paul KH Tam,Michael KW Li, Department of Surgery, Pamela Youde Nethersole Eastern Hospital, *Division of Paediatric Surgery, Department of Surgery, Queen Mary Hospital, Hong Kong

Introduction:
Laparsocopic intracorporeal knotting is technically demanding and physically exhausting to a surgeon. For those operations involving continuous sutures including laparoscopic pyeloplasty and hepaticojejunostomy, the instrument knotting can be very difficult at the end of suturing, especially when the remaining thread is short. We apply a common and easy knotting technique to secure the suturing and save time and effort of instrument knotting.
Method:
After a laparsocopic intracorporeal continuous suturing, a sliding Tautline knot of 3-4 throws is fashioned with the needle and thread. Technically it is easy and applicable even the remaining thread end is very short and conventional surgeon knotting becomes difficult. The knot is fasten simply by pulling the end of thread and becomes secure. The strength of tying is adequate for any low-pressure hollow organ including renal pelvis, bowel or biliary duct, and the flip flap anchorage in the laparoscopic hernioplasty. For extra strength an additional throw of knot can be added over the Tauline knot.
Conclusion
This technique benefits those laparoscopic surgeries requiring continuous suturing, and those operations requiring knotting in a limited space. It is our knotting method of choice after a laparsocopic continuous suturing in children.

S040 Short Poster

VIDEO-ASSISTED LAPAROSCOPIC PROCEDURES IN PERITONEAL DIALYSIS CATHETER MALFUNCTION,
E. Cesca MD, P. Betalli MD,F. Fascetti Leon MD,B. Andreetta MD,G.F. Zanon MD,P.G. Gamba MD, University of Padoua, Italy-*Division of Pediatric Surgery, § Paediatric Dipartiment

Objective: Laparoscopic surgical techniques can be used for peritoneal dialysis (PD) catheter placement or for revision of dysfunctional catheters with outflow obstruction. Correction involves catheter replacement or revision via laparotomy. There are few reports about laparoscopic management of peritoneal dialysis catheters. The purpose of this study is to analyse the cases of peritoneal catheter revision or replacement with mini-invasive techniques performed in our Centre.
Methods: Data about patients (demographics, diagnosis, operative management and outcome), undergone laparoscopic peritoneal catheter revision or replacement in our Department of Paediatric Surgery since June 99 to December 2004, were reviewed in a retrospective study.
Results: In our institution, laparotomic peritoneal catheter insertion is routinely adopted (June 1999- December 2004: 55 peritoneal catheter

inserted). Four patient (3F, 1M), mean age 9 years (1-16 years), underwent laparoscopy for catheter revision or replacement.
PD was adopted in two patients with congenital renal dysplasia, in one patient with nephrotic syndrome and in one patient with vesicoureteral reflux. The cause of the catheter's malfunction was: obstruction in two patients and dislodgement in the other two cases.Two dysfunctional catheters were just revised by adesiolysis and partial omental resection was performed. Two catheters were removed (both with in and out-flow problems and tunnel infection) and a new catheters were easily placed under laparoscopic vision.The two catheters revised by adhesions subsequently failed because of dislodgement and were replaced with open procedures one the day after and one month later respectively. The two catheters removed and reinserted didn?t have any following problems. The mean operative time was 60 minutes, no major complications occurred, no conversion to open procedure. In all cases PD started the day after surgery.
Conclusions: Videolaparoscopy proves to be a useful tool in a PD programme, not only for catheter insertion but also for diangnosis and rescue of catheter dysfunction. In our experience laparoscopic technique is a safe procedure, indicated as first approach in catheter dysfunction. Replacement of a new catheter seems to be a more successful technique than the simple revision of the old one.

S041 Short Poster

A SURVEY OF STERILIZATION TECHNIQUES FOR RE-USABLE LAPAROSCOPIC INSTRUMENTS, B. Banieghbal MD, CH Baragwanath Hospital, Johannesburg, South Africa

Aim: With increasing popularity of laparoscopic operations, sterilization is becoming an increasing concern especially in countries in which prohibitive cost of disposable instruments by and large exclude their usage. More affordable re-usable instruments are used extensively world-wide but only a few companies provide fully auto-clavable instruments. There is concern that proper sterilization techniques are thus not followed for the more commonly available rubber/plastic coated re-usable instruments.
Method: The largest private and government hospitals in South Africa were contacted and OR nurses in-charge of laparoscopic surgery were questioned telephonically and subsequently verified with written questionnaires. Specifically; techniques of re-usable hand instrument sterilization were sought for and detailed enquires were made of Gluteraldhyde usage.
Results: A total of 24 hospitals are included in this study: Only 3 hospitals used autoclave or Ethylene Oxide gas sterilization exclusively. In 10 hospitals; Gluteraldhyde soaking for 10-20 minutes is used exclusively. In 11 hospitals; the instruments are sterilized with gas (2) or autoclave (9) for the first case of the day. If there is any subsequent laparoscopic operations planned for that day, soaking with Gluteraldhyde is also used. Gluteraldhyde soak time was from 5-20 minutes. More disconcerting is that in all these hospitals, OR nurses believe that full sterilization is accomplished in 10-20 minutes of Gluteraldhyde soak time.
Conclusion: Gluteraldhyde ?sterilization? of laparoscopic hand instruments appears to be the standard practice in almost all OR rooms in South Africa. Gluteraldhyde solution need a soak time of 6-10 hours for proper sterilization, depending on the preparation. 10-20 mins soak only provides a highly disinfected instrument.
A disturbing scene is shown in this report, which underscores a relative lax attitude about sterility of laparoscopic equipment. The root of the problem is the plastic covering for these instruments which excludes autoclaving and possibly a ?minimally access mind-set? that somehow has influenced surgeons and OR nurses alike that full sterilization is not quite required for these instruments as the surgery is after all ?minimally access?.
A complete guideline for proper sterilization of laparoscopic instruments is urgently needed and requested from IPEG committee.

S042 Short Poster

ND:YAG LASER ENDOSCOPIC TREATMENT FOR RECURRENT TRACHEOESOPHAGEAL FISTULA: PROMISING RESULTS., Jose L Peiró MD, Claudia Marhuenda MD,Josep Lloret MD,Carles Giné MD,Antonio Moreno MD,Vicen Martínez-Ibáñez MD, Department of Pediatric Surgery. Hospital Vall d?Hebrón. Barcelona. Spain.

INTRODUCTION: Tracheoesophageal fistula (TEF) may appear as congenital H-type or as a complication of 10 % of repaired esophageal atresia. Surgical approach of TEF represents a thoracotomy and high rate of recurrences. Several endoscopic treatments with adhesives substances have been used without satisfactory results. Our aim is obtain optimal results in TEF closure by means of Nd:YAG laser endoscopic treatment.
METHODS: From May 2003 five patients with recurrent TEF after esophageal atresia repair were treated endoscopically with Nd:YAG laser using a rigid ventilating bronchoscope and flexible bronchoscope in one case. After visualization of TEF hole in the membranous side of the tracheal lumen, a 600 microm fiber is passed through the bronchoscope work channel. Laser fiber is inserted into TEF at 30 watts in continuous pulse to burn and destroy TEF mucosal lining, until TEF obliteration is observed. After 1 month a radiological contrasted esophagogram is performed to check TEF closure.
RESULTS: Five patients with recurrent were treated, 2 boys and 3 girs, at ages between 2 months and 11 years. Rigid bronchoscope was used in 4 cases (sizes 3 to 5) and flexible in one because difficult oral oberture. No intra or postoperatory complications were presented. Presently, 3 cases have radiological confirmation of TEF closure and 2 cases are pendent of radiologic study and a second laser treatment. The succesfully cases needed 1,3 and 2 sessions to achieve TEF closure. Contrast radiologic control examination shows obliteration of the fistula, but a esophageal little pouch can be present. Patients follow-up was 2 months, the earlier, to 2 years.
CONCLUSIONS: Nd:YAG laser endoscopic treatment for closure of recurrent TEF is a simple, safe, minimally invasive procedure, that permits multiple and repeated applications. Although more cases are needed, this endoscopic treatment seems to be very effective for TEF obliteration.

S043 Short Poster

LAPAROSCOPIC CUTDOWN TO THE INFERIOR EPIGASTRIC VEIN : ANOTHER ACCESS TO THE CENTRAL VENOUS SYSTEM IN A PARENTERAL NUTRITION DEPENDANT PATIENT, Paul PHILIPPE MD, Monika GLASS MD, Paediatric Surgery, Centre Hospitalier de Luxembourg, Luxembourg

Aim : to report a new technique in vascular access for long term parenteral nutrition
Method : case report
Description : We report the case of a seven years old child with a chronic intestinal atrophy and malabsorption syndrome secondary to an immunologic syndrome of unclear aetiology, on total parenteral nutrition since birth.
Eleven various long term access (percutaneous lines or implanted chambers) had been lost to infections or occlusions. He presented with subacute infection of his 12th implanted port, not responding to long term antibiotics. Echocardiography demonstrated clots in the superior vena cava and right atrium, that did not respond to fibrinolysis. Explantation was unavoidable.
The superior caval system could not be catheterised because of the clots. The inguinal areas were unavailable because of severe diaper rash secondary to his chronic diarrhoea.
By laparoscopy, using a 3mm telescope in the umbilicus and 2 3mm ports, the right inferior epigastric vein was isolated close to its junction with the iliac vein. Using a Bard 5Fr catheter introducing kit ?, the vein was catheterised with the needle introduced percutaneously and extraperitoneally, and a guide wire advanced.. Using the peel-away introducer, a 4.2Fr Broviac (Bard ?), tunnelled on the anterior abdominal wall, was advanced to the most distal part of the inferior vena cava under fluoroscopic guidance.
The procedure was completed in less than 30 minutes and was well tolerated.
The patency of the inferior vena cava was demonstrated by Doppler ultrasound at 6 and 12 month.The catheter had to be removed after 19 month because of infection, and was replaced by a subclavian cathter.
Conclusions : We conclude that this technique offers another alternative to gain central venous access in difficult cases, when the traditional routes are unavailable.

S044 Short Poster

LAPAROSCOPIC REPAIR OF CONGENITAL DIAPHRAGMATIC DEFECTS IN CHILDREN, Nabil M Dessouky BS, Pediatric Surgical Division, the Specialized Children's University Hospital

Background:
Surgical procedures are frequently performed on the diaphragm in children. The development of video-assisted surgery brought about a significant change in the surgical repair of these diaphragmatic conditions.
Material and Methods:
Cases with congenital diaphragmatic defects presented over a period of a year had undergone an attempt at minimally invasive surgical repair. Candidates for laparoscopic correction were children having mild symptoms with good respiratory and haemodynamic conditions.
Results:
The study included twelve cases with congenital diaphragmatic defects: three Morgagni hernias with a large part of the liver also herniating into the sternocostal hiatus (Larry hernia) in one case; four Bochdalek hernias(all of them were left-sided) and five cases of esophageal hiatus hernia, one of these was a large hernia of the mixed sliding/ paraesophageal type. Their ages varied between 7 ? 32 months with a mean of 16 months.
Four ports were used for laparoscopic access in most of the cases except in the hiatal hernias where a fifth was added. All the herniated viscera were repositioned into the abdomen. Laparoscopic repair was successful in all cases except one case which was converted to open surgery. Dacron mesh was only used in the case of Morgagni-Larry hernia. Nissen fundoplication was performed for all hiatal hernias. Injury to the pleura occurred in one case of hiatus hernia. There was no recurrence with a follow-up period of 4-11 months.
Conclusion
Under specific conditions, laparoscopy can be an effective and more advantageous alternative to laparotomy for congenital diaphragmatic defect in children. A longer follow-up period is needed for evaluation of the technique.

S045 Short Poster

LARGE THORACOSCOPIC PERICARDECTOMY FOR PURULENT PERICARDITIS: EXPERIENCE WITH 20 CASES, Liem T Nguyen PhD, Tuan M To MSc,Dung A Le MD, National Hospital of Pediatrics, Hanoi, Vietnam

OBJECTIVE: to present our experience in performing thoracoscopic pericardectomy for purulent pericarditis in 20 children.
METHODS AND PROCEDURES: Patient was placed in right lateral position. Pericardectomy was carried out using one optical trocar and two operating trocars. Pleural insufflation with carbon dioxide was maintained at 2 to 4mmHg pressure. Anterior pericardectomy was performed from the left phrenic nerve to the right border of the sternum to free the anterior part of the heart, notably the cardiac apex and the original area of the great vessels. Purulent debre were removed prior to detaching the epicardial peel.
RESULTS: This study included 20 patients. The mean age was 8.5 years. The time from onset of the disease to surgery ranged from 7 to 34 days (average 16 days). Operation time ranged from 50 to 150 minutes (average 90 minutes). There were no intraoperative or postoperative complications. All cardiac tamponade symptoms disappeared immediately after operation. Follow-up 4-15 months after surgery showed normal clinical manifestations and chest x-rays in all children.
CONCLUSIONS: Thoracoscopic pericardectomy is feasible and safe for purulent pericarditis. The technique provides minimal trauma to the patient, less pain, quicker recovery and better cosmetic result than open operation.

S047

EXPERIENCE WITH 125 CONSECUTIVE PEDIATRIC THORACOSCOPIC LOBECTOMIES, Craig T Albanese MD, Steven S Rothenberg MD, Lucile Packard Children's Hospital; Stanford, California and Presbyterian/St. Luke's Hospital, Denver, Colorado

Objective: The early experience with the technique and short-term outcomes after pediatric thoracoscopic lobectomy were independently reported by the authors several years ago. This report updates their combined experience, evaluating the safety, efficacy, and longterm outcomes.
Methods: From January 1995 to September 2004, 125 consecutive patients underwent thoracoscopic lobectomy. Preoperative diagnoses included cystic adenomatoid malformation/sequestration (n=97), bronchiectasis (n=17), lobar emphysema (n=8), and malignancy (n=3). Ages ranged from 2 days to 18 years, weight from 2.8 to 78 kgs. Three or 4 valved ports were used with controlled pneumothorax. Single lung ventilation was used in all. Follow-up ranged from 3 months to 9 years.
Results: All but 2 procedures were completed thoracoscopically; one was converted to repair an injured upper lobe bronchus during a lower lobectomy and another due to what was believed to be a potentially inadequate margin during resection of a large tumor. Operating time ranged from 35 to 220 minutes. There were 95 lower, 22 upper and 8 middle lobe resections. There were 4 postoperative complications; pneumonia, pneumothorax, empyema, and prolonged chest tube drainage. There were no reoperations. Median hospital stay was 2.8 days. Longterm follow-up revealed no cases of musculoskeletal deformity at the operative sites.
Conclusion: Present techniques and equipment allow complete thoracoscopic resection of pulmonary lobes in any age/size child with low morbidity and no mortality. Longterm outcomes support the efficacy of this technique that spares growing children a thoracotomy that has potential for late musculoskeletal morbidity.

FRIDAY

S048

THORACOSCOPIC REPAIR FOR CONGENITAL DIAPHRAGMATIC HERNIA: EXPERIENCE WITH 45 CASES, Liem T Nguyen PhD, Dung A Le MD, National Hospital of Pediatrics, Hanoi, Vietnam

OBJECTIVE: to describe the surgical technique and results of thoracoscopic repair of congenital diaphragmatic hernia (CDH) in 45 children.
METHODS AND PROCEDURES: Patient was placed in lateral position. The operation was carried using one optical trocar and two operating trocars. Pleural insufflation with carbon dioxide was maintained at 2 to 4mmHg pressure. The hernia defect was repaired using non-absorbable interrupted sutures with extracorporeal knots.
RESULTS: 45 children underwent thoracoscopic repair for CDH by the same surgeon from January 2001 to December 2004. There were 19 newborns and 26 children above 30 days old. The hernia was located in the left side in 37 children and in the right side in 8 children. The mean operative time was 54 minutes. There was minimal blood loss during operation. Conversion was required in 4 cases. There were no operative and postoperative complications. Two newborns died on the second and third postoperative day. The mean postoperative hospitalization was 4.6 days.
CONCLUSION: Thoracoscopic repair is feasible and safe. It could be applied not only for children but also for newborns.

S049

THORACOSCOPIC REPAIR OF OESOPHAGEAL ATRESIA ? THE UK EXPERIENCE, Gordon A MacKinlay MD, Gregor M Walker MD,Fraser D Munro MD,Hugh W Grant MD,Stephen R Potts MD, The Royal Hospital for Sick Children, Edinburgh, The Radcliffe Infirmary, Oxford and The Royal Belfast Hospital for Sick Children

Objective
The first successful thoracoscopic division of a tracheo-oesophageal fistula and repair of oesophageal atresia was reported by Rothenberg in 2000. We report the first 12 cases attempted in UK.
Method
We reviewed the first 12 cases attempted in 3 paediatric surgical units in UK. 10 were performed in one unit and the others in two separate centres. We describe the evolution of the surgical technique and the outcomes to date for those patients in whom a primary thoracoscopic repair of oesophageal atresia was achieved. Two of the 12 patients had isolated oesophageal atresia.
Results
In the first case, a 1.6 kg newborn, division and ligation of the fistula was achieved but primary oesophageal repair proved impossible due to a right sided aortic arch and vascular ring not recognised on pre-operative echocardiography. The baby proved to have Trisomy 18 and further surgery was not undertaken. A further 9 cases in the same unit had successful completion of surgery.
The azygos vein was clipped in 2 cases, coagulated using bipolar forceps in 7 more and left intact in one. The fistula was clipped in 3 cases and suture-ligated in the remainder. Oesophageal anastomosis was achieved with 5/0 vicryl and intracorporeal knotting. One case showed a radiological, but not clinically apparent, leak. This was treated conservatively but a subsequent fistula between the trachea and a peripheral bronchus needed thoracotomy. One infant required balloon dilatation for a minor anastomotic stricture.
One baby in another unit underwent successful division of the TOF but failure to maintain lung collapse necessitated thoracotomy to achieve oesophageal anastomosis.
A case of isolated oesophageal atresia in another unit was successfully repaired under tension, but complicated by a postoperative anastomotic leak (managed conservatively) and stricture, which required dilatation.
Conclusion.
Thoracoscopic repair of oesophageal atresia can be achieved safely with a favourable early outcome. As expertise in thoracoscopy develops hopefully more centres will adopt this approach with its cosmetically excellent results.

S050

ADRENALECTOMY IN CHILDREN: THE ROLE OF MINIMALLY INVASIVE SURGERY, Piero Romano MD, Luigi Avolio MD,Giuseppe Martucciello MD,Henry Steyaert MD,Jean S Valla MD, Department of Pediatric Surgery, IRCCS Policlinico San Matteo, Pavia, Italy - Fondation Lenval pour Enfants, Nice, France

Introduction: The development of laparoscopic surgery has extended its indications to include adrenalectomy in children as well as in adults. Since conventional adrenalectomy requires a large incision, minimally invasive surgery offers a less aggressive solution in some selected cases.
Methods and procedures: Patients treated in two different hospitals were evaluated retrospectively. 25 adrenal masses in 24 children (9 girls, 15 boys) were treated by adrenalectomy from 1993 to 2004: 1 hyperplasia, 2 pheocromocitomas and 21 neuroblastomas with different biological aspects. Patients were aged 1 month to 14 years (mean age 45 months). Lesions were right sided in 13 children, left in 10 and bilateral in 1. Preoperative radiological investigations showed a well-delimited lesion in 12 cases; there was local diffusion in 5 (neuroblastoma stages 2B and 3) and 7 were metastatic neuroblastomas (stages 4 and 4S). Lesions ranged in size from 2 to 30 cm.
Minimally invasive procedures were performed on 8 children: in 3 patients it was adopted to perform a biopsy whereas in the remaining 5 adrenalectomy was done. In 7 cases procedures were performed through a retroperitoneal approach, while in the others a transperitoneal biopsy was done. Minimally invasive procedures were limited to the removal of small localized adrenal tumors and to biopsies.
Results: No major early complications were observed either in open or in minimally invasive surgery. Three patients died (stage 4) and 3 others are still on therapy. Follow-up on the living children has not yet been not enough long to consider them free from disease.
Conclusions: The potential advantages of minimally invasive adrenalectomy in children are similar to those reported for other applications of laparoscopic surgery (small incision, decreased postoperative pain, quicker discharge). This approach must be limited to operations on lesions presumed to be benign but preoperative criteria of non malignancy are often difficult to define. Indications can be expanded to include to non-secreting stage I neuroblastoma, and, for some surgeons, to stage 4S tumors. There seems to be no age and weight limit. The technique applied varies in accordance with anatomy and the surgeon's experience: minimally invasive adrenalectomy, in our experience, was preferentially performed through a lateral retroperitoneal approach. The lesion must have a reasonable size (diameter inferior to 50mm) and well-defined limits in preoperative Xrays.

S051

VIDEO-ASSISTED SURGERY OF ABDOMINAL CAVITY IN PAEDIATRIC ONCOLOGY., Przemyslaw Mankowski MD, Andrzej Jankowski MD,Pawel Kroll, Dept. of Paediatric Surgery, Traumatology and Urology,

Purpose: The aim of the work is to estimate the usefulness and invasive propensity of video-assisted surgery in diagnosing and treatment of oncological diseases of abdominal cavity in children.
Material and methods: There were 48 laparoscopic procedures performed in 46 children treated with oncological diseases in Dept. of Paediatric Surgery in Poznan between March 1998 and July 2004. The average age of patient was 8.4 years and the Body Mass Index (BMI) was 17.0.
In 19 cases the diagnostic biopsies were only performed and in 29, the videoscopy technique was used in order to remove the abdominal tumors. The laparoscopic method was useful in operating of 31 patients and the open surgery with help of video technique (VATS) was performed in 17 children. The invasive propensity (CRP, IL-6, time of hospitalization, etc.) and usefulness of videoscopy in paediatric surgery were analysed.
Results: According to our experience, we can ascertain that the videoscopy allows to perform many kinds of diagnostic and threrapeutic procedures in children as well as wide inspection of abdominal cavity with minimal operative trauma. There were no post-operative significant complications observed in any patient. The operation results and the post-operative courses were satisfactory and did not negatively caused the treatment of main diseases.

S052

MINIMALLY INVASIVE VIDEO-ASSISTED THYROIDECTOMY IN YOUNG PATIENTS: REPORT OF 24 CASES, C Spinelli MD, A Berrettini MD,M Ghionzoli MD,S Gozzini MD,P Miccoli MD, Cattedra di Chirurgia Pediatrica, Università di Pisa

Methods: From October 1998 to December 2004 in the Department of Surgery at the University of Pisa, 24 patients ages 18 years or younger (20 girls, 83.3% and 4 boys, 16.7%; range, 11 to 18; mean age, 15 years, 10 months) underwent a surgical operation with video-assisted technique for thyroid pathology. Surgical therapy with video-assisted technique was chosen; a lobectomy was used in 16 cases (66.7%) and a total thyroidectomy in 8 case (33.3%).
Results: The histologic examination found benign pathology in 16 cases (66.7%) and a malignant lesion (papillary type) in 8 cases (33.3%). No postoperative complications were observed.
Conclusions: The results of the mini-invasive video-assisted technique for thyroidectomy in this preliminary experience seem to be equal to those of the traditional open surgical technique. Elective indications of the mini-invasive video-assisted technique are the volume of the nodule and histological type; this technique cannot be used in cases of voluminous goiter, medullary carcinomas and poorly differentiated carcinomas. The advantage that this technique offers, in addition to a better postoperation period, is an improved esthetic result, which is particularly important in young patients.
References:
1.Spinelli C et al. Minimally invasive video-assisted thyroidectomy. Pediatric Endosurgery & Innovative Techniques, Vol 7, No 2, 2003
2.Spinelli C et al. Minimally invasive video-assisted thyroidectomy: Report of 16 cases in children older than 10 years. J Ped Surg, Vol 39, No 9, 2004

S053

COMPLETE SUBCUTANEOSCOPIC HARVEST AND TRANSPOSITION OF LATISSIMUS DORSI MUSCLE FOR THE TREATMENT OF POLAND's SYNDROME. A SURGICAL FIRST., Marcelo Martinez-Ferro MD, Carlos Fraire MD,Aixa Reussmann MD, National Children's Hospital "J.P.Garrahan". Buenos Aires

Purpose: Although endoscopically assisted harvest of free latissimus dorsi muscle flaps is being used more frequently, after harvesting, an open techinque is needed to suture the muscle into its new position. No report of a complete subcutaneoscopic transposition of this muscle has been published. Our purpose is to describe in detail the evolution of a new, completely endoscopic technique, determine its advantages, disadvantages, and complications, and discuss the vast potential of this approach for other frequent pediatric surgical diseases.
Methods: From January 1996 to December 2004, 120 patients with Poland's Syndrome were evaluated at our institution, and 18 required a latissimus dorsi muscular flap for reconstruction of the chest deformity. The last three cases were endoscopically approached. The technique evolved from a 3 trocar harvest of the muscle combined with an axilary incision for muscle fixation in the first two cases, to a 6 trocar approach with CO2 insufflation of the subcutaneous space in our last patient. Initially a custom made balloon performs the subcutaneous dissection and creates the optical work space that permits the insertion of all the working ports. Latissimus dorsi harvesting is performed with a monopolar hook. The patient is rotated anteriorly and an additional subcutaneous pocket is performed in the anatomic space normally occupied by the pectoralis major. A tunnel connecting both pockets is created. The graft is dragged and passed through the tunnel and rotated to its new position. Under endoscopic vision, the muscle is sutured to the fascia overlaying the lateral sternum and the clavicle.
Results: Operative time was 360 minutes (300 to 420 minutes). No intraoperative complications were observed. One patient (case 2) presented postoperative pneumothorax that was drained on the 4th postoperative day. No further complications were observed and all the patients recovered uneventfully.
Cosmetic results are excellent in all patients.
Conclusions: Complete subcutaneoscopic latissimus dorsi transposition can be safely performed in patients with Poland Syndrome. Advantages of this approach include excellent cosmetic results and the precise visualization and mobilization of the vascular pedicle. Following this concept, many pediatric surgical diseases (eg: congenital torticollis, subcutaneous tumors, cervical tumors, etc.) should be easily approached by minimally invasive techniques.

S054

AN INNOVATIVE MINIMALLY INVASIVE TREATMENT FOR SCOLIOSIS IN CHILDREN: VERTEBRAL BODY STAPLING USING SHAPE MEMORY ALLOY (NITINOL), Harsh Grewal MD, Randal R Betz MD,Linda P D'Andrea MD, Section of Pediatric Surgery, Temple University Children's Medical Center and Orthopedic Surgery, Shriners Hospitals for Children, Philadelphia

Introduction: In skeletally immature children with progressive scoliosis (less than 50 degrees) vertebral body stapling of the convex side of the anterior spine may keep the curve from progressing while preserving movement and flexibility and provide a better alternative to bracing or fusion.
Objective: To describe a minimally invasive technique of vertebral body stapling using a shape memory alloy (NITINOL) staple for the treatment of scoliosis in children.
Methods: A retrospective review of patient records, operative records and radiographs of children undergoing vertebral body stapling. Thoracic curves were stapled using a thoracoscopic technique with single lung ventilation and fluoroscopic control, usually requiring 3 to 4 portals. Lumbar curves were stapled using a mini-incision retroperitoneal exposure with fluoroscopic control.
Results: A minimally invasive vertebral body stapling was performed in 46 children with 62 curves (thoracic-40, lumbar-22). 16 children had double curves stapled. The curves stapled ranged from T4-L4. Usually 2-3 staples were used at each level. All children had their curves successfully stapled without any intra-operative neurological injuries. Mean estimated blood loss was 255 ml (50-1500ml, 1500 ml loss was in case 1). Postoperatively there were 6 complications (chylothorax-1, pancreatitis-1, diaphragmatic hernia-1, atelectasis-3). None of the staples were dislodged, there was one broken staple, and none of the staples moved. In one patient staples were removed because of persistent pain. Preliminary results reveal stability of curves (within 10 degrees) in 87% of the adolescent idiopathic scoliosis patients at one year.
Conclusion: An innovative minimally invasive treatment for scoliosis in children utilizing vertebral body stapling appears to be a safe alternative to bracing or fusion in skeletally immature children with idiopathic scoliosis.

S055

INTRACORPOREAL, ROBOTICALLY-ASSISTED MANAGEMENT OF CHOLEDOCHAL CYST: ANALYSIS AND DEMONSTRATION OF TECHNIQUE FROM THE LAB TO THE OPERATING ROOM, Michael S Irish MD, Thane Bliman MD,Steve Rothenberg MD, Blank Children's Hospital, Des Moines, IA & Presbyterian-St. Luke's Hospital, Denver, CO

Introduction: Reports of robotically assisted minimally invasive surgery (RMIS) have increased over the last several years. Few reports of robotically-assisted surgery in pediatric patients have addressed the management of choledochal cysts. We present our initial RMIS experience in the laboratory and in an adolescent patient. We discuss technical considerations, advantages and disadvantages of robotically-assisted, completely intracorporeal, choledochal cyst resection with Roux-Y reconstruction and enteroenterostomy.
Materials & Methods: Intracorporeal, CBD resection, Roux-Y choledochojejunostomy and enteroenterostomy was performed in 2 piglets (wt.<5kg) in a feasibility study of RMIS for management of choledochal cysts in humans. Both animals were immediately sacrificed to evaluate the anastamoses. The same procedure was performed on a 17y/o female with a type I choledochal cyst. The da Vinci? Surgical system was used for all procedures.
Results: In the piglets, these procedures took 100 and 110 minutes respectively. The procedure for our patient took 4 hours to complete. No intraoperative complications were encountered. Anastamoses in the piglets were found intact upon sacrifice. In our patient, on the first postoperative day, a significant bile leak was diagnosed and reoperation revealed the leak in the posterior aspect of the choledochojejunostomy. This was repaired and the patient has remained well at six month follow-up.
Conclusion: RMIS can offers advantages over conventional minimally-invasive surgery including articulating instruments enabling more precise, intracorporeal tissue manipulation and suturing, 3-dimensional vision and intuitive ergonomics. In the management of choledochal cyst, we found these advantages helpful in completing this complex procedure without the need for extracorporeal enteroenterostomy.

S056

ROBOTIC SURGERY IN INFANTS AND NEONATES, John J Meehan MD, John Lawrence MD,Laura Phearman RN,Paula Francis RN,Anthony Sandler MD, The University of Iowa Hospitals and Clinics - Children's Hospital of Iowa

Purpose: Robotic technology has become another valuable tool in minimally invasive surgery. One criticism of the equipment is the relative size of the trocars. Additionally, the extra length required to articulate the movement of the instruments may limit their usefulness in the smaller chest and abdomen of a neonate or infant. We retrospectively reviewed our experience with robotic surgery in children less than 10 kg in size.
Methods: A total of 11 procedures were attempted in 11 children including 6 fundoplications (55%), 2 intraabdominal neuroblastoma resections (18%), 1 Kasai portoenterostomy (9%), 1 congenital diaphragmatic hernia repair (9%), and 1 resection for a CCAM (9%). Two procedures were performed in the chest (18%) and 9 in the abdomen (82%). The children weighed 2.5 to 9.6 kg with an average weight of 6.4 kg. Initially, only a 12 mm camera and 8 mm instruments were available for use. Later, a set of 5 mm instruments and a 5 mm camera were introduced. Results: Nine of 11 patients (82%) had their procedure successfully completed using robotic instruments. The smallest child to have their operation completed robotically was 2.7 kg. Two patients did not have their procedure completed with the robot. A 2.5 kg child with a CDH did not have an adequate intrathoracic domain for the articulating movement of the robotic instruments and was repaired thoracoscopically. In the child with the CCAM (7.7kg), we were not confident with the anatomy and converted this operation to an open procedure. No intra-abdominal space issues arose in the remainder of the patients as the Kasai, both neuroblastoma resections, and all 6 fundoplications were completed using the robot. We used the 8 mm instruments in 5 patients (45%) and the 5 mm instruments in 6 (55%). Additionally, we used the 3-D 12 mm camera in 6 patients (55%) and the 2-D 5 mm camera in 5 patients (45%). We had no trouble maintaining insufflation in any patient irregardless of the port size or patient size. Suturing and knot tying were not limited by the small intraabdominal domain and was felt to be significantly easier than using standard laparoscopic instruments.
Conclusion: Robotic surgery can be safely accomplished in small children, particularly neonates and infants. The intrathoracic domain of some neonates may still be limiting factor. Further studies are required to determine the potential boundaries of robotic surgery for infants and neonates.

S057

ROBOTICALLY-ASSISTED THORACIC PROCEDURES IN INFANTS AND CHILDREN, Dra. Natalia E Tamburi, Michael S Irish MD,Onyebuchi Ukabiala MD,Thom E Lobe MD, Blank Children's Hospital, Des Moines, Iowa, USA

Purpose: Minimally invasive, robotically-assisted thoracic surgery in pediatric patients is evolving with the advancement of technique and refinement of smaller instruments. Our purpose is to evaluate the use of robotic surgical systems in the management of various surgical conditions in infants and to determine any advantages, disadvantages, and complications.
Methods: From April 2003 to December 2004 we performed robotically-assisted thoracic procedures in 9 male patients with a mean age of 5.3 years (range 4 days to 23years), and a mean weight of 19.6kg (range 3.8 to 70kg) using the da Vinci(TM) system (Intuitive Surgical, Sunnyvale, CA) (7 cases) and the Zeus(TM) system (Computer Motion, Goleta, CA) (2 cases). The indications were: mediastinal mass (2), bronchogenic cyst (3), sequestration (1), bronchiectasis with Kartagener's Syndrome (1), myasthenia gravis (1) and esophageal atresia with tracheoesophageal fistula (TEF) (1) . The operations performed included: excisional biopsy of mediastinal mass (2), bronchogenic cyst resection (2, primary, 1 recurrent), lobectomy for bronchiectaisis (1), resection for sequestration (1), thymectomy (1), and repair of a TEF (1).
Results: Two procedures required open conversion. One, in the case of lobectomy for bronchiectasis, where the hilar anatomy could not be safely dissected, and another in the primary resection of a bronchogenic cyst where suboptimal port placement made dissection of the mediastinum difficult. All other procedures were completed robotically. Pneumothorax requiring tube thoracostomy in the thymectomy patient was the only complication. Mean length of hospitalization was 3.6 days (range 1 to 7 days)
Conclusions: Robotically-assisted thoracoscopic procedures can be safely performed for a variety of pathologies in patients as small as 3.8kg. Advantages of this technology include the increased range of motion of robotic instruments imparting the ability to perform delicate and precise procedures in small spaces. Currently, the use of a 5mm camera sacrifices the advantage of 3-dimensional vision available to the surgeon with the larger 1.0 cm camera but does not appear to be a limitation in the small working space of an infant's chest. The need for conversions to thoracotomy due to poor port placement should improve as more experience is gained.

S058

EXPERIENCE WITH DA VINCI ROBOT-ASSISTED PROCEDURES IN CHILDREN, Aayed R Alqahtani MD, Abdulrahman Albassam MD, College of medicine & King Khalid university Hospital, Riyadh, Saudi Arabia

Minimally invasive approaches for surgical intervention in pediatric patients continue to develop both in technical complexity and equipments. Recently robot-assisted surgery has been introduced and continues to find its place in minimal access surgery.
Here, we report our experience with Da Vinci robot-assisted procedures in pediatric patients.
Methods
This is a retrospective review of all children who underwent Da Vinci robot-assisted procedures between June 20004 and December 2004. Data collected included setup time, operating time, and outcomes.
Results:
19 patients were included (10 girls, 9 boys) with an average age of 10 years (range: 4 to 20 years). There were 6 cholecystectomies, 4 Nissen fundoplcations, 3 gastric banding, 2 interval appendectomies, one splenectomy and cholecystectomy, one heller myotomy, one adrenalectomy, and one thoracic sympathectomy. All cases were completed successfully except one. All had uneventful postoperative course.
Conclusion:
Our experience with this procedure have shown the additional advantages of computer-enhanced robot-assisted surgery. We recognized the improved degree of freedom, tremor filtration, and an excellent three dimensional visualization. With more team experience, the time required for the system and the operating room setup has decreased significantly.

S059 Short Poster

THE SINGLE INSTRUMENT PORT LAPAROSCOPIC (S.I.M.P.L.) NEPHRECTOMY, Imran Mushtaq MD, Mohan Gundeti MD, Great Ormond Street Hospital and Guys Hospital

Purpose:To describe a novel modification of the posterior prone retroperitoneoscopic nephrectomy/nephroureterectomy, which allows the entire procedure to be performed through a single instrument port.
Method:With the patient in the prone position a retroperitoneal working space is created with the aid of a homemade balloon. A single instrument port is then placed at the tip of the 11th/12th rib under direct vision. Gerota's fascia is incised adjacent to the posterior abdominal wall to enter the peri-nephric space. The kidney is identified and mobilised by blunt dissection on the postero-medial aspect to reveal the hilar vessels. The hilar vessels are controlled and divided between clips or with a harmonic scalpel. The ureter is identified distally and mobilised as far as possible before division. The proximal ureter and remaining surface of the kidney are freed from surrounding attachments. The specimen is removed directly by the camera port or in an endobag.
Result:We have employed this technique in 25 children of varying ages with good success. In three children bilateral synchronous procedures were performed. There have been no complications or conversions and the cosmetic outcome has been excellent. The operative time is not significantly prolonged.
Conclusion:The S.I.M.P.L. nephrectomy is a feasible and safe technique for the experienced paediatric laparoscopic surgeon.

S060 Short Poster

RETROPERITONEOSCOPIC ADRENALECTOMY: AN EARLY INSTITUTIONAL EXPERIENCE., Pedro-Jose Lopez MD, Agostino Pierro PhD,Curry Joe MD,Mushtaq Imran MD, Departments of Paediatric Urology and Paediatric Surgery, Great Ormond Street Hospital, London

INTRODUCTION: The retroperitoneoscopic approach is rapidly becoming the procedure of choice for paediatric adrenalectomy. The rapid access to the vascular pedicle makes this access ideal for adrenal surgery where haemodynamic instability is a common feature. Our aim is to review our initial experience with this technique.
METHOD: Patients were placed in a fully prone position and the location of the 12th rib iliac crest and paravertebral muscles were marked. An incision was made lateral to the para-vertebral muscle and half way between the iliac crest and costal margin. Blunt dissection proceeded to the space outside Gerotas fascia. A retroperitoneal working space is created around the kidney with the aid of a home made balloon. A 10 mm Hasson port was then inserted. A 5mm working port was placed lateral to the tip of the 12th rib. If necessary, a second 5 mm working-port was inserted below the costal margin, but through the para-vertebral muscle. Dissection was carried out with diathermy and/or Harmonic Scalpel ? and adrenal vessels were divided between clips. The specimen was removed in an endopounch through the 10mm port.
RESULTS: In a 16 month period, 6 adrenalectomies were performed in 5 patients; two right, two left and one bilateral. There were 3 boys. The mean age at surgery was 7.8 years (range 1.1- 14.7). Presentation was with hypertension (n=2), Cushing's syndrome (n=2) and abdominal pain. Mean operative time was 154 min (110-186). The single port adrenalectomy technique was performed in 3. The histopathological reports of the specimens were adrenal cyst, cystic pheochromocytoma, adrenal cortical tumour (2) and central Cushing disease, and all completely resected. There were no operative complications and all patients remain symptom free.
CONCLUSION: These cases represent the first laparoscopic adrenalectomies performed at our institution. The general learning curve for laparoscopy has been long since surmounted for the senior reporting surgeons and this experience has proved vital to expand our repertoire with such encouraging early results. The technique confers excellent intra-operative haemodynamic instability. We now consider the retroperitoneoscopic approach the technique of choice for adrenalectomy.

S061 Short Poster

URACHAL REMNANTS, LAPAROSCOPIC APPROACH: A CONSECUTIVE SERIES OF 24 CHILDREN, Salmai Turial MD, Th Hückstädt,St Richter,V Engel MD,F Schier, Pediatric Surgery University medical centre Mainz, Germany

PURPOSE
The urachus normally obliterates during months 4 to 5 of gestation. Incomplete obliteration can result in the formation of an umbilical sinus, fistula, cyst, or abscess in the infraumbilical area. Usually, urachal remnants are treated in the ?open? method. This study evaluates the role of laparoscopy in this anomaly.
PATIENTS AND METHODS
During the period from 1993 to Dec. 2004, 24 children presented with urachal remnants (aged 4 weeks to 10 years, median age was 4,7 years). In 4 patients an abscess had developed. In no patient urine leaked. Under general anesthesia, a 5-mm laparoscope was placed to the left of the umbilicus. Two additional 2-mm ports were used for the left and the right hand of the surgeon. The urachal remnants were exposed, excised by electrocauthery, and the bladder-sided stump ligated with two nonabsorbable sutures. No drains were used. The specimen were exteriorized via the umbilicus.
RESULTS
Operative time was 20 to 45 minutes (median: 25 minutes). There were no intra-or postoperative complications. In 35% of cases the right median umbilical ligament had to be transsected first in order to obtain view of the urachus.
CONCLUSION
The traditional treatment of a residual urachus is surgical resection of the entire tract from the dome of the bladder to the umbilicus through a lower midline incision.The laparoscopic approach to the complete excision of urachal abnormalities in adults has recently been advocated by some groups but little has been reported in the pediatric literature as case-reports. The laparoscopic approach for urachal remnants is safe, allows for clear visualization of the anatomy, and yields a better cosmetic result. This technique should become the procedure of choice for the management of urachal pathology.

S062 Short Poster

LAPAROSCOPY IN MANAGEMENT OF INTERSEX PATIENTS, Nabil M Dessouky BA, Division Of Pediatric Surgery, Cairo University

In recent years, laparoscopy has gained acceptance as a useful method in management of intersex states. The indications for laparoscopy in such conditions are still evolving.
Laparoscopic operations were performed for 35 patients with intersex conditions. Their ages ranged between 3 weeks and 46 years. Cases of gonadal dysgenesis (GD) included 16 patients; five of them were true hermaphrodites (TH). Patients with female pseudohermaphroditism (FPH) included 9 cases while those with male pseudohermaphroditism (MSH) were ten.
Simple diagnostic laparoscopy was performed for 9 cases; four of these were FPH reared as males having congenital adrenal hyperplasia (CAH) with fully masculinized external genitalia .They reversed their sex after surgery.
Hysterectomy was performed for 12 patients: four cases had mixed gonadal dysgenesis (MGD); four cases were TH reared as males, two cases of dysgenetic male pseudohermaphroditism, a case of persistent Mullerian duct syndrome and a male adult with lately diagnosed CAH. Twenty-six gonadectomies were performed for 16 patients: streak gonads (7), ovaries (4), dysgenetic testes (5) and ovotestes (4). Bilateral gonadectomy for gonadoblastoma was performed for three patients: a pure gonadal dysgenesis, an androgen insensitivity syndrome and a patient with 5-alpha reductase deficiency.
Laparoscopic orchiopexy was performed for 13 patients. Staged Fowler Stephen's technique was adopted in eight of these cases. Laparoscopic repair of associated hernial sacs was performed in three cases.
Although the initial diagnosis can be reached in most cases of intersex by the clinical presentation, cytogenetic, biochemical and hormonal studies; yet in certain cases, laparoscopy provides a minimally invasive technique for their accurate diagnosis especially for cases with abnormal gonadal differentiation. It also serves as an efficient method for completion of their surgical reconstruction and removing structures contradictory to the assigned gender.

S063 Short Poster

PNEUMOVESICOSCOPIC URETERIC REIMPLANTATION IN CHILDREN WITH VESICOURETERAL REFLUX AND PARAURETERAL (HUTCH) DIVERTICULUM, Holger Till MD, Jennifer Dart Yin Sihoe MS,Edwin Chan BS,Chung Kwong Yeung MD, Dept. of Surgery, Div. of Pediatric Surgery and Pediatric Urology

PURPOSE: Pneumovesicoscopic ureteric reimplantation (Cohen's type) proved to be a safe and beneficial approach to children with significant vesicoureteral reflux (VUR). The present study investigates the feasibility of this method to correct more complex anatomical cases of VUR like paraureteral (Hutch) diverticulum and megaureter.
MATERIAL AND METHODS: 6 patients (age 11 months to 8.5 years) had recurrent UTI due to VUR (grade 3-5) associated with Hutch diverticulum (unilateral VUR in 4, bilateral VUR in 2, 1 additional megaureter). Transurethral cystoscopic guidance served for placement of the camera port (5 mm). The bladder was evacuated to install the pneumovesicum (CO2 pressure of 10-12 mmHg). After insertion of two working ports (5mm), the diverticulum could be mobilized and resected. The ureter was followed for 2.5 to 3cm into the extravesical space (the megaureter was then tapered inside the bladder (interrupted 5-0 vicryl). A submucosal tunnel was created (Cohen's type) and the ureter was drawn through the tunnel and the ureterocystoneostomy was completed (interrupted 5-0 Biosyn). For bilateral VUR, one child received subureteral Deflux injection simultaneously, the other bilateral reimplantation.
RESULTS: All procedures were completed successfully. Mean operating time was 173 min. (range 140-200 min.). Patients were discharged 1.7 days postoperatively without a stent (range 1-3 days). Follow-up after 3 months showed no evidence of significant VUR, no diverticulum recurrence or ureteral obstruction.
CONCLUSION: Children with Hutch diverticulum and associated VUR can be corrected effectively by pneumovesicoscopic ureteral reimplantation. The long-term outcome will need further evaluation.

S064 Short Poster

GUIDELINES FOR EXPLORATORY ENDOSURGERY IN CONSTANT URINARY DAMPNESS, Chris z Kimber MD, Neil z McMullin MD,Peter z Borzi RN, Department of Paediatric Urology Royal Childrens Hospital, Melbourne , Monash Medical Centre Melbourne and Mater Hospital Brisbane

Total constant urinary dampness in children is usually diagnosed in late childhood and is rare. Ureteral ectopia is the usual cause however this may be difficult to prove prior to surgery. Complete workups including cystoscopy, MRU, IVP,MCU and DMSA/DTPA rarely reveal the ectopic ureter or renal tissue. These children are often desperate for symptom resolution and readily accept diagnostic laparascopy/retroperitonealoscopy.
Aim :To develop appropriate guidelines for the type of endosurgical technique required in blind exploration of constant urinary dampness.
Methods:A retrospective review of all cases treated in 2 major paediatric urology centres over a seven year period was performed. Five females (age 8-15) presented with constant urinary dampness. All patients underwent at least 2 cystoscopies, MR urography, mcu, IVP, nuclear medicine studies and ultrasound. No ectopic renal tissue or ureter was identified in any of these studies. Exploratory surgery was offered after full informed consent including the risk of negative endoscopy.
Results:Two girls presented with a solitary left single system kidney and no orifice in the right trigone at cystoscopy. A small right pelvic kidney with an ectopic ureter was identified at laparoscopy. Laparoscopic nephro-ureterectomy was performed with complete resolution of symptoms.
Unilateral uncomplicated duplex systems occurred in the remaining 3 patients. The contralateral kidney in this group appeared entirely normal. Retroperitoneal exploration of the normal non-duplex kidney was offered. This identified an ectopic ureter and small nubbin of tissue above the normal kidney in cases. These ureters were clipped and divided with immediate ceasation of constant dampness.
Conclusions:On the basis of our experience we recommend the following guidelines for the treatment of constant dampness.
1)Standard urological workup is usually negative and exploratory endosurgery should be offered.
2)Patients with solitary kidneys require laparoscopy for nephro-ureterectomy of the contralateral dysplastic pelvic kidney.
3)Retroperitoneal endosurgery to the contral-lateral normal kidney is appropriate when there is an uncomplicated duplex system present. Excision of the upper pole nubbin or division of the ectopic ureter will relieve the distressing symptoms.

S065 Short Poster

LAPAROSCOPIC EXCISION OF MÜLLERIAN DUCT DERIVATIVES IN INTERSEX PATIENTS, Ahmed Aref MSc, Mohamed M Elbarbary MD, Hani M Abdelraoef MD,Essam Elhalaby MD,Mona Mamdouh MD,Nermin Salah MD,Mahmoud ElDaw MD, Cairo University Specialized Pediatric Hospital, Tanta University Children Hospital

Introduction and Objectives: Removal of Mullerian Duct derivatives (MDD) in intersex patient is a frequent procedure that has been usually performed through traditional surgical approaches. These approaches are both invasive and associated with risks. In recent years laparoscopic excision of MDD was described. We present a review of two centers? experience with laparoscopic excision of MDD in intersex patients, emphasizing the efficacy of laparoscopy in treating these patients.
Methods and Procedures: Notes of one hundred and eight intersex patients referred to the pediatric endocrinology during the last 4 years in 2 academic tertiary referral centers were reviewed. Eleven patients undergone laparoscopic excision of MDD represent the focus of the current study. Their ages at surgery ranged between 2 and 22 years (mean 6.9). Nine patients presented with ambiguous genitalia, one for evaluation of impalpable testis and another for short stature. Chromosomal analysis and preoperative workup confirmed the diagnosis mixed gonadal dysgenesis (n=8), true hermaphrodite (n=2), and congenital adrenal hyperplasia (n=1). Three ports were used; one was placed in the umbilicus for a 5 mm telescope and two 5mm working ports inserted in both iliac fossas.
Results: Laparoscopic excision was completed in all 11 cases. Excision of hemiuterus was performed in seven patients, total hysterosalpingectomy in three and prostatic utricle in one. Laparoscopic gonadectomy was performed unilaterally in 8 patients and bilaterally in one. Mean operative time was 85 minutes. There were no intraoperative complications. Postoperative umbilical port infection occurred in one case. Oral feeding started on the first postoperative day and patients were discharged on the third postoperative day. Follow up of 6 months to 2 years showed satisfactory results in all patients.
Conclusions: Laparoscopic excision of MDD is a safe and viable alternative to traditional surgery in intersex.

S066 Short Poster

THE LAPAROSCOPIC TWO-STAGE FOWLER-STEPHENS ORCHIDOPEXY : PRESERVATION OF THE GUBERNACULAR VESSELS AND A PURELY LAPAROSCOPIC 2ND STAGE TECHNIQUE, Stuart A Robertson MD, Fraser D Munro MD,Gordon A MacKinlay MD, Department of Surgery, Royal Hospital for Sick Children, Sciennes Place, Edinburgh

Aim: Controversy exists over the optimal laparoscopic technique to mobilise intra-abdominal testes. We describe a modification of the two-stage laparoscopic Fowler-Stephens technique in which the gubernacular vessels are preserved and the testis is brought down the canal via the internal ring. A purely laparoscopic 2nd stage is performed (rather than an inguinal crease incision). We report the outcomes with this technique, used in our unit between 1996 and 2004.
Methods: All laparoscopic Fowler-Stephens orchidopexies undertaken at our hospital from 1996 to July 2004 were identified from a prospectively collected database. A retrospective case-note review was undertaken.
Results: 21 patients were identified, 4 with bilateral and 17 unilateral intra-abdominal testes, a total of 25. Mean age at presentation was 21 months (range 0 ? 56 months). Mean age at 1st stage was 36 months (range 11 ? 68 months). The testis position at initial laparoscopy was ?high? (> 2cm from IIR) in 5, ?close to IIR? (1-2cm from IIR) in 9, ?peeping? (< 1cm from IIR) in 6 and ?pelvic? (hanging over pelvic brim) in 5. The testis size at this stage was either ?normal?, ?good sized? or ?reasonable sized? in 15, ?small? or ?dysplastic? in 5, and in 5 the size was not commented upon. The testicular vessels were mainly divided by diathermy at 1st stage, but in 6 the vessels were clipped. The 2nd stage was undertaken 6 months after the first, in order to allow the blood supply (via the vas and cremasteric vessels) to develop. 12 testes had changed position category during this interval, 2 having ascended to a higher position and 10 descended to a lower position. 12 were in the same position at both stages and in 1 case the position was not com-

mented upon at 2nd stage. A purely laparoscopic 2nd stage technique was used in 21 cases, and an assisted-open 2nd stage was undertaken for one case. In three cases the testis was palpable at EUA and so an open 2nd stage orchidopexy was performed. Follow up was at two visits, at 6 months after the 2nd stage and then at 18 months. Of the 22 testes followed up at the time of audit, 3 testes had atrophied and 19 survived, giving a survival rate of 86%. All surviving testes were palpable in the scrotum.
Conclusion: The 2 stage laparoscopic Fowler-Stephens orchidopexy, with preservation of the gubernacular vessels and predominantly using a purely laparoscopic 2nd stage, has provided a very good testis survival rate, close to 90%.

S067 Short Poster

LAPAROSCOPIC SALVAGE OF MALFUNCTIONING PERITONEAL DIALYSIS CATHETERS, A Numanoglu MD, MI McCulloch MD,A van der Pool MS,AJW Millar MD,H Rode MD, Departments of Paediatric Surgery and Paediatric Nephrology, Red Cross Children's Hospital and University of Cape Town, Rondebosch, 7700, South Africa

Aim: Peritoneal dialysis (PD) is the preferred method of treatment for chronic renal failure awaiting renal transplantation in our institution. PD is a practical and relevant form of dialysis in developing countries as patients can be trained to do this at home. PD catheters can block and may require revision. Our aim for this study was to visually identify the cause of malfunction and modify our laparoscopic insertion technique if necessary. This would prevent replacement of PD catheters and reduce morbidity and costs.
Patients and methods: 43 patients required PD catheter insertion between 2001 and 2004 of which 24 were done laparoscopically. Four patients had their catheter tip sutured to pelvic peritoneum and 11 underwent omentectomy at initial insertion. Laparoscopic salvage performed by two or three 5mm ports. If required the tip of catheter could be inspected and cleaned by exposing it through one of the port sites.
Results: Twenty patients required re-operation for malfunctioning catheters. Eleven had 13 laparoscopic salvage operations and 9 had open replacement of catheters. Average age was 8 years (range 2-14) and male:female ratio was 6:14. Causes of malfunction identified in the laparoscopic group were occlusion by fimbria in 4 and omentum in 1, peritonitis in 4 and displacement of catheter in 4. In the open replacement group 2 patients had peritonitis and 1 had occlusion with fimbria and 1 with omentum. Five had no cause identified. Re-look laparotomy and diathermia haemostasis of fimbria was required in one patient who had bleeding from fimbria after retracting it from PD catheter laparoscopically.
Conclusion: 46% of patients required PD catheter salvage operation. Laparoscopic approach enabled us to visualise the cause of malfunction and correction of problems without replacing the catheter as has been our previous practise. We are modifying our laparoscopic insertion technique to include suturing of tip of catheter to pelvic peritoneum, routine omentectomy and ovarian pexy when required.

S068 Short Poster

VESICOURETERIC REFLUX AND RECURRENT URINARY TRACT INFECTION, Cheung Kwong Yeung MD,Sujit Kumar Chowdhary MS, Edwin Chan MS, Jennifer Dart Yin Sihoe MS,Biji Sreedhar MSc, Div. of Pediatric Surgery and Pediatric Urology, Chinese University of Hong Kong, Prince of Wales Hospital, Shati, Hong Kong

Background:It was our impression based on previous experience, that a small proportion of children with gross vesicoureteric reflux (VUR) and megaureters have stenosed ureteric orifice.We investigate the incidence of this subgroup and report the outcome with endoscopic ureteric reimplant with pneumovesicum.
Patients and Methods: Patients with primary VUR referred for surgery were recruited. Preoperative investigations included ultrasound (US), micturating cystourethrogram (MCU), DMSA scan and bladder function evaluation.During the preoperative counselling, subureteric deflux injection was offered as an option for low grade reflux and endoscopic ureteric reimplant was offered as an option for severe reflux or stenosed ureteric orifice found in endoscopic evaluation. The cystoscopic findings were video recorded and in case of doubtful stenosis, a ureteric catheter was used to calibrate the orifice.The failure of 3F ureteric catheter to be negotiated into the orifice was taken as indicative of stenosed orifice. Postoperative recovery and result of investigation at 3 months after repeat US and MCU were recorded.
RESULTS: Eighteen children (M/F16/2) with 32 refluxing ureters were selected for evaluation. Refluxing ureters were classified as grade 5 in 16, Grade 4 in 10,Grade 3 in 5 and Grade 2 in one ureter. Eight had recurrent UTI, others had progression of scar or persistence of reflux. Bladder dysfunction was present in 4 children severe detrusor instability in 3 and poor emptying in 1, leading to initial vesicostomy in 2 children.Two refluxing ureters were found to be associated with Hutch diverticulum at repeat MCU. At initial cystoscopic examination, stenosed ureteric orifice was found in 5 of the 32 refluxing ureters (16%),all of them had presented with recurrent UTI and severe VUR associated with huge megaureter.These ureters were reimplanted by the endoscopic Cohens technique and were found to have a dysplastic atretic terminal segment. Reflux resolved in all children and none had UTI over a follow up period of 6m- 24m.
CONCLUSION: Recurrent UTI with severe dilating VUR in children requires careful attention to bladder dynamics and anatomy of vesicoureteric junction. A stenosed ureteric orifice with dysplastic atretic terminal end of the ureter is a small(13%)but significant subset of primary refluxing ureters. Endoscopic Cohens ureteric reimplant has lead to resolution of symptoms in all children in this subgroup

S069 Short Poster

VESICOSCOPIC URETERAL REIMPLANTATION IN CHILDREN WITH VESICOURETERIC REFLUX. ANY ASSOCIATION WITH BLADDER SPASM?, EdwinKW Chan MS, Jennifer Dart Yin Sihoe MS,Cheung Kwong Yeung MD, Division of Paediatric Surgery & Paediatric Urology, Department of Surgery, The Chinese University of Hong Kong, Prince of Wales Hospital, Hong Kong SAR, China

Background: Bladder spasm is commonly encountered after open bladder surgery including ureteral reimplantation and poses a significant management problem. Patients often require narcotic analgesics and antimuscarinic agents. Recently vesicoscopic ureteral reimplantation under CO2 pneumovesicum has been introduced. We evaluate the occurrence of bladder spasm after vesicoureteric reimplantation and review their management.
Material and methods: Children who have vesicoscopic ureteral reimplantation performed for vesicoureteric reflux were recruited. Patient who has additional surgical procedures in the same operation setting were excluded. After the operation, 0.25% bupivicaine is given to the port sites. The timing, frequency and duration of bladder spasm, defined as acute spasmodic pain in the region of the bladder causing significant distress to patient e.g. crying, bending up of knees lasting for at least 1 minute when the child has been previously comfortable, was recorded. Post-operative analgesics comprised of paracetamol 10mg/kg/dose and pethidine 1mg/kg/injection given on demand. Dosage of analgesics used and demand for additional use of oxybutynin was recorded.
Results: 22 children are included in this study. Age ranged from 5 months to 12 years. (Mean 5.7 year) Bladder spasm has not been noted in any single patient. Use of oxybutynin has not been required. 5 patients did not require use of any analgesics. 16 patients required paracetamol only, with a mean of 2.6 doses per children. Only 2 patients required additional pethidine injection. (Mean 1.5 injections per patient)
Conclusion: Our early experience shows that vesicoscopic ureteral reimplantation is not associated with any significant bladder spasm in this study. Analgesic requirement is also minimal in this group of patients. Vesicoscopic bladder surgery should be the method of choice for ureteral reimplantation in future.

S070 Short Poster

THE ROLE OF LAPAROSCOPY IN THE MANAGEMENT OF PATIENTS WITH AMBIGUOS GENITALIA, Marìa M Bailez MD, Aixa Reusmann MD,Pablo Laje MD, Pediatric Surgery . J. P. Garrahan Hospital . Buenos Aires . Argentina.

Introduction Gonadal histology is required in some intersex patients with abnormal gonadal development like mixed gonadal dysgenesis(MGD)and true hermaphroditism (TH) . In female sex reassigment patients ,laparoscopic biopsies and eventual gonadal resection are done at the same time of feminizing genitoplasty. The role of laparoscopy in patients raised as males is excision of mullerian structures, prostatic utricle and orchidopexy .
Aim : Share and discuss the thecnical details of the treatment of these unusual gonads.

M&M : Thirteen pts.(9 females and 4 males) between 21 days and 10 years were treated with laparoscopy. Diagnosis wasTH in 6 and MGD in 7 .All TH pts. were female reassigned. Only 3 of theMGD pts. were female reassigned. Gonadal biopsies were taken along the longitudinal axis of the gonad as both ovarian and testicular tissue may be found at its polar ends . Depending on the previous workup and the result of the frozen section biopsy, the gonad was removed. Half of the TH pts. had an ovary (O) and a testicle (T) ; 2 had bilateral ovotestes (OT) and 1 an O and an OT. All T and OT were resected except 1. Using zoom lens unilateral ovarian component was separated and preserved. A streak gonad was recognized in all the pts with MGD and was removed without prior biopsy together with the surrounding peritoneum and the ipsilateral gonaduct because of the risk of an in situ gonadoblastoma.It was always associated with an intrabdominal or inguinal dysgenetic testicle, which was removed at the same time in patients with female sex assigment.
A simultaneous resection of the streak,gonaduct and hemiuterus was done in the 4 pts with MGD and male reassigment .Only 1 of them had an scrotal testicle and an associated primary (1pt.) or staged Fowler Stephens orquidopexy (2pts) were required.
Results : We performed simultaneous laparoscopy and feminizing genitoplasty in all but 1of the females (8/9). Mean operative time was 3,5 hours (2,5-5,5 h). Mean operative time in males was 75 minutes (45 - 100) .Bilateral gonadoblastoma was found in the testicular component of OT in a 1 year old pt.There was a 100% correlation between frozen and definitive biopsies.
Discussion: Although sex may be assigned before the biopsy is taken, histology in these patients is required for definitive diagnosis.Laparoscopic better visualization and quicker access to intrabdominal gonads encouraged us to perform simultaneous gonadal and genitalia procedures

S071 Short Poster

USE OF THE LIGASURE DEVICE IN LAPAROSCOPIC VARICOCELE LIGATION IN CHILDREN AND ADOLESCENT, Antonio Marte MD, Micaela Borrelli MD,Pasquale Cautiero MD,Mercedes Romano MD,Maria Domenica Sabatino MD,Antonio Vessella MD,Parmeggiani Pio MD, Second University of Naples

Purpose: We reviewed our experience of laparoscopic Palomo varicocele ligation (LPV) with LigaSure device in male children and adolescents with varicocele.
Materials and Methods: Between June 2003 and October 2004, 25 varicoceles were treated using LPV with LigaSure vascular sealing. Patient ages ranged from 10 to 19 years (mean 14.5). Indication for surgery included II ? III grade varicocele and/or ipsilateral testicular hypotrophy. One patient had recurrent contralateral inguinal hernia and 2 presented an ipsilateral patent processus vaginalis (PPV). Umbilical open access using a 5 mm port was achieved, keeping the pneumoperitoneum pressure lower than 15 mmHg. Under laparoscopic guidance 3 and 5 mm additional ports were applied in the right and left lower quadrants, respectively. Once the vessels were isolated, vascular sealant was used 3 to 4 times to ensure coagulation of the spermatic vessels and then they were divided. Inguinal hernia and PPV were treated according to Schier technique. All procedures were performed as day surgery cases.
Results: Mean operating time was 18 min. No patient presented perioperative complications. Eleven out of 16 patients recovered testicular size. Two patients required vaginal resection due to secondary hydrocele.
Conclusion: Laparoscopic Palomo varicocele sealing can be performed safely, rapidly and it is a highly successful method to correct varicoceles in young males. In our opinion, laparoscopic Palomo varicocele sealing should be regarded to as the ideal technique to correct the associated inguinal hernia or PPV.

S072 Short Poster

ACTUAL PRACTICE OF LAPAROSCOPY AND THORACOSCOPY IN NEONATES: A GECI STUDY OVER 10 YEARS., N Kalfa MD, H Allal MD,H Lardy MD,M Robert PhD,F Varlet PhD,O Reinberg PhD,G Podevin MD,Y Heloury PhD,F Becmeur PhD,I Talon MD,L Harper MD,P Vergnes PhD,I Valioulus MD,M Lopez MD,RB Galifer PhD, GECI Groupe d'Etude en Coeliochirurgie Infantile - Service de Chirurgie Viscérale Pédiatrique, Hôpital Lapeyronie, CHU Montpellier, France

Objective. This study aims to evaluate the actual indications of video-surgery during the first month of life and to describe the most recent trends of its practice. Methods: 245 neonates (mean age: 15.9 days, weight: 3360g) from 8 European university hospitals were enrolled in this multicentric study from 1994 to 2005.
Results: -Indications for laparoscopy were: pyloric stenosis (n=85), ovarian cysts (n=63), volvulus with malrotation (n=10), congenital diaphragmatic hernias (n=9), intestinal duplications (n=9), duodenal atresias (n=7), gastro-esophageal reflux (n=2), and biliary atresia (n=1), exploratory and others (n=21); For thoracoscopy: esophageal atresias and esotracheal fistula (n=8), congenital diaphragmatic hernias (n=2), others (n=3). For videoassisted-thoracotomy: oesophageal atresia (n=26)
-33 conversions (15%) to laparotomy (n=29) or thoracotomy (n=4) were necessary either for maltolerance of insufflation (5 cases) or technical difficulties (28 cases) mainly for exposition or anastomosis. This rate was stable over the period study.
-Complexity of the surgical procedures progressively rose: decreased minimal age at surgery, increase number of patients < 2200g, more surgical procedures > 2hrs and more thoracoscopies since 2001, use of higher insufflation pressure since 1999.
-16 surgical incidents occurred (7.5%), mainly before 2001: 11 were minor (parietal hematoma, eventration); 3 neonates had to be reoperated for incomplete treatment of pyloric stenosis; 2 incidents were more threatening (duodenal wound, diaphragmatic artery injury) but with no further consequences. We report no mortality.
-26 anesthetic incidents (12%) occurred during insufflation (desaturation, hypotension, hypercapnia >45 mmHg, hypothermia <34.9°C, postoperative metabolic acidosis). Significant risk-factors for an incident ($p<0.05$) were: young age of patient, low body temperature, thoracic insufflation, high pressure and flow of insufflation, length of surgery.
Conclusion: The recent technological advances and increased surgeons? experience allow a larger use of videosurgery during the first month of life with more and more complex procedures. Nevertheless, the morbidity should not be neglected and a profile of the patient at risk of an insufflation-related incident emerged from this study.

S073 Short Poster

LAPAROSCOPIC PARTIAL SPLENECTOMY FOR A NONPARASITIC SPLENIC CYST USING RADIOFREQUENCY ABLATION, K Khelif MD, F Maassaarani MD,M Dassonville MD,MH De Laet MD, Department of surgery Queen Fabiola Children's University Hospital, Université Libre de Bruxelles, Brussels / Belgium and Auvelais Hospital / Belgium

Objective :
Radiofrequency (RF) ablation is an established technique for the management of hepatic tumours. Herein we report the case of a 4 year old patient with a nonparasitic lower pole splenic cyst treated by a laparoscopic partial splenectomy with use of RF energy.
Methods and procedures:
A 4 year old boy presented with a symptomatic 7cm nonparasitic lower pole splenic cyst. A laparoscopic lower pole splenectomy was performed using a 4 trocar technique (three 5mm and one 10mm umbilical trocar). This new approach consisted in thermofusing the lower pole vessels with the ligasure, and creating a 1cm desiccation zone with the RF needle 5mm inside the demarcation line. The RF needle is inserted percutaneously in the spleen under visual control. RF works by conversion of RF waves into heat creating thus a coagulative desiccation resulting in solid organ shrinkage and sealing of blood vessels. The cooked parenchyma is then divided with the scissors without any blood loss. The specimen is subsequently retrieved in an endobag after aspiration and morcellation.
The operating time was 90 min, with 15 min for the RF phase.
The patient was discharged on day 2, and the postoperative course uneventful. The follow up work up at 1 year showed a well vascularised 5cm remaining spleen on Doppler ultrasound, a normal platelet count, and no Howell-Jolly bodies on peripheral blood smear.
Conclusions:
Laparoscopic partial splenectomies offer a definitive treatment for nonparasitic splenic cysts and function preservation. They also offer minimal postoperative discomfort, reduced length of hospital stay and an excellent cosmetic result. The RF allowed us to operate in a clear surgical field, with no blood loss nor splenic tissue spillage. This approach spared the need for blood transfusions, and offers great promise for partial splenectomies in children.

S074 Short Poster

LAPAROSCOPIC PROCEDURES FOR BENIGN ABDOMINAL AND RETROPERITONEAL CYSTS IN PEDIATRIC PATIENTS., Igor V Poddoubnyi MD, Anatolyi F Dronov MD,Alexei N Smirnov MD,Andrei A Isaev MD,Artur Mannanov MD,Tatyana M Glybina MD, Moscow State Medico-Stomatologic University

The total number of 711 pediatric patients (aged from 6 days to 15 years) underwent laparoscopic procedures for different variants of benign abdominal and retroperitoneal cysts during the period from 1993 to 2004 :

- 536 laparoscopic procedures were performed for various benign ovarian and paraovarian cysts. All the procedures (emergency and planned) were accomplished laparoscopically, irrespective of the patient's age and the cyst size (the maximal volume of cystic teratoma was 9.0 litres, paraovarian cyst ? 7,5 litres);
- laparoscopic resection of hepatic cysts were performed in 24 patients (4 cases of cystic echinococcosis among them) without intraoperative, postoperative complications and conversions to open procedure;
- laparoscopic resection was performed in 49 patients for different variants of large splenic cysts. There were no conversions to open procedure. Laparoscopic splenectomy was performed in one patient with large splenic lymphangioma for multiple cysts that appeared during the period of 2 years after the primary procedure. There were no other cases of relapse and no indications for reoperation in our series;
- laparoscopic resection of large renal cysts was performed in 53 patients (echinococcosis in 2 cases). Laparoscopic procedure was successful and effective in all cases including 14 cases of perihilar cysts. No cases of conversion and no indications for reoperation occurred;
- gastric and duodenal duplication cysts were excised laparoscopically in 8 patients;
- 13 cases of mesenteric cysts were revealed laparoscopically, laparoscopic excision was accomplished in 2 cases, in other 11 patients open bowel and mesentery resection was needed;
- 9 cases of omental cysts (maximal volume was 5.0 litres) were successfully treated laparoscopically;
- 12 patients with diaphragmatic cysts and 7 patients with isolated abdominal and retroperitoneal enterogenous cysts underwent effective laparoscopic surgery.

We consider endoscopic surgery the method of choice for the treatment of various benign abdominal and retroperitoneal cysts in children.

S075 Short Poster

OPTIMIZING OUTCOMES IN THE THORACOSCOPIC MANAGEMENT OF COMPLICATED PARAPNEUMONIC EFFUSION IN CHILDREN, Jeffrey C Pence MD, Ronald P Mageau MD,Laurie A Driscoll, Brody School of Medicine at East Carolina University, Greenville, NC, USA

This retrospective study investigated the impact of delayed surgical referral and subsequent thoracoscopic intervention (VATS) upon clinical outcomes in children diagnosed with complicated parapneumonic effusion. Forty-six children underwent VATS at two tertiary pediatric centers during a ten year period ending in 2004. Study groups were stratified based upon timing of surgical consultation and intervention. Patients in group I (n=29) underwent early VATS within 72 hours of hospitalization following confirmation of symptomatic complicated parapneumonic effusion; whereas, patients in group II (n=17) underwent VATS greater than 72 hours following admission and universally subsequent to ineffective drainage of the affected pleural space utilizing non-surgical methods. Fibrinolytic therapies were not offered as an adjunct to drainage. Preadmission and outcome variables were recorded and compared using the Mann-Whitney test, with a P value of less than 0.05 considered significant. Representative results (with standard deviations) are displayed in the following table:

Group	Operative Time (min)	Duration of Tube Thoracostomy (hr)	Time to Defervescence (hr)	Length of Hospital Stay (d)
I	90 (±29)	79 (±45)	49 (±26)	7.7 (±3.4)
II	104 (±36)	98 (±35)	89 (±107)	13.6 (±5.8)
P value	0.03	0.01	0.12	<0.01

Additional outcome indicators, including transfusion events, ventilator requirements, and postoperative hospital days, were also improved with early drainage. In summary, this study affirms the efficacy of VATS in the treatment of fibrinopurulent to organizing parapneumonic effusion in pediatric patients. These data support the expedient recognition, prompt referral, and effectual thoracoscopic drainage of complex parapneumonic effusions for the purpose of optimizing clinical outcomes.

S076 Short Poster

THORACOSCOPIC PULMONARY ARTERY BANDING, Yuri A Kozlov MD, Vladimir A Novogilov MD,Pavel S Yurkov MD, Department of Newborn Surgery, Pediatric Hospital, Irkutsk, Russia

Introduction. Since the original description of pulmonary artery banding by Muller and Dammann in 1952, the indications for this intervention have changed from simple cases of left to right shunt at the ventricular level to more complex conditions, particularly for left ventricular retraining. Many neonates and infants are now treated by primary repair with good results, and PA banding is selected as the initial operative procedure in fewer patients. This operation through open thoracotomy has remained the treatment of choice over the past few decades. We report a case the application of thoracoscopic approach for pulmonary artery banding.
Materials and Methods. The 1-month patient was a male infant with atrioventricular septal defect and Down syndrome. Primary repair is not feasible (2500 g. weight and congestive heart failure). We used a videothoracoscopic approach. Three entry ports (5 mm.) were necessary for the surgical instruments: one into the fourth intercostal space on the middle axillary line for the camera, and the two others into the third and fifth intercostal space on the anterior axillary line. The camera was first inserted. The pulmonary trunk was identified. The pericardium was grasped with an instrument and then opened anterior and parallel to the left phrenic nerve. The pulmonary artery trunk was separated from the aorta, first with an electrocautery hook and then with a right angled dissector. The Gore-Tex band was wrapped around the main pulmonary trunk with constricting the vessel. The optimal perimeter of the band was determined with according to the Trusler's rule. The mean pulmonary artery pressure felt to 18 mmHg. The pericardium was left open, and a chest tube was introduced under visual control through the first port.
Results: The procedure was completed in 120 minutes. The patient was extubated on day 1 postoperatively. There were no procedure-related complications. The position of the band was explored by transthoracic echocardiography. The band was in the correct position without distortion of the pulmonary bifurcation.
Conclusion: Potentially, the thoracoscopic pulmonary artery banding might have implications for clinical use for palliation and left ventricular retraining in children with congenital heart disease.

S077 Short Poster

THORASCOPIC VERSUS THORACATOMY FOR CORRECTION OF SEVERE SPINAL DEFORMITY, Robert E Eilert MD, Mark A Erickson MD,Steven Rothenberg MD, The Children´s Hospital

Thesis: Thoracoscopic anterior spinal fusion creates less morbidity and is just as effective as open thoracotomy in correcting severe scoliosis or kyphosis.
Method:176 patients were treated by combimed anterior and posterior spinal fusion for severe spinal deformity at The Children's Hospital in Denver, Colorado, U.S.A. between January 2000 and December 2004. 122 had an anterior approach by open thoracotomy and 54 had a thoracoscopic approach for their anterior fusion. The posterior fusions were performed with instrumentation by open technique in all the patients. We compared the morbidity and the correction in the two groups.
Results:
Open (122)Thoracoscopic (54)
Operative Time3.2 hrs.2.1 hrs.
Est. Blood Loss347cc.206cc
Days, Chest Tube33
C Tube Drainage886cc677cc
Days Intubated22
Days ICU 43
Days LOS 98
Scoliosis Correction56%60%
Kyphosis Correction41%43%
The operative time,chest tube drainage and intensive care time were less in the thoracoscopic group.The correction of scoliosis and kyphosis were comparable in the two groups.

Conclusion: Using a thoracoscopic approach for the correction of severe spinal deformity is as effective as open thoracotomy in cases requiring combined anterior and posterior spinal fusion with less morbidity.

see table copied from word processor on previous page

S078 Short Poster

THORACOSCOPIC THORACIC DUCT THERMOFUSION WITH THE LIGASURE DEVICE FOR PERSISTENT POSTOPERATIVE CHYLOTHORAX IN 2 CHILDREN., K Khelif MD, F Maassaarani MD,M Dassonville MD,MH De Laet MD, Queen Fabiola Children's University Hospital , Université Libre de Bruxelles, Brussels / Belgium and Auvelais Hospital / Belgium

Objective:
Chylothorax is an uncommon complication of cardiac surgery in children that carries a high morbidity and a potential mortality if not treated properly.
We report here 2 children, who developed a persistent postoperative chylothorax treated by a thoracoscopic thoracic duct thermofusion and section with the ligasure device. The aim of the present study is to evaluate the application of the ligasure to the thoracic duct.
Methods and procedure:
2 children aged 3 and 6 years, developed a persistent chylothorax following respectively a Fontan procedure and an aortic coarctation repair. The former presented a right chylothorax due to indirect lymphatic rupture secondary to increased venous pressure, and the latter, a left chylothorax due to direct injury at surgery.
Voluminous chylous drainage persisted, in both, for more than 3 weeks despite cessation of enteral feedings and administration of somatostatine. Finally, a right thoracoscopic coagulation and section of the thoracic duct with the ligasure 5mm device, without clipping, successfully controlled the chyle leakage.
The 5mm ligasure features dissecting, sealing and cutting capabilities. The ligasure is a computer-controlled bipolar diathermy system designed to seal blood vessels up to 7mm in diameter, with however no specific recommendations regarding lymphatics.
Results:
The lymph leakage ceased immediately in the first patient and within 2 days in the second one, with no recurrence after oral intake resumption on day 5.
Both patients are free of recurrence at 1 year.
Conclusions:
Thoracoscopic coagulation and section of the thoracic duct with the ligasure appears to be an effective and safe therapeutic option for the treatment of postoperative chylothorax.
This is, to the best of our knowledge, the first reported use of ligasure for lymphatic vessels.

S079

LAPAROSCOPIC REDO-NISSEN IN CHILDREN: EXPERIENCE OF MONTPELLIER, M Lopez MD, H Allal MD,N Kalfa MD,D Forgues MD,MP Guibal MD,RB Galifer PhD, Department of Pediatric Surgery, Lapeyronie Hospital, Montpellier, France

AIM: This retrospective study report our experience in laparoscopic approach of failed antireflux surgery.
METHODS: 417 patients were operated for a gastro-esophageal reflux (GER) by laparoscopy in our unit from august 1993 to February 2004. Thirty redo procedures (7%) were performed. The indications were: 24 (80%) recurrent reflux resistant to the medical treatment and 6 (20%) severe dysphagias resistant to iterative dilatations. The average age was 4.8 years old. 19 patients (63%) were males and 11 patients (37%) females. The time between the first and the redo was an average of 16 months. 10 of them (33%) were neurological impaired; in 7 patients, a percutaneus gastrostomy was associated. The techniques previously used were: 13 Nissen, 7 Nissen Rossetti, and 10Toupet.
Results:
The redo were performed by laparoscopy in 27 cases. A conversion was necessary in 3 children because of a difficult dissection. In cases of reccurent reflux, we realized a valve disassembly, reconstruction of hiatus and Nissen refundoplication. For dysphagia, the release of the hiatus needed a complete valve redo in 3 cases. The duration was 140 minutes (110 to 240 mn). The solely complication was a pleural perforation. All the patients were fed on the first day. The mean duration of hospitalization was 3.1 days. The follow-up was from 1 month to 9 years. A new reccurent reflux occured in 6 patients (4 neurologically impaired).
Conclusion: The failure rate of the anti-reflux laparoscopic surgery is similar to the conventional surgery. The redo procedure is possible by laparoscopic with a success rate similar to the classic surgery. The rate and morbidity of complications are acceptable and decrease with experienced surgeons. The indications should be similar to the classic surgery.

S080

CAN FAILURE OF LAPAROSCOPIC NISSEN FUNDOPLICATIONS IN PEDIATRIC PATIENTS BE PREDICTED?, Curt S Koontz MD, Handel Robinson MD,Mark L Wulkan MD, Division of Pediatric Surgery, Joseph B Whitehead Department of Surgery

OBJECTIVE: The purpose of this study was to determine if hiatal suture technique influenced laparoscopic Nissen fundoplication (LNF) failure. A secondary goal was to determine preoperative predictors of LNF failure.
METHODS: After IRB approval, a retrospective chart review was performed on 199 patients who underwent LNF during the period between July 1998 ? July 2003. Demographics, presenting symptoms, and outcome data were compared between patients who underwent re-operation (REDO) and patients with primary LNF only (PRIM). Data was analyzed with the Student's t-test, chi square, and Fisher's exact test. Data is presented as mean ± standard deviation, and p less than 0.05 was considered significant.
RESULTS: Twenty-six of 199 patients (13%) underwent re-operation (RO). Age of the REDO group and PRIM group was 35±53 and 48±67 months, respectively (NS). Weight of the REDO group and PRIM group was 16±22 and 16±20 kg, respectively (NS). Operative time for the REDO group and PRIM group was 92±39 and 90±35 minutes, respectively (NS). Figure-of-eight sutures were used to approximate the hiatus in 19 REDO (73%) and 101 PRIM (58%) patients. Inturrupted sutures were used in the other patients. There was no significant difference between the two suture techniques. Time to RO was 15±21 months. Reason for RO was recurrent GERD (n=19), hiatal hernia (n=20), and esophageal stenosis (n=1). Operations included hiatal repair (n=20), wrap repair (n=19), and antroplasty (n=5). Complications included stricture (REDO: n=3; PRIM: n=5, NS), and 1 wound infection in the PRIM group. There was no sigificant difference in the PRIM and REDO groups of the following possible predictors of LNF failure: neurologic disease, respairatory disease, prematurity, age < 1 year, or gagging.
CONCLUSIONS: Hiatal suturing technique does not influence the rate of wrap failure. There were no predictors of LNF failure in our study population.

S081

THORACOSCOPIC-ASSISTED ESOPHAGECTOMY AND LAPAROSCOPIC GASTRIC PULL-UP FOR LYE INJURIES IN CHILDREN-EARLY RESULTS AND FOLLOW-UP, Timothy D Kane MD, UPMC and Children's Hospital of Pittsburgh, Pittsburgh, PA., U.S.A.

Introduction: Esophageal strictures are often the result of accidental ingestion of caustic agents. The management and follow-up of two children who developed strictures following lye ingestion are described here.
Methods: Retrospective chart analysis of both patients.
Results: Case 1: A 17 y female ingested lye containing substance resulting in the need for gastrostomy and retrograde esophageal dilatations. A long esophageal stricture and intolerance oral feeds developed. One year later, a thoracoscopic esophagectomy, laparoscopic gastric conduit creation, pyloroplasty, gastric pull-up, and cervical esophagogastric anastomosis were performed. The operation took 7 hours, a barium swallow was done 4 days later, and she was discharged in 8 days on full feeds. Over 2 years later she is gaining weight and tolerating all oral feeds. Case 2: A 13 mo old female who ingested lye, developed airway compromise and underwent tracheostomy and gastrostomy on the day of injury. Retrograde esophageal dilatations were initiated at 1 mo. For 8 mos, strictures persisted and she developed intolerance of oral secretions. At age 21 mo, thoracoscopic esophageal mobilization, laparoscopic creation of a gastric conduit, pyloroplasty, and cervical esophagogastric anastomosis were performed. The small thoracic inlet and scarring from the tracheostomy necessitated a right thoracotomy to negotiate the conduit safely up to neck. The operation lasted 13 hours. She had no significant complications except for prolonged ventilator therapy and she was discharged home on a pureed feeds. Nine months following esophageal replacement she is thriving and gaining weight.
Conclusions: Esophagectomy and gastric pull-up for esophageal lye

injuries can be accomplished utilizing a combination of thoracoscopy and laparoscopy with excellent results. Significant scarring in the neck and mediastinum from the initial injury or subsequent dilations may make the thoracic dissection more difficult.

S082

EXPERIENCE WITH GASTRIC TUBE CARDIOPLASTY IN TREATMENT OF GER, B.Haluck Guvenc MD, Selami Sozubir MD,Levent Avtan MD,Ufuk senel MD, Kocaeli University, School of Medicine, Dept. of Pediatric Surgery, Kocaeli, Turkey,Istanbul University, Istanbul School of Medicine, Dept. of Surgery, Istanbul, Turkey

Introduction: The most common esophageal motility disorder in childhood is gastroesophageal reflux (GER). The choice of the best surgical procedure is a challenging issue due to problems such as unwrapping of fundoplication or dislocation of the fundus. Our initial clinical experience using gastric tube cardioplasty in treatment of GER is presented.
Methods / Procedure: Eight patients, (4months - 12years) consisting of three boys and five girls with complicated GER underwent gastric tube cardioplasty between 2001-2004. Seven patients suffered from secondary GER due to esophageal atresia (n: 3), cerebral palsy (n: 2) and corrosive esophageal burn (n: 2). In the present technique, an adequate intra-abdominal esophageal length is fashioned from the lesser curvature by stapling and creating a gastric tube without an additional fundic wrap. The operation was accomplished using minimal invasive approach in three cases, one of which was converted to open related to stapler discordance. The postoperative follow up period ranged from 8 to 24 months. Two cases died due to unrelated causes other than primary disease. Six cases were reevaluated by 24-hour pH monitoring. Reflux and related symptoms disappeared in all cases during one to four months period.
Conclusion: We advocate gastric tube cardioplasty as an effective, easy and reasonable alternative procedure with minimum dissection, in children with gastroesophageal reflux disease.

S083

BARIATRIC SURGERY FOR MORBIDLY OBESE ADOLESCENTS: EARLY RESOLUTION OF OBESITY RELATED COMORBID CONDITIONS, Carroll M Harmon, MD PhD, Ronald Clements MD,Tara Loux BA, University of Alabama Hospital, Birmingham, AL, Children's Hospital of Alabama, Birmingham, AL

Introduction: Pediatric obesity and its associated complications have increased dramatically over the past decade. The results of bariatric surgery in adolescents are limited. We report our early results with gastric bypass performed on 14 teenagers over the past 5 years.
Methods: Fourteen severely obese adolescents underwent Roux-Y gastric bypass at our institutions. We performed a retrospective chart review to elicit outcomes measurements, including weight loss, laboratory data, resolution of comorbid conditions and post-operative complications. Student's t-test was used for statistical analysis.
Results: Twelve adolescents completed laparoscopic Roux-Y gastric bypass. One patient was converted to open operation and one underwent a planned open operation. Mean age was 18.5±1.6 years, and mean follow-up was 14.5 ± 9.8 months. Preoperative weight ranged from 127.6 to 216.9kg (mean 167.8kg) with BMI range of 41.9 to 65.3kg/m2 (mean 54.6kg/m2). Obesity related comorbid conditions included type 2 diabetes or glucose intolerance (n=4), hypertension (n=3), obstructive sleep apnea (n=7), gastroesophageal reflux disease (n=3), and hypercholesterolemia (n=2). The range of weight loss following gastric bypass was 10.2 to 110.3kg (mean 59.0kg, p<0.00001), as determined by weight at last clinic visit (follow-up range 2 to 29 months). Postoperative BMI's ranged from 25.5 to 56.3kg/m2 with a mean change of 19.0 kg/m2 (p<0.00001). Mean percent excess body weight loss was 65.0%. Systolic blood pressure decreased (131.6±14.5mmHg vs. 119.8±10.6 mmHg, p=0.036). Total cholesterol, LDL cholesterol and triglyceride levels also decreased significantly (179 vs. 134 mg/dL, p=0.048, 110 vs. 75 mg/dL, p=0.012, and 144 vs. 54 mg/dL, p=0.018, respectively). Type 2 diabetes, hypertension, sleep apnea, and hypercholesterolemia resolved in all patients under follow-up. Complications included severe thiamine deficiency (n=1), persistent iron deficiency anemia (n=2), wound infection (n=1, open operation), anastomotic stricture requiring dilation (n=1), nephrolithiasis (n=1) and respiratory arrest secondary to narcotic overuse (n=1). There were no deaths.
Conclusion: Roux-Y gastric bypass in adolescents with severe morbid obesity results in substantial weight loss and resolution of comorbid conditions, however, complications can be significant. Long-term follow-up data are required for definitive assessment for the role of bariatric surgery in obese adolescents.

S084

NON ENDOCRINE CYSTIC SOLID PANCREATIC TUMORS. PLACE OF LAPAROSCOPIC MANAGEMENT IN CHILDREN AND ADOLESCENT, Jean Stephane VALLA MD, Henri STEYAERT MD, Xavier CARPENTIER,Jean BREAUD MD, Andrei ZAVATE, Fondation LENVAL Pediatric Surgery

Introduction: The aim of this retrospective study is to review our single institution experience in a total of 12 laparoscopic pancreatic surgeries in children and to discuss the role of laparoscopy in management of pancreatic diseases.
MATERIALS: 12 patients, 4 boys with an average of 12 years (4 months to 19 years). Mean size tumor 6 cm (2 to 13cm) 7 tumors were located in the head, 3 in the corpus, 2 in the tail; in all cases, the tumor was well limited at the preoperative radiological set-up (US, CT. scan, MRI); oncological markers were negative. Various procedures have been performed: 8 enucleations (4 for solid cystic papillary tumor + 2 for duplication + 1 for congenital cystic + 1 for teratoma) 2 explorations and drainage for post-traumatic pseudo cyst, 1 partial resection for lymphangioma, 1 biopsy and marsupialisation fot multiple serious cystadenoma.
The specimen were retrieved in an endobag through enlarged umbilical hole or pfannenstiel incision (2 cases)
RESULTS: Mean operative time was 80 min. 3 cases were converted to open surgery due to large tumor and difficult dissection; 5 cases of postoperative pancreatitis but no fistula, no reoperation.No contradiction between the preoperative and final diagnosis.
After a mean follow-up of 4 years (range 1.5 to 12 years) all were alive with no recurrence
DISCUSSION: only in 4 cases the preoperative diagnosis was certain. Laparoscopy allows to perform an exploration and a guided biopsy for frozen section if necessary. In the four cases of solid- cystic papillary tumor, enucleation was possible without damage to the main pancreatic duct. Preservation of pancreatic and splenic tissue was possible in all cases.
CONCLUSION: Laparoscopic approach of benign pancreatic tumors is feasable and allows to choose for a less radical approach to surgical management.
This presentation is illustrated by a video

S085

LAPAROSCOPIC MANAGEMENT OF PANCREATIC DISEASE IN INFANTS AND CHILDREN, Steven S Rothenberg MD, Thane Blinman MD, The Mother and Child Hospital at Presbyterian/St Lukes Hospital

Introduction: Pancreatic diseases in infants and children requiring surgical intervention are relatively rare. This paper describes the laparoscopic management of hyperplasia, tumors, and pseudocysts of the pancreas.
Methods: From 1995 to 2004 10 patients age 3 weeks to 16 years and weight 3.8 to 68 Kg were treated for giant persistent pseudocyst - 7, pancreatic adenoma -2, and islet cell hyperplasia. Six of seven pseudocyst were treated with a cyst gastrostomy and one by distal pancreatectomy. The adenomas were treated by a limited local resection and a distal pancreatectomyand the case of islet cell hyperplasia by a 90% pancreatectomy.
Results: All cases were completed successfully laparoscopically. The avg operative time for the cyst gastrostomy was 64 minutes with an average time to full feeds of 5 days. The adenoma resections avg 65 minutes and the 90% pancreatectomy 100 minutes. There were no intra-operative or post-operative complications, and there has been no recurrence of the pseudocysts or hypoglycemia.
Conclusion: Laparoscopic treatment of pseudocyst, adenomas, and islet cell hyperplasia in infants and children is a safe and effective approach. Operative times are short, operative morbidity low, and clinical outcomes are excellent.

S086

LAPAROSCOPIC APPROACH IN TREATMENT OF APPENDICEAL GENERALIZED PERITONITIS IN CHILDREN: COMPARATIVE, PROSPECTIVE, RANDOMIZED STUDY, Vladimir I Kotlobovsky MD, Anatoly F Dronov MD,Aslan E Ergaliev,Damir B Dzenalaev, Department of Laparoscopic Surgery, Pediatric Hospital, Aktobe, Kazakhstan; Department of Pediatric Surgery, Russian Medical University, Moscow, Russia

Aim. Evaluation of laparoscopic approach for treatment of appendiceal generalized peritonitis in children.
Materials. Since 1991 4637 children ranged from 7 days to 16 years of age underwent laparoscopic appendectomy. In 274 (6%) cases appendicitis was complicated by generalized peritonitis. Prospective, comparative, randomized study includes 100 of those patients ranging from 1 to 14 (9,18 +-3,7) years of age in laparoscopic group, and 100 patients, ranging from 2 to 14 (8,24+-3,5) years in open group. Axilar temperature, heart rate, breath rate, leukocytes level, leukocytes index, total protein, nitrogen, urea, creatinine, total bilirubin, were analyzed before surgery and daily until 10-th day after surgery. Operation time, conversion rate, minor and major complications, gastrointestinal function repairing, length of hospital stay were also analyzed.
Results. No mortality. Contraindications rate ? 9%. Conversion rate - 2%. Operation time ? 61.7+-24 min in lap. vs. 73.2+-31 min in open group. Study demonstrates higher levels of axilar temperature, heart rate, leukocytes, leukocytes index, nitrogen, bilirubin, lower level of total protein in open group ($p<0.05$). There was significant earlier gastrointestinal function repairing in lap. group ($p<0.001$). Minor surgical complications rate - 10% in lap. group vs. 21% in open group ($p<0.05$). Major surgical complications rate - 13% in lap. group vs. 16% in open group ($p=0.55$). The rate of abscess formation was 4% in both groups. The rate of pneumonia - 1% in lap. group vs. 3% in open group ($p<0.05$), rate of critical conditions - 2% in lap. group vs. 4% in open group ($p=0.067$). Hospital stay - 15.7+-3.1 days in lap. group vs. 21.2+-3.8 days in open group.
Conclusions. Laparoscopic approach could be successfully performed more then in 90% cases of appendiceal generalized peritonitis in children. It demonstrates better post-operative results then open surgery.

S087

LAPAROSCOPIC "LEAK-FREE" TECHNIQUE FOR THE TREATMENT OF CHOLEDOCHAL CYSTS, Pablo Laje MD, Horacio Questa MD,Maria M Bailez MD, Division of Pediatric Surgery, National Pediatric Hospital "JP Garrahan", Buenos Aires, Argentina

Objective: The aim of this report is to show our experience with novel technical details for the laparoscopic treatment of choledochal cysts.
Introduction:The laparoscopic approach for the treatment of choledochal cysts has been used in our institution for more than two years. Bile leak through the end-to-end hepaticojejunostomy was a major complication in 1 patient.
Material & Method: Between June/2004 and December/2004 we operated on four patients with diagnosis of choledochal cyst by means of a leak?free technique, consisting of a single or double laparoscopic running suture to build an end-to-side hepaticojejunostomy. Ages ranged from 2 months to 6 years (mean, 3,4 years). We used a four-trocar technique in all cases. A transparietal stitch to the gall bladder neck was used to lift the liver. The hepatic bile duct was transitorily sealed with the bipolar sealer (Ligasure) while preparing the Roux-in-Y. We left no drains.
Results: Mean operative time was 360 minutes (range, 290 to 460). No leak was observed. Mean time for the hepaticojejunostomy was 25 minutes. All patients had excellent postoperative recoveries with a mean hospital stay of 5 days. All patients are asymptomatic on a mean follow up period of 4 months.
Discussion: We think that this leak-free technique is safe, easily reproducible for experienced surgeons and effective to avoid bile leaks.

S088

LAPAROSCOPIC ANTEGRADE CONTINENCE ENEMA USING A TWO PORT TECHNIQUE, Brice Antao MD, Joanne Ng MD,Julian Roberts MD, Paediatric Surgical Unit, Sheffield Children's Hospital, Western Bank, Sheffield S10 2TH, UK

INTRODUCTION: The antegrade continence enema (ACE) is an effective method of treatment of faecal incontinence and constipation. More recently laparoscopy has been used in the construction of an antegrade continence enema (ACE). We report our experience of laparoscopic ACE procedure and describe a simple laparoscopic approach to this procedure using a two port technique.
MATERIAL AND METHODS: Eleven children with intractable constipation underwent the ACE procedure laparoscopically over the last 3 years. All cases had full bowel preparation the day before surgery. This procedure was done through one 5-mm camera port and two 5-mm working ports in 8 cases and using the camera port and only one additional 5-mm working port in 3 cases. The appendix was used in 5 cases and the caecum in 3 cases with the three port technique while the appendix was used in 3 cases with the two port technique. An extracorporeal technique was used where-in the appendix/caecum was delivered through the 5-mm port site in the right lower quadrant. The mucocutaneous anastomosis was stented using a gastrostomy button.
RESULTS: Between 2001 and 2004, 11 children (9 male, 2 female) underwent a laparoscopic ACE procedure at a median age of 9 years (range 7 ? 14 years). This procedure was easy to perform and no case required conversion to an open procedure. The wash-outs via the device were commenced at a median age of 5 days (range 1-5 days). Median post-operative hospital stay was 2 days (range 1-5 days). This procedure was effective in resolving constipation in 8 cases. In 3 cases, constipation still persisted due to lack of compliance from the patient. There were no episodes of stenosis or herniation; however one case required a revision of ACE due to persistent leakage. Median follow-up period was 15 months (range 6-32 months).
CONCLUSION: Laparoscopic ACE technique is a simple and effective approach in creating an antegrade continence enema. This procedure can be done using a two port technique, which has the advantage of providing superior cosmesis.

S089

THE LAPAROSCOPIC ASSISTED TRANS-ANAL PULL-THROUGH FOR HIRSCHSPRUNG: A MULTICENTRIC EXPERIENCE IN THE LAST FIVE YEARS, M. Lima MD, G. Tursini MD,L. De Biagi MD,T. Gargano MD,G. Cobellis MD,G. Amici MD,MGR Aceti MD,G. Riccipetitoni MD,G. Mattioli MD,V Jasonni MD, Dept. Of Ped. Surgery ? ?Alma Mater Studiorum? University of Bologna,Dept. Of Ped. Surgery ? Annunziata Hospital ? Cosenza ,Dept. Of Ped. Surgery ? ?G. Salesi? Hospital ? Ancona ,Dept. Of Ped. Surgery? ?G. Gaslini? Hospital ? Genova (Italy)

Introduction
Advances in laparoscopy determinates very important modifications in the treatment of Hirschsprung disease. The aim of this study is analyse the results, of four different centres, in the treatment of Hirschsprung disease, according to Georgeson's primary laparoscopic pull-through.
Materials and Methods: In the last 4 years 74 cases of HD, in four different centres of pediatric surgery, were submitted to primary laparoscopic pull-through (LPT) according to Georgeson's technique. The age ranged between 20 days and 15 years. All were investigated by rectal suction biopsy, barium enema and anorectal manometry. No diverting colostomy was performed and the patients were managed with pre-operative bowel nursing. Surgery required 3 operative ports as described by Georgeson. The colon was examined and several biopsies were performed at different proximal levels to precisely define the normoganglionic colon. Surgery was postponed after the results of the intraoperative histochemical studies. The definitive diagnosis were: 27 ultra short segment (US), 37 recto sigmoid segment (RS), 6 long segment (LS), 1 total colonic aganglia (CA) and 3 rectosigmoid segment associated to IND extended to the left flexure. The mesocolon was divided using ligasure, bipolar or monopolar hook. After the transanal dissection was completed, the videoassisted pull-through was carried out making attention to the placement of the pedicle and of the sieromuscular cuff. The operative time ranged from 180? and 540?
Results: There were 2 conversions to open technique, while in 1 case a postoperative colostomy; no addictional intraoperative complication was found. The patients had analgesics for 24 hours. Bowel movements were

observed at 24-48 hours , the oral feeding started after 48 hours, the median hospital stay was 7 days. At follow-up 3 patients had grade I enterocolitis in the first months; 2 cases of LS and one case of RS had about 4 toilets/day. In one case of US soiling was present for 5 months postoperatively.
Conclusion: The laparoscopic pulll-through is a safe operation for almost all cases of HD. It allow to obtain several biopsies necessary to define the precise diagnosis of the disease and to perform a correct surgery. Moreover the laparoscopy permits to avoid the torsion of the vascular pedicle during the trans anal pull-through.

S090

LAPAROSCOPIC APPROACH TO PEDIATRIC EMERGENCIES -11 YEARS SINGLE SURGEON EXPERIENCE, Igor V Poddoubnyi MD, Moscow State Medico-Stomatologic University

The total number of 1767 pediatric patients underwent laparoscopic surgery during the period from 1993 to 2004 for various urgent indications:
? laparoscopic appendectomy was performed in 1250 patients (aged from 7 days to 15 years) with acute appendicitis (among them 226 with various forms of peritonitis). Conversion occurred in 5 cases (0.4%), complications rate was 1.4% (17 cases), relaparoscopy was performed in 3 cases, there were no relaparotomies;
? laparoscopic adhesiolysis for complete acute adhesive small bowel obstruction was performed in 88 patients (from 14 days to 15 years) It was successful in 81 cases (92%), conversion occurred in 6 patients with bowel necrosis or total affection of the abdominal cavity with adhesions;
? laparoscopic desinvagination was performed in 94 patients (from 2 months to 13 years) and it was successful in 87 cases (92.5%), conversion occurred in 7 patients with bowel necrosis;
? abdominal trauma was the indication for laparoscopy in 82 cases. Laparoscopic examination and manipulations made it possible to avoid laparotomy in 53 cases (64.6%);
? laparoscopic procedures were performed in 68 patients with Meckel's diverticulum pathology (bleeding, inflammation, bowel ileus). Laparoscopic diverticulum resection was successful in 64 cases (94.1%), conversion for circular bowel resection was performed in 4 cases;
? laparoscopic procedures for acute gynecological indications performed in 156 patients were successful in all cases;
? laparoscopy for other rare conditions (primary omentitis, foreign bodies, internal hernias, incarcerated inguinal hernias etc.) was performed in 29 patients, open procedure was needed in 3 cases.
Thus we can say that laparoscopic procedures were successfully performed in 1713 (96.9%) from 1767 patients with the most common emergency conditions. Conversions and complications rates were low. Laparoscopy is the method of choice for pediatric emergencies in our everyday practice.

IPEG 2005 Poster Abstracts

Basic Science

P001 MARTE, ANTONIO "VERSATILITY OF LAPAROSCOPIC APPROACH IN TREATING INGUINAL HERNIA IN ADOLESCENTS AND CHILDREN"

P002 PRASAD TR, SAI "LAPAROSCOPIC APPENDICECTOMY: A TRAINEE'S PERSPECTIVE"

Cancer

P003 LIMA, M. "LAPAROSCOPIC GONADAL BIOPSY FOR CRYOCONSERVATION"

P004 SAXENA, AMULYA "MECHANISM AND ADVANTAGES OF FIBRIN GLUE SPRAY IN LAPAROSCOPIC HEPATIC BIOPSY OF ONCOLOGICAL PATIENTS"

P005 VALLA, JEAN STEPHANE "PSEUDO TUMORAL GASTRIC DUPLICATION WITH PANCREATIC AND PULMONARY ECTOPIC TISSUE"

Colon/Bowel

P006 ALHINDI, S "LAPAROSCOPIC CHOLECYSTECTECTOMY FOR CHILDREN WITH CHOLELITHIASIS DUE TO SICKLE CELL DISEASE"

P007 ALHINDI, S "LAPAROSCOPICALLY ASSISTED APPENDECTOMY IN CHILDREN WITH COMPLICATED APPENDICITIS"

P008 ALMARAMHI, HAMDI "LAPAROSCOPIC REDUCTION OF INTUSSUSCEPTIONS IN CHILDREN"

P009 ALQAHTANI, AAYED "BENIGN NODULAR LYMPHOID HYPERPLASIA PRESENTING WITH A MASSIVE LOWER GASTROINTESTINAL BLEEDING IN A CHILD: A DIAGNOSTIC AND THERAPEUTIC CHALLENGE"

P010 BEYERLEIN, STEFAN "THE ROLE OF LAPAROSCOPY IN THE TREATMENT OF CHRONIC VOLVULUS OF THE STOMACH IN EARLY CHILDHOOD"

P012 COBELLIS, GIOVANNI "LAPAROSCOPIC ENDORECTAL PULL-THROUGH FOR THE TREATMENT OF LONG SEGMENT HIRSCHSPRUNG'S DISEASE"

P013 CZAUDERNA, PIOTR "VIDEO-ASSISTSED REMOVAL OF THE DESMOPLASTIC SMALL ROUND CELL TUMOR (DSRCT) OF THE SIGMOID - CASE REPORT."

P014 DE LAGAUSIE, PASCAL "LAPAROSCOPIC SURGERY OF OMENTUM IN CHILDREN"

P015 DE LAGAUSIE, PASCAL "ABDOMINAL LYMPHANGIOMAS IN CHILDREN: INTEREST OF LAPAROSCOPIC APPROACH"

P016 FARTACHEK, R "LAPAROSCOPIC APPENDICECTOMY: KEEPING IT SAFE, SIMPLE, AND COST EFFECTIVE."

P017 FOUAD, ETTAYEBI "MESENTERIC LIPOMA IN CHILD: TREATMENT BY LAPAROSCOPY"

P018 GIUSEPPE, LI VOTI "LAPAROSCOPIC JEJUNOSTOMY IN A CHILD WITH CHRONIC INTESTINAL PSEUDOBSTRUCTION"

P019 KEIMARI, MENDEZ "IS THERE AN ADVANTAGE IN PERFORMING OUTPATIENT LAPAROSCOPIC CHOLECYSTECTOMY IN CHILDREN?"

P020 KRAFKA, KAREL "LAPAROSCOPIC BOWEL RESECTION IN HIRSCHPRUNG´S DISEASE"

P021 LEYS, CHARLES "A COST ANALYSIS TO ESTABLISH A CLINICAL PATHWAY FOR NON-COMPLICATED APPENDICITIS: WHAT IS THE IMPACT OF LAPAROSCOPY?"

P022 LOPEZ*, PEDRO-JOSE "LAPAROSCOPIC FIXATION OF A PROLAPSING ILEOSTOMY – A CASE REPORT"

P023 MUNRO, F "LAPAROSCOPIC MANAGEMENT OF INTESTINAL PERFORATION OCCURING DURING COLONOSCOPY IN CHILDREN"

P024 NACHULEWICZ, PAWEł "LAPAROSCOPIC TREATMENT OF CROHN DISEASE."

P025 PARTRICK, DAVID "LAPAROSCOPIC MANAGEMENT OF COMPLICATED APPENDICITIS"

P026 PHILLIPS, J. DUNCAN "LAPAROSCOPIC APPENDECTOMY IN CHILDREN AFTER THE "LEARNING CURVE": A SUPERIOR OPERATION"

P027 PRASAD TR, SAI "LAPAROSCOPIC ASSISTED TRANSUMBILICAL MECKEL'S DIVERTICULECTOMY"

P028 PRASAD TR, SAI "LAPAROSCOPIC RESECTION OF TORTED MECKEL'S DIVERTICULUM IN A 13 YEARS-OLD BOY"

P029 SHIMOTAKAHARA, AKIHIRO "A CASE OF OBSTRUCTION AFTER LAPAROSCOPY-ASSISTED TRANSANAL ENDORECTAL PULL-THROUGH FOR HIRSCHSPRUNG'S DISEASE"

P030 TIRABASSI, MICHAEL "LAPAROSCOPIC RESECTION OF A COLONIC DUPLICATION"

P031 TURIAL, SALMAI "LAPAROSCOPIC MANAGEMENT OF A MISSED SUBHEPATIC APPENDICULAR ABSCESS IN A 5-YEAR-OLD CHILD"

P032 VALFRÈ, LAURA "TRANS-UMBILICAL LAPAROSCOPIC-ASSISTED APPENDECTOMY (T.U.L.A.A): RETROSPECTIVE ANALYSIS"

P033 VAN TUIL, CORNELIA "LAPAROSCOPIC EXTRA MUCOSAL BIOPSIES IN COLON DYSMOTILITY DIAGNOSIS"

P034 WELTZIEN, ALEXANDRA "TRANSUMBILICAL REPAIR OF SMALL BOWEL ATRESIA IN A NEWBORN"

P035 YAGMURLU, AYDIN "LIGATION OF THE STUMP IN LAPAROSCOPIC APPENDECTOMY: SINGLE OR DOUBLE"

P036 ZITSMAN, JEFFREY "UNEXPECTED FINDINGS DURING LAPAROSCOPIC APPENDECTOMY"

Forgut

P037 CAMPS, JUAN "LAPAROSCOPIC CLOSURE OF A PEDIATRIC GASTROCUTANEOUS FISTULA"

P038 CATANA, DAN "A NEW CASE OF BLUE RUBBER BLEB NEVUS SYNDROME IN A 15FH YEARS OLD GIRL"

P039 CENTONZE, ANTONELLA "LAPAROSCOPIC ASSISTED JEJUNOSTOMY: AN EFFECTIVE PROCEDURE FOR THE TREATMENT OF NEUROLOGICALLY IMPAIRED CHILDREN WITH FEEDING PROBLEMS AND GER"

P040 CHAN, S "CHOLECYSTECTOMY: SHIFTING GOALPOSTS IN THE LAPAROSCOPIC ERA."

P041 ELBARBARY, MOHAMED "A GIANT HIATAL HERNIA MIMICKING RIGHT DIAPHRAGMATIC HERNIA: PITFALLS IN DIAGNOSIS AND MANAGEMENT"

P042 FALCHETTI, D. "GASTROSTOMY-ASSISTED LAPAROSCOPIC NISSEN PROCEDURE FOR NEUROLOGICALLY IMPAIRED PATIENTS"

P043 GITZELMANN, CHRISTOPHER "THE EFFECT OF LAPAROSCOPIC ANTIREFLUX SURGERY ON POSTOPERATIVE DUMPING SYNDROME"

P044 GUELFAND, MIGUEL "OBESE ADOLESCENTS IN DEVELOPING COUNTRIES: LAPAROSCOPIC GASTRIC BANDING PART OF A MULTIDISCIPLANARY SOLUTION"

P045 HENNESSEY, IAIN "COMBINED LAPAROSCOPIC AND ENDOSCOPIC REMOVAL OF A MASSIVE TRICHOBEZOAR"

P046 INGE, THOMAS "BONE MINERAL CONTENT REMAINS SUPRANORMAL ONE YEAR AFTER LAPAROSCOPIC GASTRIC BYPASS IN ADOLESCENTS"

P047 LOW, YEE "LAPAROSCOPIC FUNDOPLICATION: THE PARS FLACCIDA APPROACH"

P048 MORGADO, H "LAPAROSCOPIC ANTERIOR GASTROPEXY FOR CHRONIC GASTRIC VOLVULUS"

P049 PENCE, JEFFREY "COMPARISON OF MINIMALLY-INVASIVE GASTROSTOMY TECHNIQUES IN CHILDREN"

P050 SIDLER, DANIEL "ESOPHAGEAL STENT IMPROVES VENTILATION IN A CHILD WITH A BRONCHO-ESOPHAGEAL FISTULA CAUSED BY MYCOBACTERIUM TUBERCULOSIS (MTB)"

P051 SUZUKI, MAKOTO "FLUOROSCOPICALLY GUIDED PERCUTANEOUS ENDOSCOPIC GASTROPEXY FOR ACUTE GASTRIC VOLVURUS"

P052 TANDER, BURAK "FLEXIBLE ENDOSCOPY IN ESOPHAGEAL STRICTURES"

P053 TANDER, BURAK "SAFETY PIN INGESTION AND IT'S ENDOSCOPIC REMOVAL"

P054 WOOD, JAMES "LAPAROSCOPIC GASTROSTOMY – A SIMPLE METHOD, IDEAL FOR TEACHING"

Genito-Urinary

P055 ARANDA, A "5 YEAR EXPERIENCE ON LAPAROSCOPIC ORCHIOPEXY FOR THE PALPABLE UNDESCENDED TESTIS"

P056 BOUHADIBA, N "LAPAROSCOPIC ASSISTED EXCISION OF ABDOMINO-SCROTAL HYDROCELE"

P057 CHACKO, JOB "THE MINIMALLY INVASIVE OPEN PYELOPLASTY"

P058 CLARKE, MELANIE "LAPAROSCOPIC REMOVAL OF A GIANT ADNEXAL CYST"

P059 CONTADOR, MONICA "GYNECOLOGYCAL LAPAROSCOPY IN CHILDREN"

P060 CRUCCETTI, ALBA "LAPAROSCOPIC PARTIAL HYSTERECTOMY, PROXIMAL SALPINGECTOMIES AND BILATERAL ORCHIDOPEXY IN AN INFANT WITH PERSISTENT MÜLLERIAN DUCT SYNDROME"

P061 FALCHETTI, D. "LAPAROSCOPIC GYNAECOLOGIC SURGERY IN PAEDIATRICS. A FOUR YEARS EXPERIENCE."

P062 FASCETTI LEON, F. "LAPAROSCOPIC ADRENALECTOMY FOR SINTOMATIC AND FUNCTIONING ADRENAL MASSES"

P063 GARCÍA ANDRADE, JORGE "LAPAROSCOPIC ASSISTED INGUINAL HERNIA REPAIR IN CHILDREN: OUR EXPERIENCE"

P064 KATZ, DOUG "LAPAROSCOPIC RESECTION OF A SEMINAL VESICLE CYST: A PEDIATRIC CASE REPORT"

P065 KATZ, DOUG "LAPAROSCOPIC MANAGEMENT OF UNUSUAL ADNEXAL PATHOLOGY"

P066 MORALES-JUVERA, EDGAR "WHEN ERGONOMICS MATTER, INLINE TROCARS FOR NON-PALPABLE TESTIS."

P067 OOMEN, M.W.N. "CRYPTORCHIDISM: DIAGNOSTIC LAPAROSCOPY OR INGUINAL EXPLORATION ?"

P068 PAPPARELLA, ALFONSO "ONE STEP VERSUS TWO STEP LAPAROSCOPIC FOWLER-STEPHENS ORCHIDOPEXY FOR THE HIGH ABDOMINAL TESTIS"

P069 QINGLIN, SUN "APPLICATION OF LAPAROSCOPE ON DIAGNOSIS AND SURGICAL TREATMENT OF IMPALPABLE TESTES"

P070 STROEDTER, LUTZ "LAPAROSCOPIC APPROACH TO ADNEX PATHOLOGY IN INFANTS AND CHILDREN"

P071 TADINI, BARBARA "RENAL LAPAROSCOPY IN CHILDREN: OUR EXPERIENCE"

P072 TURIAL, SALMAI "LAPAROSCOPIC-ASSISTED EXCISION OF A HUGE OVARIAN CYST"

P073 VAN TUIL, CORNELIA "LAPAROSCOPIC MANAGEMENT OF OVARIAL CYSTS: PITFALLS TERATOMA"

P074 VINARDI, S. "MCCUNE-ALBRIGHT SINDROME: LAPAROSCOPIC DIAGNOSIS"

P075 WEIL, ROBERT "NO RETRO-LOOK: RETROPERITONEOSCOPY"

P076 YARDENI, DANI "THE NONPALPABLE TESTIS - WHEN TO DO WHAT?"

P077 ZALLEN, GARRET "LAPAROSCOPIC INVERSION AND LIGATION INGUINAL HERNIA REPAIR"

Instrumentation

P078 BENKOE, THOMAS "LAPAROSCOPIC APPENDECTOMY: DO CHILDREN BENEFIT FROM THE TWO PORT-TECHNIQUE?"

P079 CHOLEWA, D "ULTRACISION IN LAPAROSCOPIC APPENDECTOMY"

P080 EL-SAIFY, WAEL "BILATERAL RENAL VEIN THROMBOSIS AND RETROPERITONEAL LAPAROSCOPIC NEPHRECTOMY IN A CHILD WITH FACTOR V (FV LEIDEN) MUTATION; CASE REPORT NO1"

P081 EL-SAIFY, WAEL "PAEDIATRIC INGUINAL HERNIOTOMY AND EVALUATION OF THE CONTRALATERAL INTERNAL RING IN THE LAPAROSCOPIC ERA"

P082 YIP, PETER KF "A SIMPLE AND SECURE METHOD TO FIX LAPAROSCOPIC TROCHARS IN CHILDREN"

Neonatal

P083 ALLAL, H "EARLY LAPAROSCOPIC KASAI'S IN A LOW WEIGHT NEWBORN. CASE REPORT"

P084 BLINMAN, THANE "LAPAROSCOPIC REPAIR OF NEWBORN CONGENITAL DIAPHRAGMATIC HERNIA"

P085 ESPOSITO, CIRO "THE EVOLUTION OF DIAGNOSIS AND TREATMENT OF 50 NEONATAL OVARIAN CYSTS IN A 22 YEAR PERIOD"

P086 GUVENC, B HALUK "MANAGEMENT OF OVARIAN CYSTS DURING INFANCY; AUTOAMPUTATION PRESENTING AS A POSSIBLE PITFALL"

P087 KOZLOV, YURI "FULL SPECTRUM OF MINIMALLY INVASIVE SURGERY IN INFANTS IN THE FIRST 3 MONTHS OF LIFE"

P088 NICHOL, PETER "RETROSPECTIVE COMPARISON OF OUTCOMES OF LAPAROSCOPIC VERSUS OPEN PYLOROMYOTOMY AT A HIGH VOLUME PEDIATRIC SURGERY CENTER"

P089 SAXENA, AMULYA "LAPROSCOPIC RESECTION OF LARGE CONGENITAL HEPATIC CYST IN NEWBORN"

IPEG 2005 Poster Abstracts

Neurosurgery

P090 GREWAL, HARSH "MICRO-LAPAROSCOPIC-ASSISTED LUMBOPERITONEAL SHUNT IN THE LATERAL POSITION FOR PSEUDOTUMOR CEREBRI IN A MORBIDLY OBESE CHILD"

Other

P091 BELTRÀ, RAIMUNDO "MEDIASTINUM PROLAPSE OF GASTRIC WRAP IN NISSEN FUNDOPLICATION IN CHILDREN. LAPAROSCOPIC CORRECTION"

P092 BELTRÀ, RAIMUNDO "POST-CHOLECYSTECTOMY BILIAR LEAKAGE. TREATMENT WITH OCTREOTIDE ASSOCIATED TO LAPAROSCOPY."

P093 BUEHLIGEN, ULF "ABDOMINAL SHUNT REVISIONS IN CHILDREN WITH HYDROCEPHALUS IN ONE TROCAR TECHNIQUE"

P095 DAGASH, HAITHAM "LAPAROSCOPIC TOTAL EXTRAPERITONEAL (TEP) HERNIA REPAIR:INITIAL EXPERIENCE"

P096 GEISS, S. "LAPAROSCOPIC APPROACH IN IMPERFORATE ANUS"

P097 HARASYMCZUK, JERZY "VIDEO-ASSISTED BREST REDUCTION PROCEDURE FOR GYNECOMASTIA IN TEENAGERS"

P098 LI, CHENGCHANG "USING LAPAROSCOPIC EXPLORATION AND IRRIGATION OF EXTRAHEPATIC DUCTS FOR CHOLESTATIC JAUNDICE IN INFANT"

P099 LIMA, M. "LAPAROSCOPIC ASSISTED ANORECTAL PULL-THROUGH FOR HIGH IMPERFORATE ANUS: THREE YEARS EXPERIENCE"

P100 MUTHURANGAM, RAMANUJAM "PEDIATRIC LAPAROSCOPIC SURGICAL SERVICE (PLSS) IN A GENERAL HOSPITAL: PROBLEMS, PROGRESS & LIMITATIONS IN A DEVELOPING COUNTRY"

P101 MUTHURANGAM, RAMANUJAM "MISPLACED HISTOACRYL INJECTION DURING SCLEROTHERAPY - LEADING TO BLEEDING, LIVER ABSCESS & MIGRATION INTO THE PULMONARY CIRCULATION"

P102 MUTHURANGAM, RAMANUJAM "ROLE OF DIAGNOSTIC LAPAROSCOPY IN UNCOMMON ABDOMINAL CONDITIONS"

P103 PATKOWSKI, DARIUSZ "THE EFFICACY OF PERCUTANEOUS INTERNAL RING SUTURING (PIRS)- A SIMPLE MINIMAL INVASIVE TECHNIQUE FOR INQUINAL HERNIA REPAIR IN CHILDREN"

P104 PIAGGIO, LISANDRO "COMPARISON OF LAPAROSCOPY VERSUS OPEN PARTIAL NEPHRECTOMY IN CHILDREN"

P105 PORRECA, A. "VIDEOASSISTED "GEORGESON" PULL-THROUGH FOR HIRSCHSPRUNG'S DISEASE IN THE FIRST 2 MONTHS OF LIFE. REPORT OF 11 CASES"

P106 PORRECA, A. "THE USE OF LIGASURE™ IN 18 CASES OF SPLENIC LAPAROSCOPIC SURGERY."

P107 RADOJCIC, BRANKA "THE FIRST YEAR EXPERIENCE WITH LAPAROSCOPIC PEDIATRIC SURGERY"

P108 SAXENA, AMULYA "LAPAROSCOPIC INGUINAL HERNIA REPAIR: SIGNIFICANCE OF SAC RESECTION"

P109 SHIDI, RASHEED "CONSERVATIVE SURGICAL CONDUCT ON GALL BLADDER LESSIONS"

P110 SPYRAKOS, S. "PLUMBISM AFTER PROLONGED RETENTION OF LEAD FOREIGN (PB) BODIES"

P111 TURIAL, SALMAI "LAPAROSCOPIC DAY-CARE SURGERY IN CHILDREN"

P112 VALDIVIESO, JUAN "THE RABBIT MODEL FOR TEACHING AND TRAINING PEDIATRIC LAPAROSCOPIC SURGERY: 5 YEARS EXPERIENCE"

P113 WALDSCHMIDT, J "EXPERIENCE WITH HEMANGIOMAS OF THE LARYNX AND TRACHEA IN 56 CHILDREN"

P114 WALKER, GREGOR "PROSPECTIVE EVALUATION OF PAEDIATRIC LAPAROSCOPIC TRAINING EXPERIENCE AND COMPETENCY"

P115 WALKER, GREGOR "OMENTAL HERNIATION FOLLOWING LAPAROSCOPIC PYLOROMYOTOMY"

P116 WILDHABER, BARBARA "RETROPERITONEAL CYSTIC LYMPHANGIOMA: LAPAROSCOPIC EXCISION IN TOTO"

Robotics

P117 KANT, ADRIEN "ROBOT-ASSISTED LAPAROSCOPIC RESECTION OF CHOLEDOCHAL CYST WITH ROUX-EN-Y RECONSTRUCTION"

P118 LAM, VINH "ROBOT ASSISTED PULMONARY RESECTION IN A CHILD WITH CCAM"

P119 TAMBURI, DRA. NATALIA "ROBOTICALLY-ASSISTED PROCEDURES IN THE MANAGEMENT OF GERD IN INFANTS AND CHILDREN"

Spleen/Solid Organ

P120 CONTADOR, MONICA "LAPAROSCOPIC SPLENECTOMY FOR HEMATOLOGICAL DISEASES IN CHILDREN"

P121 DUFFY, BRIAN "LAPAROSCOPIC EXCISION OF CONGENITAL HEPATIC CYSTS IN THE PEDIATRIC POPULATION: A CASE SERIES AND LITERATURE REVIEW"

P122 EL-SAIFY, WAEL "LAPAROSCOPIC PANCREATIC SURGERY IN THE PAEDIATRIC POPULATION; A LITERATURE REVIEW"

P123 FALCHETTI, D. "WISKOTT-ALDRICH SYNDROME: ANOTHER INDICATION FOR LAPAROSCOPIC SPLENECTOMY IN CHILDREN"

P124 FALCHETTI, D. "LAPAROSCOPIC TREATMENT OF A WANDERING CYSTIC SPLEEN"

P125 JANIC, NENAD "LAPAROSCOPIC PARTIAL PERICYSTECTOMY OF HYDATIDE LIVER CYST IN CHILDREN"

P126 KLEINER, OLEG "A RARE CASE OF PEDIATRIC WANDERING SPLEEN SUCCESSFULLY TREATED BY LAPAROSCOPIC SPLENOPEXY"

P127 MATTHYSSENS, LUCAS "THERAPEUTIC ENDOSCOPIC RETROGRADE CHOLANGIO-PANCREATICOGRAPHY WITH PAPILLOTOMY IN AN INFANT WITH ACUTE PANCREATITIS : A CASE OF PANCREAS DIVISUM"

P128 PEIRO, JOSE LUIS "LAPAROSCOPIC SPLENECTOMY IN CHILDREN"

P129 PHILIPPE, PAUL "REGRESSION OF HEPATIC FIBRONODULAR HYPERPLASTIC LESIONS AFTER LAPAROSCOPIC LIGATION OF A CONGENITAL EXTRAHEPATIC PORTOCAVAL SHUNT"

P130 SAKAMOTO, JUN "A CASE WITH A PANCREATIC PSEUDOCYST AFTER LAPAROSCOPIC SPLENECTOMY"

P131 SHLASKO, EDWARD "EXPERIENCE WITH USE OF THREE-PORT TECHNIQUE FOR LAPAROSCOPIC SPLENECTOMY IN CHILDREN"

P132 VALDIVIESO, JUAN "LAPAROSCOPIC CHOLECYSTECTOMY IN CHILDREN: 7 YEARS MULTI-CENTRIC EXPERIENCE"

P133 YAGMURLU, AYDIN "IS EN BLOC STAPLING OF SPLENIC HILUM IN LAPAROSCOPIC SPLENECTOMY SAFE?"

Thoracoscopy

P134 ALMULHIM, SAAD "THORACOSCOPIC RIGHT MIDDLE LOBECTOMY FOR HYDATID CYST"

P135 ALTOKHAIS, TARIQ "THORACOSCOPIC PROCEDURES IN PEDIATRICS: SAFETY AND FEASIBILITY"

P136 BERCHI-GARCIA, FRANCISCO JOSÉ "MINI-INVASIVE LOBECTOMY IN INFANTS AND CHILDREN"

P137 GUVENC, B. HALUK "VATS AS AN ADJUNCTIVE TOOL IN THE MANAGEMENT OF CONGENITAL ARTERIOVE-NOUS MALFORMATION OF THE CHEST WALL"

P138 ISHKOVA, SVETLANA "CHANGING OF BREATH MECHANIC DURING THE VIDEOTORACOSKOPIC OPER-ATIONS IN CHILDREN WITH EMPYEMA"

P139 KOZLOV, YURI "THORACOSCOPIC SURGERY IN NEONATES: EXPERIENCE FROM SIBERIA"

P140 MANKOWSKI, PRZEMYSLAW "VIDEO-ASSISTED SUR-GERY OF THORAX IN PAEDIATRIC ONCOLOGY."

P141 MCLEOD, ELIZABETH "THORACOSCOPIC GUIDED PLEU-RAL BIOPSY AS AN AID TO DIAGNOSIS OF PAEDIATRIC TB"

P142 MESSINEO, ANTONIO "TREATMENT OF WOUND SEROMA, A RARE COMPLICATION OF NUSS PROCE-DURE"

P143 PENCE, JEFFREY "FIBRINOLYTIC SALVAGE THERAPY FOR POSTOPERATIVE RECURRENT PARAPNEUMONIC EFFU-SION IN COMPLEX PEDIATRIC EMPYEMA"

P144 AZZIE, GEORGES "THORACOSCOPIC RESECTION OF ESOPHAGEAL DUPLICATION IN CHILDREN: REPORT OF TWO CASES"

P145 SHIMOTAKAHARA, AKIHIRO "THE "NUSS PROCEDURE". OUR EXPERIENCE OF MINIMALLY INVASIVE REPAIR OF PECTUS EXCAVATUM."

P146 STROEDTER, LUTZ "THORACOSCOPIC THYMECTOMY IN CHILDREN"

P147 VALLA, JEAN STEPHANE "NEUROGENIC MEDIASTINAL TUMOR REMOVAL BY THORACOSCOPY 7 CASES"

P148 VILLALPANDO C, RICARDO "THORACOSCOPIC APPROACH FOR CONGENITAL CYSTIC LUNG DISEASE IN PEDIATRIC PATIENTS"

P149 WALDSCHMIDT, J "THORACOSCOPY (VATS) IN PEDI-ATRIC CHYLOTHORAX"

P150 GVOZDIKOV, V.S. "APPLICATION OF LASER TECHNOLO-GIES IN LAPAROSCOPIC SURGERIES IN CHILDREN"

P151 KAPUSTIN, V.A. "LAPAROSCOPIC APPENDECTOMY IN TREATING APPENDICULAR PERITONITIS IN CHILDREN"

P001 – Basic Science

VERSATILITY OF LAPAROSCOPIC APPROACH IN TREATING INGUINAL HERNIA IN ADOLESCENTS AND CHILDREN, Antonio Marte BA, Micaela Borrelli MD,Pasquale Cautiero MD,Mercedes Romano MD,Maria Domenica Sabatino MD,Antonio Vessella MD,Alfonso Papparella BA, Second University of Naples

Purpose: This study was aimed to evaluate the results of laparoscopic repair of inguinal hernia and associated pathologies in children and adolescents.
Methods: The records of 44 patients (30 boys and 14 girls) who underwent laparoscopic hernia repair at our institution between June 2003 and June 2004 were reviewed. Their mean age was 3.2 years (range, 4 months to 18 years). No hernia opening was found in two patients, whereas 2 bilateral hernias were found laparoscopically. Two patients presented incarcerated omentum. In 4 patients with hydrocele , the internal ring was sutured and the hydrocele evacuated through the scrotum whereas the hydrocele of cord was simply incised and evacuated laparoscopically. 3 patients underwent laparoscopic Palomo varicocele ligation with LigaSure followed by internal ring suture (1 patient presented recurrent inguinal hernia) . The hernia repairs were all performed with the use of a transumbilical 5 mm Hasson's port and 2 reusable 3-mm ports and a round polypropylene stitch passed directly into the abdominal cavity through the abdominal wall. In all patients, inguinal ring was sutured with an N shaped fashion and grabbing some underlying tissue , not only peritoneum.
Results. After a mean follow-up of 9.6 months no patient presented recurrent inguinal hernia. The procedure yelded satisfactory cosmetic results and no major complication (testicular atrophia) was recorded. For recurrent hernias after open repair, the laparoscopic method was as simple as fresh hernia repair. The simultaneous varicocele sealing was uneventful and well tolerated.
Conclusion. The procedure is versatile, can be safely performed with the added advantages of lower costs, no recurrences, and improved cosmesis. A long term follow-up study is needed for further evaluation.

P002 – Basic Science

LAPAROSCOPIC APPENDICECTOMY: A TRAINEE's PERSPECTIVE, Sai Prasad TR MD, Chan Hon Chui MD,Anette Jacobsen MD, Department of Paediatric Surgery, KK Women's and Children's Hospital, Singapore

Introduction
We report the results of laparoscopic appendicectomy done by a trainee in pediatric laparoscopic surgery and analyse the safety and efficacy as a laparoscopic training procedure.
Methods
A retrospective analysis of all the consecutive cases of laparoscopic appendicectomy done by a trainee in pediatric laparoscopic surgery from September 2003 to January 2005 was done. The conversion rate, complications, operative duration and duration of hospital stay were analysed.
The procedure was done through 3 ports; 1 umbilical 10mm camera port and 2 working ports in the left iliac fossa and suprapubic region. The base of the appendix was ligated with a pretied polyglactin loop suture (vicryl endoloop, Ethicon) and removed through the umbilical port. Closed suction drain was placed in the pelvis after peritoneal lavage in cases of appendicular perforation and peritonitis.
Results
A total of 56 consecutive patients (30 males and 26 females) with acute appendicitis aged 3-15 years (mean 10.4 years) underwent laparoscopic appendicectomy. 8 patients had acute appendicitis (AA), 19 had acute suppurative appendicitis (ASA) adherent to caecum with localized and/or pelvic pus pocketing, 26 had perforated gangrenous appendicitis (APA) with generalized peritonitis and 3 had normal appendix. There were no operative complications and none required conversion to open surgery. 3 patients underwent simultaneous laparoscopic assisted transumbilical meckel's diverticulectomy (LATUM); one with perforated meckel's diverticulum (MD) and secondary appendicitis and 2 with incidental narrow based MD. The operative duration ranged from 25 minutes to 110 minutes; 25-95 minutes for AA or ASA (mean 47.5 mins) and 35-110 minutes (mean 76.2 mins) for APA. The hospital stay ranged from 1-14 days; 1-7 days (mean 3.3 days) for AA or ASA and 3-14 days (mean 5.8 days) for APA. There were 2 complications; 1 had adhesive intestinal obstruction and underwent successful laparoscopic adhesiolysis and 1 had umbilical wound infection.
Conclusions
Laparoscopic appendicectomy in children is a safe and also an effective laparoscopic training procedure.

P003 – Cancer

LAPAROSCOPIC GONADAL BIOPSY FOR CRYOCONSERVATION, M. Lima MD, G. Ruggeri MD,M. Domini MD,S. Tursini MD,L. De Biagi MD,T. Gargano MD,A. Gentili MD, Paediatric Surgery, University of Bologna, Via Massarenti 11, 40138 Bologna, Italy

Introduction: Many malignant diseases and some non-malignant conditions require to be treated with chemotherapy or radiant therapy, which at certain doses make human infertile. Cryoconservation of ovarian tissue is one of the actual techniques for fertility preservation. Laparoscopy has been already used with great success in the treatment of adnexial pathologies. Therefore, we have used laparoscopy to collect large ovarian specimens in young female patients before starting a therapy against cancer.
Methods: In 4 years we submitted 9 patients (4 children and 5 young girls) to laparoscopic gonadal specimen collection. The older patient, aged 18, had an rabdomyosarcoma. An ?open laparoscopy? approach was used: a 10 mm laparoscope was introduced into the peritoneal cavity. Two 5 mm trocars were introduced in the lower abdominal quadrants. Once the ovaries were identified, large ovarian specimen were taken, frozen and sent to the Department of Gynaecology for storage.
Results: All procedures were successfully performed. No complication occurred. The post-operative period was uneventful and short. Tissues are still frozen and stored at ?196° C at the Reproductive Medicine Unit.
Conclusions: Cryoconservation of gonadal tissue is an experimental method that has recently gained interest. Technology for gonadal tissue preservation is continuously evolving. Sure valid results are difficult to be guaranteed. At thawing of cryoconserved ovarian tissues the percentage of survived follicles is between 72 and 89%. Methods to preserve fertility include cryopreservation of embryos, oocytes and ovarian tissues. Cryoconservation of ovarian tissues avoid the ethical dilemmas about the future of embryos. Moreover, primordial follicles are less sensitive then oocytes to temperature changes. The gametogenesis is preserved, thus fertility and steroidogenetic activity after autologous gonadal transplant. We believe that laparoscopy is the best tool to be used in these cases: it is minimally invasive and it is a safe and simple procedure with minimal scars.

P004 – Cancer

MECHANISM AND ADVANTAGES OF FIBRIN GLUE SPRAY IN LAPAROSCOPIC HEPATIC BIOPSY OF ONCOLOGICAL PATIENTS, Amulya K Saxena MD, Cornelia van Tuil MD, Pediatric Surgical University Medical Center, Münster, Germany

Laparoscopic hepatic biopsies in oncological patients require more attention because of the presence of a "sick liver". Oncological patients, who require biopsies to rule out hepatic masses or metastases, are generally on chemotherapy and as a result manifest with coagulation disturbances. Hepatic biopsies in children with coagulation disturbances can be quite challenging. Once the biopsy site has been located under vision and a desired size of tissue has been obtained all attention is paid to the control of blood loss from the biopsy site. Although primarily monopolar cautery or laser may be applied to control the large loss of blood, a sealant is required to check the further oozing of blood. Fibrin glue has been frequently used in the conventional way to control bleeding from parenchymatous organs. However, spray applications of Tisseel® (Baxter Inc, Germany) has further more advantages. The mechanism of action has been studied in details. The spray application enables the coverage of a larger surface area and allows for a uniform seal formation. Blood loss can be controlled immediately and the same spray may be used for further interrupted applications without coagulation of the specially designed spray head. Special applicator spray head now allow for the installation of fibrin glue on the surface of the liver in laparoscopic procedures. The fibrin spray appears as uniform foam during laparoscopic application, which forms an effective elastic seal. Sealing of the biopsy site is achieved within approximately 15 seconds and is sufficient to control acute as well as delayed loss of blood despite coagulation disturbances.

P005 – Cancer

PSEUDO TUMORAL GASTRIC DUPLICATION WITH PANCREATIC AND PULMONARY ECTOPIC TISSUE, Jean Stephane VALLA MD, Jean BREAUD MD, Xavier CARPENTIER,henri STEYAERT MD, fondation LENVAL Pediatric surgery

AIM: To report an exceptionnal case of gastric duplication managed by laparoscopy.
MATERIAL: Out of 17 duplication enteric cysts managed by laparoscopy in our department, 4 were located on the stomach and one of them was discovered by a visible and palpable abdominal mass in a two years old girl. US, CT scann, MRI revealed a large mass, heterogeneous (one liquid part [65x 40mm] with septa plus one solid irregular part [46x35 mm])located behind the stomach. Several preoperative diagnosis were discussed : teratoma, neuroblastoma, pancreatic cystic tumor, lymphangioma, duplication. All tumoral markers (Alfa foeto protein, VMA, HVA) were normal. A four trocarts laparoscopic approach was performed and the stomach suspended to the abdominal wall. The tumor was sticked to the anterior part of the pancreas and the posterior part of the stomach; ultrasonic dissection allowed complete resection without opening the stomach.
RESULT: No complication. Histology confirmed the diagnosis of gastric duplication with heterotopic pancreatic tissue in the liquid part and heterotopic pulmonary tissues in the solid part.
DISCUSSION: Gastric duplication should be considered in the differential diagnosis of intra or retroperitoneal masses. Laparoscopic management allowed first an exploration and biopsies for frozen sections (answer : mature teratoma) and secondly complete resection in the same time. If pancreatic ectopia is quite usual in gastric duplication, pulmonary ectopia is exceptionnal and could be considered as an associated intraabdominal extralobar pulmonary sequestration.
CONCLUSION: minimally invasive surgery allow to resect enteral duplication even if they are large and deeply localised, without opening the intestinal tract. The presentation is illustrated by a video

P006 – Colon/Bowel

LAPAROSCOPIC CHOLECYSTECTECTOMY FOR CHILDREN WITH CHOLELITHIASIS DUE TO SICKLE CELL DISEASE, S Alhindi MD, Salmaniya medical complex

Aim:
Laparoscopic cholecystectomy for children with cholelithiasis due to sickle cell disease is rarely reported and its place and safety is yet to be established.
Methods:
A prospective study was conducted between January 1996 to June 2004.All children with sickle cell disease underwent laparoscopic cholecystectomy on elective basis received exchange blood transfusion and intravenous hydration 24 hour before surgery as well prophylactic antibiotic.
Laparoscopic cholecystectomies were done by 4-trocar 5mm in diameter and the gall bladder was removed through umbilical port. We used clip for cystic duct and diathermy for cystic artery. All patients had local anaesthesia at trocar sites
Results:
38 children with cholelithiasis due to sickle cell disease underwent laparoscopic cholecystectomy. The age of the patients range between 2 ? 12 years .The operative time was 50-65 minutes and hospital stay range between 1-3 days .Complication in this study included, conversion of one case due to difficult anatomy, intraoperative perforation of the gall bladder in other case and one umbilical omental eventration. No patient required opiate analgesia or blood transfusion.
Conclusion:
Laparoscopic cholecystectomy in children with sickle cell disease is safe and required minimal analgesia

P007 – Colon/Bowel

LAPAROSCOPICALLY ASSISTED APPENDECTOMY IN CHILDREN WITH COMPLICATED APPENDICITIS, S Alhindi MD, Kingdom of Bahrain ,Salmaniya medical complex ,Division of pediatric surgery

Aim :
Different methods of laparoscopic appendectomy have been used in children with simple acute appendicitis . However, in complicated appendicitis, limited laparoscopic procedure have been used.We describe laparoscopically assisted appendectomy in children with complicated appendicitis.
Method:
A prospective study conducted between January 2003 to december 2004, where all children under the age of 12 year underwent laparoscopically assisted appendectomy in cases of complicated appendicitis by one surgeon using two trocars, 10 mm for ifra-umbilical fold and 5mm trocar in left grion skin crease. All patient had local anaesthesia at trocar sites as well diclofenac suppositories
Cases of fixed appendicular mass were excluded.
Results:
73 children with complicated appendicitis underwent laparoscopically assisted appendectomy. All patients received antibiotic for 7-10 days postoperative. Hospital stay between 7-10 days. Operative time range between 40-65 minute. Analgesia requirement is minimal for all patient. No blood transfusion needed. Three patient developed complication, one had umbilical wound infection treated conservatively and another developed pelvic collection treated by antibiotic and the third has the appendex divided into two parts requiring delivery of the retracted part again by laparoscopically assisted method in same session.
Conclusion:
Two port laparoscopic assisted appendectomy is safe in complicated appendicitis in children and has excellent cosmosis.

P008 – Colon/Bowel

LAPAROSCOPIC REDUCTION OF INTUSSUSCEPTIONS IN CHILDREN, Hamdi Almaramhi MD, Aayed R Alqahtani MD, College of medicine & King Khalid university Hospital, Riyadh, Saudi Arabia

Background: Intussusceptions is a fairly common problem in children. Approximately 85% of intussusceptions in children are reduced by pneumatic or hydrostatic enemas. The remaining will require surgical intervention. However, 10% of those infants undergoing surgical exploration were found to have reduced spontaneously . In order to reduce the number of unnecessary surgical exploration, different laparoscopic assisted techniques have been described. In most of them the reduction was assisted by an intra-operative enema. Our experience with none-assisted laparoscopic reduction of intussusception is presented with a detailed description of the technique.
Methodes: The clinical records of all children with intussusceptions undergoing laparoscopic reduction at our institution during a period of two years were reviewed retrospectively. Demographic data, clinical presentation, duration of symptoms, diagnostic and therapeutic modalities were evaluated. Follow up was also obtained.
Results: between November 2002 and November 2004, 8 patients underwent laparoscopic reduction of intussusceptions. There were 6 boys and 2 girls with an average age of 14 months (range: 4 to 30 months). 3 patients had the symptoms for more than 24h prior to their presentation. Two were diagnosed clinically and six were diagnosed by abdominal ultrasound. All patients underwent unsuccessful hydrostatic contrast enema reduction. Successful laparoscopic reductions were achieved in all cases. There were no complications. Fluid diet was started after full recovery from anesthesia and was tolerated by all patients. They were all discharged within 24h post-operatively. The follow-up reported no complaints or recurrences.
Conclusion: We believe that the laparoscopic reduction of intussusceptions is a safe and a successful procedure. In addition to the usual advantages of minimally invasive procedures, It will eliminate unnecessary laparotomies in some patients. It is our believe that It does not need to be assisted by intra-operative air or other types of enemas.

P009 – Colon/Bowel

BENIGN NODULAR LYMPHOID HYPERPLASIA PRESENTING WITH A MASSIVE LOWER GASTROINTESTINAL BLEEDING IN A CHILD: A DIAGNOSTIC AND THERAPEUTIC CHALLENGE, Aayed R Alqahtani MD, College of medicine & King Khalid university Hospital, Riyadh, Saudi Arabia

Benign nodular lymphoid hyperplasia of the terminal ileum in children is a rare entity. Moreover, it is exceedingly rare to present with a massive gastrointestinal bleeding requiring an urgent surgical resection. Herein, we report a 10-years old girl who presented with a massive lower gastrointestinal bleeding. She continued passing fresh blood per rectum and transfused 6 units of packed red blood cells. All pre-operative localizing studies, including Meckel's scan, colonoscopy and gastroscopy, failed to

identify the exact source of bleeding. On table retrograde and antegrade enteroscopies were able to localize submucosal lesions at the terminal ileum, compatible with a nodular lymphoid hyperplasia. Laparoscopic assisted limited right hemi-colectomy was performed and the patient was cured.

P010 – Colon/Bowel

THE ROLE OF LAPAROSCOPY IN THE TREATMENT OF CHRONIC VOLVULUS OF THE STOMACH IN EARLY CHILDHOOD, Stefan Beyerlein MD, L Stroedter MD,J Schleef MD,M E Hoellwarth PhD, Dept. Of Paediatric Surgery, University Medical Centre, Graz (Austria)

Aim:
Chronic volvulus of the stomach in early childhood is rare, organoaxial and can be managed non-operatively in most of the cases. Surgical treatment is indicated in patients who failed to improve with conservative management. The techniques are discussed controversial in the literature.
Method:
A retrospective study (1995-2003) of a series of 6 children (3 female, 3 male, mean age at surgery 3.2 years) is presented, being refractory to conservative treatment for more than 3 months. The initial operation was an anterior gastropexy. 5 of the 6 operations were performed laparoscopically. The mean post-op observation time is 3 years with a range of 0,6 to 7,3years.
Results:
One child was completely free of symptoms after laparoscopic anterior gastropexy. The other 5 children reported a relief of symptoms but showed no weight gain and persistent gastroesophageal reflux, which was confirmed by upper GI studies and pH-metry. 3 of these children were reoperated due to increasing symptoms and underwent laparoscopic Toupet procedure. The further course of these children was uneventful. For the other 2 children a conservative antireflux regimen was sufficient to gain good results.
Conclusion:
Our limited experience suggests that in this group of children with chronic, recurrent volvulus of the stomach and no improvement with conservative treatment, a simple anterior gastropexy might not be sufficient. These patients seem to require a more complex antireflux procedure. All surgical procedures can safely be performed laparoscopically even then if redo procedures are needed.

P012 – Colon/Bowel

LAPAROSCOPIC ENDORECTAL PULL-THROUGH FOR THE TREATMENT OF LONG SEGMENT HIRSCHSPRUNG's DISEASE, Giovanni Cobellis, Alba Cruccetti,Luciano Mastroianni,Rosella Tallarico,Michele Ilari,Giuseppe Amici,Ascanio Martino, Pediatric Surgery Unit, Salesi Children's Hospital ? Ancona, Italy

Introduction: Recently laparoscopic primary treatment of Hirschsprung's disease (HD) has been widely performed. The laparoscopic technique is still rarely reported for the staged pull-through of long segment HD. We report our early experience in the staged laparoscopic endorectal pull-through of long segment HD.
Patients and procedures: Between November 2001 and April 2003 we treated 3 infants with radiological evidence of long segment aganglionosis. The age of the patients was between 6 days and 4 months. In all patients we performed at the same time rectal biopsy, multiple laparoscopic biopsies and a stoma proximally to the aganglionic segment. The histology showed distal left colon aganglionosis (proximal to the splenic flexure) in two patients and total colonic aganglionosis (TCA) with 15 cm of small intestine involved in one. The two patients with distal left colon aganglionosis were operated on at the age of 8 months, whereas the TCA patient was operated on at 14 months. All three patients underwent stoma closure and laparoscopic endorectal pull-through according to Georgeson's technique.
Results: There were no intra-operative or early post-operative complications in all three patients. The mean operative time was 270 minutes. The two infants with distal left colon aganglionosis (both with preoperative enterocolitis and one affected by Down syndrome) had recurrent post-operative enterocolitis during the first year post-op. In one of these patients the anorectal manometry showed high anal tone and internal sphincter miectomy was performed 7 months after operation. At the 22 months follow-up these two patients had a moderate constipation and no episode of enterocolitis for the last 12 months. At the 9 months follow-up the patient with TCA had a regular growth curve and frequency of defecation was 1 - 3 times daily without perianal excoriations.
Conclusion: Our preliminary experience shows that laparoscopic surgery can be safely performed in the treatment of long segment aganglionosis, with good efficacy even in patients with colostomy.

P013 – Colon/Bowel

VIDEO-ASSISTSED REMOVAL OF THE DESMOPLASTIC SMALL ROUND CELL TUMOR (DSRCT) OF THE SIGMOID - CASE REPORT., Piotr Czauderna PhD, Anna Balcerska PhD,Andrzej Golebiewski MD, Department of Pediatric Surgery and Department of Pediatrics, Hematology and Oncology, Medical University of Gdansk, Poland.

10-year-old girl was admitted due to the huge abdominal mass with preliminary diagnosis of ovarian cyst which was supported by abdominal US and CT. Markers for germinal tumors were negative. On laparoscopy ovaries were found to be normal, while 10 cm tumor arising from sigmoid mesentery was found. The tumor was mainly cystic but contained a solid part, too. Tumor was dissected laparoscopically with bipolar cautery from the colon and removed completely together with the piece of omentum through minilaparotomy in the lower abdomen. Other abdominal organs (liver, spleen, omentum, mesenteric lymph nodes and parietal peritoneum) were unchanged.; no metastases were found. Microscopic diagnosis was desmoplastic small round cell tumor. The patient was put on postoperative chemotherapy according to CWS protocol for soft tissue sarcomas. Due to the short follow-up it is difficult to assess the patient's final outcome.
DSRCTs are extremely rare pediatric tumors associated with very poor prognosis (20-30% overall survival at 3 years). Most reports deal with single cases only. Complete tumor removal with aggressive chemotherapy and abdominal irradiation remain the cornerstone for cure. To our best knowledge no laparoscopic removal of DRSCT was reported.

P014 – Colon/Bowel

LAPAROSCOPIC SURGERY OF OMENTUM IN CHILDREN, Pascal de LAGAUSIE PhD, Allaa el GHONEIMI PhD, Arnaud DELARUE MD, Jean Michel GUYS PhD, Hôpital la Timone (Marseille, France) et Robert Debré (Paris, France)

Introduction: One such organ, the omentum is harvested via a laparotomy. Because laparoscopy could be used in children for diagnosis and for treatment in many abdominal or retro-peritoneal situations, omentopexy or omentectomy are done also by laparoscopic surgery.
Material and methods: we reviewed all procedures using omentum in the last five years during laparoscopy in children, in two surgical paediatric team (hospital: Timone and Robert Debré).
Results: Omentectomy (partially or totally) was used in three situations: omental torsion, mimicking acute appendicitis (2 cases), localization of lymphangioma (4 cases of which one was revealed by a chronic ascite), and second look after ovarian teratoma (1 case). Omentopexy (or omental packing) was used in many indications: after partial splenectomy (3 cases of epidermoid cyst), liver kystectomy (2 cases of which one was hydatic cyst), postro-inferior pseudo cyst of the pancreas drained by laparoscopy (1 case), persistent lymphocele after kidney transplantation (1 case), ablation of pyelic cyst (1 case), omentectomy during laparoscopic implantation of peritoneal dialysis catheters (5 cases).
Discussion: It is now basis evidence that omentum play an important role in cicatrisation and in immunizing defence. With important qualities of reinsertion, great omentum participle in septic or lymphatic effusion reduction. We considered that omentopexy is a simple procedure, safe and inexpensive. It could be used in many procedure, particularly in case of partial reduction of solid organ. Like in open surgery, use of epiploon is possible in plastic, thoracic or pelvic procedures. Great omentum could be the localization of specific pathology: omental torsion, lymphangioma, lipoma, angioma and secondary localisation in case of ovarian tumour. In these cases, omentectomy could be easily performed by laparoscopic approach, even in small child.
Conclusion: omentum could be used in many cases during laparoscopic procedure. We have to think to this possibility, in order to reduce secondary complications.

P015 – Colon/Bowel

ABDOMINAL LYMPHANGIOMAS IN CHILDREN: INTEREST OF LAPAROSCOPIC APPROACH, Pascal de LAGAUSIE PhD, Arnaud BONNARD MD, Dominique BERREBI MD, Karine LAMBOT MD, Claude LOUIS-BORRIONE MD, Arnaud DELARUE MD, Jean-Michel GUYS PhD, Service de Chirurgie Pédiatrique et de Radiologie, Hopital d'enfant la Timone, 264

rue Saint Pierre, 13005 Marseille (France), Service de Chirurgie Pédiatrique et d'anatomo-pathologie, Hopital Robert Debré, 46 Bld Serrurier, 75019 Paris (France)

SUMMARY :
Lymphangiomas are rare benign lesions of the lymphatic system. The most common symptoms were abdominal tumour or ?acute abdomen? in children. The treatment of choice is complete surgical resection, but the recurrence rate with incomplete resection is high, and laparotomy expose to adhesions. We report our experience in lymphangiomas laparoscopic approach.
Patients and methods: It is a retrospective study of 15 consecutive operations for lymphangiomas in children (5 months- 14 years), treated during a 5 years period (1999-2004).
Results: 6 were treated by primary laparotomy approach. 9 patients were treated by laparoscopic procedure, 6 successfully. 3 conversions were necessary (one case requiring partial colectomy, one retroperitoneal case with adherence on aorta and vena cava, one case with partial volvulus). Morbidity include 2 cases of acute occlusion caused by adhesions after laparotomy. There were no recurrence of lymphangioma (mean follow-up: 35 months).
Discussion: laparoscopy procedure could be successfully used in case of abdominal lymphangioma, even in emergency. When the laparoscopic resection is impossible, laparotomy or sclerotherapy could be discussed.

P016 – Colon/Bowel

LAPAROSCOPIC APPENDICECTOMY: KEEPING IT SAFE, SIMPLE, AND COST EFFECTIVE., A A Mahomed MD, R Fartachek MD, V MacLean RN, Department of Paediatric Surgery, Royal Alexandra Children's Hospital, Brighton, UK.

Aim:
To monitor in theatre surgical costs and outcome of laparoscopic appendicectomy over a defined period. To determine what cost savings could be achieved without compromise to safety of patients.
Methods:
A prospective audit was carried out over a 15 month period between 11/10/03 and 11/01/05. All patients, who were operated on by a single surgeon, had detailed costs of inventory for laparoscopic appendicectomy compiled on a case by case basis and recorded on a proforma by a dedicated theatre nurse. Costs were based on estimates provided by hospital managers and overall costs per procedure were collated on a Microsoft Access database and changes in cost over the period of the study, analysed. Additional data on patient demographics, intraoperative complications and post operative performance was retrieved and processed in similar manner.
A standard 3 port technique with exclusive use of hook diathermy for division of the mesoappendix was utilised in all cases. Patients were discharged when well and reviewed at 6 weeks post operatively. SPSS was used for basic statistical analysis.
Result:
A total of 18 cases, 8 males and 10 females, with mean age of 12.2 years, were recorded over the study period. Three of the appendices were gangrenous, 2 suppurative and 3 perforated. 5 patients had surgery for chronic right iliac fossa pain.
Mean operating time was 61 minutes. There were no intra-operative complications, in particular no significant bleeding and no conversions despite the varied stage of appendicitis. Mean post operative stay was 48 hours and there was one readmission without re-operation.
The in- theatre surgical costs were brought down from £221.43 per procedure to £41.02 with most of the cost savings made by usage of non disposable ports, instruments and haemostatic dissecting device.
Conclusion:
The in-theatre surgical cost of laparoscopic appendicectomy is progressively falling to levels comparable to open procedures. Being cost prudent does not compromise patient safety. Exclusive use of a hook diathermy device for mesoappendiceal dissection is safe and integral to the cost saving strategy.

P017 – Colon/Bowel

MESENTERIC LIPOMA IN CHILD: TREATMENT BY LAPAROSCOPY, Ettayebi Fouad, KISRA Mounir,BENHAMMOU Mohamed, Rabat University, children's Hospital, Morocco

Mesenteric Lipoma is a rare benign tumor of mature fat cells. The aetiology is not well known. Generally asymptomatic. It occasionally causes abdominal pain, ileus and small bowel volvulus.
Ultrasonography and C.T. scan of the abdomen show this lesion as homogeneous mass with fat density surrounded by a thin capsule.
We report a 8-year-old child with a mass in the low-abdomen and recurrence pain. The patient has been treated by laparoscopy. Three port has been used.
Total excision without the affected intestinal loop was possible. Then the lipoma was exteriorised via the ombilicus.
- Histology confirmed a lipoma with non evidence of malignancy
- The patient made a good recovery with no symptoms reported at follow-up 1 year later.

P018 – Colon/Bowel

LAPAROSCOPIC JEJUNOSTOMY IN A CHILD WITH CHRONIC INTESTINAL PSEUDOBSTRUCTION, Li Voti Giuseppe MD, Amoroso Salvatore MD,Milazzo Mario MD, Chirurgia Pediatrica, Osp. Casa del Sole,Università di Palermo,

Objective of the study: chronic intestinal pseudo-obstruction (CIP) is a severe condition characterized by recurrent symptoms of bowel obstruction, in the absence of lumen-occluding lesions. Because of motility disorders, since neonatal age these children show failure to thrive,vomiting, constipation and malnutrition. Long term enteral nutritional support, by gastrostomy or jejunostomy, appears the gold treatment. We performed a laparoscopy-assisted jejunostomy in a patient with CIP. Our technique is described and results discussed.
Methods and procedures: a 14 years old male child, affected by CIP, was admitted to our Unity with severe malnutrition. He had undergone, two years before, a duodeno-jejunal anastomosis because of a diagnosis of duodenal compression by superior mesenteric artery. He had no improovement from this operation. Xray study demonstrated a persistent Gastroparesis. A short term trial of nasojejunal feeding was effective in weight gain. Because of the special anatomical pattern detrmined from the previous operatio we performed a laparoscopy-assisted jejunostomy and inserted a mic key button for feeding.
A 5 mm laparoscopic camera port was placed through the umbilicus, by an open access. Two further 5 mm ports were placed in the left lower quadrant and in the cross-point of umbilical transverse line and left breast midline.The camera was moved to the inferior port site. Avoiding adhesions we managed to find the first jejunal loop. A bowel segment, approximately 10 cm distal to the ligament of Treitz, was softly grasped and brought up to the abdominal wall at the left upper port site. Bowel was secured to abdominal wall by few unabsorbable sutures and minimally ostomy was done in order to insert a the jejunostomy button. We correct position of the botton was checked by laparoscopy.Enteral nutrition restarted via nasojejunal tube 3 days postoperatively and via jejunostomy 8 days later. We observed no intraoperative complications or difficulties because of previous surgery adhesions.
Conclusions: laparoscopy-assisted jejunostomy is a safe and effective procedure to achieving enteral access in patients with CIP.

P019 – Colon/Bowel

IS THERE AN ADVANTAGE IN PERFORMING OUTPATIENT LAPAROSCOPIC CHOLECYSTECTOMY IN CHILDREN?, Mendez Keimari MS, Sabater Roberto MS,Lugo-Vicente Humberto MD, Department of Surgery, U.P.R. School of Medicine, Puerto Rico

Laparoscopic cholecystectomy is a procedure generally performed leaving the child overnight after surgery.
Purpose: Determine if there is an advantage in performing outpatient laparoscopic cholecystectomy while setting clinical parameters for those who will benefit from in-hospital postop stay. Material: From 2000-2004, a single pediatric surgeon performed 52 laparoscopic cholecystectomies in two institutions. From these patients, only those admitted and operated the same day of surgery were selected for the study (35 patients). Patients were divided in Group A, for procedure done outpatient, and Group B, if the child was left for overnight observation. Outpatient defined as discharged the same day of surgery. Retrospective review of

charts compared preoperative demography, symptoms, operative parameters, complications, associated medical conditions, medical expenses and postoperative hospital stay between both groups.
Results: Group A consisted of 13 patients and Group B consisted of 22 patients. All patients in Group A left the hospital the same day of surgery. Distribution by age, sex, duration of symptoms or use of preoperative imaging studies in the groups was not statistically different. Presence of an associated medical condition was higher in the in-hospital patients (Group B) but difference was not statistically significant, neither was the presence of an associated hematologic condition. Some patients had a concomitant procedure during the same intervention with no statistic difference between groups. Neither were differences in intra-operative parameters like blood loss estimates or duration of surgery. One patient, from group B, developed post-operative complication of repetitive vomiting with no statistical difference. Pain management was the same in both groups. The difference of the mean postoperative stay was statistically significant between group A (3 hours) and B (23 hours). Difference in medical expenses was also statistically significant with mean of $538 for group A and $886 for group B.
Conclusions: Laparoscopic cholecystectomy is a procedure that can be safely done sending the child the same day of surgery. Children harboring a complicated gallbladder disease process or associated medical condition benefits from overnight observation. Pain management is crucial in both cases. Reduced hospital stay and medical expenses are significant advantages in performing laparoscopic cholecystectomy as an outpatient procedure.

P020 – Colon/Bowel

LAPAROSCOPIC BOWEL RESECTION IN HIRSCHPRUNG´S DISEASE,
Karel Krafka MD, Jiri Tuma MD, Clinic of pediatric surgery, Faculty Hospital Brno

Introducion: We describe our initial experience using laparoscopy in a child with Hirschprung´s disease.
Methods: Our patient aged 1 year with intial colostomy after biopsy confirmed Hirschprung´s disease underwent laparoscopic bowel resection.Our procedure was done using 5mm camera ,two 5mm and one 3mm working ports,the transition zone was evaluated during the operation after a laparoscopic seromuscular frozen biopsy (rectosigmoid area). After the
laparoscopic mobilisation of the rectosigmoid the dissection to the pelvis was done and the Swenson procedure performed.The operation time was 320 minutes.The colostomy closure followed after 1 month after the laparoscopic resection.
The functional outcome is very good with no constipation and good cosmetic result.
Conclusion:The laparoscopic approach to the treatment of children with Hirschprung´s disease has a very good cosmetic and functional outcome.

P021 – Colon/Bowel

A COST ANALYSIS TO ESTABLISH A CLINICAL PATHWAY FOR NON-COMPLICATED APPENDICITIS: WHAT IS THE IMPACT OF LAPAROSCOPY?,
Charles M Leys MD, Harold N Lovvorn MD,Mary T Austin MD,Eddie L Lambert BS,Wallace W Neblett MD, Department of Pediatric Surgery, Vanderbilt University Medical Center

Introduction: With intent to create a cost-effective clinical pathway for non-complicated acute appendicitis, our aim was to test whether shorter hospital stays could justify the cost of the laparoscopic approach. While clinical pathways may optimize utilization of health care resources, the impact of laparoscopy on a pathway for appendicitis has not been determined.
Methods: We reviewed the medical and financial records of all patients who underwent appendectomy for non-perforated, non-gangrenous acute appendicitis at our children's hospital from January 2002 to June 2004. Statistical analyses used Chi-square and Student's t-tests.
Results: We identified 146 patients treated for non-complicated appendicitis: 60 with laparoscopic appendectomy (LA) and 86 with open appendectomy (OA). Mean hospital costs were $4,908 for LA and $3,955 for OA (P<0.001). Operating room costs were $2,729 for LA and $1,718 for OA (P<0.001). However, the mean post-operative length of stay was significantly shorter for LA (35.7 hours) versus OA (43.1 hours, P=0.002). Discharge within 24 hours occurred in only 9% after OA, but in 27% after LA (P=0.005). The additional hospital capacity created by shorter post-operative stays after LA could generate a $25,000 incremental profit margin over the next 100 laparoscopic cases.
Conclusions: Laparoscopic appendectomy for non-complicated acute appendicitis facilitates earlier discharge, yet is associated with higher operative costs. Shorter hospital stays after laparoscopic appendectomy can translate into additional hospital revenue over time, which may justify the immediate expense of the laparoscopic approach. In conjunction with a clinical pathway to streamline post-operative care, laparoscopy may permit even greater reductions in length of stay and prove a cost-effective adjunct.

P022 – Colon/Bowel

LAPAROSCOPIC FIXATION OF A PROLAPSING ILEOSTOMY ? A CASE REPORT,
Pedro-Jose Lopez* MD, Neil Shall° MD,Joe Curry * MD, Department of Paediatric Surgery * and Paediatric Gastroenterology°, Great Ormond Street Hospital, London

INTRODUCTION: Prolapse remains a common and troublesome symptom for many children who require a stoma. Fortunately for the majority, the stoma will be temporary. However for some it will be necessary to have the stoma for years if not lifelong. A technique that can offer reliable stabilisation in the event of prolapse and be performed entirely laparoscopically would be a huge advantage. We report our attempt at such a procedure in a 5-year-old girl with intestinal dysmotility and chronic constipation who had required an ileostomy and who was severely troubled with significant prolapse.
METHODS: A 5mm Hasson port was placed, using an open technique, in the left flank. Two further 5mm working-ports were positioned in the left upper quadrant and the left iliac fossa, respectively. The peritoneum at the back of the anterior abdominal wall, next to the ileostomy, was opened for approximately 10cm. The ileum adjacent to the stoma was stitched to the back of anterior abdominal wall at the free edge of the peritoneum with interrupted 3/0 Prolene? (as demonstrated on video). Ports were closed with Vicryl? and Indermil glue?.
RESULTS: Enteral feed was commenced on full recovery from anaesthesia. The child was discharged the following day with no complications. There has no been further stomas prolapse at 4 months follow-up.
CONCLUSION: This technique clearly requires further evaluation and with the likely difficulty that will be encountered on closure, will probably only be applicable to prolapse in the long term stoma. Nevertheless It does appear be highly effective and a technically very straightforward procedure.

P023 – Colon/Bowel

LAPAROSCOPIC MANAGEMENT OF INTESTINAL PERFORATION OCCURING DURING COLONOSCOPY IN CHILDREN,
F D Munro MD, James A Morecroft* MD,A D Ram* MD,Gregor Walker MD, Royal Hospital for Sick Children, Edinburgh and Booth Hall Children's Hospital*, Manchester

Purpose
Perforation of the intestine occurs in one per 1700 diagnostic examinations. Immediate repair is recommended if the perforation is recognised during the procedure. We report successful laparoscopic management of intestinal perforation occurring during colonoscopy in 3 children.
Methods
Review of case records and operative videos
Results
3 children (ages 3,12 and 15 years) had perforation of the intestine recognised during diagnostic colonoscopy. In all cases an immediate laparoscopy was undertaken. The perforations were easily found (descending colon, sigmoid colon and terminal ileum). Extensive serosal tears were also noted in the sigmoid colon in two cases. In one case an extensive tear of the sigmoid was exteriorised through a minilaparotomy incision in the left iliac fossa and repaired. In the other two cases the perforations were sutured laparoscopically. All three patients made an uneventful recovery following surgery. One patient was diagnosed subsequently with Crohn's disease, one with non specific colitis and the third had no colonic abnormality.
Conclusion
Intestinal perforation is a recognised risk of colonoscopy. As the bowel has been prepared prior to the examination, peritoneal soiling is usually minimal and primary repair of the perforation is recommended if this is recognized early. Laparoscopic repair appears to be safe in these circumstances and allows more rapid recovery with only minimal abdominal scars.

P024 – Colon/Bowel

LAPAROSCOPIC TREATMENT OF CROHN DISEASE., Pawe? Nachulewicz PhD, Hor Ismail PhD,Anna Chy?yñska MD,Piotr Kaliciñski PhD, Children Memorial Health Institute Dapartment of Pediatric Surgery and Organ Transplantatio, Warsaw, Poland

The laparoscopic resection of ileocecal segment in Crohn's disease is a well described procedure. In many centers it is procedure of choice when operative treatment is indicated.
Case presentation
Authors presents very severe case of Crohn's disease, where inflammatory changes were localized not only in ileocecal region but also in anus, rectum, and sigmoid colon.
Long term conservative treatment was not effective, and patient was qualified to operative treatment. Laparoscopic operation was performed. The ileocecal region was excised and ileostomy was exposed. Distal colon was cut by stapler device and freely left in abdomen. There were no intra- or postoperative complications. The patient was discharged five days after operation. During eight month observation the general condition of the patient has been improved. Ileostomy is very well tolerated. Gaining of weight is being observed. The steroids treatment was withdrawn. Closure of the ileostomy is planned after min 2 years of observation.
The authors presents operative technique and video from the operation.

P025 – Colon/Bowel

LAPAROSCOPIC MANAGEMENT OF COMPLICATED APPENDICITIS, David A Partrick MD, John Petty MD, Richard J Hendrickson MD, Denis D Bensard MD, Frederick M Karrer MD, The Children's Hospital, University of Colorado

Background: Laparoscopic appendectomy is a well-described and established technique to treat acute appendicitis. However, the operative approach to perforated appendicitis remains controversial due to concerns of increased morbidity from intraabdominal abscess formation following laparoscopy in these cases. The purpose of this study is to determine if laparoscopic appendectomy leads to an increased risk of intraabdominal abscess formation in cases of complicated appendicitis.
Methods: All laparoscopic appendectomy cases with gross as well as pathologic confirmation of appendiceal perforation were reviewed over a two year period. Data collected included patient age, radiographic studies, operative and pathologic findings, length of stay, and postoperative complications.
Results: Out of 266 laparoscopic appendectomies performed, 53 (20%) had complicated appendicitis with evidence of perforation. Eleven of these were treated initially with abscess drainage followed by interval laparoscopic appendectomy 6-8 weeks later. The remaining 42 patients (mean age 8.5 years) had a primary laparoscopic appendectomy performed with one child (2%) converted to an open procedure. Preoperative CT scans revealed evidence of perforation with free intraabdominal fluid in 17 patients, intraabdominal abscess in 9 patients, phlegmon in 4 patients, and a small bowel obstruction in 3 patients. Mean length of hospital stay was 5.2 days with a range from 2 - 16 days. Five patients had a drain placed intraoperatively within a well-formed abscess cavity. Five other patients (12%) developed an intraabdominal abscess within a week postoperatively, four of which required CT-guided percutaneous drainage.
Conclusions: Complicated appendicitis can be managed successfully laparoscopically with a low conversion rate even with preoperative evidence of abscess or phlegmon formation. The 12% incidence of postoperative intraabdominal abscess formation is well within the incidence of 10 - 30% following open appendectomy reported in the literature.

P026 – Colon/Bowel

LAPAROSCOPIC APPENDECTOMY IN CHILDREN AFTER THE "LEARNING CURVE": A SUPERIOR OPERATION, Douglas York BS,Angela Smith BS,Daniel vonAllmen MD, J. Duncan Phillips MD, University of North Carolina at Chapel Hill and WakeMed Hospital, Raleigh, North Carolina

Purpose: Despite its increasing popularity, several recent studies comparing laparoscopic appendectomy (LA) with open appendectomy (OA) in children have failed to demonstrate significant improvements in patient outcomes. Most series include the "learning curve," wherein the surgeon inexperienced with laparoscopic techniques compares his/her results to OA with its extensive history. This study was designed to investigate outcomes in pediatric appendectomy patients managed by surgeons with extensive laparoscopic experience.
Methods: Retrospective review of 197 consecutive children undergoing appendectomy for presumed acute appendicitis from January 2002 through May 2004 at a university-affiliated community hospital by pediatric and general surgeons, each with extensive laparoscopic surgical experience. Patients received all pre-, intra-, and postoperative care by the same emergency department staff, anesthesiologists, surgical residents, and nurses.
Results: 116 patients underwent LA and 81 underwent OA. LA and OA patients had similar ages, histories, temperatures, and preoperative white blood counts. Only 2 LA patients required "conversion" to OA. Of 122 acute (non-gangrenous, non-perforated) appendicitis cases, mean operation times were 47 minutes (LA) and 48 minutes (OA) (p=NS). The LA group (n = 71) had a faster return to full diet (17.6 hours vs. 28.6 hours, p = 0.0008), and shorter post-operative length of stay (LOS) (1.06 days vs. 1.66 days, p<0.0001) when compared to the OA group (n = 51). Complication rates, time on intravenous (IV) antibiotics and IV opiates were similar among the two groups. Complicated appendicitis cases (gangrenous or perforated) (LA, n = 34; OA, n = 26) were similar, and showed no significant differences between groups with regard to LOS, return to normal bowel function, complication rate, and time on IV antibiotics or opiates. In these patients, LA was associated with an increased operation time (LA, 65min; OA, 51 min, p = 0.02). The negative appendectomy rate was 7% (LA, n = 11; OA, n = 4).
Conclusion: Following the completion of the laparoscopic surgery "learning curve," LA has a comparable operation time and results in a decreased post-operative LOS, and faster return to normal bowel function when compared to OA in children with acute non-gangrenous, non-perforated appendicitis. Operation times were increased for LA in complicated appendicitis cases, but outcomes were comparable among LA and OA groups.

P027 – Colon/Bowel

LAPAROSCOPIC ASSISTED TRANS-UMBILICAL MECKEL's DIVERTICULECTOMY, Sai Prasad TR MD, Chan Hon Chui MD,Anette Jacobsen MD,Tan Eng Looi Carolyn MD, Department of Paediatric Surgery, KK Women's and Children's Hospital, Singapore

Introduction
We present the experience of a trainee in pediatric laparoscopic surgery, in the diverse presentations and laparoscopic management of meckel's diverticulum (MD) in children and analyse the safety and efficacy of the procedure.
Methods
Retrospective analysis of all the consecutive cases of laparoscopic meckel's diverticulectomy done by a trainee in pediatric laparoscopic surgery from January 2004 to January 2005 was done.
The procedure, laparoscopic assisted trans-umbilical meckel's diverticulectomy (LATUM) was done through 3 ports; 10mm umbilical camera port and 5mm working ports in the left iliac fossa and supra pubic region (omitted in cases of bleeding MD). The MD was delivered through the umbilical incision. Resection of MD and anastomosis was done extracorporeally with single layered interrupted polyglactin sutures (vicryl, Ethicon).
Results
8 patients (2 males and 6 females) aged 3-13 years (median, 12 years) underwent LATUM. 3 patients had painless per-rectal bleeding and 1 patient presented with features of intestinal obstruction due to a mesodiverticular band and intestinal ischaemia. 2 patients had features masquerading as appendicitis; one had perforated MD forming a mass along with secondary inflammation of appendix, and the other had a torted and gangrenous MD. In 2 patients, incidental MD with a narrow base was noted at appendicectomy for appendicitis. All patients underwent successful LATUM procedure along with appendicectomy in 3 patients. The operative duration was 72-165 minutes (mean, 112 mins). There were no operative complications and none required conversion to open surgery. The hospital stay was 4-7 days (mean 4.7 days). Ectopic gastric epithelium was found in all the 3 patients with bleeding MD and 1 patient with incidental MD. One of the bleeding MD also had ectopic pancreatic tissue. The patient with meckel's band intestinal obstruction presented with adhesive intestinal obstruction 2 weeks after the surgery. Laparoscopic assisted minilaparotomy was done to release the pelvic adhesions. There were no other complications during the follow-up.

Conclusions
LATUM is a safe and effective procedure with a better cosmetic outcome that can be performed for diverse manifestations of MD. The technique also allows palpation of the MD and avoids usage of expensive staplers.

P028 – Colon/Bowel

LAPAROSCOPIC RESECTION OF TORTED MECKEL's DIVERTICULUM IN A 13 YEARS-OLD BOY, Sai Prasad TR MD, Chan Hon Chui MD,Anette Jacobsen MD, Department of Paediatric Surgery, KK Women's and Children's Hospital, Singapore

Introduction
We report an unusual case of acute abdomen due to a torted meckel's diverticulum (MD) in a 13-years-old boy and illustrate the efficacy of laparoscopy in the diagnosis and management of acute surgical abdomen.
Methods
The clinical features, investigations, laparoscopic management and follow-up were noted.
Results
A 13 years old male presented with acute lower abdominal pain, one episode of blood streaked stools and low-grade fever for one day's duration. On examination the right iliac fossa was extremely tender with a positive rebound tenderness. The haemogram was normal except for a marginally raised total white count of 11,600/mm3 (4,500-11,000/mm3). The Ultrasonogram revealed free fluid in the paracolic gutter and probe tenderness at the right iliac fossa. At laparoscopy, a torted and gangrenous MD that was retort shaped with a narrow pedicle and multiple twists was found covered with omentum and adherent to the parieties at the right iliac fossa. The MD was resected successfully after ligating the narrow base with a pretied loop suture (vicryl endoloop, Ethicon) and was delivered through the umbilicus. The entire procedure was performed through one 10mm umbilical camera port and two 5mm working ports at the left iliac fossa and suprapubic region. The histopathological examination revealed a completely infarcted lesion. The postoperative recovery was uneventful and the patient was discharged on the 4th post-operative day.
Conclusions
Torsion of the MD is a rare form of complicated MD and we believe this is only the third case described in children and the first to be managed entirely by laparoscopy. This case also illustrates the versatility of laparoscopy in the diagnosis and management of acute abdominal conditions in children.

P029 – Colon/Bowel

A CASE OF OBSTRUCTION AFTER LAPAROSCOPY-ASSISTED TRANSANAL ENDORECTAL PULL-THROUGH FOR HIRSCHSPRUNG'S DISEASE, Akihiro Shimotakahara PhD, Atsuyuki Yamataka PhD,Hiroyuki Kobayashi PhD,Go Miyano BA,Junichi Kusafuka BA,Geoffrey Lane PhD,Takeshi Miyano PhD, Department of Pediatric General and Urogenital Surgery, Juntendo University School of Medicine

Purpose To report a case of obstruction after laparoscopy-assisted transanal endorectal pull-through (LTEPT) for Hirschsprung?fs disease (HD).
Case report A 4-week-old boy with biopsy-proven HD underwent LTEPT. Laparoscopy showed a caliber change at the sigmoid colon. Before pull-through, the posterior rectal cuff was split along its entire length cranially, starting from the dentate line. Biopsy-proven normo-ganglionic colon was then successfully pulled-through. The initial postoperative recovery was uneventful, however, after three weeks, he developed abdominal distension typical of obstruction. Suction rectal biopsy of the neo-rectum was normo-ganglionic. Barium enema demonstrated narrowing of the rectum with proximal colonic dilatation, and, on digital examination, there was a palpable circumferential stenosis 4cm proximal to the anal margin, suggesting that the obstruction was secondary to a residual rectal cuff. Dilatation was attempted several times, but failed to resolve the obstruction. Re-operation through a posterior sagittal approach was performed and confirmed the presence of a residual rectal cuff surrounding the neo-rectum circumferentially. The dorsal side of the residual rectal cuff was removed completely. Postoperatively, he was free from obstruction. Currently, he is 4.5 years-old and his bowels open 2 to 4 times a day with occasional staining.
Conclusion Operative findings suggested that the rectal cuff that had originally been split had re-approximated spontaneously after LTEPT, or that the distal part of the posterior rectal cuff had retracted into the proximal rectal cuff and become folded when the colon was being pulled-through. This case implies that near-total excision of the posterior rectal cuff is mandatory during LTEPT for HD to eliminate the risk for post-operative obstruction; in other words, splitting the muscular rectal cuff alone is inadequate.

P030 – Colon/Bowel

LAPAROSCOPIC RESECTION OF A COLONIC DUPLICATION, Michael V Tirabassi MD, Kevin P Moriarty MD, Baystate Medical Center Children's Hospital, Tufts University School of Medicine

Case Report:
A previously healthy eighteen-year-old female presented to the emergency department with sudden onset of severe left lower quadrant abdominal pain, fever, and tachycardia. Symptoms began two hours prior to admission and were not associated with nausea, vomiting, or constipation. Laboratory studies were significant for a leukocytosis of 16.8 and a negative urine pregnancy test. Abdominal ultrasound was only significant for a small amount of free pelvic fluid. CT scan of the abdomen and pelvis was significant for a thin walled fluid collection in the left mid-abdomen adjacent to the descending colon. The patient was taken to the operating room for exploratory laparoscopy. A ruptured colonic duplication was identified attached to the transverse colon and omentum. The descending colon and splenic flexure were mobilized and the omental attachments of the enteric duplication were divided. Following this the segment of the transverse colon that was densely adherent to the enteric duplication was delivered through a Bianchi type incision. The enteric duplication cyst was then dissected from the transverse colon. There was no communication between the cyst and the lumen of the transverse colon. The patient was discharged home on the second post-operative day tolerating a regular diet, her symptoms alleviated.

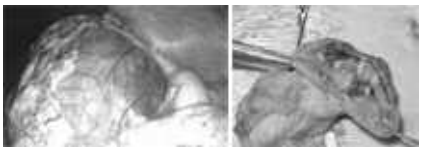

P031 – Colon/Bowel

LAPAROSCOPIC MANAGEMENT OF A MISSED SUBHEPATIC APPENDICULAR ABSCESS IN A 5-YEAR-OLD CHILD, Salmai Turial MD, G Abdul-Aziz,R Brzezinska MD,V Engel MD,F Schier, Pediatric Surgery, University medical centre Mainz, Germany

Objective:
To demonstrate a case of laparoscopically treated and originally missed subhepatic perforation of the appendix.
Method:
A 5-year-old child presented to a regional hospital with abdominal pain and vomiting. Markers of acute inflammation were very high (WBC 16,1/nl, CRP 138,4 mg/l) Abdominal sonography was normal. Chest X-ray suggested a right-sided pneumonia and a right-sided subdiaphragmatic air-fluid level. Despite antibiotics, the general condition worsened throughout the next 2-weeks therapy. The pleural effusion increased and required tapping. Now, ultrasound suggested a liver abscess secondary to basal pneumonia. Percutaneous drainage under sonographic guidance failed due to intestinal loop interposition. The child was transferred. Laparoscopy revealed a subhepatic perforation of the appendix. The 250 ml pus was drained.
Results:
The preoperative diagnosis of an intrahepatic abscess was incorrect; the lesion was extrahepatic. Laparoscopic evacuation was easy.
Postoperative recovery was prompt.
Conclusion:
Missing perforations of an atypically positioned appendix in children is

not uncommon. Laparoscopy can be helpful in cases of doubtful ultrasonography.

P032 – Colon/Bowel

TRANS-UMBILICAL LAPAROSCOPIC-ASSISTED APPENDECTOMY (T.U.L.A.A): RETROSPECTIVE ANALYSIS, R Gesmundo, L. Valfrè, S. Vinardi,E. Maiullari,F Canavese, Regina Margherita, Torino Italy

Introduction: appendectomy is one of the most commonly performed surgical procedures in general surgery and laparoscopic appendectomy represents the beginning of minimal invasive era in visceral surgery. But until yet, laparoscopic appendectomy is not the standard method for removal of the appendix and discussion about the value and the advantages of laparoscopic appendectomy is still going on.
Aims: The authors report their experience about trans-umbilical laparoscopic assisted ?one-trocar? appendectomy (T.U.L.A.A.) in a retrospective analysis. From november 2001 to December 2004 we have managed 94 patients (59 females and 35 males).
Results: We have analysed 94 T.U.L.A.A.: 68 surgical routine and 26 in urgency. The surgical mean time was 38 minutes: 37.9 minutes in routine and 38.2 in urgency. The histological evaluation shows 60 hyperemics appendicitis, 25 phlegmonosics and 9 empyematosics.
Conversion to the open procedure was necessary in 1 patient.
Complications: 1 peritonism the second day after surgery and 2 suppurations of the cut.
Conclusions: T.U.L.A.A. in the treatment of appendicitis allows to explore the addominal cavity completely and resolve associated pathologies; the aesthetical results are better; correction of umbilical hernia is possible and postoperative pain is reduced; quick recanalization ; shorter hospitalization and time inactivity.
There are few disadvantages: the use of only one instrument doesn?t allow the mobilization of subsierosa appendix or strongly adherent to the intestinal loops; the small umbilical breach doesn?t allow the passage of large gangreneted appendix without risking laceration. The duration of T.U.L.A.A. is comparable to laparotomic approach (mean time 29.5 minutes). There is no time difference between routine and urgency laparoscopic approach.

P033 – Colon/Bowel

LAPAROSCOPIC EXTRA MUCOSAL BIOPSIES IN COLON DYSMOTILITY DIAGNOSIS, Cornelia van Tuil MD, Amulya K Saxena MD, Pediatric Surgical University Medical Center, Münster, Germany

Although Hirschsprungs disease is ruled out in most patients with motility disorders using standard rectal biopsy techniques, dysmotility disorders of the colon are extremely difficult to diagnose in a vast majority of patients. Elaborate diagnosis of such patients is only possible after inspection of the colon and obtaining multiple biopsies for histopathological investigations. In such cases it was traditionally opted against taking serial colon biopsies due to the invasiveness of the open technique. The laparoscopic extra mucosal biopsy (LEMB) technique has been found suitable for such patient groups. This technique requires no or little colon preparation and can be performed as a day care procedure. LEMB is performed using an umbilical optic port along with two work ports using 3.5 mm or 5 mm instruments depending on the age of the child. The procedure involves identification of pathological colonic segments, incision of the taenia libera using metzenbaum scissors without opening the colonic mucosa, elevation of the biopsy edge and further preparation between the mucosa and serosa using metzenbaum scissors until the desired length of the biopsy has been obtained. In case of bleeding that may obscure vision at the site of biopsy, saline washings are utilized. In none of the cases performed at our center, a colon mucosal injury/ perforation was encountered. LEMB is a safe technique which is easy to perform. After entering the abdominal cavity it takes an average of 2 ? 3 min to take a biopsy. LEMB in our practice is a minimal invasive technique to obtain serial colon biopsies without morbidity for extensive histopathological examinations in severe motility disorders of the colon.

P034 – Colon/Bowel

TRANSUMBILICAL REPAIR OF SMALL BOWEL ATRESIA IN A NEWBORN, Alexandra Weltzien MD, Salmai Turial MD,Felix Schier MD, Department of Pediatric Surgery, University Medical Centre Mainz, Germany

Objective: To demonstrate a case of laparoscopy-assisted correction of an ileal atresia.
Method: The intestinal atresia was known prenatally. Two days after birth, a 10-mm trocar was inserted at the umbilicus for a thoracoscope featuring a coaxial 5-mm working channel. A 2-mm trocar was inserted at the left lower abdomen for manipulation of the bowel. An atretic segment was found in the right lower abdomen and exteriorized at the umbilicus together with the 10-mm trocar.
Results: Exteriorization was easy. The prolapsed bowel segment was not incarcerated and could be followed for considerable length proximally and distally. The anastomosis was identical to the open approach. The postopertaive course was uneventful.
Conclusion: A combined approach enjoys the advantages of both: the technical ease of open anastomosis and the almost scarless access of minimally-invasive surgery. The technique deserves further study.

P035 – Colon/Bowel

LIGATION OF THE STUMP IN LAPAROSCOPIC APPENDECTOMY: SINGLE OR DOUBLE, Hulya Ozkan-Ulu MD,Gulnur Gollu MD,Mine Fedakar MD,Meltem Bingol-Kologlu MD,Huseyin Dindar MD, Aydin Yagmurlu MD, Department of Pediatric Surgery, Ankara University School of Medicine

Insufficient closure of the appendix stump can lead to intra-abdominal abscess formation or peritonitis. Hence, we aimed to compare single ligation of the stump with double endoloop usage in pediatric laparoscopic appendectomy.
A retrospective chart review was performed in 156 children who underwent laparoscopic appendectomy. Operation was performed using a single endoloop on the appendiceal stump in 39 children, and with double endoloop in 117. Eight patients in double ligation group and 15 children in single ligation group had perforated appendicitis. The operative time was shorter in children with both acute and perforated appendicitis who underwent a single ligation of the stump (48.4±1.5 min versus 58.1±3.3 min in acute, 75.3±5.7 min versus 93.8±8.8 min in perforated, $p<0.05$). Length of hospital stay was similar for both groups. Postoperative complications were found in three patients (7.7%) in double ligation group, consisting of intraabdominal abscess, stump appendicitis and postoperative intussusception. In single ligation group, there was only one intraabdominal abscess formation (0.85%) ($p<0.05$).
In conclusion, limited with the retrospective nature of the data, simple single ligation of the appendiceal stump facilitates and shortens laparoscopic appendectomy without an increase in postoperative complications.

P036 – Colon/Bowel

UNEXPECTED FINDINGS DURING LAPAROSCOPIC APPENDECTOMY, Jeffrey L Zitsman MD, Children's Hospital of New York Presbyterian, Division of Pediatric Surgery, College of Physicians and Surgeons, Columbia University, New York, NY 10032, U.S.A.

Between January 1, 1993 and December 31, 2004 the author performed 586 appendectomies for presumed appendicitis. Patients who underwent incidental appendectomy during surgery for other indications were not included. Open appendectomy was performed in 202 cases (34.5%), while 384 patients (65.5%) underwent laparoscopic appendectomy. Five cases of laparoscopic appendectomy were converted to open procedures for technical reasons. Unexpected pathology was noted in 4 (1.9 %) open appendectomies (ovarian cyst (2), pancreatitis, Meckel's diverticulum). Twenty-seven (7.0 %) patients who had laparoscopic appendectomies were found to have additional pathology including inguinal hernia (9), femoral hernia, inguinal lymphadenopathy, ovarian and paraovarian cyst (8), ovarian teratoma, pelvic inflammatory disease, Meckel's diverticulum, paracolic hernia, Crohn's disease, omental infarction, and symptomatic adhesions related to previous surgery (2). In 3 cases a previously diagnosed umbilical hernia was repaired as part of the laparoscopic procedure. Laparoscopic appendectomy offers better intrabominal visualization than open appendectomy, and allows the surgeon an opportunity to diagnose and provide selective treatment for a greater number of unexpected findings.

P037 – Forgut

LAPAROSCOPIC CLOSURE OF A PEDIATRIC GASTROCUTANEOUS FISTULA, Juan I Camps MD, Faranak Vossoughi MD, Palmetto Health Children's Hospital, Columbia, SC

Introduction: Most of the gastrocutaneous fistulas (GCF) post gastric tube will close spontaneously without surgical intervention. The use of Methotrexate and Steroids along with fungal skin infection will cause a

failure in the spontaneous closure of the GCF.
Case Presentation: This is a 6 y/o AA girl with Juvenile Dermatomyositis with severe dysphagia and failure to thrive. She was prostrated on bed with strong inmunodepressant medications. She underwent a laparoscopic Toupet partial fundoplication and Gastric tube. She recovered from surgery without a problem but she took several months to improve her symptoms from the Dermatomyositis. Regular feeding and medications were given though the gastric tube. After five months under treatment, the gastric tube was removed in the office. For the next two months, the GCF never closed. Multiple attempts were done in order to help closing the GCF spontanously. Body features such as Cushing Syndrome from chronic steroid medications and the use of Methotrexate will prevent a good healing of the GCF.
Laparoscopic procedure: Routine approach was done for laparoscopic surgery. Patient was placed in a supine position, the nasogastric tube and a Foley catheter were placed as a standard fashion.Two 5 mm port were used, one in th umbilical site and the other in the right subcostal areas. A 5 mm scope was placed first on the umbilical port site, and then the scope was moved to the second port 5 mm on the right side of the abdomen. A 30 degree scope was needed to look on the anterior abdominal wall. The umbilical port was dilated for a 12 mm diameter to introduce a staple device. No major adhesions were seen from previous laparoscopic surgery. The stomach was released from the abdominal wall using a stapler device. Stomach insufflation by nasogastric tube confirms good seal of the stomach closure.
Discussion: Many options have been described to treat GCF. Human fibrin sealant injection and percutaneous endoscopic suturing are two examples. The most common approach is the traditional open approach with a full thickness closure in multiple layers. Our proposal for GCF closure in this special case adds the advantage of working away from the infected wound, minimal risk for complications and an excellent way to resolve the problem in a faster manner with a shorter medical care.

P038 – Forgut

A NEW CASE OF BLUE RUBBER BLEB NEVUS SYNDROME IN A 15FH YEARS OLD GIRL, DAN CATANA PhD, PASCAL De LAGAUSIE PhD,J.FRANCOIS MOUGENOT PhD, MSCURIE HOSPITAL BUCHAREST, R.DEBRE HOSPITAL PARIS

Introduction:Blue rubber bleb nevus syndrome(BRBNS) is a syndromme characterized by multiple cutaneous venous malformations in association with visceral lesions ,most commonly affecting the gastrointestinal(GI) ?(1860 Gascoyen).
Alexandra was admitted in MSCurie Hospital Bucharest at age of 7 months for huge cavernous haemangioma of left limb.She has multiple succesful surgical excisions.
Since year 2000 she had chronic severe anemia of unclear ethiology , with weekley transfusions.In 2003-2004 she was admitted and investigated in Paris, France.Finally spiral abdominal CT suspicioned multiple intestinal haemangiomas.Videoendoscopy
and endoscopic ultrasound confirmed ampular haemangioma, duodenal and colic haemangiomas.
In january 2004, M2A-given endocapsula exam releaved the possibility of multiple jejuno-ileal haemangiomas;On 20.01.2004 in Robert Debre Hospital Paris she had ampulectomy and billiary-pancreatic ducts reimplantation on stents, angioma excision
with 11 enterotomies, 2 colotomies and apendicectomy.In may-june 2004 she has normal hemoglobinemia(13,5gr.%), normal intestinal transit, normal abdominal ultrasonography .
Conclusion:When cutaneous haemangioma is associated with anemia, BRBNS have to be suspicioned.Endoscopic therapy has limited value, transmural lessions asking for surgical solutions.

P039 – Forgut

LAPAROSCOPIC ASSISTED JEJUNOSTOMY: AN EFFECTIVE PROCEDURE FOR THE TREATMENT OF NEUROLOGICALLY IMPAIRED CHILDREN WITH FEEDING PROBLEMS AND GER, Ciro Esposito MPA,Alessandro Settimi MPA, Antonella Centonze MD, Guglielmo Capano MD,Giuseppe Ascione MD, 1Deparment of Experimental and Clinical Medicine, Chair of Pediatric Surgery, ?Magna Graecia? University, Catanzaro, Italy

Background : Feeding problems and gastroesophageal reflux (GER) are major problems in severely neurologically impaired children. Many patients are managed with a simple gastrostomy, with or without fundoplication. Unfortunately, fundoplication and gastrostomy are not devoid of complications, which further stresses the need for other options in the management of these difficult patients.
Methods: Since January 2002 eleven patients (age range, 5-yrs to 14-yrs) have been treated by creating a jejunostomy using laparoscopic assisted procedure.
The procedure was performed using two 10-mm trocars. The technique consists in identifying the first jeujnal loop, grasping it 20 to 30-cm away from the Treitz ligament with a fenestrated atraumatic forceps and exteriorising it to the trocar orifice under visual guide. The jeunostomy was created outside the abdominal cavity in open surgery. At the end of the jejunostomy the correct position of the intestinal loop and feeding tube was controlled via laparoscopy.
Results: Surgery lasted 40 minutes on average, the laparoscopic part only 5 minutes. There were no perioperative complications; hospital stay was 3-4 days for all patients. At the longest follow-up (18 months), all patients had experienced a significant weight gain, with a high level of parental satisfaction. One patient died one year after the procedure, for unknown causes. All the others are doing well, without complications or problems and the parents are extremely satisfied for the improvement of the quality of life of their children.
Conclusions: Laparoscopic assisted jejunostomy is a safe and effective procedure to adopt in neurologically impaired children with feeding problems and GER.
This procedure certainly solves these patients? feeding problems even if the reflux is not completely eliminated. We advocate the use of this procedure in neurologically impaired patients with feeding problems and reflux due to its overall practicability and considering the minimal surgical trauma it entails. This technique is extremely safe because it allows the surgeon to verify at the end of procedure, the status of the jejunostomy from outside and inside the abdominal cavity. The improvement of the quality of life of these children after the jejunostomy seems to be an important advantage of this procedure.

P040 – Forgut

CHOLECYSTECTOMY: SHIFTING GOALPOSTS IN THE LAPAROSCOPIC ERA., A A Mahomed MD, S Chan MD, J Curry MD, Department of Paediatric Surgery & Gastroenterology, Royal Alexandra Children's Hospital, Brighton and Royal Aberdeen Children's Hospital, Aberdeen*.

Aim
To review a cohort of laparoscopic cholecystectomy cases prospectively accrued over an 8.5 year period, specifically evaluating indications and outcome from surgery and to determine a correlation between initial symptoms and final histology.
Method
Patients who underwent laparoscopic cholecystectomy in two paediatric surgical centres in the United Kingdom between 05/96 and 08/03 and 09/03 to 11/04 respectively, were studied. Information on patient demographics, presenting symptoms, indications for surgery, investigations, operative technique, complications and length of hospital stay were extracted from prospectively held databases (EMAS & Microsoft Access) and analysed.
Result
A total of 22 cholecystectomies were performed during the period of study. Mean age of patients was 11.3 years with an equal gender distribution. Symptomatic cholelithiasis was the main indication for surgery(13). Cholecystectomy was also performed for haemolytic disease(2), acute recurrent pancreatitis of unknown cause(2), trauma(1)and for asymptomatic stones which were calcific and non resolving(4). All patients had ultrasound scans with 4 patients additionally undergoing an MRCP. A standard 4 port approach was used with gallbladder extracted through the umbilical port. Patients with hereditary spherocytosis had a concomitant splenectomy. Mean operative time in the latter 8 cases was 85 minutes with median post operative stay for the whole series, of 1 day. Histology revealed chronic cholecystitis in all but 3 cases. Review was at 6 weeks and all patients, discharged well.
Conclusion
The laparoscopic option has resulted in an expansion of the traditional indications for cholecystectomy. MRCP is a useful investigation to exclude choledocholithiasis. There is no clear correlation between histology and presenting symptoms. The natural history of asymptomatic gallstones in children is not known although a consensus is emerging to support cholecystectomy for all calcific non-resolving gallstones, out with infancy.

P041 – Forgut

A GIANT HIATAL HERNIA MIMICKING RIGHT DIAPHRAGMATIC HERNIA: PITFALLS IN DIAGNOSIS AND MANAGEMENT, Mohamed M Elbarbary MD, Ahmed E Fares MSc,Tamer Nabil MSc,Mohamed K Elweshahy MD,Fahim A Elbassiony MD, Cairo University Specialized Pediatric Hospital

Introduction: Giant Hiatal hernias are rare complex variants of diaphragmatic defects. The stomach is usually the only organ herniating in the chest in these defects. We report a case of giant mixed hiatal hernia where small and large bowel also herniated in the right chest cavity giving the wrong impression of being a right Bochdalek hernia.
Methods and Procedures: A 6 year old female child was referred to our section after being diagnosed of having right sided diaphragmatic hernia. The diagnosis was suspected on a plain chest x-ray done for the diagnosis of repeated chest infection. A CT scan confirmed the presence of both a gastric shadow together with bowel loops in the right chest cavity and fluoroscopy showed non paradoxical movement of the right copula. Right thoracoscopic repair was attempted. At the beginning of the procedure a hernial sac was seen coming out from the posterior mediastinum. The procedure was abandoned when examination of the right diaphragmatic copula proved to be intact. Hiatal defect was suspected, and a repeat CT scan and upper gastrointestinal contrast study confirmed the presence of a giant mixed type hiatal hernia containing the stomach, small and large bowel. Successful repair of the giant hernia was completed laparoscopically after repositioning of the bowel in the abdomen and difficult dissection of the intrathoracic stomach.
Conclusion: Minimally invasive techniques proved effective in assessing and repairing such rare giant hiatal defect.

P042 – Forgut

GASTROSTOMY-ASSISTED LAPAROSCOPIC NISSEN PROCEDURE FOR NEUROLOGICALLY IMPAIRED PATIENTS, D. FALCHETTI MD, F. TORRI MD,P. ORIZIO MD,P. SALUCCI MD,G. BORONI MD,G. EKEMA, Department of Pediatric Surgery, Spedali Civili, Brescia, Italy

Laparoscopic Nissen procedure (LNP) is the most common surgical treatment of GERD in neurologically impaired (NI) patients but is associated with high complication rates. Aim of this study is to verify the long term safety and effectiveness of LNP and the impact of an associated gastrostomy (GS) as a treatment for GERD in NI patients.
Materials and Methods From September 1995 through April 2004 24 NI patients (M/F = 15/9; age: 3 mos-16yrs; weight: 2,2-40 Kg) underwent LNP. Indications were refractory dysphagia (65%), emesis (52%), bleeding (39%) and recurrent pneumonia (39%). Diagnosis was based on endoscopy (71%), histology (63%), pH studies (50%), upper g.i. X-ray (13%) and in selected cases on gastric emptying studies. Nine patients had combined LNP and GS, 6 had already a GS device (PEG). Postoperatively the GS use was encouraged both for feeding and air evacuation.
Results There were no surgical complications nor conversions and all the patients had a bowel function restoration on the first day. Mean hospital stay was 7 days; mean follow up was 55 months (range 9-112). Symptoms subsided in all cases but 4 (3 recurrent pneumonia, 1 chronic bleeding). No child was referred to have retching or vomiting. Esophagitis healed in 13/14 patients; pH-study normalized in 11/13 patients and improved in 2. We had major complications in 8 cases, 5 of them without a GS: 6 paraesophageal hernia without GER recurrence and 2 partial wrap disruption. One child died before reoperation, another was treated with a correct use of GS and required no surgical treatment. Patients with paraesophageal hernia underwent laparoscopic repair and a GS was added in 3 of them. Two children relapsed (1 of them 3 times) and further repair was performed in laparotomy. Three patients died for respiratory complications, 3 for GER-unrelated causes. As a total the group of 15 patients with GS had a complication rate of 13%, compared to 67% of the 9 patients without GS.
Conclusions In NI children LNP can be troubled by significant problems. GS can be very helpful both for feeding and decompressing, with a benefit in improving the outcome and in preventing complications. NI children require awareness of all their problems and may need adjunctive diagnostics, treatments and a closer follow-up.

P043 – Forgut

THE EFFECT OF LAPAROSCOPIC ANTIREFLUX SURGERY ON POSTOPERATIVE DUMPING SYNDROME, Christopher A Gitzelmann MD, Peter Esslinger MD,Peter Sacher MD,Martin Meuli MD, Department of Surgery, University Children's Hospital of Zurich, Switzerland and Department of Surgery, Children's Hospital Lucerne, Switzerland

Introduction: Dumping-Syndrome(DS) results from accelerated passage of nutrients from the stomach into the small bowel causing rapid uptake of glucose ultimately leading to postprandial hyperglycemia followed by insulin-induced reflectory hypoglycemia. The symptoms of DS are well known and should not be neglected if observed following open fundoplication (OF). Since the introduction of laparoscopic fundoplication (LF), the rate of postoperative DS appears to have decreased significantly. We retrospectively analyzed the OF and LF at our institutions with respect to occurrence of postoperative DS.
Materials and Methods: The charts of 27 children following fundoplication (LF=22, OF=5) were studied. Ages were 7 weeks to 18 years, indication for surgery was complicated GER in 26 cases and Achalasia in one case. Reflux was documented preoperatively by symptoms and upper GI-study. All patients showed normal stomach emptying as per GI-study. Surgery was performed by standard procedure using 5-port technique with either 3 or 5 mm instruments. All cases were performed by the same 2 surgeons. Eighteen Nissen fundoplications, 3 Toupet and one Dor fundoplications were performed laparoscopically. Four Nissen and one Toupet fundoplications were perfomed open.
Results: No postoperative DS was observed or recorded in the laparoscopic fundoplication group. DS was present and documented postoperatively in 3 of the 5 open cases.
Summary and Conclusion: Postoperative Dumping-Syndrome is a well known entity following open fundoplication for GER. The etiology has not been fully elucidated, however, intraoperative vagal nerve damage has been associated with postoperative pyloric sphincter dysfunction leading to DS. In our study none of the LF showed clinical or serological signs of postoperative DS. These findings lead us to hypothesize that magnification and better visualization of the field during laparoscopic fundoplication with consecutive reduction of damage to the vagal nerve and its' branches may account for the reduced rate of postoperative Dumping-Syndrome when compared to open fundoplication.

P044 – Forgut

OBESE ADOLESCENTS IN DEVELOPING COUNTRIES: LAPAROSCOPIC GASTRIC BANDING PART OF A MULTIDISCIPLANARY SOLUTION, Miguel Guelfand MD, Pedro-Jose Lopez MD,Mauricio Berry MD, Hospital de Niños Exequiel Gonzalez Cortes, Santiago, Chile

INTRODUCTION: One of the factors that identify developed countries is there increasing rates of obesity especially in the young. In the last decade we have seen an increasing rate of obesity in the paediatric population with all of its associated morbidity and implications for later life. We present our experience with laparoscopic gastric banding as part of a multidisciplinary for this problem in children.
METHOD: Those children currently under the care of the Obesity Unit who have either failed medical management or have developed complications (hypertension, endocrine or orthopaedic) were referred for consideration of laparoscopic gastric banding. A four port technique was used. Pneumoperitoneum was created with a Verres needle and a 10mm camera port was placed at the umbilicus. A 15mm port was placed in the left upper quadrant for the silicone band and 2 5mm ports were placed in the left and right upper quadrant. A Nathanson retractor was placed in the epigastrium with out port. An oblique retro-oesophageal was created and the silicone band was passed from right to left and positioned at the upper third of the stomach. The fundus is secured at three points with sutures.
RESULTS: During 2004, 4 patients under went the procedure. They were all female; mean age was 14 (range 13-15). The body mass index was 37 (33-41). All patients were fully fed within 24hrs and discharged between 36 and 48 hours pot-op. The mean weight decrease was 10 kilos (9-12) at 4 weeks post-op. There were no intra or post operative complications.
CONCLUSION: Childhood obesity is likely to be an increasing problem in our country. We emphasise the importance of a multidisciplinary medical approach. While surgery might be considered to be a drastic measure to take in children it certainly has an important role to play. Our

experience with this laparoscopic technique is very promising and should be considered for those children who have failed conservative management of their obesity or who are developing associated complications.

P045 – Forgut

COMBINED LAPAROSCOPIC AND ENDOSCOPIC REMOVAL OF A MASSIVE TRICHOBEZOAR, Iain A Hennessey MD, Gordon A MacKinlay MD, The Royal Hospital for Sick Children, Edinburgh

Aim
To report the successful removal of a large gastric trichobezoar using combined laparoscopic and endoscopic techniques.
Method
A 12 year old girl was admitted in October 2004 with a 2 month history of abdominal pain, weight loss and loss of appetite. Examination revealed an emaciated patient with a BMI of 13 and a large, smooth, fixed, tender mass in her epigastrium. Imaging revealed this to be a large gastric trichobezoar.
Following endoscopic confirmation, a laparoscopic approach was then selected to remove the mass. A 10mm camera port was placed below the umbilicus using an open technique and a further 5mm port was placed in the left hypochondrium. The stomach antrum was then mobilised and sutured to the umbilical port site, a gastrostomy was formed (requiring a modest extension of the port site). The trichobezoar was then removed through this aperture using Rampley forceps and gradual traction. In the final stages of the trichobezoar removal an endoscope was used to visualise the remaining hair and to guide its removal using a laparoscopic grasper reinserted through the gastrostomy. The abdomen was finally irrigated laparoscopically in an attempt to retrieve any spilled hair or gastric juice. The port sites were then closed. Total operating time was 3.5 hours. A total of 420g of hair was removed (Fig1).
Result
The postoperative course was uneventful and she was discharged with no complications. The patient is being followed up by the surgical and psychiatric services in an attempt to prevent a recurrence of the trichobezoar.
Conclusion
The above technique combines a cosmetically excellent result with the ability to ensure complete removal of a gastric trichobezoar of any size.

P046 – Forgut

BONE MINERAL CONTENT REMAINS SUPRANORMAL ONE YEAR AFTER LAPAROSCOPIC GASTRIC BYPASS IN ADOLESCENTS, Thomas H Inge MD, Stephen R Daniels MD,Victor F Garcia MD, Cincinnati Children's Hospital Medical Center

INTRODUCTION: Due to the physiologic necessity of bone mineral accretion during adolescence, concern has been raised about potential adverse effects of gastric bypass (GBP) on adolescent bone health. We hypothesized that morbidly obese adolescents would have supranormal bone mineral content (BMC) and density (BMD) which would not be significantly affected by GBP.
METHODS: 20 subjects (mean age 18.4 yrs) underwent laparoscopic GBP. Daily Ca and Vit D supplements were prescribed. Total BMC and BMD were determined using dual energy xray absorptiometry (DEXA) at 3 and 12 months postoperatively. Data were normalized to patient height and compared to age, gender, and race specific population norms by calculation of standard deviation (Z) scores. Differences between timepoints were assessed using Students T test.
RESULTS: Mean preoperative weight was reduced significantly 12 months after GBP (Table; $p<0.001$ for weight change). Preoperatively, nearly all exceeded weight limits of the DEXA scanner. Postoperative BMC (Table) and BMD (not shown) were on average > 2 standard deviations above normal and did not change significantly from 3 to 12 months (p=NS), despite massive weight reduction.

Time Weight BMC BMC(Z) Preop 155kg 3 months 124kg 2,980+/-470g 2.36 12 months 94kg 3,120+/-490g 2.37 BMC data derived from 26 individual DEXA scans
CONCLUSIONS: During a period of high susceptibility to bone mineral density loss, detailed examination shows no loss of bone mineral density or content 3 months beyond gastric bypass in this small cohort of adolescent bariatric patients. Indeed, bone mineralization in general remains more than 2 standard deviations above normal despite dramatic reduction in weight status. While serial assessment throughout adulthood will be required in these patients, these preliminary findings are reassuring.

P047 – Forgut

LAPAROSCOPIC FUNDOPLICATION: THE PARS FLACCIDA APPROACH, Yee Low MD, Chan Hon Chui MD,AS Jacobsen, KK Women's and Children's Hospital

Fundoplication for gastroesophageal reflux disease in children is now increasingly done endoscopically. Benefits cited include decreased operative stress and shorter recovery times. However, safe and effective laparoscopic fundoplication requires advanced laparoscopic skills, with a steep learning curve.
At the KK Women's and Children's Hospital in Singapore, laparoscopic fundoplication is one of the more common endoscopic surgical procedures carried out. Recently, we modified our technique by using the pars flaccida approach. By specifically identifying the pars flaccida as a surgical landmark, and first opening peritoneal windows on both sides of the cardia, the dissection to create the passage behind the cardia was greatly eased. Even in the hands of our trainee surgeons, the dissection was achieved neatly and in a much shorter time than before. This minor technical modification, when taught specifically, was easily reproducible and consistently and considerably eased dissection and shortened operative times.

P048 – Forgut

LAPAROSCOPIC ANTERIOR GASTROPEXY FOR CHRONIC GASTRIC VOLVULUS, M Campos BA, H Morgado BA, E Trindade BA,JL Carvalho MD, Pediatric Surgery Service, Pediatric Gastroenterology Unit - Pediatric Service - Pediatric Department - Hospital S. João

Gastric volvulus is a rare clinical entity characterized by abnormal rotation of the stomach around an axis made by its two fixed portions, the cardia and pylorus. It can be primary or secondary if it coexists with anomalies of adjacent organs, such as diaphragmatic hernia, eventration, asplenia/ polysplenia syndrome, or wandering spleen. Although, in same cases, chronic gastric volvulus can be managed with conservative measures, frequently surgical treatment (gastropexy or gastrostomy) is necessary.
We report the case of a 3-month-old female with an history of frequent nonbilious vomiting since the first days of live. A barium contrast-enhanced upper gastrintestinal radiographic study showed a dilatated stomach, twisted along its axis from greater to lesser curvature.
A laparoscopic anterior gastropexy was performed. With one year follow-up, the child is thriving and completely free of symptoms.
To our knowledge this is the most premature diagnosis of primary chronic gastric volvulus reported in the literature. Laparoscopic anterior gastropexy is a simple procedure, easy to perform even in small children, with optimal cosmetic and functional results.

P049 – Forgut

COMPARISON OF MINIMALLY-INVASIVE GASTROSTOMY TECHNIQUES IN CHILDREN, Jeffrey C Pence MD, Kim G Mendelson MD,Laurie A Driscoll, Brody School of Medicine at East Carolina University, Greenville, NC, USA

Minimally-invasive techniques have largely supplanted the necessity of open surgery for gastrostomy creation in children. These techniques include the classic percutaneous endoscopic gastrostomy (PEG) and the laparoscopic gastrostomy (LG). This study introduced laparoscopic assistance to classic PEG (LAPEG) in order minimize those complications attributable to the blind intraabdominal aspect of the original procedure, including acute visceral and/or solid organ injury, hemorrhage, peritonitis, and malposition. A retrospective analysis of all children undergoing these minimally-invasive techniques was performed at a single institution over a seven year period ending in 2004. Ninety-three children, aged one month to 15 years, were evaluated. These children underwent either classic PEG (n=4), laparoscopic-assisted PEG (LAPEG, n=13), or laparoscopic gastrostomy (LG, n=76). Laparoscopic procedures were performed utilizing a transumbilical 2-mm telescope for direct visualization. Open conversion was required in two patients undergoing LG. Younger children (mean age, 30 months) typically underwent LG, followed by LAPEG and PEG (mean ages, 76 months and 108 months, respectively). Mean operating times (min, with standard deviations) were recorded as follows: LG, 54±19; LAPEG, 42±14; and PEG, 46±24. LAPEG and PEG were not significantly different in operative time; however, operative times for both LAPEG and PEG were significantly reduced when compared to LG (Kruskal-Wallis test, P=0.02). One acute major complication (dislodge-

ment with peritonitis) was identified following LG. Latent complications were recorded during a follow-up interval ranging from 4-90 months. Single episodes of gastric prolapse and gastrocolocutaneous fistula were recorded following LG. A single episode of dislodgement with peritonitis following elective gastrostomy button exchange was noted following LAPEG. Minor complications, including the formation of gastrocutaneous fistula, gastrostomy dislodgement without peritonitis, and formation of metaplastic granulation tissue, occurred at a higher frequency in LG when compared to LAPEG or PEG. In summary, these data would support the utility of LAPEG in constructing minimally-invasive feeding access in children. LAPEG appears to provide superior results when compared to LG. Further, direct visualization and control using laparoscopic guidance when performing classic PEG should theoretically enhance safety and optimize outcomes of this procedure.

P050 – Forgut

ESOPHAGEAL STENT IMPROVES VENTILATION IN A CHILD WITH A BRONCHO-ESOPHAGEAL FISTULA CAUSED BY MYCOBACTERIUM TUBERCULOSIS (MTB), Daniel Sidler MD, S W Moore MD,P Goussard MSc,S Kling MSc,R P Gie PhD, Department of General Surgery/Paediatric Surgery and Department of Paediatrics and Child Health, Tygerberg Children's Hospital, Stellenbosch University, Cape Town, South Africa

Introduction: Broncho-esophageal fistula is a rare and mostly fatal complication of MTB. The previous six children with broncho-esophageal fistulae requiring ventilation at our hospital did not survive because the resultant large air leak made effective mechanical ventilation impossible.
Case: A 12-month-old boy presented with pulmonary tuberculosis and respiratory failure requiring mechanical ventilation. Severe abdominal distension developed which resulted in compromised ventilation. A bronchogram (radiocontrast administered via the endotracheal tube) confirmed a left-sided broncho-esophageal fistula. Flexible bronchoscopy demonstrated a massive connection between the left main bronchus and the esophagus, together with tracheal and bronchial compression and glandular herniation into the airways.
A Sengstaken ?Blakemore tube was inserted and the esophageal balloon inflated to seal the fistula. This reduced the air leak and it was possible to ventilate the child more effectively. A stent was placed in the esophagus via a rigid scope and deployed to compress the esophagus. The child was fed via a duodenal tube. His parenchymal lung disease improved and he could be weaned from ventilation, but failed extubation due to tracheal compression from a massive right-sided paratracheal gland. After this gland was enucleated, the child was successfully extubated. The stent was removed after three weeks with a flexible gastroscope, without complications and before extubation. Drug sensitive Mycobacterium Tuberculosis was cultured from a bronchial washing.
Discussion: In our experience, this patient is the first survivor of a MTB acquired broncho?esophageal fistula requiring ventilation. In this case the esophageal stent provided time for the parenchymal lung disease to improve, and made successful extubation possible.
Conclusion. In cases of broncho-esophageal fistulae requiring mechanical ventilation, stent placement may improve ventilation and allow time for the lung to recover. Smaller stents, which may cause less tracheal compression, are necessary for small children. It may then not be necessary to remove the stent before extubating the child.

P051 – Forgut

FLUOROSCOPICALLY GUIDED PERCUTANEOUS ENDOSCOPIC GASTROPEXY FOR ACUTE GASTRIC VOLVURUS, Makoto Suzuki MD, Minoru Kuroiwa PhD,Norio Suzuki MD,Jun Sakamoto PhD,Yoshiaki Tsuchida PhD, Department of Surgery, Gunma Children's Medical Center, Gunma, Japan

[INTRODUCTION] Acute gastric volvulus in childhood is uncommon. Delay in the diagnosis can result in gastric ischemia and perforation. It requires prompt decompression by a nasogastric tube followed by anterior gastropexy to prevent recurrence. We report a handicapped boy presented with an acute gastric volvulus and was treated successfully by the fluoroscopically guided endoscopic percutaneous gastropexy.
[CASE REPORT] A 6-year-old boy weighing 9 kg who had developmental disorder accompanied by encephalic hypoplasia was presented with a history of recurrent nonbilious vomiting and marked upper abdominal distension. Plain radiographs of the abdomen showed a hugely dilated stomach suggesting gastric volvulus. Fortunately, the stomach was decompressed by a 10-Fr. nasogastric tube. After decompression, the symptoms promptly improved. Upper gastrointestinal contrast studies showed the mesentericoaxial volvulus of the stomach. There were no associated anomalies such as a diaphragmatic hernia or eventration, malrotation or hiatal hernia.
[GASTROPEXY PROCEDURE] An anchoring device was obtained from Create Medic Co. (Tokyo, Japan). The device is furnished with two 20-gauge needles: one is to insert a thread and the other to hold a loop wire. After the stomach was fully inflated with the endoscope, fluoroscopically guided to avoid injury to other organs, the fixing sutures were placed greater curvature of the stomach by means of an anchoring device, which introduces a thread (3-0 polyglactin suture) into the stomach through one needle and conducts it outside the abdomen by catching it with a wire loop through the other needle. An extracorporeal knot was taken and buried subcutaneously by placing a tiny stab incision over the skin. Three fixing sutures were placed and the operating time was 71 min in total. The postoperative period was uneventful. There has been no recurrence of symptoms after a 3 month?f follow-up period.
[DISCUSSION] Our technique of percutaneous gastropexy was based on our positive experience with percutaneous endoscope gastrostomy in neurologically impaired children. The concomitant use of the fluoroscope allowed us to perform percutaneous placement of gastropexy sutures in the optimal anatomic position and to avoid injury to other organs. We believe that the fluoroscopically guided endoscopic percutaneous gastropexy is simple and an excellent technique for management of acute gastric volvulus in children.

P052 – Forgut

FLEXIBLE ENDOSCOPY IN ESOPHAGEAL STRICTURES, Burak Tander MD, Ender Ariturk MD,Riza Rizalar MD,Suat H Ayyildiz MD,Ferit Bernay MD, Ondokuz Mayis University, Department of Pediatric Surgery, Samsun, Turkey

Introduction: Esophagoscopy is a reliable tool, for the evaluation and treatment of the esophageal strictures. Dilatation of these strictures may be necessary according to the findings at the esophagoscopic examination. We evaluated the patients with esophageal stricture who underwent flexible esophagoscopy for the management of the esophageal stricture, which were caused by esophageal atresia or corrosive esophageal burn.
Patients and Methods: Between January 2004 and November 2004, ten patients underwent flexible esophagoscopy for esophageal stricture. We evaluated the primary diseases, radiologic examinations, management and treatment of the strictures.
Results: There were ten patients (6 male, 4 female, mean age 1.5 years). Three cases had alkali ingestions, whereas two patients experienced acid burns. In five patients, the strictures were developed after the primary repair of the esophageal atresia. All of our patients have evidence of stricture at the esophagographic examination. Eight cases had a single stricture of one vertebra length at the middle esophagus, one patient had three strictures at 12, 20 and 30th cm distance from the mouth, who underwent an esophageal stent application with the aid of the flexible esophagoscope after the dilatation therapy. Another patient had a stricture at the proximal esophagus of 1.5 vertebra length. We observed stenosis in nine patients and we inserted a guidewire into the biopsy channel of the esophagoscope, advanced it to the stomach through the stenosis. Then, we withdrawn the esophagoscope, inserted a balloon catheter or a bougie on the guidewire and push it to the stomach. After 3 hours of surgery all patients have oral intake and they did not have any perforation or other complication.
Conclusion: Flexible endoscopy is a minimally invasive procedure to evaluate and treat the esophageal strictures in children. The dilatation of the esophagus with aid of flexible esophagoscopy is safe and effective.

P053 – Forgut

SAFETY PIN INGESTION AND ITS ENDOSCOPIC REMOVAL, Burak Tander MD, Ayhan G Kalayci MD,Sule Kocak MD,Riza Rizalar MD,Ferit Bernay MD, Ondokuz Mayis University, Departments of Pediatric Surgery and Pediatric Gastroenterology, Samsun, Turkey

Aim: Safety pin ingestions are common in our country due to cultural reasons. In this study, we evaluated open safety pin ingestions and their removal from esophagus and stomach by flexible endoscopy in our department.
Cases:
Case1: Eight months old male. At chest x-ray, he had an open safety pin

in his upper esophagus. Flexible esophagoscopy revealed the safety pin with sharp point was directed cephalad, it was advanced into the stomach with a foreign body forceps, then rotated in the stomach and hold at the rear again and removed. Postoperative course was uneventful.
Case 2: Eight months old male. At chest x-ray, he had an open safety pin in the middle esophagus. Flexible endoscopy revealed that the sharp point was directed cephalad. The pin was grasped at the backside by endoscopic forceps, pushed into the stomach, rotated in the stomach and pulled with the forceps out. Postoperative course was uneventful.
Case 3: Six months old male. Chest x-ray showed an open safety pin in the lower esophagus which sharp point was cephalad. Flexible endoscopy revealed the pin was in the fundus of the stomach. It was grasped and removed by a foreign body forceps. The postoperative course was uneventful.
Case 4: One year old female. Chest x-ray showed an open safety pin which sharp point was directed caudal, it was hold by the endoscopic forceps at the tail of the pin and removed. The postoperative course was uneventful.
Conclusion:
Removal of the open safety pin from the esophagus and stomach by flexible endoscopy is a effective and reliable method. Open surgical interventions are not necessary in most cases.

P054 – Forgut

LAPAROSCOPIC GASTROSTOMY ? A SIMPLE METHOD, IDEAL FOR TEACHING, James Wood MD, Erik La Hei MD,Albert Shun MD, Children's Hospital at Westmead

Laparoscopic gastrostomy (LG) was first described in 1991 and with the increasing use of laparoscopy in paediatric surgical practice has rapidly become proven and accepted as a better tolerated and safer technique than the widely used open and percutaneous endoscopic techniques.
We modified this accepted technique of LG in an attempt to make it more accessible to surgeons without advanced laparoscopic skills such as intracorporeal suturing. The modified procedure comprised several essential basic laparoscopic skills which we observed were readily attainable by a closely mentored trainee inexperienced in laparoscopic surgery. This procedure was routinely used as a training exercise during a 4 year period from 2000-2004.
A retrospective review of the hospital database revealed that in 28 (52%) of 54 LG the operating surgeon had been a trainee. Outcome was assessed by length of hospital stay, time to full gastrostomy feeds, accuracy of placement, stoma leakage or return to theatre. There was no significant difference (p=0.76 paired t-test) in the length of hospital stay or return to feeds.
We conclude that following these modifications the LG technique remains equally effective but more accessible. It presents an important opportunity to learn the fundamental skills of minimally invasive surgery at a time when these opportunities are limited by restrictions of working hours and pressure for efficiency. We anticipate this will complement the basic skills laboratory training and plan to use it as a way of validating virtual reality training carried out in our skills centre.

P055 – Genito-Urinary

5 YEAR EXPERIENCE ON LAPAROSCOPIC ORCHIOPEXY FOR THE PALPABLE UNDESCENDED TESTIS, M Riquelme MD, A Aranda MD, E Candanosa MD,H Villalvazo MD, Hospital Christus-Muguerza, Monterrey, Mexico

BACKGROUND.-Most of the recent laparoscopic orchiopexy papers are about the non palpable testes. The objective of this presentation is to show the results of this approach in patients with undescended palpable testes.
MATERIAL AND METHODS.-Between January 1999 and September 2004, 28 patients with 30 undescended palpable testes were treated by laparoscopy orchiopexy. Inclusion criteria were: Patients with palpable cryptorchidism were included. Patients with non palpable testes, retractable and vanishing testes were excluded. Patients age ranged between 8 months and 9 years (average 21.72 months). We used 4 ports (1 of 10-mm, 2 of 2 or 3 mm and 1 of 5-mm), 4-mm lens and 2 or 3 mm instrument in all cases. In the palpable testis we usually open the peritoneum of the internal ring to dissect the vas and testicular vessels and pull the testis into the abdominal cavity cutting the gubernaculum and then pull- trough the testis to the scrotum with Prentiss maneuver, previously having a 10mm trocar inserted.
RESULTS. - The average surgical time was 50 minutes. We had only one conversion to open orchiopexy due to ectopic testis, that was found above the external oblique aponeurosis; the rest of the testes were descended by laparoscopy; 5 (16.6%) were peeping testes and 13 (43%) were in the inguinal canal. We had 2 patients that had bleeding of the epigastric vessels during the scrotum trocar placement, that require clipping of the epigastric vessel, one suffered atrophy due to accidental injury of the spermatic vessels, all the others were successfully fixed in the scrotal sac. We found homolateral side inguinal hernia in 16 (53.3%) and in all of them we did not close the processus vaginalis, we only resected the membranes. We found 1 (3.3%) with contralateral hernia in which we did close the processus vaginalis. These 28 patients have 5 months to 5 years follow up and 29 of these testes maintain good size and a correct position at the end of this study, with no recurrent inguinal hernia.
CONCLUSIONS. - The laparoscopic approach is a safe way to descend the palpable testicle. We found that peeping testis are easier to descend by laparoscopy compared to open procedure. In palpable testis we have 16.6% chances of peeping testis. It is not necessary to close the area of dissection and the processus vaginalis because it closes by itself. We had our complications on the first cases. We see the following advantages on laparoscopic.

P056 – Genito-Urinary

LAPAROSCOPIC ASSISTED EXCISION OF ABDOMINO-SCROTAL HYDROCELE, N M BOUHADIBA BA, P M GODBOLE BA,S M MARVEN BA, Sheffield children's hospital. United kingdom

INTRODUCTION: Abdomino-Scrotal Hydrocele (ASH) is a rare form of congenital hydrocele, which may have significant long term consequences from a pressure effect on pelvic and retroperitoneal structures, displacement of the vas with effect on spermatogenesis, and malignant transformation. There is no tendency to spontaneous resolution and therefore the treatment of choice is complete excision. However the open approach is very challenging and needs an extensive muscle division and inguinal canal dissection. There are no reports of a laparoscopic approach. We report the first case of laparoscopic assisted excision of ASH
METHOD: A 3 years old male presented with large hydrocele, which was proved to be an ASH on abdominal ultrasound. A transabdominal retroperitoneal dissection via two 5mm instruments ports viewed by a 5mm 30 degree laparoscope was performed. The peritoneum was first incised and the abdominal portion of the cyst mobilized with preservation of the vas and vessels. The cyst was further mobilized and excised, entirely intact via a 3cm preperitoneal inguinal incision. The dumbbell shaped cyst was entirely retroperitoneal and there was no communication of the cyst with the processus vaginalis.
CONCLUSION: Laparoscopic Assisted Excision of Abdomino-Scrotal Hydrocele offers excellent visualization, safe dissection and complete excision of ASH, precluding extensive muscle or inguinal canal dissection, with an excellent cosmetic result. We therefore advocate its use for the treatment of ASH.

P057 – Genito-Urinary

THE MINIMALLY INVASIVE OPEN PYELOPLASTY, Peter D Furness MD, Job K Chacko MD, Martin A Koyle MD, The Children's Hospital of Denver

Background: The dismembered pyeloplasty is the operation of choice to address ureteropelvic junction obstruction (UPJO). Recently with the advent of improved minimally invasive techniques and equipment, laparascopic dismembered pyeloplasty (LP) has gained popularity. LP has been offered with the idea that this technique offers superior post-operative recovery especially in the older patient due to decreased traumatic access. We present our experience with a minimally invasive open pyeloplasty.
Materials and Methods: A retrospective review of the last 5 years of consecutive open pyeloplasties at a tertiary children's hospital was evaluated with regard to age, surgical operative time, length of hospital stay, need for post-operative narcotics and surgical success.
Results: 79 patients had a dismembered pyeloplasty using an open flank incision. 36 patients (< 1year), 13 (1-5 years), 8 (5-10 years) and 22 were > 10 years old. Mean surgical time for patients < 1 year was 110.8 minutes, 1-5 years 105.5 minutes, 5-10 years 129.8 minutes, and > 10 years 131 minutes. Incision sizes for the respective groups were

2.13 cm, 1.93 cm, 2.69 cm and 3.38 cm. The last 20 patients under 1 year had incisions between 1-1.5cm. The majority of incisions were an anterior subcostal muscle splitting approach. All patients received postoperative ketorolac. Supplemental narcotics were not required in any patients less than 10 years old. All patients were discharged in < 23 hours. Radiologic improvement was seen in 76/79 patients with a success rate of 96%
Conclusion: The minimally invasive approach to open pyeloplasty is a safe and effective treatment choice to address UPJO. The procedure can be easily performed through a small incision without excessive post-operative pain issues which allows for early discharge.

P058 – Genito-Urinary

LAPAROSCOPIC REMOVAL OF A GIANT ADNEXAL CYST, Melanie C Clarke MD, Fraser D Munro MD, Royal Hospital fof Sick Children, Edinburgh

Objective: Case report describing the laparoscopic excision of a giant para-tubal cyst.
Methods and Procedures: Retrospective review of case notes and operative video.
Results: 13 year old girl with a past medical history of hereditary spherocytosis . Previous open splenectomy and cholecystostomy. Found at routine follow-up haematology clinic to have an asymptomatic abdominal mass, thought to be arising from the pelvis. USS and MRI suggested an enormous simple cyst possibly arising from the left ovary or adnexa, measuring 20cm x 16cm x 7.5cm. The decision was made to attempt laparoscopic removal. Operative findings were that of a giant cyst that appeared to be arising from the left fallopian tube. The cyst was lying centrally and was displacing the entirety of the bowel superiorly. Percutaneous aspiration and deflation was performed with almost 2 litres of crystal clear fluid drained. The cyst was then shelled out of the broad ligament and removed intact. A similar, but much smaller, cyst of about 1.5cm in diameter was present on the right which was also removed. Pathological inspection confirmed a giant tubal/fimbrial cyst. The patient was discharged home within 48 hours post-surgery. No intra- or post-operative complications were encountered.
Conclusion: Laparoscopy provides a safe and effective method for the intact removal of even enormous adnexal cysts.

P059 – Genito-Urinary

GYNECOLOGYCAL LAPAROSCOPY IN CHILDREN, Monica Contador MD, Juan P Valdivieso MD, Pamela Oyarzun MD,Marcos Cuminao MD, Hospital de niños Roberto del Río. Santiago, Chile

Purpose: Laparoscopic pelvic exploration (LPE) in pre and postpubertal girls has been reported to be safe and effective in the diagnosis and treatment of some benign gynecological disorders. We evaluate our experience using this technique.
Material and Methods: Retrospective review of LPE performed from September 1998 to November 2004. Nineteen patients were evaluated by a Pediatric Gynecologist and Pediatric Surgeon. Preoperative ultrasonography revealed cystic lesions in 15 patients. LPE was performed under general anesthesia with a three trocar technique.
Results: The group included 6 patients with dysmenorrhea; 4 with chronic pelvic pain; 3 with acute abdominal pain, 2 abdominal mass, 1 precocious puberty, 2 hypergonadotrophic hypogonadism and 1 secondary amenorrhea. Postoperative diagnosis includes an ovarian cyst in 8, paraovarian cyst in 10, 1 mature ovarian teratoma, 1 ruptured follicle, 1 with ovarian streaks and 1 endometriosis. More than one postoperative diagnosis was found in 5 patients. Cyst removal with ovarian preservation was performed in 7 cases and 10 underwent paraovarian cyst removal. Four patients required small cyst punctures. Other procedures included ooforectomy in 1, three gonadal biopsies, one endometriosis cauterization, and one appendectomy. No intra or postoperative complications were observed. No conversions were required. Oral intake was reassumed within 2 to 4 hrs postoperatively and most patients were discharged the day after surgery. One patient had persistent pelvic pain and one developed an asymptomatic small ovarian cyst that has been followed with US.
Conclusions: Minimally access surgery for benign gynecological disorders is safe and effective for both diagnosis and treatment. LPE performed in girls provides a short hospital stay with low morbidity and good cosmetic results.

P060 – Genito-Urinary

LAPAROSCOPIC PARTIAL HYSTERECTOMY, PROXIMAL SALPINGECTOMIES AND BILATERAL ORCHIDOPEXY IN AN INFANT WITH PERSISTENT MÜLLERIAN DUCT SYNDROME, Alba Cruccetti, Giovanni Cobellis,Luciano Mastroianni,Michele Ilari,Rosella Tallarico,Giuseppe Amici,Ascanio Martino, Pediatric Surgery Unit, Salesi Children's Hospital ? Ancona, Italy

Introduction: Persistent müllerian duct syndrome (PMDS) is an uncommon form of male pseudohermaphroditism characterized by the presence of a uterus and fallopian tubes in a normally differentiated 46XY male.
Case report: A ten days old male came to our hospital for obstructed right inguinal hernia, which was reduced. The patient had also unpalpable left testis and inguinal right testis. The inguinal ultrasound showed the right testis in the omolateral inguinal canal and an ipoechoic imagine at the internal inguinal right ring.
During surgery for inguinal repair both testis, a uterus and fallopian tubes were found at the opening on the hernia sac. The testis, fallopian tubes and uterus were replaced in their original position in the pelvis and the hernia repaired. The karyotype was a normal 46,XY and the diagnosis of PMDS was confirmed.
At 15 months of age the boy underwent surgery. A four trocar tecnique was used. The testicles were found attached and then separated, bilateral proximal salpingectomy was performed, leaving the fimbriae with each epididymis. The vasa deferentia were easly separated to the level of the cervix. Partial excision of the uterine fundus was performed, leaving the vasa deferentia intact on a pedicles of myometrium. The gonadal vessels were mobilized, allowing bilateral orchidopexy.
Results: The operative time was 130 minutes, there were no intra or post-operative complications and the boy was discharged the second day post-op. At 8 months follow-up the left testis is high in the scrotum, and the right testis is at external right inguinal ring.
Conclusions: To our knowledge this is the first reported case of laparoscopic partial hysterectomy, proximal salpingectomies and bilateral orchidopexy in an infant with PMDS.

P061 – Genito-Urinary

LAPAROSCOPIC GYNAECOLOGIC SURGERY IN PAEDIATRICS. A FOUR YEARS EXPERIENCE., D. FALCHETTI MD, F. TORRI MD,D. DE PREVIDE MD,S. MILIANTI MD,M. UBERTAZZI MD,C. SPECCHIA* MD,G. EKEMA MD, Department of Pediatric Surgery, *Department of Gynaecology and Obstetrics, Spedali Civili, Brescia, Italy

Laparoscopic surgery is being recognized as a valid therapy for gynaecologic problems also in paediatrics. Subject of the paper is to verify this statement through the review of our experience in the last four years. Between 2000 and 2004 20 girls aged 11months-14years (mean 11years) were admitted for suspected ovarian mass. All the patients were studied by ultrasound and in selected cases a CT scan or NMR was performed.
As the mass was confirmed, a laparoscopy was scheduled. The procedure was done in emergency when a torsion of the ovary was suspected. Surgery always started as a 1-trocar diagnostic procedure by means of an operative laparoscope. Intraoperative findings included simple cyst (7 cases), ovarian torsion (6 cases), teratoma (3 cases), theca lutein cyst, hydrosalpinge, salpinge cyst, ovarian hydatid (1 case each).
Annexiectomy was required in 3 cases and resection of salpinge in 1; in 17 cases an ovary sparing procedure could be performed.
Every operation was performed with 2 or 3 trocars. A conversion to open surgery was preferred in 4 cases for prudential or technical reasons. Postoperative period was uneventful in all patients. At a short term follow-up ultrasound examination of preserved ovaries showed no significant differences as compared to the other ones.
Laparoscopic surgery is very helpful in gynaecological problems also in pediatrics. It improves accuracy of diagnosis, is less traumatic and affords highly conservative procedures.

P062 – Genito-Urinary

LAPAROSCOPIC ADRENALECTOMY FOR SINTOMATIC AND FUNCTIONING ADRENAL MASSES, F. Fascetti Leon MD, P. Bettalli MD,E. Cesca MD,A. Toniato MD,P.G. Gamba MD, University of Padoua, Italy-*Division of Pediatric Surgery, § Operative Unit of Special Surgical Patology

Objective: Laparoscopic adrenalectomy is a technique largely adopted in adults for treatment of most surgical disease of the adrenal gland. There

are few reports about mini-invasive surgery of adrenal gland masses in paediatrics patients. The purpose of study is to analyze a small series of symptomatic and/or functioning adrenal masses in childhood treated using laparoscopy .
Methods: patient records and operative reports were retrospectively reviewed for demographics, diagnoses, operative management, and outcomes for patients undergoing laparoscopic adrenalectomy between June 2001 and June 2004 in our Centre.
Results: six paediatrics patients (3M, 3F), main age 8 years (1-15), undergoing adrenalectomy, for adrenal masses (average diameter 4 cm, range 3-7 cm), all symptomatic, 5 functioning (1 feocromocitoma, 4 cortico-adenomas, 1 soft tissue sarcomas).
The mean operative time was 120 minutes, no major complication (small bleeding in one patient easy controlled, no blood transfusion required), no conversion to an open procedure. The main hospital stay was 5 days and all patients had normal hormonal level recovery within a month. Malignant mass excision was radical.
Conclusions: our experience supports that laparoscopic adrenalectomy may be performed safely and successfully in paediatric functioning adrenal masses.

P063 – Genito-Urinary

LAPAROSCOPIC ASSISTED INGUINAL HERNIA REPAIR IN CHILDREN: OUR EXPERIENCE, Jorge A García Andrade MD, Fernando L Moncayo MD,Michele J Ugazzi MD, Hospital Docente Ambato and Clinica del Niño y Familia

From September 2002 to Nov. 04 we made 34 cases of indirect inguinal herniorrhaphy by laparoscopic assistance in children , between one month to fiftheen years old. We used 5 to 10 mm umbilical boarding for introducing the telescope. Another 5 mm boarding suprapubic for hand-needle and scissors, and 2mm abord in the internal ring level at inguinal channel to pass the monofilament suture which anchorages and it leagues the internal inguinal ring. The anchorage of the ligature is completed in the mayor oblicuos aponeurosis.
In our stadistics predominated the male sex with 21 cases(61.7%). The same prevalence occurs in patients between one month to 1 year old with 15 cases. In relation with the presentation, the right side predominated with 17 cases(49.9%). In the laparoscopic exploration we found permeable contralateral process in 12 cases (35.2%).
As associated anomalies we found 6 cases of umbilical hernias in patients under 4 years old, and the presence of 3 cases (8.8%) of ovarian cysts in girls. Theses pathologies were resolved in the same surgery. We had one complicated case (2.9%) in a 4 year old girl with a little hematoma at the posterior wall by pucturing the epigastric vein.
Of the 34 cases had 4 big inguinoescrotal hernias in males, two of them 14 years old, whom after six months postoperatory control are asintomatyc.
CONCLUSIONS
In our stadistics we found contralateral sac in 12 cases(35.2%) it has superior prevalence in relation with several reports that describe to 20%. The surgery times average for unilaterals hernias is 20 minutes and 35 minutes for the bilaterals.
More than 50% of our patients have postoperatory control more than one year.We don´t have recidivas in the 34 cases, even several patients had big hernials sacs as in the inguinalescrotal hernias cases, which demostrate that a well ligature of the indirect sac doesn´t requiere to be resecated.
We believe that it is a safety, aesthetic, and fast recuperation technic that lets a complete exploration, and resolves contralaterals herniary sacs with another associated pathologies.
we must mentioned that this technic revolutizion the terapeuthic handling of this pathology because it resolves the hernia without opening or resercking aponeurosis and herniary sacs, therefore it respects for direct vision doesn´t involve the ligadure of the herniary sac, the nobles tissiues as the spermatic cord,and the round ligament.

P064 – Genito-Urinary

LAPAROSCOPIC RESECTION OF A SEMINAL VESICLE CYST: A PEDIATRIC CASE REPORT, Michael J Leinwand MD, Anthony DeRoss MD,Hyman Rabinovitch MD,Matthew Moront MD,Christine Finck MD,Charles D Vinocur MD,Marshall Z Schwartz MD, Douglas Katz MD, Department of Surgery, St. Christopher's Hospital for Children, Philadelphia, PA

INTRODUCTION: The laparoscopic resection of seminal vesicle cysts has been previously described, but few have been reported in pediatric patients. Here we describe the management of a 17-year-old boy who presented with left-sided groin pain and was found to have a multilobular cyst of the left seminal vesicle.
METHODS AND PROCEDURES: The work-up included scrotal and abdominal ultrasonography, magnetic resonance imaging, and renal scintigraphy. The patient underwent rigid cystoscopy with placement of a right ureteral stent, and laparoscopic resection of the left seminal vesicle cyst.
RESULTS: Testicular ultrasonography was normal. Abdominal ultrasonography showed a 7 cm left-sided multilobular seminal vesicle cyst and ipsilateral renal agenesis. MRI confirmed these findings. Renal scintigraphy showed a normally functioning solitary right kidney. Laparoscopic operative time was four hours, fifteen minutes. Pathology showed a benign seminal vesicle cyst. The postoperative course was uneventful, and the patient was discharged home on postoperative day two.
CONCLUSION: Seminal vesicle cysts can be safely resected laparoscopically in pediatric patients. The laparoscopic approach offers the advantages of outstanding visualization of deep pelvic structures, minimal postoperative pain, and short hospitalization.

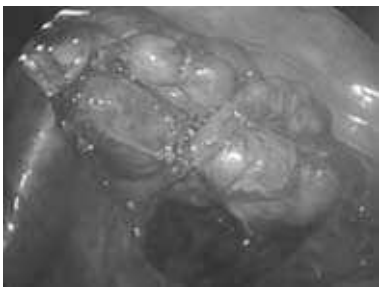

P065 – Genito-Urinary

LAPAROSCOPIC MANAGEMENT OF UNUSUAL ADNEXAL PATHOLOGY, Michael J Leinwand MD, Anthony DeRoss MD,Matthew Moront MD,Douglas Katz MD,Marshall Z Schwartz MD,Charles D Vinocur MD,Christine M Finck MD, St. Christopher's Hospital for Children

INTRODUCTION: It is important to consider adnexal masses in the adolescent female who presents with right lower quadrant pathology. The most common of these disorders are cysts of the ovary, whereas fallopian and parafallopian cysts are more rare. We report on four such cases of unusual adnexal pathology managed laparoscopically.
METHODS AND PROCEDURES: The work-up of these patients included CT scan and/or pelvic ultrasonography. All four patients underwent laparoscopic resection of the lesions.
RESULTS: All patients were fifteen years old with right-sided lesions. Patient presentation included abdominal pain, irregular menses, or an asymptomatic pelvic mass. In three patients, adnexal pathology was determined by imaging studies. Findings at operation included dilatation of the fallopian tube in one patient and parafallopian cysts in three. In all cases, the lesions were completely resected with preservation of the ovaries. Mean operative time was 2.5 hours (range: 0.8-4.3 hours). Pathology showed the fallopian lesion to be a dilated tube with proximal stenosis. The parafallopian cysts were all benign simple cysts. The postoperative course of all patients was uneventful, and the mean hospital stay was 2.8 days (range 1-5 days).
CONCLUSION: The management of the adolescent female with right lower quadrant lesions can be challenging. In the setting of unusual adnexal pathology, the laparoscopic approach can be both diagnostic and therapeutic. In addition to providing excellent visualization, it allows for definitive resection with minimal postoperative pain, short hospitalization, and excellent cosmesis.

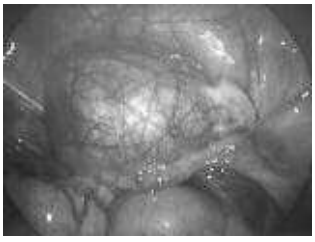

P066 – Genito-Urinary

WHEN ERGONOMICS MATTER, INLINE TROCARS FOR NON-PALPABLE TESTIS., Edgar Morales-Juvera PhD, Ricardo Villalpando C PhD,Jose A Ramirez PhD,Gabriel Reyes G. PhD, Hospital of Pediatrics, National Medical Center, XXI, IMSS

The non-palpable testis it is a frequent procedure in minimal invasive pediatric surgery, and there is no doubt about that the procedure should be done by this method.
The most frequent trocars sites are the umbilicus for the optic, and a couple of trocars in the right and left lower quadrants. The problem with this setting it is the lack of ergonomics especially in larger patients.
We propose an ?inline? placement of all trocars, keeping the optic in the umbilicus and 2 working trocars distributed between the umbilicus and the pubis, all in midline. We use a 30 degrees optic, and 2 or 3 mm instruments.
The dissection is carried out from the distal testicular vessels towards it origin, followed with a dissection of the deferent, once completed this dissection an scrotal incision is made and the ?inguinal canal? is created with a 5mm trocar or Kelly/mosquito forceps, grasping the testicle from the gubernaculum and pulling it out to the scrotum, where it is fixed with PDS or a non absorbable suture, as surgeon preference. A final inspection is done to make sure there are no peritoneal attachments left in the vessels or deferent.
We have observed some advantages with this setting, a) the surgeon keeps both hand aligned with the body, b) the camera man do not interfere with the surgeon movements, c)- surgeon and camera man have the same angle of vision, making easier to coordinate the procedure, d) if it is a bilateral the setting still the same.
And we think that al the team end with less fatigue, especially the surgeon that do not needs to be with one hand over the patient

P067 – Genito-Urinary

CRYPTORCHIDISM: DIAGNOSTIC LAPAROSCOPY OR INGUINAL EXPLORATION ?, M.W.N. Oomen MD, D.C. Aronson MD, Pediatric surgical centre of Amsterdam, (Emma Children's Hospital AMC / Vumc), Amsterdam, The Netherlands

Background: When the testicles are not in a scrotal position at the age of two, orchidopexia is indicated. In cryptorchidism the testicle can be present in the abdomen, or absent due to secondary atrophy or agenesis. Preoperative imaging seems not reliable. Since 1992 we replaced the inguinal exploration by diagnostic laparoscopy. Aim: to analyse the morbidity of this approach, and to prevent unnecessary groin explorations.
Methods: Analysis of prospective data collection. From 1992-2003, in 99 boys with a median age of 3yr-6m (range 11m-15yr, 5m). There were 149 non-palpable testicles were treated.
Results: Preoperative ultrasound was performed in 22 without therapeutic consequences. In 25 cases a bilateral cryptorchidism was present, in 20/25 a karyogram was obtained, and in 19/25 a HCG-test was performed. Laparoscopic inspection revealed 76/149 intra-abdominal testicles. In 26/149, the vas deferens and the testicular vessels ended blind (secondary atrophy), in 20/149 an agenesis of the testicle was present (no vessels or vas), and in 20/149 the funicular-structures disappeared in the internal ring.
Inguinal exploration was performed in 106 cases: in 19/103 a rudimentary testicle was removed due to already endoscopic known atrophia (n=4) and at exploration discovered atrophia (n=15). In 81/103 orchidopexia was performed. Six children required a testicle prosthesis by inguinal exploration. In 43/149 inguinal exploration after laparoscopy was not indicated. The median laparoscopy time was 17 minutes (range 5-65). The median length of hospital stay was 1 days (range 0-2).Complications: Two atrophied after orchidopexia, 1 wound abscess and 1 vas leasion.
Conclusion: Diagnostic laparoscopy for cryptorchidism is a good and safe procedure, that prevented inguinal exploration in 1/4rd of cases. Laparoscopy replaces preoperative imaging.

P068 – Genito-Urinary

ONE STEP VERSUS TWO STEP LAPAROSCOPIC FOWLER-STEPHENS ORCHIDOPEXY FOR THE HIGH ABDOMINAL TESTIS, Alfonso Papparella MD, Carmine Noviello MD,Mercedes Romano MD,Pasquale Cautiero MD,Antonio Marte MD,Pio Parmeggiani, II University of Naples Pediatric Surgery

Laparoscopy has been widely accepted for diagnosis, classification of impalpable testis. Laparoscopic one and two-stage Fowler-Stephens procedure has gained large popularity in the child for the treatment of the high intra-abdominal testis . In the 1959 Fowler and Stephens reported on the survival rate of testes in which the spermatic vessels had been ligated In 1991 Bloom and then Caldamone and Amaral proposed this two stage approach by means of laparoscopy. In 1999 Lindgren reported a 100% of success with one stage technique. We reviewed our cases treated with the Fowler-Stephens (FS) orchiopexy performed laparoscopically in 1 or 2 stages.
Materials and Methods: We reviewed the records of all boys who underwent laparoscopy for a nonpalpable testis at our institutions since 1999. Patients who underwent testicular vessel transection and orchiopexy performed laparoscopically in 1 or 2 stages were considered for evaluation. Office charts and operative reports were reviewed in detail
Results : A total of 54 patients with 63 testicular units (mean age 1.9 year) were submitted to laparoscopy, 29 had an intraabdominal testis (IAT) and 9, with high IAT, were managed by a FS procedure. In 5 testes we performed a two stage procedure, while 4 had one stage. There were no differences in hospitalization, operating time and early surgical complications were not recorded. Follow up ranged from 1 to 3 years. Of 9 patients who underwent FS orchiopexy, testicular atrophy developed in 2; the remaining are in scrotal position , with normal consistency and well perfused as revealed by color Doppler ultrasound. Significant differences were not recorded between the groups.
Conclusions : Laparoscopic orchiopexy is a logical extension of diagnostic laparoscopy for the treatment of the abdominal testis. Fowler-Stephens procedure is an effective technique in the treatment of high intra-abdominal testis. The similar success rate of the two groups suggest that the one stage FS procedure avoids repeat anaesthesia, the difficult and extensive dissection occasionally required during reoperation.

P069 – Genito-Urinary

APPLICATION OF LAPAROSCOPE ON DIAGNOSIS AND SURGICAL TREATMENT OF IMPALPABLE TESTES, Sun Ginglin, Children's Hospital Affiliated to Souzhow University

[Abstract] Objective To discuss the application of laparoscope on diagnosis and surgical treatment of impalpable testes. Methods The laparoscopic approach used in 29 boys (34 testes) for the diagnosis and treatment of cryptorchidism. Results All patients reached their final diagnosis: 21 testes were in the abdomen, 16 of them underwent primary descending and fixation, and other 5were given Fowler-stephen fixation by stages. 13testes were absent. Conclusion Accuratissime, diminished insult, and instant recovery are the main advantages of laparoscope usage for diagnosis and surgical treatment of impalpable testes, the primary descending and fixation is also effective for the suitable ones.

P070 – Genito-Urinary

LAPAROSCOPIC APPROACH TO ADNEX PATHOLOGY IN INFANTS AND CHILDREN, Lutz Stroedter MD, Paola Zaupa MD,Stefan Beyerlein MD,Juergen Schleef * MD,Michael Hoellwarth MD, Medical University Graz, Dept. Of Paediatric Surgery, Auenbrugger Platz 34, A-8036 Graz, Austria *Ospedale Infantile e Pie, Istituto per l'Infanzia, via dell'Istra 65/1, Trieste, Italy

Introduction:
Laparoscopy is a common technique used for diagnostic purposes and treatment of inner genital pathologies in children and adults. The purpose of this study was to analyse our experience and laparoscopic management of pathologic findings of the female adnexe in young girls.
Patients and Methods:
A retrospective study of the charts of female patients between 1998 and 2004 was performed. All girls with pathologic findings of the ovaries or Fallopian tubes were included. The group of patients with a laparoscopic approach was analysed and techniques discussed.
Results:
136 patients were identified with adnex pathology. 55 of these were diagnosed or/and treated laparoscopically. Mean age was 12,8 y (28 days-18.9y). 12 patients had a ovarian torsion (8 right,3 left,1 bilateral) and 5 of these ovaries (1bilateral, 3 right) had to be resected. In the remaining 8 patients retorsion was performed. Oophoropexie of the effected side was performed in 4 of these. Both sides were fixated in 1 and 7 received no fixation. Ovarian cysts were the most common finding

(29 patients: 15 right, 12, left, 2 bilat). The cysts were treated symptomatic in 7, resected in 4 and fenestrated in 16 patients. One cyst was punctured only and in one the cyst was taken out together with the autoamputated ovary. 7 biopsies were taken (4 cysts, 2 torsion, 1 tumour) and 3 tumours were identified. Conversion to open techniques was necessary in 5 patients (2 cysts, 2 tumours). Paraoophoron cysts and adnexitis was found in 9 patients each. There have been no complications seen in this group.
Conclusion:
In children with ovarian pathology laparoscopy is safe. Diagnosis can be secured and well treated in one approach in most of the cases.
Conversion to open techniques can be necessary in children with suspected tumours or technical difficulties in the management of big cysts.

P071 – Genito-Urinary

RENAL LAPAROSCOPY IN CHILDREN: OUR EXPERIENCE, Barbara Tadini MD, Lorenzo Repetto MD,Nino Guarino MD,Efisia Marras MD,Roberto Lace MD,Marco Bianchi MD, UOA Pediatric Urology O.I.R.M.-S.Anna Torino, Italy ° UOA Urology San Giovanni Battista Torino, Italy

Introduction: laparoscopic renal surgery is actually the gold standard in adult patients. Major progress in instrumentation made possible to perform laparoscopic renal surgery in children too. We present our experience in renal laparoscopy in infancy during the last 5 years.
Methods: from August 1999 to December 2004 31 renal laparoscopic procedures were performed on 30 children 12 months-16 years old (mean age 42 months). Mean body weight was 19 kg (range 9-67). Twenty-seven patients underwent unilateral retroperitoneal nephrectomy,1 child, affected by Denis Drash Syndrome, underwent transperitoneal bilateral nephrectomy and 10 days later to a left ureterectomy, always by transperitoneal approach. Two children underwent renal cyst marsupialization and the last child affected by lymphoma, underwent retroperitoneal laparoscopic renal biopsy. Indication for surgery were: renal function less than 9% in case of unilateral nephrectomy, prevention of renal neoplastic changes in patient with Denis Drash Syndrome, symptomatic large renal cysts, suspected lymphoma not diagnosed with a previous percutaneous biopsy.
Results: all procedures were completed laparoscopically, even in 5 cases in which peritoneum was entered while creating retroperitoneal space. Intraoperative blood losses were minimal, but 1 patient required a blood transfusion for a postoperative bleeding into the retroperitoneal space. All patients but 3, were discharged on the 2nd postoperative day. Mean follow-up was 24 months (range 3-64) cosmetic results were excellent in all patients and no long term complications have been encountered so far.
Conclusions: laparoscopic renal surgery in children is feasible and safe either with retroperitoneal than with transperitoneal approach with good results and minimal discomfort for the child.

P072 – Genito-Urinary

LAPAROSCOPIC-ASSISTED EXCISION OF A HUGE OVARIAN CYST, Salmai Turial MD, A Weltzien MD,G Abdul-Aziz,R Brzezinska MD,F Schier, Pediatric Surgery University medical centre Mainz, Germany

OBJECTIVE:
To demonstrate a case of laparoscopy-assisted removal of a huge ovarian cyst.
METHOD:
A 14-year-old girl noticed progressive grow of the abdomen. On ultrasonography a huge cystic lesion was identified. The origine of the cyst was unclear. Percutaneous fluid aspiration revealed no malignant cells. Intraoperatively, 12 liters of turbid fluid were drained laparoscopically from the cyst. Eventually, the empty cyst stretched throughout the complete abdominal cavity. Now it became evident that the cyst originated from the right ovary. Due to the size of the cyst wall, it was removed via a mini- laparotomy in the right groin.
RESULTS:
Initial orientation was difficult; the first trocar had inadvertedly entered the cyst. Exteriorization of the collapsed sac was easy. Also, dissection from the remaining ovarian tissue was easy. The postoperative course was uneventful.
CONCLUSION:
Even in huge intraabdominal cysts, an initial laparoscopy may be helpful in identificating the source of the lesion and in greatly reducing the access trauma.

P073 – Genito-Urinary

LAPAROSCOPIC MANAGEMENT OF OVARIAL CYSTS: PITFALLS TERATOMA, Cornelia van Tuil MD, Amulya K Saxena MD, Pediatric Surgical University Medical Center, Münster, Germany

Cysts formations in the ovaries of newborn female infants is quite rare however not uncommon. Since the advent of laparoscopic procedures in the newborns, management of such cysts has been frequently undertaken using the minimal invasive technique in this age group. At least one third of newborn ovarian lesions are nonneoplastic arising due to maternal hCG (human chorionic gonadotropin) stimulation of the neonatal ovary and do not require any treatment. However large cysts, or cysts that have already undergone torsion, should be resected. A useful guideline is that any palpable ovarian cyst in a newborn is resected. The possibility of visual exploration of ovarial cysts can give a clue to the type of cyst; however the palpation of such cysts is not possible using the minimal invasive technique. In three newborns, managed at our center, laparoscopy was employed to diagnose and manage large ovarian cysts. In one of our cases a simple solitary cyst had masked a teratoma of the ovary. Since our laparoscopic management protocol involves an umbilical incision for the optic port and two lower abdominal incisions for the work ports, the ovary in question was brought outside the abdominal cavity over the port incision, after aspiration of its contents, for manual palpation. This enabled us to explore a masked teratoma with dental and trichial contents. De-roofing of cysts and aspiration of the cystic contents alone can be a major pitfall in the laparoscopic management. We therefore strongly recommend the manual palpation of a cystic ovary outside the abdomen especially during laparoscopic procedures to avoid the pitfall of leaving behind an unattended tumor.

P074 – Genito-Urinary

MCCUNE-ALBRIGHT SINDROME: LAPAROSCOPIC DIAGNOSIS, R. Gesmundo,R. Lala,R. Guanà, S. Vinardi, F. Canavese, Regina Margherita, Torino Italy

Personal experience about laparoscopic diagnosis of peripheral precocious puberty in McCune-Albright (MAS) syndrome is reported.
As molecular genetic analysis on peripheral blood is rarely indicative, we strongly recommend it on ovarian cyst samples in isolated peripheral precocious puberty (PPP) as well as in PPP associated with other MAS signs as: cafè au lait spots,
bone fibrous dysplasia, peripheral endocrinopathies other than PPP.
These samples should be taken with the least invasive technique available.
We propose in children under the age of three trans umbilical laparoscopic ovarian cystectomy (TULOC) as an alternative to the usual technique, which should be performed in older children.
We underline that, in these children, long experimental drug treatments could be avoided when removing a single pathological cyst.
Five cases between the ages of 4 months and 6 years (mean 2.5 yrs) are presented.
We asses the diagnostic and therapeutic efficacy of laparoscopy.

P075 – Genito-Urinary

NO RETRO-LOOK: RETROPERITONEOSCOPY, Robert Weil MD, C A Gitzelmann MD,D Weber MD,R Gobet MD, Division of Pediatric Urology, University Children's Hospital Zurich, Switzerland

Background: Minimal invasive techniques in pediatric urology are becoming more widely established. We report the initial experience with retroperitoneoscopy at our center.
Patients and Method: From May 2002 to September 2004 retroperitoneoscopy was performed in 14 patients, aged 4 months to 13 years (mean age: 4 years), including 7 nephrectomies (one bilateral), 7 partial nephrectomies (5 upper, 2 lower pole) and 1 resection of an abdominal hydrocele. 5 children were younger than 2 years.
Results: Retroperitoneoscopy was completed successfully in 13 patients, conversion was required in 1 case due to unclear anatomy. Mean operative time was 200 minutes. Mean hospital stay for 13 patients was 4.75 days (range 4 to 6 days), 1 patient underwent an additional ureteroneocystostomy and was discharged after 10 days. Follow up did not show any long-term complications, to date.
Conclusion: Retroperitoneoscopy is in our hands an effective and a safe approach to the treatment of children with benign nonfunctioning kidneys or moieties. With the growing experience of the surgical team the indications for retroperitoneoscopy are expanding

P076 – Genito-Urinary

THE NONPALPABLE TESTIS - WHEN TO DO WHAT ?, Dani Yardeni MD, Asher Pressman MD,Basem Kawar MD,Maged Zebidat MD,Idit Lavi MS,Leonardo Siplovich MD, Haemek Medical Center, Afula , Israel

Introduction: The preferable treatment for nonpalpable testis is, as yet, undetermined. During the past five years we routinely start by performing a diagnostic laparoscopy, followed by complete, or assisted, laparoscopic orchiopexy in one or two stages, according to the shape and position of the testis. In this study we evaluate the outcome of this policy.
Methods: We retrospectively reviewed the medical records of all the young males who underwent laparoscopy for nonpalpable testis at our hospital from January 2000 to December 2004. Statistical analysis utilized Student's t-test and regression analysis.
Results: 65 males, ages 9 months to 10 years, underwent laparoscopy for nonpalpable testis, 17 of them were younger than 18 months at the time of the first operation. The left testis was not palpable in 31 males; the right in 17 and both testes were not palpable in 14. Thirty-two atrophic or vanished testes were found in 31 males. 21 males underwent 1-stage laparoscopic orchiopexy without division of the spermatic vessels and 16 of these were laparoscopic assisted. 17 males underwent laparoscopic 2-stage Fowler-Stephens orchiopexy, in 4 of them, this method used bilateral. At one to 58 months follow-up, 5 testes in 4 males had vanished post orchiopexy. All after 2-stage Fowler-Stephens laparoscopic orchiopexy and 3 of the 4 boys were older than 24 months at the time of the first operation. 39 testes are well developing, of these, 37 are in a good scrotal position and 2 are located high in the scrotum. There were five, not major, complications.
Conclusions: The high success rate combined with minimal complications makes the laparoscopic orchiopexy the procedure of choice for treating nonpalpable testes. Although not statistically significant, our outcome supports the 1-stage laparoscopic orchiopexy as compared to the 2-stage Fowler-Stephens. Operating on a small baby, at younger age, may enables us to bring the testes to the scrotum in one stage without division of the spermatic vessels due to the short inguinal canal and consequently, apparently improving the outcome.
Key Words: testis; undescended; nonpalpable; laparoscopy; orchiopexy

P077 – Genito-Urinary

LAPAROSCOPIC INVERSION AND LIGATION INGUINAL HERNIA REPAIR, Garret Zallen MD, Philip L Glick MD, Doernbecher Children's Hospital, Portland OR and Children's Hospital of Buffalo, Buffalo, NY

Inguinal hernia repair is the most common procedure performed by pediatric surgeons. Several laparoscopic repairs have been described, but all of them have a slightly higher recurrence rate. We describe a technique in girls where the sac is grasped, inverted, twisted and then subsequently ligated with an endoloop. This technique is simple and can be performed quickly. Using 3mm instruments without trocars, minimizes incision length and postoperative pain is almost non-existent. With the addition of the leash technique, dissection of an adherent ovary can be done easily without damage to the sac.

This procedure has been done in over 30 patients and have had no recurrences. We believe that this should become the laparoscopic repair of choice in females with inguinal hernias.

P078 – Instrumentation

LAPAROSCOPIC APPENDECTOMY: DO CHILDREN BENEFIT FROM THE TWO PORT-TECHNIQUE?, Thomas Benkoe MD, Marion Nowak,Ernst Horcher MD,Winfried Rebhandl MD, Department of Pediatric Surgery, University of Vienna

Introduction:
In pediatric surgery laparoscopic appendectomy is a well established operative surgical procedure. Beside the classic laparoscopic three port appendectomy, the two port laparoscopic assisted (extraabdominal) appendectomy through the umbilicus is performed at our the department since 1997.
Patients and Methods:
From 1997 until 2004, 87 patients (median = 10.8 years; range 2.3-18.4 years; sex: m = 49, f = 38) were non-consecutively operated with two-port-technique. In this retrospective study we analyzed 50 acute appendectomies and 37 elective procedures. We compared all laparoscopic assisted two port appendectomies, which were carried out as clinical acute (n = 50) or as elective procedures.Trocars were inserted in the umbilicus (12 mm blunt trocar) and the left lower quadrant (5mm trocar). The appendix was then pulled out through the umbilical incision and extraabdominal appendectomy was performed by means of stapler device or ligation.
Results:
The mean operating time, irrespective of pathological diagnosis, was 25 minutes (range: acute = 10-60 vs chronic disease. = 10-85 min). Histopathology revealed acute inflammatory disease (catarrhal, phlegmonous, perforated) in 52% , a chronic inflammation (fibrosis, neurogen) in 27% and lymphatic hyperplasia of the appendix in 21%.
The mean postoperative hospital stay was 4 days (range: 1-7 days) which was independent from clinical diagnosis. Patients without pathological findings were discharged one day earlier (median =3 days). Postoperative complications appeared in 3 patients (2 subcutaneous abscess, 1 haematoma).
Conclusion:
The decision to perform the two port technique is made after insertion of the second trocar. Then it is possible to see wether the coecum and appendix can be removed by this technique. The laparoscopic assisted two port appendectomy is a safe alternative to the three port procedure. This technique combines an amelioration of all already known advantages of the laparoscopic issue (cost efficiency, improved cosmetic, operation
time and less postoperative pain) with an safe and easy to perform extraabdominal appendectomy. There was no increase in umbilical infection rate .

P079 – Instrumentation

ULTRACISION IN LAPAROSCOPIC APPENDECTOMY, D Cholewa MD, A Bartenstein MD,C Boillat PhD,U Waldschmidt MD,Z Zachariou MD, Pediatric Surgery University Hospital CH-3010 Bern

Objective: Only a few data on ultrasonically activated scalpel (UAS) for appendectomy exist. The aim of the study was to examine mechanical, microbiological and morphological changes on the removed appendix in order to evaluate if UAS application is justified for appendix dissection.
Method: We investigated the resection margins in twenty laparoscopically removed appendices using a 5 mm UAS-scissor for the mesenterial dissection (UAS settings: level 3, axial freq. 55 000 Hz, longit. amplitude 60 µm). The overall time for this dissection was measured and Roeder slings were used before cutting the appendix with conventional scissors. Immediately after removal, a swap from the resection site was performed and a 1cm slice was resected from the basis of the appendix with the UAS. A second swap was taken from this surface. The resected appendix was immerged in solution and air was insufflated into the appendix lumen from the apex. Seal burst pressures were recorded when air bubbles were visible at the UAS resected end. Manifestations of coagulative denaturation were measured in HE stains.
Results: The average time for mesenteriolum dissection was 250 (54-1200) sec. No conversion to open surgery was necessary. Coagulation with the UAS was effective in all procedures and no bleeding occurred. Histological changes that extended to full thickness damage were observed over a distance of 2(1-3) mm from the UAS resection rim with no morphological changes beyond 3 mm. Mean seal burst pressure of the appendiceal lumen was 35(20-160) kPa. The bacterial culture

growths were less in UAS resected probes (2/20 positive) compared with the conventional scissors cut appendices stumps (16/20 positive). There were no differences in seal burst pressures and denaturation zones between advanced stages and initial forms of appendicitis.
Conclusion: UAS is a fast and probably safe tool in laparoscopic appendectomy. The resection level shows less bacterial contamination and seems to seal the resection level tightly. It averts complex time-consuming manoeuvres and electric current transmission that may cause side effects.
This study is supported by Ethicon Endo-Surgery Switzerland

P080 – Instrumentation

BILATERAL RENAL VEIN THROMBOSIS AND RETROPERITONEAL LAPAROSCOPIC NEPHRECTOMY IN A CHILD WITH FACTOR V (FV LEIDEN) MUTATION; CASE REPORT NO1, WAEL M EL-SAIFY MSc, M KULKARNI, Department of Paediatric Surgery, Norfolk and Norwich University Hospital, UK

INTRODUCTION
Renal vein thrombosis (RVT) is a well-recognised but now rare clinical entity in children. We reported successful retroperitoneal laparoscopic nephrectomy in a child for a non functioning left kidney secondary to inferior vena cava (IVC) and bilateral in-utero renal vein thrombosis due to heterozygosity for factor V Leiden mutation leading to resistance to activated protein C, and discuss the safety and feasibility of the procedure.
CASE REPORT
A 2980 gm full-term male infant presented with the ?diagnostic triad? of palpable abdominal mass, gross haematuria, and thrombocytopenia. Diagnosis of RVT was confirmed by Doppler ultrasound scan. Follow up radionuclide DMSA scan at 16 months showed left renal function less than 6%. Retroperitoneal laparoscopic nephrectomy was successfully completed. Initial access was achieved through 10 mm trocar incision at the lower border of the tip of the 12th rib. A working space is developed by blunt finger dissection, pneumoretroperitoneum is created and 2 additional 5mm trocars are placed; on the lateral edge of the erector spinae muscle and mid axillary line 2-3 cm above the iliac crest. Using blunt dissection the kidney is then freed at all aspects. The renal vessels are approached posteriorly and ligated with clips and divided. The ureter is dissected as far as possible, ligated and sectioned. The specimen was removed intact through 10 mm port site. Estimated blood loss was minimal. There were no technique related injuries. The child enjoyed a rapid return to full activity within 2 days of surgery.
CONCLUSION
Retroperitoneal laparoscopic nephrectomy can be performed safely in the presence of abnormal venous collateral secondary to IVC and RVT in infants with factor V mutation.

P081 – Instrumentation

PAEDIATRIC INGUINAL HERNIOTOMY AND EVALUATION OF THE CONTRALATERAL INTERNAL RING IN THE LAPAROSCOPIC ERA, WAEL M EL-SAIFY MSc, Department of General Surgery, University Hospital of Hartlepool, UK

Introduction:
The role of laparoscopy in paediatric herniotomy and evaluation of the contra lateral ring in children with unilateral inguinal hernia remains a controversial topic. This review summarises the current status of laparoscopy in the management of paediatric inguinal hernia.
Methods:
A literature review was carried out accessing all English language journal articles since 1990. Medline database was searched for 'Inguinal hernia' and 'Laparoscopy and children'. Other articles cited in bibliographies were also obtained.
Results:
A number of techniques have been used to evaluate the contra lateral internal ring such as exploration via the ipsilateral hernia sac during open herniotomy, in-line exploration via the anterior abdominal wall, or exploration via the umbilical approach during laparoscopic herniotomy. The later approach offers a more direct view of the contra lateral ring and patent processus vaginalis, if present, than through the ipsilateral hernia sac approach.
Laparoscopic hernia repair provides a safe alternative approach to open inguinal herniotomy in children with minimal morbidity and superior cosmoses.
Conclusions:
Laparoscopic herniotomy is safe and feasible in children with all the potential benefits of minimal invasive surgery. Laparoscopic examination provides accurate information, helps to identify silent contra lateral hernia and prevent unnecessary contra lateral inguinal exploration.

P082 – Instrumentation

A SIMPLE AND SECURE METHOD TO FIX LAPAROSCOPIC TROCHARS IN CHILDREN, Peter KF Yip,* Paul KH Tam,MKW Li, Department of Surgery, Pamela Youde Nethersole Eastern Hospital, * Division of Paediatric Surgery, Department of Surgery, Queen Mary Hospital, HONG KONG

Introduction:
Fixing a trochar onto the abdominal wall in children during a laparoscopic procedure is important to keep the procedure fluent. The common methods of fixing trochars including simple suture tying or suture tying over rubber tubing are either insecure or clumsy. We introduce another easy method to fix the trochars.
Method:
Before anchoring the trochar a piece of polyurethrane adhesive Tegadrem (3M Health care, ST. Paul USA) was wrapped over the trochar. A silk stitch is anchored to neighbouring skin, and then it is transfixed over the shaft of trochar.
Result:
Both the in and out movement of trochar can be restrained.
Cleansing of instruments after the procedure is also easy, and the dressing does not leave any glue on the instrument surface afterwards.
This method is simple, fast, secure, and can be applied to trochars of any size.

P083 – Neonatal

EARLY LAPAROSCOPIC KASAI's IN A LOW WEIGHT NEWBORN. CASE REPORT, H Allal MD, M Lopez MD,N Kalfa MD,D Forgues MD,MP Guibal MD,RB Galifer PhD, Visceral Pediatric Surgery Department, Lapeyronie Hospital, Montpellier, France

Aim: One of the prognostic factors of Kasai success is the precocity of surgery. The authors present an early and curative laparoscopic treatment in a newborn with biliary atresia and describe the technical details of procedure.
Methods: A 2.3 Kg neonate was admitted with a history of jaundice, and fecal acholia since birth, with elevated total bilirubin and abnormal hepatic test .
Abdominal ultrasound showed a small gallbladder with hyperechogenicity in porta hepatis and absence of biliary principal duct. Others metabolic and hematological test were normal. The procedure was performed at 20 day-old of life by laparoscopy. The cholangiography confirms the biliary atresia, and Kasai's procedure was continued by laparoscopy and transumbilical extracorporeal Roux-Y approach.
Result: The duration of the procedure was 220 min, with good tolerance of pneumoperitoneum. There was no complication. Feeding was started on the 3rd postoperative day, with normal stools color and decrease of jaundice. The follow up at 8 months was normal.
Conclusion:
The laparoscopic Kasai can be performed early in a low weight newborn without complications, with an acceptable surgical time and anesthetic tolerance. This procedure allowed to keep an adhesions-free abdomen for an eventual hepatic transplantation. The real role of this promising technique must nevertheless be confirmed by larger series.

P084 – Neonatal

LAPAROSCOPIC REPAIR OF NEWBORN CONGENITAL DIAPHRAGMATIC HERNIA, Thane A Blinman MD, STEVEN R ROTHENBERG MD, HOSPITAL FOR INFANTS AND CHILDREN, PRESBYTERIAN/ST.LUKE'S MEDICAL CENTER

OBJECTIVE: While medical management of newborns with congenital diaphragmatic hernia (CDH) continues to improve, techniques for surgical repair have not advanced. Many groups have published case reports of repair of (Bochdalek) CDH as well as traumatic hernias in adults and children, but no one offers laparoscopic repair of CDH in the newborn. Here, we develop a technique for laparoscopic repair of left-sided diaphragmatic hernia in the newborn.
METHODS: All babies born with left-sided CDH between 1999 and 2004 were considered for laparoscopic repair. In the NICU, babies were treat-

ed medically until clinical endpoints were reached (pCO2 < 55, FiO2 < 50%, PEEP < 8, minimum pressors). In the operating room, diaphragmatic defects were closed primarily with non-absorbable interrupted suture using a 4- or 5-trocar (3 and 5mm) technique and 10?15cmH20 pneumoperitoneum.
RESULTS: Six babies underwent laparoscopic repair. All but one of the repairs were completed without conversion to an open technique. Operating time averaged 90 minutes (70—110min). There were no intraoperative complications, and no postoperative exacerbation of pulmonary hypertension or hypercarbia. Average time to full feeds was 6.8 days. All babies were discharged to home. There was one recurrence.
CONCLUSIONS: CDH can be repaired in the newborn laparoscopically. The main advantages include better visualization and precision, decreased pain and deformity, and better cosmesis. While some babies with severe pulmonary hypertension may not tolerate CO2 pneumoperitoneum, select patients benefit from this new technique.

P085 – Neonatal

THE EVOLUTION OF DIAGNOSIS AND TREATMENT OF 50 NEONATAL OVARIAN CYSTS IN A 22 YEAR PERIOD, B CIGLIANO,A CHIAPPINELLI, C ESPOSITO, A SETTIMI,A SAVANELLI,G VALLONE, PEDIATRIC SURGERY-UNIVERSITY "FEDERICO II", NAPOLI. PEDIATRIC SURGERY-UNIVERSITY "MAGNA GRAECIA",CATANZARO. RADIOLOGY-UNIVERSITY "FEDERICO II", NAPOLI

INTRODUCTION
Ovarian cysts are the most common intraperitoneal masses found in female newborns.
Prenatal and postnatal ultrasonography (US) are accurate for diagnosis and follow-up.
The management of these lesions depend on their dimension, evolution and US appearance.
MATERIAL AND METHODS
Between ?82 and 2004 we observed 50 ovarian cysts in 41 newborns: 24 were right sided, 8 were left sided and 9 were bilateral.
All cases had prenatal and postnatal US. All were asymptomatic despite size (except for a palpable mass in largest cysts) or torsion (present in 41,4 % of patients).
We did not observe rupture or other complications.
A conservative approach consisting in US follow-up was used in 13 patients.
28 newborns were treated: in 2 cases a US-guided needle aspiration was performed.
10 patients were treated in open surgery (4 cystectomy, 1 ovariectomy and 5 annexiectomy) and 16 patients laparoscopically (1 needle aspiration, 8 cystectomy, 5 ovariectomy and 2 annexiectomy).
9 cases were bilateral: all of them needed a unilateral treatment, 2 also a simple needle aspiration of the controlateral cyst.
No patient developed post-operative complications.
CONCLUSIONS
Ovarian cysts are unusual in pediatric age; they rarely appear with symptoms of cyst rupture or intestinal occlusion or perforation.
The incidence has markedly increased with the widespread use of ultrasounds during pregnancy.
The differential diagnosis includes mesenteric and urachal cysts, the rare enteric duplications, hydrometrocolpos and lymphangiomas.
Usually cysts 4-5 cm in diameter or larger, not decreasing in size or complicated are treated.
Our experience has shown that the majority of ovarian cysts developed complications during the last weeks of pregnancy or in the first 15 days of life. Probably more aggressive prenatal in utero treatment should be necessary. We strongly recommend close US postnatal monitoring: increasing dimensions or ultrasonographic signs of torsion represent indication for treatment. Laparoscopy is a reliable, safe and easy technique that we have been performing since 1984.

P086 – Neonatal

MANAGEMENT OF OVARIAN CYSTS DURING INFANCY; AUTOAMPUTATION PRESENTING AS A POSSIBLE PITFALL, B Haluk Guvenc MD, Burak Erkus MD,Arzu Ozyer MD, Kocaeli University, School of Medicine, Dept. of Pediatric Surgery, Kocaeli, Turkey

Introduction: The widespread use of routine antenatal ultrasound scanning has increased the frequency of intrauterine diagnosis of ovarian cysts. In utero adnexal torsion may present with subsequent autoamputation in some of these lesions. Pre and postnatal ultrasonographic findings, however, may not always be relevant in making the correct diagnosis.
Methods / Procedure: A seven-month-old girl was referred to our clinic with a 35x28x29 mm left adnexal cystic mass which failed to resolve after a period of conservative management. The mass was reported to be 32x33x40 mm in size during repeated antenatal ultrasound scanning. Laparoscopic approach revealed a freely floating autoamputated left ovarian cyst. The cyst was successfully removed through the umbilical port following drainage of its hemorrhagic content. Preoperative ultrasound and abdominal CT failed to detect the presence of autoamputation.
Conclusion: We advocate laparoscopic approach as a safe and efficacious tool in the diagnosis and treatment of ovarian cysts detected by antenatal ultrasound scanning. We believe that, the possibility of an otherwise silent autoamputated ovarian cyst may necessitate laparoscopic intervention for exact diagnosis, even in neonates presenting with small simple ovarian cysts under 4 cm in diameter

P087 – Neonatal

FULL SPECTRUM OF MINIMALLY INVASIVE SURGERY IN INFANTS IN THE FIRST 3 MONTHS OF LIFE, Yuri A Kozlov MD, Vladimir V Novogilov MD,Pavel S Yurkov MD,Sergei N Larionov MD,Svetlana V Ionushene MD, Department of Newborn Surgery, Pediatric Hospital, Irkutsk, Russia

Introduction. The revolution in open pediatric surgery in the past 10 years has been performed with help of modern less invasive endoscopic technology. The difficulty of performing these procedures in newborn was adopted with use new endosurgical instruments, cameras and advanced techniques. Better results, cosmesis and less postoperative stress following MIS is a advantage over open surgery. We report our experience in use of MIS strategies for treatment of broad spectrum congenital pathologies of thorax, abdomen and other condition by infant in the first 3 months of life.
Materials and Methods. We reviewed the medical record of all 80 patients who underwent endoscopic procedures at our hospital from January 2002 through November 2004. The smallest child weighed 800 g. There were three different groups: LAP - laparoscopic operation (41), VATS - thoracoscopic operation (28), NES - neuroendoscopic operation (11). In these groups dominated following technology: LAP - pyloromyotomy (14), ovarian cystectomy (5) , Nissen and Thal fundoplication (5) , repair of duodenal atresia and malrotation (4), inguinal hernia repair (4), diagnostic examination (4); VATS - ligation of patent ductus arteriosus (14), repair of esophageal atresia (3), decortication (2); NES - third ventriÓulostomy (6), fenestration of the cyst (5). We adopted also new technology aortopericardiosternopexy, suturing of diaphragmatic defect, pulmonary artery banding, laparoscopic-assisted Soave. All endoscopic procedures were performed under general anesthesia with ECG, SpO2, BP and end-tidal carbon dioxide monitoring.
Results. We have no intra- and post-operative death, bleeding or infection. The conversion was: VATS - 1 patient with TOF and vascular abnormality (unexpected right sided aorta and double aortic arch). All patients discharged from hospital between day 3 - 64.
Conclusion. Our study demonstrated that endoscopic procedures can be performed safely and successfully for most congenital and acquired conditions in infants in the first 3 months of life. We recommend MIS as first line therapy for pyloric stenosis, PDA, GERD, duodenal and esophageal atresia, selected form of hydrocephalus.

P088 – Neonatal

RETROSPECTIVE COMPARISON OF OUTCOMES OF LAPAROSCOPIC VERSUS OPEN PYLOROMYOTOMY AT A HIGH VOLUME PEDIATRIC SURGERY CENTER, Obinna O Adibe MD, Peter F Nichol, Alan W Flake MD, Peter A Mattei MD, Children's Hospital of Philadelphia

Objective of the study: Laparoscopic pyloromyotomy (LP) is utilized widely for treatment of hypertrophic pyloric stenosis. There are no randomized trials and few large retrospective studies comparing it to open pyloromyotomy (OP). We examined the results of pyloromyotomy at a high-volume pediatric teaching hospital during the time when the laparoscopic technique was first introduced to compare outcomes of laparoscopic and open pyloromyotomy.
Methods and procedures: We performed a 5-year retrospective review of outcomes of laparoscopic and open pyloromyotomy at our institution. Institutional records of all patients were reviewed. The two techniques were compared for number of complications (mucosal injury, incomplete myotomy, incisional hernia), operative time, time to full feeds, length of

stay, and frequency of emesis after operation.
Results: The number of pyloromyotomies performed was 335 (212 laparoscopic, 123 open). There was no significant difference in operative time (LP=30.5 min vs. OP=32 min; p=0.3), time to full feeds (LP=22.4 h vs. OP=23.5 h; p=0.2), frequency of postoperative emesis (LP=1.8 vs. OP=2.2; p=0.8), or length of stay (LP=49.3h vs. OP=50.5h; p=0.6). There were 5 mucosal perforations in the laparoscopic group (2.3%) and 2 in the open group (1.6%) (p=). Four of these in the laparoscopic group occurred during the first 2 years of the 5 year review period. There were 3 incomplete pyloromyotomies in the laparascopic group (0 in the OP) all within the first 2 years of the study. Five additional patients in the laparoscopic group required conversion to an open procedure because of poor visualization. There was one incisional hernia in the open group (LP=0). The total rate of complications were 3.7% (LP) vs. 2.4% (OP).
Conclusions: Laparoscopic pyloromyotomy can be performed safely with similar outcomes to open pyloromyotomy. There appears to be an institutional learning curve when the laparoscopic technique is introduced as reflected by the rates of mucosal injury and incomplete pyloromyotomy. Nevertheless there is no significant difference in the rate of complications in either group when performed at a high-volume pediatric surgery center.

P089 – Neonatal

LAPROSCOPIC RESECTION OF LARGE CONGENITAL HEPATIC CYST IN NEWBORN, Amulya K Saxena MD, Cornelia van Tuil MD, Pediatric Surgical University Medical Center, Münster, Germany

Newborn laparoscopic procedures still present many challenges due to the small size of the patient, reduced area to perform procedures as well as technical difficulties still faced due to instrumentation. A newborn female infant was referred to our center after birth with a large cystic mass in the upper abdominal cavity. Diagnostic laparoscopy was performed using 2.7mm 0º optic and the findings revealed a congenital liver cyst of 5 cm in diameter on the left lobe of the liver. Furthermore the cyst was attached to the liver with a stalk of 1 sq. cm on the surface. Two 2.7 mm work ports were inserted in the left and the right side of the abdominal cavity, with a grasper to push on the cyst and a monopolar hooked cautery to dissect the stalk. Meticulous dissection was performed and the entire cyst was separated from its hepatic attachment. The entire cyst was then displaced into the lower abdomen. A needle was inserted through the abdomen and under optic visual control inserted into the cyst. The entire cystic contents were aspirated and the needle was removed. The cyst wall devoid of the fluids was removed through the work port. There was no blood loss during the procedure and the child was discharged after 3 days without any complications. This is the first report of a laparoscopic congenital hepatic cyst resection in a newborn. The complete removal of such cysts using the minimal invasive technique to avoid malignancy, as described in the literature, is of significant importance.

P090 – Neurosurgery

MICRO-LAPAROSCOPIC-ASSISTED LUMBOPERITONEAL SHUNT IN THE LATERAL POSITION FOR PSEUDOTUMOR CEREBRI IN A MORBIDLY OBESE CHILD, Harsh Grewal MD, Karin S Bierbrauer MD, Pediatric Surgery and Pediatric Neurosurgery, Temple University Children's Medical Center and Temple University School of Medicine, Philadelphia, PA, USA

Introduction: Pseudotumor cerebri or idiopathic intracranial hypertension is a known complication of morbid obesity which often requires neurosurgical intervention for worsening symptoms. Placement of a lumboperitoneal shunt (LPS) is one of the treatment options, but in a morbidly obese patient can be technically challenging. We describe the use of 3-mm instrumentation for micro-laparoscopic assistance in placing the peritoneal end of the shunt.
Case Report: A 16-year-old morbidly obese young girl with increasing headaches, and worsening visual symptoms not responding to medical management, but responding to lumbar punctures with drainage of cerebrospinal fluid was diagnosed with pseudotumor cerebri. She underwent fenestration of the optic nerve with minimal improvement. Following an extensive work-up and because of decreasing visual acuity and contraction of her visual fields she underwent LPS. Due to her body habitus secondary to her morbid obesity a laparoscopic assisted approach was utilized for placement of the peritoneal end of the LPS. The procedure was performed in the lateral decubitus position with the right side up, and fluoroscopy was utilized to access the lumbar subarachnoid space. A radially expanding 3-mm trocar was then placed midway between the anterior axillary line and umbilicus; using carbon dioxide pneumoperitoneum a 3-mm thirty degree telescope was placed to visualize the right colonic peritoneal attachments. The shunt tubing was tunneled subcutaneously from the spine to the anterior axillary line and was inserted just anterior to the right colon peritoneal attachments using a percutaneously placed peel-away sheath and dilator under direct laparoscopic visualization. The incisions were sealed with cyanoacrolate glue. There were no operative or post-operative problems and she was discharged home with resolution of symptoms and her visual acuity and fields normalized at three-month follow-up.
Conclusion: Micro-laparoscopic-assisted lumboperitoneal shunt placement in the lateral position is an efficient and safe method for the treatment of pseudotumor cerebri. Micro-laparoscopy is a simple and effective minimally invasive tool for placing the peritoneal catheter, especially in the morbidly obese patient.

P091 – Other

MEDIASTINUM PROLAPSE OF GASTRIC WRAP IN NISSEN FUNDOPLICATION IN CHILDREN. LAPAROSCOPIC CORRECTION, R Beltrà MD, R. Santana MD,C Hernández MD,L. Sanchis MD, Unidad de Cirugía Digestiva y Laparoscópica. Servicio de Cirugía Pediátrica

The Nissen fundoplication is the most frequently done procedure in the prevention of gastro-oesophageal reflux disease symptoms (GERD) in children. The use of laparoscopy for this technique means an important advantage with significant benefits and the trend nowadays is to perform it mostly through this via.
However, in occasions is necessary to carry out the fundoplication by laparotomy. When a failure occurs and re-operation is mandatory, the procedure has added difficulties mainly because of adherences to the liver, diaphragm and hiatus crus.
Laparoscopic approach minimizes those inconveniences permitting us very fine dissections with more magnified and clear vision.
We report a 23 months old child who complained of vomiting, food retention, dysphagia, apnoeic episodes, burble sounds when eating and failure to thrive since several months ago. He had been operated at the age of 4 months due to severe respiratory symptoms caused by aspiration of refluxed material in the context of GERD. A Nissen fundoplication through conventional laparotomy was performed.
X-rays studies showed the prolapse of the fundoplication through the oesophageal hiatus into the posterior mediastinum.
We carried out the correction of this complication through laparoscopic procedure. We put back the fundus wrap and the lower end of the oesophagus into the abdominal cavity. The oesophageal hiatus was narrowed anterior to the oesophagus by placing deep sutures through the two limbs of the left crus of the diaphragm. Finally we placed some sutures between the diaphragmatic hiatus and the fundoplication.
We comment the benefits we found with this technique and we show a video from the operation.

P092 – Other

POST-CHOLECYSTECTOMY BILIAR LEAKAGE. TREATMENT WITH OCTREOTIDE ASSOCIATED TO LAPAROSCOPY., R. Beltrà MD, L. Sanchis,R Santana,C Hernández, Unidad de Cirugía Digestiva y Laparoscópica. Servicio de Cirugía Pediátrica

Laparoscopic approach has proven to be the first choice when a cholecistectomy have to be done in children. Results are excellent and complications, rare.
Herewith we present the case of a 13 year old girl to whom we performed an uneventful laparoscopic cholecistectomy due to symptomatic cholelithiasis.
She came back 4 days later complaining of abdominal pain and fever. Free liquid in the right subphrenic space was detected in the ultrasonography study. Conservative treatment was started with antibiotics and fat free diet.
In despite of that the patient worsened and the ecography, after another 4 days, showed a significant increase in the amount of liquid collection throughout the whole subphrenic area. A puncture retrieved bile.
Through a laparoscopy we found and aspirated almost 1.000 cc of bile content. We checked the correct sealing of the cystic duct, which had 2 metallic clips correctly applied, and the absence of leakage coming from the area of the rest of the bile ducts. A light oozing seemed to come from the gall bladder's bed. We sealed the raw surfaces with tissular fibrin

glue and left two drains.
An average amount of 250-300 cc of bile was obtained daily through the drains. After 6 days without any appreciable diminution of the losses we started treatment with Octreotide acetate, synthetic polypeptide structurally and pharmacologically related to somatostatin, which has been proven to cause reduction in gastrointestinal fat absorption and decrease bile secretion.
The outcome was excellent, with reduction of 50% of biliar excretion on day 2, few amounts on day 3 and no drainage at all after day 4. On day 7, after negative ultrasonography findings, we withdrew the drains. Three months later the girl remains asymptomatic.
We believe that the association of Octreotide is a safe option for a quick and effective resolution of the post-cholecistectomy biliary leakage in infancy.

P093 – Other

ABDOMINAL SHUNT REVISIONS IN CHILDREN WITH HYDROCEPHALUS IN ONE TROCAR TECHNIQUE, Ulf Buehligen MD, Clinic for Pediatric Surgery, University of Leipzig

Introduction: Abdominal shunt revisions after ventriculo-peritoneal shunts in children with hydrocephalus internus of different causes occur quiet often at every age. Approxiametely one-third of all shunt revisions are necessary with too short abdominal shunt drainage. The laparoscopical abdominal shunt revision in one-trocar-technique is a new and sensitive operation.
Method: Laparoscopy allowes a good insight into the abdominal cave, peritoneum and facilitates, identification of pseudocysts or adhesions. The peripherial shunt drainage can we localised exactly and can be positioned into the abdominal cave under good visual conditions. A 5mm optical system (optic) with integrated 3.5mm working channel allowes access to adhesions the free peripherial catheter without additional incisions. The catheter can be disconnected at the lower valve connector and connected to a longer drainage system. This one will be pulled into the abdominal cave on the abdominal cave on the old catheter. Peripherial catheter which do not reach into the free abdominal cave any more can be implanted again safely with an adapted puncturing technique.
Results: In the time between 5-1996 and 2-2004 we used the laparoscopical abdominal revision with 53 patients. The one-trocar-technique allowes a good view into the abdominal cave and a safe transposition of the new and longer catheter. In only two cases a cardial transposition was necessary because of considerable abdominal adhesions.
Conclusion: In comparison with the conventional operation the one-trocar-technique is easier to carry out, gives a better view and is short in duration of the operation and hospitalisation. The conventional incisions are not necessary any more. Additional operative steps in the abdominal cave are possible without any problems.

P095 – Other

LAPAROSCOPIC TOTAL EXTRAPERITONEAL (TEP) HERNIA REPAIR:INITIAL EXPERIENCE, Haitham I Dagash, Brice A Antao,Sean S Marven MD,Ali Majeed, Sheffield Children's Hospital

Objectives: The Total Extra-Peritoneal (TEP) approach has been proclaimed to be the procedure of choice in laparoscopic tension free mesh inguinal hernia repair. We present our initial experience with this approach in two adolescent males.
Methods: A 10mm port is placed just below the umbilicus and a zero degree scope used. Then two 5mm ports are placed laterally. Dissection is carried out laterally pushing the peritoneum off the anterior abdominal wall muscles. The sac was not excised but separated from the cord structures. A Vypro (Ethicon) ® composite prolene and vicryl mesh was place over the hernial orifices and secured with a protac gun.
Results: Two boys aged 14 and 15 years respectively presented with an inguinoscrotal hernia. Their weights were 84 and 89 kilograms and they were active sportsmen pursuing professional careers. They underwent TEP repair of their hernias as day cases. There were no intra or postoperative complications. At discharge both patients were pain free. Neither suffered from chronic groin pain and were both able to resume their full sporting activities within 3 weeks . At 3 months follow-up both patients were satisfied with the outcome of their surgery.
Conclusion: TEP repair of large inguinoscrotal hernias is feasible in the adolescent age group. Our initial experience suggests that there is minimal postoperative pain and early resumption of activities.

P096 – Other

LAPAROSCOPIC APPROACH IN IMPERFORATE ANUS, S. Geiss MD, F. Becmeur MD,A. Schultz MD,C. Henry MD,I. Talon MD,E. Pierre louis MD, Department of Paediatric Surgery, Centre de la Mère et de l?Enfant, 68 024 Colmar, France,Department of Paediatric Surgery, Strasbourg University Hospitals, Hôpital de Hautepierre, 67 098 Strasbourg, France

Background :
Posterior sagittal anorectoplasty seemed to be the best approach for most intermediate and high imperforate anus and cloacal malformations since 1982. A few paediatric surgery teams began their own experience with a laparoscopic pull-through since 2000.
Patients :
Three patients with an imperforate anus were operated on by laparoscopy after a previous colostomy. They were 3 boys. The birth weight was respectively 2900g, 3200g and 3600g. Two of them had a rectourethral fistula and one a hemisacrum with an anterior meningocele and a long and narrow perineal fistula (Currarino syndrome). Associated genitourinary defect was noticed in one patient with a right renal dysplasia who presented a cat-eye syndrome.
Methods :
A loop descending colostomy was performed in the 24 first hours of life. Laparoscopy was done between the 3rd and 5th month (average weight, 6600g). One optical trocar through the ombilicus and three operative trocars were required. The dissection, sparing the mesenteric vessels could lead easily to the rectourethral fistula in 2 cases. It was suture with a Vicryl 5/0 with intracorporeal knots. Striated muscle structures were located thanks to an electric stimulator used outside on the midline perineal raphe after opening the skin sagittaly on the future site of the anus. A trocar was inserted from outside to through the anal sphincter and pull through was then easily completed. In the case of Currarino, the anterior meningocele was dissected and preserved. In the case of cat-eye syndrome, the right ureteronephrectomy was realized in the same time. The procedure never exceeded 2 hours.
Colostomy never interfered with the mobilization of the rectum during the pull-through. It was closed between 2 and 3 months after the pull-through.
Discussion:
Follow-up is too short (between 18 to 3 months) to discuss the continence, but laparoscopic approach seems to be feasible without any damage to the striated sphincter and allows a very anatomical dissection and pull-through

P097 – Other

VIDEO-ASSISTED BREST REDUCTION PROCEDURE FOR GYNECOMASTIA IN TEENAGERS, Jerzy Harasymczuk PhD, Przemyslaw Mankowski PhD,Marcin Kazmierski MD,Andrzej Jankowski PhD, Department of Pediatric Surgery, Traumatology and Urology, Poznan University of Medical Sciences, Poland

Aim of that work: To present self-experiences in the treatment of gynecomastia in children using newly developed video-assisted brest reduction procedure. To compare results of the video-assisted treatment of gynecomastia based on axillar-approach to those obtained using classical method of breast reduction with areolar incision.
Material and methods: Material consisted of 33 boys aged from 10 to 17 years, presenting both monolateral and bilateral gynecomastia, treated in our Department from 2002 to 2004. Video-assisted brest reduction procedure was performed in each case. During the procedure endoscopic system was inserted into the skin incision in the axillar area, allowing to visualise the range of demanded reduction of the breast parenchyma. The technique allowed to avoid a large undermining between the skin and the muscular plane, that frequently may occur during standart procedures. The excision of overgrowed breast parenchyma was performed through-out the same incision, and no additional surgical approach was demanded to be done in any case. Redon drainage was left for one or two days. The post-op stiches were removed on day 7.
Results: The resulting scar in the axillar area was relativelly small and inconspicious and postoperative breast contour was satisfacted to the patients. No complications were noted in the 6-months follow-up period. Comparing our material to the results of previously used techniques, the adventage of video-assisted procedure is that it allows to remove the breast parenchyma without leaving any scarring around the mammaes, which, from the psychological point of view, was greatly appreciated by

the patients. Time of the operative procedure and the lenght of hospital stay, as well as number of possible complications, remains the same both for the classical and video-assisted breast reduction procedures.
Conclusion: We claim, that video-assisted breast reduction procedure appears to be the most suitable technique for the surgical management of gynecomastia.

P098 – Other

USING LAPAROSCOPIC EXPLORATION AND IRRIGATION OF EXTRAHEPATIC DUCTS FOR CHOLESTATIC JAUNDICE IN INFANT, Chengchang li MD, Qiang Wu MD,Yan Zou MD, Department of Pediactric Surgery, Guangzhou children's hospital, Guangzhou 510120, China.

Purpose:
Surgical treatment is indicated when it is difficulty to differentiate causes of prolonged jaundice in infant. Conventional laparotomy has disadvantages of large trauma, wound dehiscence, delayed recovery, etc. To minimize the complications and achieve early and accurate diagnosis in infant with prolonged jaundice, the laparoscopic exploration and irrigation for extrahepatic ducts were evaluated.
Methods:
After creation of pneumoperitoneum, 5mm 0©b laparoscope was introduced through infraumbilical trocar, one grasping forceps and one coagulating scissor were placed through two trocars in the right upper abdomen, another trocar in left upper abdomen is for pulling out fundus of gallbladder. After opening hepatoduodenal ligament and dissection of porta hepatis, the liver status and the presence of gallbladder, common bile duct and hepatic ducts were evaluated, followed by resection of enlarged hilar lymph nodes. After dissection, the fundus of gallbladder was pulled out through the left upper port and opened, a silica gel canula was inserted into the cavity of gallbladder for irrigation, the cholangiography was performed in some cases, liver biopsy was performed routinely. Bile duct irrigation was applyed for one week postoperatively.
Results:
34 infants (1m ~6m) with prolonged jaundice received laparoscopic exploration of extrahepatic ducts, biliary atresia was confirmed in 14 cases, 5 cases were transformed to Kasai¡¯s procedure. Another 20 cases were cholestasis syndrome, two weeks after operation, the level of blood total bilirubin declined apparently in 11cases, declined in 7 cases , no change in 2 cases. There was no wound dehiscence. The average staying time postoperatively is 7 days. With follow-up of 2 months to 5 years, no jaundice recurred except light hepatocirrhosis was found in 4 cases.
Conclusions:
Laparoscopic exploration and irrigation of extrahepatic ducts can minimize the complications, with advantages of good exposure, less traumatic and quick recovery compared with traditional laparotomy.

P099 – Other

LAPAROSCOPIC ASSISTED ANORECTAL PULL-THROUGH FOR HIGH IMPERFORATE ANUS: THREE YEARS EXPERIENCE, M. Lima MD, G. Ruggeri MD,S. Tursini MD,T. Gargano MD,L. De Biagi MD,A. Pigna MD, Pediatric Surgery?University of Bologna - Italy

Background/Purpose: The aim of this report is to describe our three years experience with the Laparoscopic Assisted Anorectal Pull-through for High Imperforate Anus (LAARP) using the laparoscopic muscle electrostimulation.
Methods: In the Dept of Pediatric Surgery of the University of Bologna, from: March 2001 to January 2004 seven patients, with a diagnosis of high anorectal malformations underwent a LAARP. The patients, all males and aged from 4 to 9 months (mean age 5.8 months), presented a rectourethral fistula.The following associated malformations were described: sacral malformation, laryngeal stenosis, urethral duplication, multicystic kidney, non palpable testis and esophageal atresia. All were treated with a colostomy in the newborn period followed by a delayed LAARP. The laparoscopic step was characterized by the stimulation of the puborectal muscle, using a modified Peña electrostimulator introduced via a trocar. All patients underwent a post operative period of anal dilatations.
Results: In six cases the LAARP was succesful while in one case, due to a strong tension from the colostomy, a conversion to open technique, was needed.
Conclusion: Although an evaluation regarding the continence is to be followed up, we consider the LAARP the treatment of choice for the high imperforate anus. It offers the advantage of a good visualization of the fistula and of the surrounding structures and minimally invasive abdominal and perineal wounds.With the laparoscopic Peña stimulator the direct observation of the puborectal slings contraction allows an evaluation of the functional contractility and an accurate colonic pull through in the centre of the muscle complex.

P100 – Other

PEDIATRIC LAPAROSCOPIC SURGICAL SERVICE (PLSS) IN A GENERAL HOSPITAL : PROBLEMS, PROGRESS & LIMITATIONS IN A DEVELOPING COUNTRY, Ramanujam T Muthurangam MD, Yik Y Ian MD,Sithasanan N Nadesh MD,Srihari S Singaravel, University of Malaya Medical Centre, University of Malaya, Kuala Lumpur, Malaysia

Purpose: To present our experience in setting up the PLSS in our institution & our initial experience with 85 cases over a two year period staffed by a single paediatric surgeon.
Methods & Procedures: 85 laparoscopic procedures were performed in children between 2003 & 2004. Their age ranged between 2 days to 10 years. The common procedures were for Hirschsprung's disease ? 12, Cholestatic jaundice - 13, undecended testis ? 14, anorectal malformations ? 5, nephrectomy ? 4 & diagnostic laparoscopy ? 15, pyloric stenosis-3, appendicectomy - 5. The operating time, conversion rate & complications were charted. The outcome due to other factors, such as limitation of funds, operating theatre time, lack of designated operation theatre & trained personnel & nursing staff were studied.
Results: The proportion of laparoscopic procedures has increased from 2003 to 2004. currently 75% of HD, 80% of diagnostic lap for cholestatic jaundice, 100% of nephrectomies for non-malignant lesions & 60 % of impalpable testes were performed by laparoscopy. Appendicectomies & other emergencies were not performed due to lack of specific OT & trained staff.Initial attempt ended up in breakage & loss of equipment. The operating time has gradually decreased & anaesthetist are more willing after initial difficulties. Lack of theatre time, surgeon's commitments & fatigue has resulted in open procedures in 20 other planned laparoscopic procedures during the same period. Although the initial cost is high, reusable equipment, & re-cycling of disposable equipment has reduced the cost. Complications occurred in 7 cases.
Conclusion: In spite of various limiting factors, setting up a PLSS is a worthwhile undertaking in our hospital. Although our progress is steady but slow, this service should be offered to the needy children, as it has definite advantages. Parental request & child's satisfaction are the major motivating factors.

P101 – Other

MISPLACED HISTOACRYL INJECTION DURING SCLEROTHERAPY - LEADING TO BLEEDING, LIVER ABSCESS & MIGRATION INTO THE PULMONARY CIRCULATION, Yik Y Ian MD,Srihari S Singaravel MD, Ramanujam T Muthurangam MD, University of Malaya Medical Centre, University of Malaya, Kuala Lumpur, Malaysia

Purpose: The aim of this presentation is to highlight an unusual complication during variceal injection with histoacryl (cyanoacrylate monomer) in a child.
Case Report: A one -year old male child was referred to paediatric surgery division due to massive hematemesis following variceal injection with histoacryl. He was resuscitated in our pediatric ICU, & a chest film showed calcified opacity in the upper abdomen & in the left lung field. Emergency laparotomy was performed to control bleeding. The upper half of lesser curvature was adherent to the liver. The gastrotomy incision near the cardiooesophageal junction showed ulceration & the bleeding vessels were ligated. The lesser curvature was released. There was an abscess like area on the inferior surface of liver. About 3.0ml of pus was drained & the cavity in the liver contained the "sugar like" granules of cyanoacrylate. The cavity was cleared, hemostasis was obtained & packed. A modified Sugiura procedure was performed to control bleeding. He recovered well.
Discussion: Complications of Sclerotherapy such as ulceration, bleeding, stricture, perforation & misplaced injection are well documented. However, migration of cyanoacrylate into the pulmonary vasculature is not reported. Conclusion: This case is presented to document the unusual complication of liver abscess following histoacryl sclerotherpay & the risk of pulmonary embolism due to histoacryl, as this substance solidifies quickly after injection.

P102 – Other

ROLE OF DIAGNOSTIC LAPAROSCOPY IN UNCOMMON ABDOMINAL CONDITIONS, Ramanujam T Muthurangam MD, Yik Y Ian MD,Srihari S Singaravel MD, University of Malaya Medical Centre, University of Malaya, Kuala Lumpur, Malaysia

Purpose: The aim of this paper is to evaluate the diagnostic & therapeutic role of laparoscopy in uncommon & undiagnosed abdominal conditions.
Patients & Method: 12 children aged between 5 month to 13 years underwent diagnostic laparoscopy from June 2003 to August 2004. These children were investigated with biochemical, radiological, endoscopic & organ imaging studies. Since a definitive diagnosis cannot be obtained, diagnostic laparoscopy was performed. The accuracy of diagnosis & the extent of the lesions were evaluated. The role of laparoscopy in providing a diagnostic or therapeutic option was studied. The cases were "duodenal hematoma" - 1 Undiagnosed acute abdomen - 4, Cause for acute symptoms in a child with Crohn's disease, "Mesenteric tumor", duodenal mass in ALL, enlarged gallbladder, right iliac fossa mass - 1,recurrent bilious vomiting & Cause for iron deficiency aneamia.
Results: Laparoscopy was diagnostic in 8 cases. Biopsy was performed in two. Laparoscopy guided the site & length of laparotomy incision in 4 & therapeutic in 2.
Conclusions: Diagnostic laparoscopy played an important role in diagnosis & in determining the therapy in 70% of cases. In developing countries, tropical inflammatory bowel disease & other infections may mimic acute abdomen & Kawasaki disease & laparoscopy is helpful in diagnosis & to determine further management.

P103 – Other

THE EFFICACY OF PERCUTANEOUS INTERNAL RING SUTURING (PIRS)- A SIMPLE MINIMAL INVASIVE TECHNIQUE FOR INQUINAL HERNIA REPAIR IN CHILDREN, Dariusz Patkowski PhD, Jerzy Czernik PhD,Rafal Chrzan PhD, Department of Pediatric Surgery and Urology, Medical University of Wroclaw

Laparoscopic herniorrhaphy is gaining increasing acceptance in pediatric surgery. Usually it is performed through three ports in abdominal wall with intraperitoneal suturing. Our own technique - percutaneous internal ring suturing (PIRS) requires only one umbilical port and one pinpoint of 18G injection needle. The aim of the study was to evaluate the efficacy of the PIRS technique for inguinal hernia repair in children.
106 children aged between 28 days and 14,5 years with 140 hernias were operated on in our Department using PIRS. The procedures were performed under general endotracheal anesthesia usually on one day hospital admission. The pneumoperitoneum was created by open technique according to Hasson by introducing 2,5mm or 5mm trocar through lower part of umbilicus depending on the type of laparoscope. Under laparoscopic-guided vision the 18G injection needle with the nonabsorbable filament inside the needle canal was introduced from outside through abdominal wall. With maneuvers of injection needle the filament was passed over the internal ring. Both filament's ends were taken outside peritoneal cavity. The knot was tightened closing the internal ring and placed in subcutaneous space. If an open inguinal ring was found contralaterally, it was closed at the same procedure.
The average operative time was 19 minutes for unilateral and 24 minutes for bilateral hernias dropping to nearly 15 minutes with gaining experience. The follow up was between 3 and 12 months. The cosmetic results were excellent with almost invisible scar in umbilicus. The only intraoperative complication was incidental puncture of iliac vein in three cases that required no treatment. There was one case of adhesion ileus with bowel strangulation. There were three hernia recurrences (2,14%) noted only in boys, one was reoperated with PIRS.
PIRS method seems to be simple and effective minimal invasive procedure with excellent cosmetic results. The recurrence rate slightly higher than that seen with the open technique is acceptable with benefits of laparoscopic procedure.

P104 – Other

COMPARISON OF LAPAROSCOPY VERSUS OPEN PARTIAL NEPHRECTOMY IN CHILDREN, L. Piaggio MD, J Franc-Guimond MD,TE Figueroa MD,R. Gonzalez, A I Du Pont Hospital for Children

PURPOSE
To compared the outcome of laparoscopic versus open partial nephrectomies (PN) for duplication anomalies in our institution. Laparoscopic surgery was the procedure of choice in the last 12 months.
MATERIAL AND METHODS
Retrospective record review of all patients undergoing partial nephrectomies in the last 3.5 years.
RESULTS
There were 33 patients (16 females) divided into 2 groups. Group 1 open (20) and group 2 laparoscopic (13). Mean age in group 1 was 21 months and in group 2, 7.4 months. Diagnosis: ectopic ureter 17, ureterocele 11, VUR 4, and 1 PUJ obstruction. Cystoscopy was performed as part of the procedure in 30 % of group 1 and 100% of group 2. Simultaneous lower tract procedures were performed in 3 patients in group 1 and 1 in group 2. Mean duration of PN was 118 min for group 1 and 178 min for group 2 . There was no significant bleeding or need for transfusion except in one patient in the open group. Average hospitalization was 2.9 days for group for group 1 and 2.5 days for group 2. Analgesic requirement was a mean of 2.3 doses of opioids and 2 doses of ketorolac for the group 1 and 4.3 doses of opioids and 0 of ketorolac for group 2. There were two complications in each group: 1 ureteral bleeding and 1 lower pole ureteral injury in group 1; and 1 omental hernia and 1 urinoma in group 2.
CONCLUSIONS
Laparoscopic PN is feasible, even in small infants and the results comparable to the open procedure.

P105 – Other

VIDEOASSISTED "GEORGESON" PULL-THROUGH FOR HIRSCHSPRUNG's DISEASE IN THE FIRST 2 MONTHS OF LIFE. REPORT OF 11 CASES, A. Porreca MD, A. Capobianco MD,G. Gaglione MD,A. Tramontano MD, Department of Surgery, - Santobono Pediatric Hospital - Naples ? Italy

Introduction. Laparoscopic pull-through (PT) for Hirschsprung's disease (HD) has been growing popularity in recent years. The aim of this study is to report our experience on 11 cases treated with this technique in the first 2 months of life.
Patients. From March 2003 to January 2005, 21 laparoscopic primary PT for HD (Georgeson technique), were performed in our department. Eleven cases were operated within 2 months of age. Three 5mm ports (umbilicus, right upper quadrant, right lower quadrant) and one 3mm grasping instrument, without cannula, in the upper left quadrant, were employed. Seromuscular biopsy was obtained through the umbilical incision after cannula removal. Colon mobilization was made with harmonic scalpel (Autosonik?). Perineal dissection was started 3-5mm proximal to dentate line using bipolar cautery and blunt dissection. The muscular cuff was split posteriorly and pushed back.
Results. The site of aganglionosis was in the sigmoid colon in 8 cases, the descending colon in 2 and in the splenic flexure in one. In one case with descending colon aganglionosis a little left flank incision was required. The median operating time was 120 minutes. The patients were fed on the first day and full diet was commenced usually in the third day. Episodes of mild enteroclitis were observed in one child.
Conclusions. Laparoscopic primary PT according Georgeson's technique appears to be a suitable procedure in the first 2 months of life. The three 5mm ports allow firstly a better visualization through the 5mm telescope, and secondly the use of the harmonic scalpel with a faster and safer tissue cutting and vessel sealing. The 3mm left upper quadrant instrument gives an optimal view of left colon vessels, adding only a minor parietal trauma.
Further follow-up is necessary to assess long-term continence results.

P106 – Other

THE USE OF LIGASURE? IN 18 CASES OF SPLENIC LAPAROSCOPIC SURGERY., A. Porreca MD, C. Terracciano MD, Department of Surgery, - Santobono Pediatric Hospital - Naples ? Italy

Introduction. The LigaSure?, a bipolar hemostatic device, has been recently reported as a useful instrument for laparoscopic splenic surgery in adults. The aim of this study is to report our initial experience with the use of LigaSure? in children undergoing splenic surgery.
Patients. In the last 2_ years we have used the LigaSure? in 18 cases of laparoscopic splenic surgery (age range 5-15 years; mean age 9 years; 11 girls and 5 boys): 16 splenectomies, 1 partial splenectomy for a mesothelial cyst and 1 decapsulation of an epidermoid cyst.
Results. Both LS1000, and the cutting instrument LS1005 were used. With the LS1000, section was obtained applying energy for longer time

between two coagulated sites, often without the need of scissors. Usually The splenic artery was isolated and sealed on the pancreatic edge. The splenic vein and the artery, distally to the previous closure, were sealed and cut with LS1000 or LS1005. In all cases effective coagulation was obtained. For partial splenectomy, splenic parenchima was coagulated and cut with LS1000 after polar artery sealing.
The only adverse effect, more evident with LS1000, was some tendency to sticking. This caused in two cases mild bleeding from the vein, easily controlled with further sealing. No conversions were required.
Conclusions. LigaSureTM offers the advantages of very low thermal damage of contiguous tissues and of only mild smoke production. It allows to perform splenectomy with 5mm operator trocars, without leaving foreign material in the abdomen. In our experience both the 5mm LigaSureTM laparoscopic instruments LS1000 and LS1005 were very effective for sealing and division of splenic vessels and also splenic tissue. LS1000 allows a more meticulous dissection, while LS 1005 is more rapid in cutting tissue and has a lesser tendency to sticking, probably due to the larger active surface.

P107 – Other

THE FIRST YEAR EXPERIENCE WITH LAPAROSCOPIC PEDIATRIC SURGERY, Branka Radojcic MSc, Radoica Jokic PhD,Milanka Tatic MSc,Svetlana Skoric MD,Mihajlo Jeckovic MD,Igor Meljnikov MS, University Clinic of Pediatric Surgery, Novi Sad, Serbia and Montenegro

Purpose: This study reviews the first year of our experience with laparoscopic surgery in children. The aim of this study is analyze of experience influence for overcome standard paediatric laparoscopic procedures.
Methods: We evaluated 42 children (30 female/12 male; age 1-18 years) who underwent minimal invasive procedures including: video-assisted and laparoscopic appendectomy (VAA; LA) - 25, laparoscopic cholecystectomy (LCH) - 5, video-assisted splenectomy - 6, video-assisted Toupet fundoplication- 1, laparoscopic hernioplasty (LH)- 2, laparoscopic exploration in the nonpalpable undescended testes (UT) - 5 and diagnostic laparoscopy (DL)- 3. We compared operative data and types of surgical procedures between the two groups of patients (first and last 6 months).
Results: 86% of all laparoscopic procedures was completed successfully endoscopical. Video-assisted operations and all diagnostic laparoscopies were finished by open surgery.
Operative time for VAA in the first group ranged from 55?120 minutes (avg. 86) vs. 55-90 minutes (avg. 70) in the second group. Average time for creation of pneumoperitoneum in the first group was 18 min vs. 12,8 min in the second group. Days to discharge in both groups were identical (3,8 for VAA, 4 for LCH and 1,33 for UT).
With advanced experience in the second period we performed hernioplasty-2, video-assisted fundoplication-1, diagnostic laparoscopies through open inguinal hernia sac and during the operations for pancreatitis acute and hydatid liver cysts.
Complications rate was 4,76% and all occurred in the second period (arterial bleeding in laparoscopic cholecystectomy and intestinal lesion during the creation of pneumoperitoneum).
Conclusion: It is preferable for a pediatric surgeon to use open Hasson technique and have the assistance of an expert laparoscopic surgeon. Great advantage of this technique is the possibility of performing few different operations during the same laparoscopy. We also concluded that minimally invasive surgery allows procedures in topographically distant abdominal areas. All our results demonstrate real benefits of advanced experience in endosurgical techniques for overcome new laparoscopic pediatric procedures.

P108 – Other

LAPAROSCOPIC INGUINAL HERNIA REPAIR: SIGNIFICANCE OF SAC RESECTION, Amulya K Saxena MD, Cornelia van Tuil MD, Pediatric Surgical University Medical Center, Münster, Germany

Laparoscopic repair of hernia in neonates and children is presently a common day care surgical procedure in many centers worldwide. Many techniques have been described in the literature using minimal access techniques for the management of inguinal hernia. However most of the techniques described, lay more emphasis on the smaller size of the incision as well as the instruments. Some techniques even avoid work ports and hernia closure is achieved using special percutaneous needles and extracorporal suturing of the hernia sac. At our center, laparoscopic inguinal hernia repairs are performed with the primary intention of hernia sac resection and intracorporal suturing and closure. Thirty-seven children, 20 girls and 17 boys underwent laparoscopic hernia repair from June 2003-June 2004. The sac was resected easily in females, and care was taken in boys not to injure the vas and the testicular vessels. After sac resection the internal ring peritoneum was closed using 4-0 monofilament sutures. There were no complications and the average time to perform each side was approximately 15 minutes. All the patients were discharged on the day of the procedure. As in the open procedures we prefer not to only ligate but also remove the hernia sac. Procedures that do not resect the hernia sac run the risk of recurrence, the actual incidence of which is emerging in the literature. The time required for laparoscopic resection versus ligation procedures is almost comparable. Our technique of careful identification and sac removal is safe in male patients. It markedly reduces the dependence of the suture material and suture knots reopening in the laparoscopic management of inguinal hernias.

P109 – Other

CONSERVATIVE SURGICAL CONDUCT ON GALL BLADDER LESSIONS, R.A. O Shidi MD, Need

Traumatic lesions of extrahepatic biliary tracts are frequently diagnosed during laparotomy when associated with lesion of other viscera. Isolated rupture of gallbladder due to closed abdominal trauma are realy uncommon. Symptoms due to lesions of gallbladder could be confused with trauma of abdomina wall and so delay the diagnosis. On descovering gallbladder rupture, the most common treatment is colecistectomy. The objective of this research is to verify if rafia of gallbladder lesion could be done as an alternative surgical conduct. Functional test by cholecystogram was performed on 10 dogs of about 10kg, after oral ingestion of Iocetamic acid -telepaque, Followed with buyden test at 30 and 60 minutes after oral ingestion of 20ml of milk shake. One week later, transverse or longitudinal cholecystotomy of 2cm, followed with primary rafia is performed at fundus or body of the gallbladder. Planimetric studies of the radiologic image before and after operation were used to evaluate gallbladder morphologic function. The gallbladder didn't present any important alteration. There was no gallstone, bile clay nor functional alterations during the period of studies. The result obtained permited to conclude that gallbladder rupture up-to 2cm length, and be sutured maintaining gallbladder preservation.

P110 – Other

PLUMBISM AFTER PROLONGED RETENTION OF LEAD FOREIGN (PB) BODIES, S. Spyrakos MD, M Soutis MD,A Panagou MD,G Christopoulos-Geroulanos MD, Surgical Department ?Aghia Sophia? Children's Hospital. Athens, Greece

Foreign body ingestion is common in the pediatric population. In the majority of cases no intervention is required. However, heavy metals when swallowed require urgent endoscopic removal. In such cases monitoring of the blood levels of the metal is necessary.
Two cases of elevated lead (Pb) blood levels, following prolonged retention of the foreign bodies are presented. In the first case a fish sinker was retained in the stomach for 13 days before endoscopic removal. In the second case the increaesd blood lead levels were due to impaction of pelets in the lung parenchyma after a gun shot in the thorax.
Both patients were asymptomatic and their lead blood levels were monitored up until they reached normal levels. Prolonged chelation therapy was required only in the case of the ingested foreign body. In the second case the lead pellets causes transient increase of blood levels but no chelation was required.

P111 – Other

LAPAROSCOPIC DAY-CARE SURGERY IN CHILDREN, Salmai Turial MD, G Abdul-Aziz,Th Hückstädt,Ch Zagar,F Schier, Pediatric Surgery University medical centre Mainz, Germany

Introduction:
The concept of laparoscopic day surgery is increasingly accepted also for children. We report our experiences with this modality.
Material und Methods:
In 2004, out of 322 laparoscopic interventions, 63 (19,5 %) were scheduled as ambulatory surgery. The age range was 1-15 years (mean 3.5 years). The most frequent procedure was laparoscopic herniorrhaphy (n=42, 75%). In the remainder, diagnostic laparoscopy was performed or laparoscopy for undescended testis or for varicocele. In four cases the

surgery was for recurrences. In four cases additional minor procedures were performed during the same session.
Results:
No postoperative complications occurred. 92,1% of all cases scheduled as day-surgery were completed as such. In five children (7.9%) the hospital discharge was delayed until the next morning due to anesthesiologic concerns.
Conclusion:
Minimally invasive surgery in children lends itself to day-care surgery. In our experience minimally-invasive surgery lends itself to ambulatory surgery. Further studies are needed to evaluate its use in children below the age of one year.

P112 – Other

THE RABBIT MODEL FOR TEACHING AND TRAINING PEDIATRIC LAPAROSCOPIC SURGERY: 5 YEARS EXPERIENCE, Juan P Valdivieso MD, Monica Contador MD, Hospital de niños Roberto del Rio. Santiago, Chile

INTRODUCTION: Training in pediatric laparoscopic surgery is a must. In 2000 we proved that the adult rabbit model could be used to resemble the main laparoscopic procedures in small children. We report now our 5 years experience in the use of this model.
MATERIAL AND METHODS: This work was done at the Laparoscopic Surgery Training Center of the University of Chile, supported in the first 2 years by Johnson & Johnson Medical and since 2002 by Tyco Healthcare International. The model consisted in adult rabbits with an average weight of 2.5 kg, operated under endovenous anesthesia, with 5 mm instruments. Animals were all sacrificed at the end of the sessions.
RESULTS: During the first year we validated the model, in a 11 animals series. Since then we have done permanent training for our residents (a total of 12 in this period) that included weekly sessions for two of them each time. Basic skills in laparoscopy, suturing, practice of some interventions like Nissen fundoplications, nephrectomies, intestinal pull-through, and simulated appendectomy using the bicorn uterus, were part of this training. The goals for each year were sistematically evaluated by the authors. Satisfactory results were found in all of the residents for basic laparoscopic skills, and almost 85% developed advanced skills. This allowed residents to gradually assist and operate in lap cases in children. Mean operative time was 2.5 hours and almost 2/3 of the animals were alive at the end of the procedure. Trocar dislogment is frecuent in this model and a purse string was used to prevent it. Using the rabbit model we developed a Basic Pediatric Laparoscopic Surgery Course for pediatric surgeons. With 6 versions to date, this course has received a good evaluation by participants. As a collateral effect, the model was adopted by 2 other pediatric laparoscopic groups in Santiago, and also to train adult surgeons residents at the same Center.
CONCLUSIONS: Our experience with this model allowed us to improve our own skills for laparoscopy in newborns and infants, and specially to give a permanent training to the residents at a very low cost. We hardly recommend it as part of all residency programs in Pediatric Surgery.

P113 – Other

EXPERIENCE WITH HEMANGIOMAS OF THE LARYNX AND TRACHEA IN 56 CHILDREN, J Waldschmidt PhD, H Giest MD,L Meyer-Junghänel MD, St. Joseph Childrens Hospital, Berlin, Germany

Introduction: Hemangiomas of the larynx and trachea are life-threatening diseases in infants. The typical sign is a stridor during the first 2 or 3 month of life, often associated with an increasing size of cutaneous hemangiomas.
Patients: In a 20 years period from 1983 to 2003 56 infants underwent endoscopical laser disobliteration of the larynx and trachea in our hospital. In 17 cases the endoluminal angioma was associated with additional disturbances like extensive hemangioma of the face or neck. The airway segments most frequently involved were the subglottic area and the larynx (n=44). The size expansion is similar to those of cutaneous angiomas: limited to the mucousa (n=27), infiltrating the submucousa with tumorous endoluminal bulging (n=22) and transmural spreading into the extratracheal adherent tissue (n=7).
Therapy: The therapeutic procedure depends on the kind of the angioma. All children were treated by NdYAG laser using a 0.4 mm bare fiber with different modes. For capillary angiomas we prefer the non contact technique, interrupted, 15-20 watt. The submucous located cavernous angioma with endoluminal bulging are treated by ablation, 20 watt single impulse. For the transmural angioma we prefer the LITT, 2-3 watt, cw.
Results: Endoluminal laser treatment has been used successfully in all children we have seen. In 50 cases one laser session was sufficient, in six children 2-4 sessions were necessary. In 16 children temporarily tracheostomy was performed. All children are alive.
Keywords: tracheal stenoses, hemangioma, NdYAG laser

P114 – Other

PROSPECTIVE EVALUATION OF PAEDIATRIC LAPAROSCOPIC TRAINING EXPERIENCE AND COMPETENCY, Gregor M Walker MD, Gordon A MacKinlay MD,Fraser D Munro MD,William G Manson MD, Royal Hospital for Sick Children, Edinburgh, Scotland, United Kingdom

INTRODUCTION: Training in laparoscopic surgery requires the attainment of certain core skills. Current logbook formats where only case numbers are recorded do not adequately demonstrate the level of skill acquired. Additionally, in many cases categorised as ?assisted?, trainees may have gained practical experience without performing the majority of the procedure. The authors present the ongoing findings of a locally devised logbook that allows individual skills to be recorded, and the level of competency assessed in a prospective fashion.
METHODS: The new laparoscopic logbook was introduction in June 2004 and is stored in a dedicated laparoscopic operating room. Trainees recorded the skills attained for each case including port insertion, camera management, tissue manipulation, diathermy dissection, suturing, knotting, and loop placement. The supervising consultant randomly assessed the competency shown in each task, using a 5-point scale.
RESULTS: In 6 months, specialist surgical registrars attended 77 cases involving laparoscopic skills. Traditionally 43 (57%) of these cases would have been categorised as ?assisted?, 29 (38%) as 'supervised? and 4 (5%) as performed independently. In 85% of cases the trainee gained experience in minimally invasive skills other than camera manipulation. All trainees attained a satisfactory level of competence in each skill.
CONCLUSIONS: This novel technique of recording skills in addition to cases more accurately demonstrates experience gained. The prospective assessment of competence is essential for continuous professional development and can be used for directed learning.

P115 – Other

OMENTAL HERNIATION FOLLOWING LAPAROSCOPIC PYLOROMYOTOMY, Gregor M Walker MD, Gordon A MacKinlay MD,Claire Clark MD,Peter Ferguson MD,William G Manson MD,Fraser D Munro MD, Royal Hospital for Sick Children, Edinburgh, Scotland, UK

INTRODUCTION: Incisional hernia, presenting with omentum herniating through the wounds post-operatively, is a recognised complication previously reported in other published laparoscopic series. The authors report on 4 infants that required exploration of wounds due to herniation of omentum in the early post-operative period following laparoscopic pyloromyotomy.
PATIENTS: Four infants (3 boys, 1 girl) underwent laparoscopic pyoloromyotomy employing single umbilical port technique with instruments passed through right upper quadrant and epigastric incisions without ports. Median age at surgery was 40 days (range 23 ? 53 days). Each case was performed or supervised by a consultant paediatric surgeon. Omentum was noted to be herniating from the wounds prior to discharge in all cases. In 3 cases, omental herniation was noted within 12 hours, and the patients were immediately returned to the operating room. The remaining case was noted when a dressing was removed 3 days post-operatively. All cases were managed with excision of the herniating omentum and formal closure. In 3 cases the omentum herniated through the upper abdominal wounds, and in one case through the umbilical wound. In each case the skin had been closed with glue rather than subcuticular suture. These complications represent 5.5% of the laparoscopic pyloromyotomies performed.
CONCLUSION: These cases emphasise the need for meticulous care when removing instruments and ports following laparoscopy in infants. Instrument removal and pneumoperioneum deflation should be performed under direct vision.

P116 – Other

RETROPERITONEAL CYSTIC LYMPHANGIOMA: LAPAROSCOPIC EXCISION IN TOTO, Barbara E Wildhaber MD, Christophe Chardot MD,Bernard Genin MD, Pediatric Surgery, University of Children's Hospital, Geneva, Switzerland

Introduction: Retroperitoneal cystic lymphangioma is a rare benign tumor of the retroperitoneal lymphatics, that usually manifests in infancy. If surgical excision is used in treatment, it needs to be as complete as possible in order to reduce the risk of recurrence. Two children are presented, in whom successful laparoscopic excision of a retroperitoneal cystic lymphangioma was performed.
Case Reports: Patient 1, a 4 year old boy, presented with acute abdominal pain located in the right epigastrium. An abdominal ultrasound (US) and CT scan revealed a macrocystic lesion (maximum cyst diameter 12 cm), located in the retroperitoneum, posterior to the spleen. Patient 2, a 18 month old female, presented with chronic vomiting and abdominal pain. US and CT scan showed a septated mass adjacent to the spleen, kidney and pancreas, with an intra-abdominal extension along the descending colon, expanding into the pelvis. Both patients underwent laparoscopic excision of those masses, whereby the cysts were freed from their adhesions using a transperitoneal approach, and, upon aspiration of the liquid, easily extracted through the trocars. Macroscopically, the resection was complete in both cases. Histologically, a cystic lymphangioma with focal inflammation and hemorrhage was found in patient 1, and an uncomplicated cystic lymphangioma in patient 2. Postoperative course in both cases was uneventful, no recurrence was observed 18 months after surgery. and both children remain asymptomatic.
Conclusion: Complete excision of a retroperitoneal cystic lymphangioma was performed in two pediatric patients, with neither complication nor recurrence. Laparoscopic excision should be considered as a therapeutic option to treat retroperitoneal cystic lymphangioma.

P117 – Robotics

ROBOT-ASSISTED LAPAROSCOPIC RESECTION OF CHOLEDOCHAL CYST WITH ROUX-EN-Y RECONSTRUCTION, Adrien J Kant MD, Christina M Shanti MD,Scott E Langenburg MD,Michael D Klein MD, Children's Hospital of Michigan, Wayne State University

Case Report: We present the first clinical report of Zeus robot- and laparoscopic-assisted excision of a type 1 choledochal cyst (CC) with Roux-en-Y reconstruction. A five-year-old boy was seen with abdominal pain, fever and vomiting. Ultrasound, CT scan and ERCP showed a fusiform dilation of the common bile duct, consistent with a type 1 choledochal cyst. At operation, the Zeus robot was used to dissect the porta hepatis and CC, which was clipped and distally divided, as was the cystic duct (115 min). We then divided the jejunum internally with an endo-GIA and exteriorized the bowel through an enlarged port site to perform the Roux-en-Y anastomosis extracorporeally with interrupted 4-0 silk sutures (116 min). Zeus was then used to create the choledochojejunostomy with six 5-0 polyglactin interrupted sutures, while the proximal common bile duct was progressively divided (128 min). Finally, the gallbladder was removed and a drain left near the anastomosis. Total operative time was 462 min from first incision to closure. The patient had a small bile leak (275 cc) from the drain on postoperative day (POD) 2, which resolved by POD 9, when his drain was removed for discharge home. CT on POD 8 revealed no intraabdominal abscess or biloma. The patient's recovery was otherwise uneventful.
Discussion: Choledochal cyst is an uncommon entity usually treated with laparotomy for excision and hepatico- or choledochoenterostomy. Of a dozen case reports to date describing laparoscopic approaches to CC, the largest two pediatric series included 35 and 45 patients, but none report the use of a robot. Minimally invasive surgery offers reductions in pain, recovery time and scarring, all significant advantages in pediatric patients. Robotic surgery further enhances minimally invasive techniques through tremor filtration, motion scaling and movement indexing, giving the surgeon fine, precise control in very small spaces. These advantages have been demonstrated in animal models, but have not yet been reported in clinical management of CC. This case demonstrates that a surgical robot can successfully aid in the performance of complex minimally invasive gastrointestinal surgery in children.

P118 – Robotics

ROBOT ASSISTED PULMONARY RESECTION IN A CHILD WITH CCAM, Mustafa H Kabeer MD, Vinh T Lam MD, David L , Children's Hospital of Orange County

An eight year old girl presented with a history of recurrent pneumonia for the past three months associated with fever and cough. She had finished her course of antibiotics. A CT scan of the chest revealed numerous cystic lesions in the left upper lobe. The diagnosis was congenital cystic adenomatoid malformation. The patient was to undergo a left upper lobe pulmonary resection with robotic assistance.
The patient underwent general anesthesia with a double lumen endotracheal tube and then had a central line, arterial line, Foley catheter and a thoracic epidural catheter placed. She was placed in a right lateral decubitus position. The entire operation was performed with four trocars:
1. 8mm trocar at 3rd intercostal space at anterior axillary line for left robotic
arm.
2. 12 mm trocar for scope at 6th intercostal space near inframammary crease on lower anterior chest.
3. 5mm accessory port at 10th intercostal space at anterior axillary line.
4. 8 mm. trocar at 10th intercostal space inline with scapular border for right robotic arm.
The dissection consisted of taking down pulmonary adhesions on the anterior thoracic wall. The oblique fissure was then dissected to isolate pulmonary arterial branches to the left upper lobe with subsequent ligation and division with an Endo-GIA 35 vascular stapler. The pulmonary venous branches were isolated in the anterior hilum and similarly ligated and divided with an Endo-GIA 35 vascular stapler. The bronchial supply was divided with an Endo-GIA vascular stapler.
The left upper lobe was then removed through the accessory port site by extending the incision from 5mm to 15mm. The cavity was irrigated with saline and the patient was given a Valsalva breath. No air leak was noted from the bronchial stump and the left lower lobe was well aerated. A chest tube was placed and the instruments and trocars were removed. She was hospitalized for six days mainly due to serous fluid output from the chest tube. Her pain was controlled with the thoracic epidural catheter and subsequently with a PCA. She has resumed full activity since her last follow-up.

P119 – Robotics

ROBOTICALLY-ASSISTED PROCEDURES IN THE MANAGEMENT OF GERD IN INFANTS AND CHILDREN, Dra. Natalia E Tamburi RN, Michael S Irish MD,Onyebuchi Ukabiala MD,Thom E Lobe MD, Blank Children's Hospital, Des Moines, Iowa, USA

Purpose: The use of robotic surgical systems has increased in the management of many pediatric surgical conditions. Recently, this has been due and refinement of technique and the development of smaller instruments. Our purpose was to evaluate an experience with robotically-assisted procedures in the management of gastroesophageal reflux disease to determine advantages, disadvantages and complications.
Methods: From October 2002 to August 2004, 18 children (8 female, 10 male) with a mean age of 6.8 years (range 1-day to 17years) and a mean weight of 27.8kg (range 2.2 to 82kg) underwent robotically-assisted, laparoscopic Nissen fundoplication. Six patients also had gastrostomy tube placement and 1 patient had pyloroplasty. The da Vinci(TM) robotic system (Intuitive Surgical, Sunnyvale, CA) was used in 15 cases, and Zeus(TM) (Computer Motion, Goleta, CA) was used in 3. The indications for surgery were gastroesophageal reflux in all cases with hiatal hernia in 7, esophageal stricture in 1, failure to thrive in 7, and delayed gastric emptying in 1 case.
Results: All procedures were completed successfully with robotically-assisted minimally invasive surgery. There were no conversions. Blood loss was negligible in all cases. Mean postoperative length of hospitalization for all patients was 2.8 days (range 1-16 days). Postoperative complications included limited dysphagia in 3 of our earliest patients. One had spontaneous resolution and two required dilation. Additional complications included superficial wound infection from gastrostomy tube leak in one patient, and recurrent hiatal hernia in one patient, which required reoperation.
Conclusions: Robotically-assisted minimally invasive surgery is feasible and safe in patients as small as 2.2 kg. Advantages of this technology include the increased range of motion of robotic instruments imparting the ability to perform delicate and precise procedures in small spaces. Currently, the use of a 5 mm camera sacrifices the advantage of 3-dimensional vision available to the surgeon with the larger 1.0 cm camera. Finally, limited tactile feedback continues to be a disadvantage compared to open surgery. We do not directly attribute any of our complications to the robotic technique. However, as more experience was gained with robotic surgery there we noted no further postoperative dysphagia.

P120 – Spleen/Solid Organ

LAPAROSCOPIC SPLENECTOMY FOR HEMATOLOGICAL DISEASES IN CHILDREN, Monica Contador MD, Juan P Valdivieso MD, Maria Morales MD,Rodrigo Contreras MD, Hospital de niños Roberto del Rio. Santiago, Chile

Purpose: Laparoscopic splenectomy (LS) has become a useful tool in the treatment of some hematological diseases. We evaluated our experience using this technique.
Material and Methods: Retrospective review of 23 LS performed from January 1998 to June 2004 in hematological patients. The series includes 14 Familiar Microspherocytosis (MS) and 9 Idiopathic Thrombocytopenic Purpura (ITP). All of them had preoperatively antipneumococcal vaccine and ultrasonography to assess spleen size and presence of gallstones. Four trocars and 45º lateral decubitus position technique was used. Harmonic scalpel was utilized in most of the cases. Intraoperative search for accesory spleen was done in all cases. The spleen was morcellated and removed in a specimen bag.
Results: The group included 23 patients (M:F= 13:10). Median age was 10 years (6-14). Seven MS patients required simultaneous lap cholecystectomy (LC). An accessory spleen was found in 3 cases. There were 2 conversions, 1 due to poor vision and 1 bleeding. No blood transfusions were required, and only two ITP patients received platelets. Median operative time was 160 min (105-270) for splenectomy alone and 235 min (200-240) for LS and LC. Postoperative complications included 3 atelectasis and a late diaphragmatic hernia. Oral intake was reassumed within 12 hrs (6-18) for LS and 36 hrs (24-48) for converted patients. Mean hospital stay was 3 days (6.5 in converted cases). Mean follow up was 14 months (5-32). All ITP patients had normal platelets count postoperatively except one that increased from 2000 to 40000 and is currently asymptomatic. All MS patients recovered without anemia.
Conclusions: Laparoscopic splenectomy in our hands shows low morbidity and short hospital stay, as in other series. Only converted cases have delayed oral intake and longer hospital stay. Careful dissection of splenic diaphragmatic adhesions is warranted to prevent diaphragmatic complications

P121 – Spleen/Solid Organ

LAPAROSCOPIC EXCISION OF CONGENITAL HEPATIC CYSTS IN THE PEDIATRIC POPULATION: A CASE SERIES AND LITERATURE REVIEW, Brian Duffy MD, C. David Tsung BS,Gary E Hartman MD,A. Alfred Chahine MD, Children's National medical Center and Georgetown University Medical center

Purpose: Congenital non-parasitic hepatic cysts are rare. Surgical excision is indicated for symptoms and to rule out malignancy. Although open surgical management is the conventional treatment for symptomatic cysts in adults, the laparoscopic approach has gained wide acceptance. We here present a case series involving laparoscopic excision of congenital hepatic cysts in the pediatric population.
Methods: The charts of children presenting with simple benign hepatic cysts in a seven year period were reviewed. The presence of a congenital hepatic cyst was the only inclusion criterion; there were no exclusion criteria. Diagnostic imaging and pathology were reviewed by attending physicians.
Results: Three patients were found. Patient #1 is a 7 week old infant presenting with abdominal pain, emesis, and a palpable abdominal mass. Ultrasound demonstrated a cystic lesion; CT scan was suggestive of a hepatic cyst. Patient #2 is a 6 year old who underwent elective excision of a persistent hepatic cyst that was previously identified by ultrasound during a prior admission. They both underwent uncomplicated laparoscopic excision. Patient #3 had a prenatally suspected left congenital diaphragmatic hernia. At birth, he was found to have a large left thoracic cyst that communicated through the diaphragm with a cystic lesion in the lesser sac. Upon exploration it turned out to be a cystic lesion emanating from the left lobe of the diaphragm and protruding through the diaphragm into the left chest. It was excised via a combined thoracoscopic and laparoscopic approach. All three lesions turned out to be simple, benign, non-parasitic hepatic cysts. Patient #2 developed a superficial wound infection treated successfully with antibiotic therapy. All children were well at 6-month follow-up.
Conclusion: Our case series is the largest report documenting laparoscopic excision of congenital hepatic cysts in the pediatric population. Although these lesions are rare, they may produce symptoms early in life. Laparoscopic excision of congenital hepatic cysts was performed safely and effectively in our population.

P122 – Spleen/Solid Organ

LAPAROSCOPIC PANCREATIC SURGERY IN THE PAEDIATRIC POPULATION; A LITERATURE REVIEW, W M EL-SAIFY MSc, University Hospital of Hartlepool, UK

INTRODUCTION:
Laparoscopic pancreatic surgery has been reported with encouraging results in adults; however its role in children is still controversial. This review summarizes current data on laparoscopic pancreatic surgery in children.
METHODS:
A literature review was carried out accessing all English language journal articles since 1990. Medline and Embase databases were searched for ?Laparoscopy? and ?Pancreatic, Paediatric?. Other articles cited in bibliographies were also obtained.
RESULTS:
The searches generated 63 references and over 90 articles were subsequently reviewed. Laparoscopic distal pancreatectomy for blunt abdominal trauma, insulinomas, solid pseudo papillary tumours and subtotal pancreatectomy for persistent hyperinsulinaemic hypoglycaemia of infancy (PHHI) have been described. Preservation of the spleen was feasible in few cases. Laparoscopic cholecystectomy and common bile duct (CBD) exploration are safe and feasible surgical techniques in the management of pancreatits and CBD obstruction in children.
CONCLUSIONS:
Paediatric laparoscopic pancreatic surgery remains in the realm of case reports; however the role of minimal invasive pancreatic surgery in children is likely to increase as more surgeons acquire advanced laparoscopic skills.

P123 – Spleen/Solid Organ

WISKOTT-ALDRICH SYNDROME: ANOTHER INDICATION FOR LAPAROSCOPIC SPLENECTOMY IN CHILDREN, D. FALCHETTI MD, F. TORRI MD,L. TONEGATTI MD,P. PEDERSINI MD,LD NOTARANGELO* MD,G. EKEMA MD, Department of Paediatric Surgery, *Department of Paediatrics, Spedali Civili, Brescia, Italy

Some pediatric hematologic and immunologic diseases require elective spleen removal. We reviewed our experience of laparoscopic splenectomy in children with Wiskott-Aldrich Syndrome (WAS) and its allelic variant (XLT), rare forms of immunodeficiency characterized by eczema, recurrent infections, and thrombocytopenia without splenomegaly,.
Patients and methods. From January 1996 to November 2004, 27 laparoscopic splenectomies were performed at the Departement of Pediatric Surgery, University of Brescia, Italy. Indications were: spherocytosis (12 cases), WAS (5 cases), chronic idiopathic thrombocytopenic purpura (5 cases), maior thalassemia (3 cases), dyserythropoietic anemia, and splenic hemangioma (1 case each).
WAS and XLT children age range was 6mos-10yrs; the main reason for splenectomy was severe thrombocytopenia (<20 x 109/L).
The procedure was always performed with 4 10mm trocars. Abdominal and epiploon retrocavity exploration was always associated to check for accessory spleens. Normal size of the spleen allowed a comfortable removal through a bag without auxiliary small laparotomy. All patients received prolonged antibiotic prophylaxis after splenectomy.
Results
Conversions were never needed. In patients with WAS the procedure time varied from 260min, in the first case, to 105min (mean 185min), including a case which required an extended peritoneal exploration to remove many accessory spleens. All patients were normally fed on the first postoperative day.
At a mean follow-up of 45mos, all patients are alive and none had episodes of severe sepsis. Platelet counts have increased in all patients; one child required bone marrow transplantation because of deterioration of the immune status.
Conclusion
Our experience supports the benefits and safety of laparoscopic splenectomy for hematologic and immunologic disorders. WAS and XLT-related severe thrombocytopenia can be a proper indication for splenectomy. In these patients, the spleen removal is technically easy because the spleen is not enlarged.

P124 – Spleen/Solid Organ

LAPAROSCOPIC TREATMENT OF A WANDERING CYSTIC SPLEEN, D. FALCHETTI MD, F. TORRI MD,S. *DUGHI MD,C. §PORTO MD,S. BENVENUTI MD,A. MANCIANA MD,E. CAPPELLARO MD,G. EKEMA MD, Department of Pediatric Surgery, * Unit of Pediatric Radiology,§ Department of Anaesthesiology, Spedali Civili, Brescia, Italy

The paper describes laparoscopic treatment of a complex splenic disorder: a splenic cyst (SC) in a wandering spleen (WS).
A 14-year-old girl with passion for martial arts came to our observation because of an abdominal mass in the left lower abdomina quadrant. Diagnosis of a WS containing an 8cm non-parasitic cyst was made. Surgery was very conservative with the aim of restoring both splenic anatomy, function and location.
Through a 4 trocars approach a near-total cystectomy after decapsulation was performed and then a bag of vycril mesh was placed around the opened spleen, and fixed in the left upper quadrant of the abdomen which was subsequently covered with omentum.
Surgery and postoperative corse were uneventful. During a 6mos follow-up period the girl attends all her usual activities without any restrictions and has had no problems. Ecographic controls constantly confirme the correct position of a cup-shaped spleen with no sign of cystic recurrence.
Both WS and SC are rare benign congenital conditions, each of which can generate severe vascular complications, and their association would seem even more dangerous. These unusual, associated splenic disorders can be treated conservatively by laparoscopic surgery.
To the best of our knowledge this is the first report of a successful laparoscopic treatment of a wandering cystic spleen.

P125 – Spleen/Solid Organ

LAPAROSCOPIC PARTIAL PERICYSTECTOMY OF HYDATIDE LIVER CYST IN CHILDREN, Nenad Janic PhD, Spasoje Radulovic MD,Zoran Golubovic PhD, University Childrens Hospital, Belgrade, Serbia
Aim: Possibilities of laparoscopic treatment hydatide liver cyst in children depending on the location and size of the cyst.
Methods: Three patients underwent treatment for hydatine liver cyst previously diagnosed by ultrasound. The diagnosis was confirmed by CT and serologic reactions. In the treatment of the selected patients the following criteria were used: localization (peripheraly positioned segments 4, 5 and 6), size
(5 -7cm), type of the cyst (unilocular) and previous conservative treatment (ceased growth of the cyst and calcification). We used the following procedure: evacuation of cystic fluid by pericystic puncture; incision of the pericyst using Ultracision 5 mm knife; vacuum aspiration of the cyst through a 10 mm port using a aspiration catheter, and partial resection of the pericyst at the level of liver surface (''unroofing") using Ultracision knife.
Results: We treated 3 patients (2 girls and a boy), aged 8, 9 and 14 years, respectively. The diameter of cysts was 5, 6,5 and 7 cm. Preoperatively, they were treated conservatively (albendazol). Postoperative follow-up of minimally 20 months showed absence of recurrence. Hospitalization was from 2-4 days. There were no complications.
Conclusion: The advantages of laparoscopic treatment of the hydatide liver cyst are: lowered trauma (minimally invasive surgery), less postoperative pain and complications, better view and approach to the cyst, better esthetic results, shorter hospital stay and rapid return to normal daily activities.

P126 – Spleen/Solid Organ

A RARE CASE OF PEDIATRIC WANDERING SPLEEN SUCCESSFULLY TREATED BY LAPAROSCOPIC SPLENOPEXY, Oleg Kleiner MD, Robert Finaly MD,Jacob Mordehai MD,Eliezer Avinoah MD,Nitza Newman MD,Zahavi Cohen MD, Department of Pediatric Surgery, Soroka Medical Center, Faculty of Health Sciences, Ben Gurion University of the Negev, Beer Sheva, Israel

Objective: Wandering spleen is a very rare clinical condition associated with a high incidence of splenic torsion and infarction. The preferred treatment for this condition is splenopexy in the left upper quadrant of the abdomen.
Case study: We describe a 12 years old girl presented with intermittent abdominal pain. An abdominal sonography was diagnostic of wandering spleen. The patient was successfully treated by laparoscopic splenopexy. The spleen was repositioned in the left upper quadrant and fixated to the posterior abdominal wall by a Vycril mesh patch attached by staples. In order to reinforce the splenopexy we created an additional support of the spleen by suturing the preexisting splenocolic ligament to the lateral diaphragm making a pouch for the inferior pole of the spleen. The postoperative course was short and uneventful. A normal position of spleen was verified by sonography at 3 and 6 months interval postoperatively.
Conclusion: Laparoscopic splenopexy is an excellent option for organ preserving treatment in wandering spleen.

P127 – Spleen/Solid Organ

THERAPEUTIC ENDOSCOPIC RETROGRADE CHOLANGIO-PANCREATICOGRAPHY WITH PAPILLOTOMY IN AN INFANT WITH ACUTE PANCREATITIS : A CASE OF PANCREAS DIVISUM, Lucas Matthyssens MD, Dirk Vervloessem MD,Micheline Van Caillie-Bertrand* PhD,Sami Cadranel# PhD,Jacques Devière# PhD, Departments of Paediatric Surgery and Paediatric Gastroenterology and Nutrition*, Queen Paola Children's Hospital, Antwerp & Departments of Gastroenterology and Endoscopy# Hôpital Erasme, Brussels, Belgium

INTRODUCTION: Pancreatitis in children is uncommon but underestimated. The etiology in children is mostly posttraumatic. Minimal invasive Magnetic Resonance (MRCP) and Endoscopic Retrograde (ERCP) CholangioPancreaticography are the diagnostic and therapeutic tools by excellence.
CASE REPORT: We present the case of a previously healthy 22 month old boy, complaining since 2 weeks of vague abdominal pain, mostly at night. Abdominal ultrasound (US) revealed a nodular hyperechogenic and cystic zone (3x2cm) at the level of the pancreatic processus uncinatus. White blood cells and pancreatic enzymes were raised and the infant was hospitalised. MRCP showed a diffusely edematous cystic lesion of 12mm diameter in the head of the pancreas. Normal Wirsung and Common Bile Ducts were seen.
A traumatic origin, after a minor car accident 6 months prior, was suspected.
After initial amelioration, severe acute pancreatitis (SAP) developed with ascites, left pleural effusion and formation of more cysts ? also at the tail of the pancreas and behind the left kidney. Percutaneous US-guided cyst aspiration showed pancreatic origin, with cultures positive for E.coli. Systemic Inflammatory Response Syndrome developed and full intensive care treatment was started. Exploratory laparotomy was performed with drainage of the pseudocysts behind and at the tail of the pancreas. At the head, an incorporated inflammatory mass was left untouched. Postoperative recovery was remarkable, but when starting enteral feeding, SAP recurred. Medical treatment was succesful and US showed total disappearance of the pseudocysts, but augmentation of the cyst in the head of the pancreas.
Therefore, MRCP with administration of Secretin was done, showing a cystic dilatation of the Santorini duct in the head, and a pancreas divisum with a filiform connection between the Santorini and Wirsung Ducts. ERCP confirmed this diagnosis. At cannulation of the Papilla minor, dirty fluid spirted out. A papillotomy of both ducts was performed without stenting.
Oral feedings were progressively restarted and the child was dismissed 3 days later in good condition. One month follow-up is perfect.
DISCUSSION: Pancreatitis in infants is challenging, for diagnostic and therapeutic purposes. The importance of Secretin administration improving MRCP and of therapeutic ERCP with papillotomy is stressed and illustrated by this rare case of complicated pancreas divisum and a review of the literature.

P128 – Spleen/Solid Organ

LAPAROSCOPIC SPLENECTOMY IN CHILDREN, Claudia Marhuenda MD,Gabriela Guillén MD, Jose Luis Peiro MD, Cristina Diaz de Heredia MD,Santiago Guindos MD,Josep Lloret MD,Vicente Martinez-Ibañez MD, Pediatric Surgery and Onco-Hematology Departments. Hospital Infantil Vall d´Hebron. Barcelona. Spain

Laparoscopic surgery has been adopted for the treatment of several pathologies in children. Laparoscopic splenectomy is considered a complex laparoscopic procedure; nevertheless, it is replacing the open technique in many hospitals.
Objective: To evaluate the results of laparoscopic splenectomy in a pediatric surgery department.

Material and methods: Thirty-five patients (between 2-16 years old) were splenectomized between june 1998 and december 2004, and their medical records reviewed. Twenty-eight of them underwent laparoscopic splenectomy (LS). The outcomes in this group were compared to the seven patients that underwent open splenectomies (OS).
Results: No differences were found between both groups regarding to age, gender or diagnosis. Hereditary spherocytosis was the diagnosis in 63% of the patients and immune thrombocytopenic purpura in 26%. Cholecystectomy was performed in 5 patients, all in the LS group. All LS were performed in the right lateral decubitus position with a four-ports approach. The mean operating time in the LS group was 190 minutes versus 124 in the OS group ($p<0.05$). The mean postoperative ileus was 27,8 in LS versus 42,8 hours in OS (NS), and the hospital stay 3,8 days versus 6,3, respectively ($p<0,01$). No differences were found between groups in the postoperative hematocrit. No differences were found in the recurrence rate of the disease between both groups. Five laparoscopic splenectomies (17,9%) were converted to open because of intraoperative complications. The complication rate was 10,7% in the LS, and 14,3% in the OS. No patient died.
Conclusions: Laparoscopic splenectomy is a safe technique, with results comparable to those of the open technique, a shorter hospital stay, and better cosmetic results. It has a steep learning curve.

P129 – Spleen/Solid Organ

REGRESSION OF HEPATIC FIBRONODULAR HYPERPLASTIC LESIONS AFTER LAPAROSCOPIC LIGATION OF A CONGENITAL EXTRAHEPATIC PORTOCAVAL SHUNT, Paul PHILIPPE MD, Elodie GAUTIEZ MD,Jean-Paul VAN NIEUWENHUYSE MD,Vincent LENS MD,Carine DEPREZ MD, Centre Hospitalier Luxembourg, Luxembourg and Centre Hospitalier Universitaire Brugmann, Bruxelles,Belgium

Aim:The role of vascular disturbances in the etiology of various hepatic neoplasia is well established. We report a rare case of congenital extrahepatic portocaval shunt, associated with multiple hepatic fibronodular hyperplasia lesions and their regression after laparoscopic ligation of the fistula.
Method: case report and analysis of the literature
Description: A 10 year old girl was investigated for chronic fatigue. Ordered because of abnormal liver function tests, an ultrasound scan demonstrated nodular lesions in segment 1 (65*36*68mm), V (55 mm diameter) and IV (12*18*19 mm). Portal Doppler exploration demonstrated a pseudocavernous transformation of the distal portal vein, with a direct communication between the proximal portal vein and the suprarenal vena cava. A good hepatopetal flow was nonetheless present. CT-guided biopsies of the main nodules were consistent with FNH. Percutaneous embolization could not be achieved because of the shortness of the communication.
The fistula was ligated laparoscopically with an uneventful postoperative course.
At one year, follow-up ultrasound and CT Scan document the disparition of all nodules but one, whose diameter has decreased from 55 to 20 mm.
The flow within the portal vein is hepatopetal, with a normal velocity, and there is no signs of portal hypertension.
Conclusions: Congenital Extrahepatic Portosystemic Shunts (CEPS) are rare anomalies. Side-to-side (type 2 shunts) are rarer. In this case, the well developed collaterals makes it closer to the type 2. Their frequent association with FNH, adenomas and even hepatoblastoma raises the question of the role of abnormal blood flow in the genesis of those tumors. This report of the regression of the nodules is a further argument, together with the risk of later encephalopathy or hepatopulmonary syndromes, to justify their closure, and laparoscopy offers an elegant way to do it.

P130 – Spleen/Solid Organ

A CASE WITH A PANCREATIC PSEUDOCYST AFTER LAPAROSCOPIC SPLENECTOMY, Jun Sakamoto PhD, Minoru Kuroiwa PhD,Makoto Suzuki MD,Norio Suzuki PhD,Yoshiaki Tuchida PhD, Gunma Children's Medical Centre

Introduction: We report a case with a pancreatic pseudocyst after laparoscopic splenectomy.
Case: A thirteen-year-old boy developed a splenic cyst presenting with abdominal pain in his left flank. Laparoscopic splenectomy (LS) was indicated. At the operation, we ligated the tissue between the pancreas tail and spleen three times before the resection with Endo-GIA. After the operation, he showed persistent abdominal free air, massive ascites with air fluid level and left pleural effusion. He was discharged on Day 26 after the operation. But on Day 33 after the operation, he suddenly complained of a severe abdominal pain and was readmitted with diagnosis of an acute pancreatitis. In the course of treatment, on Day 60 after the operation, a pancreatic pseudocyst behind the stomach connected to the pancreas tail was confirmed. He was treated conservatively because he was free from symptoms. The cyst disappeared after forty days since we first recognized it.
Discussion: LS is recommended recently comparing with open splenectomy because of its less invasiveness, shorter hospital stay and superiority in an aesthetic point of view. A few complications were reported so far and this is the first report describing a pancreatic pseudocyst after LS in an adolescent patient to the best of our knowledge. The cause of this complication might be due to inadequacy or insufficiency of the ligation of the pancreas tail region. We have to keep some severe complications in mind after LS as we experienced in this case.
Conclusion: Although most of the LS operations are carried out safely, we may encounter some severe complications at times. A pancreatic pseudocyst is one of such critical complications. This is the first report of a case with a pancreatic pseudocyst after LS in children.

P131 – Spleen/Solid Organ

EXPERIENCE WITH USE OF THREE-PORT TECHNIQUE FOR LAPAROSCOPIC SPLENECTOMY IN CHILDREN, Radhakrishnan Satheesan MD,Amir Szold MD,Peter S Midulla MD, Edward Shlasko MD, Division of Pediatric Surgery, Maimonides Medical Center, Brooklyn, NY 11219 and The Tel Aviv Sourasky Medical Center, Tel Aviv, IL

Laparoscopic splenectomy is traditionally performed using a four-trocar technique with a dedicated liver retracting port. We would like to present our experience with laparoscopic splenectomy in children using a three-port technique without using a dedicated liver retracting port.
Of 42 consecutive pediatric patients undergoing splenectomy during the period June 2000 to September 2004, 32 had their splenectomy done using a three-port technique. The average age of the patients was 12.4 years. The average time of operation was shorter in those laparoscopic splenectomies using three rather than four trocars (86 vs. 121 minutes). The average weight of the spleen (212 vs. 260 gm) was not significantly different. The length of postoperative stay was 2.23 days in the three-port group versus 4.77 days in the four-port group.
The most common indication for surgery was ITP (27pts - 64%), followed by heriditary spherocytosis (7pts - 16%), epidermal cyst (3pts - 7%), thallasemia major (2pts - 5%), sickle-cell anemia (1pt - 2%), autoimmune hemolytic anemia (1pt - 2%) and splenic abscess (1pt - 2%). There were three complications. One patient developed a post-operative hematoma, one patient developed pancreatitis, and one patient (whose indication for surgery was a salmonella splenic abscess) developed a post-operative sub-phrenic collection.
We reaffirm that laparoscopic splenectomy can be done safely and effectively in the pediatric population. Using only three ports does not compromise the patient's safety or the operative time, while improving pain, recovery time, and cosmesis.

P132 – Spleen/Solid Organ

LAPAROSCOPIC CHOLECYSTECTOMY IN CHILDREN: 7 YEARS MULTICENTRIC EXPERIENCE, Juan P Valdivieso MD, Monica Contador MD,Ricardo Ibanez MD,Ivan Alcoholado MD,Cecilia Briones MD,Antonieta Ramirez MD,Juan C Olivares MD, Hospital Roberto del Rio, Clinica Davila y Hospital Clinico Universidad de Chile. Santiago, Chile

Purpose: The high incidence of non-hemolytic gallbladder stones in our country (up to 20%) provides a significant number of pediatric patients with this disorder. We report our experience with Laparoscopic Cholecystectomy (LC) in children.
Materials and Methods: Retrospective review of 92 patients that underwent LC from January 1998 to January 2005. Epidemiological data, symptoms, imaging studies, duration of operation, conversion rate, complications, time to enteral feeding, use of pain medication, hospital stay and pathology reports were analyzed. Preoperative ultrasonography (US) was obtained in all cases. Four trocars, 10 or 5mm 0º optic lens and 12-15mm Hg pneumoperitoneum was used in most cases.

Results: Demographics data were: (M:F=32:60), median age: 139 months (8-216) and median weight: 43.75 kg (7,6-78.5). 10 patients had Familiar Microspherocytosis (6 of them with simultaneous splenectomy). Another 2 patients had hemolytic anemia of unknown cause. Comparing hemolytic with non-hemolytic patients we just found a significant diference in weight (34 v/s 48.5 kg) with no diference in age. US revealed stones in 89 children (3 of them with signs of acute cholecystitis (AC)). Clinical symptoms of AC were present in 5 patients and 3 had symptomatic vesicular polyps. There were 4 conversions (4.3%). The reasons to convert were: bile duct section (a 9 years old patient with Mirizzi Syndrome); bleeding (one patient without transfusion); one patient with poorly defined anatomy and one with multiple adhesions. Mean operative time was 117 min (40-245) in cholecystectomy alone, 174 min (90-280) in AC, and 212 min (180-250) in the converted group. Surgical complications included the bile duct section with primary end to end repair, bleeding in 2 patients, and 10 gallbladder disruption with mild bile leak. Oral intake started at a mean of 14 hours. Most patients received postoperative analgesia for 24hrs and were discharged the next day. Pathology reports confirmed chronic cholecystitis and cholelithiasis in 80 cases, acut cholecystitis in 9 and 3 patients with benign polyps. Follow up was uneventful in all patients.
Conclusions: Our experience with laparoscopic cholecystectomy includes mostly non hemolytic patients. These results with low morbidity rate and short hospital stay confirms that this technique is safe and effective in children

P133 – Spleen/Solid Organ

IS EN BLOC STAPLING OF SPLENIC HILUM IN LAPAROSCOPIC SPLENECTOMY SAFE?, Gulnur Gollu MD,Hulya Ozkan-Ulu MD,Rahsan Vargun MD,Suat Fitoz MD,Ismail H Gokcora MD, Aydin Yagmurlu MD, Department of Pediatric Surgery and Radiology, Ankara University School of Medicine

Laparoscopic splenectomy has gained increasing acceptance in the surgical management of a variety of hematologic disorders. Most investigators use vascular staplers or clips for sectioning of the splenic artery and vein. However, there are some concerns about the possible arterio-venous fistula formation related to stapler usage. Hence this study was aimed to evaluate the development of arteriovenous fistula in a series of 11 consecutive children who underwent laparoscopic splenectomy.
The indications were; hereditary spherocytosis (n=2), idiopathic thrombocytopenic purpura (n=3), Thalassemia (n=2), sickle cell disease (n=2), acute myeloblastic leukemia (n=1) and Ewans? syndrome (n=1). A routine four trocar technique was used in all patients. Vascular isolation was achieved with an Endo-GIA (powered vascular linear stapler). Doppler ultrasonographic evaluation was performed in all patients one year after the operation. There were no arteriovenous fistula formations related to the previous operation with a mean follow-up of 1.5 years (12 ? 22 months).
Although limited with the small number of the series, no cases of arteriovenous fistula development occurred after en bloc stapling of the splenic hilum in pediatric laparoscopic splenectomy. In conclusion, the preliminary data suggest that, en-bloc stapling can thus safely be performed in pediatric laparoscopic splenectomy with no related short-term vascular complications.

P134 – Thoracoscopy

THORACOSCOPIC RIGHT MIDDLE LOBECTOMY FOR HYDATID CYST, Saad I ALMULHIM MD, Sami I ALMAJED MD,Medhat Bukhari MD, Saudi Aramco hospital

thoracoscopic lung resection is an established procedure in adult and pediatric surgery. totally thoracoscopic lobectomy for hydatid cyst has not yet been reported in medline english litrature. we present this case as case of right middle lobe hydatid cyst removed thoracoscopically. We hight the technique and specific precations pertenant to hydatid disease. Our patient is a 17 year old boy presented with cough, fever, and chest pain that eventually progresed to septic shock. he was resuscitated, intubated and treated with antibiotics and pressors. his chest x-rays showed a right middle lobe cyst. his CT scan suspected a hydatid cyst for which he recieved Albendazol. 2 weeks after extubation and 3 weeks of Albendazol a right middle lobectomy including the hydatid cyst was done succefully. We used three 5mm working ports and two 12mm ports to be able to use the staplers. Harmonic scalpel and staplers used for the dissection. No intraoperative spillage occurred. 14% hypertonic saline solution was availabe on the table as a precaution. the speciemen was extracted in 10mm endocatch bag via the 12mm port. He was discharged four days postoperatively. follow up three months later with chest x-rays show no evidence of recurrence.
thoracoscopic lobectomy or segmentectomy for hydatid cyst can be done safely, preferrably after medical treatment with Albendazol. intraoperative precautions to avoid and treat leakage should be taken.
(photos and short video will be shown)

P135 – Thoracoscopy

THORACOSCOPIC PROCEDURES IN PEDIATRICS: SAFETY AND FEASIBILITY, Tariq Altokhais MD, Aayed R Alqahtani, College of medicine & King Khalid university Hospital, Riyadh, Saudi Arabia

Objectives:
the purpose of this study is to evaluate the feasibility, safety, and efficacy of performing thoracoscopic procedures in infants and children.
Methods:
A retrospective review of all pediatric patients who underwent thoracoscopic surgery over a period of two years.
Results:
During a period of two years, 35 patients underwent thoracoscopic procedures. The indications include , empyema in 12 patients, congenital lung lesions in 6, tracheo-esophageal fistula in 6, lung biopsy in 6, spontaneous recurrent pneumothorax in 2, diaphragmatic evetration in 2 , and hydatid lung cyst in one patient. All but one procedure were completed thoracoscopically. The conversion was in a neonate with a long gap (isolated) esophageal atresia. There were no intra-operative or post-operative morbidities. One infant died postoperatively as a result of a missed tension pneumothorax on the opposite side secondary to barotraumas.
Conclusion:
It is technically feasible to perform thoracoscopic approach in different types of pediatric pathologies. This procedure proves to be safe and efficacious. It provides the advantage of avoiding thoracotomy in addition to the excellent exposure in most of the procedures.

P136 – Thoracoscopy

MINI-INVASIVE LOBECTOMY IN INFANTS AND CHILDREN, Francisco José Berchi-Garcia PhD, Indalecio Cano MD,Juan Anton-Pacheco MD,Aracelis Garcia MD,Maria Lopez MD,Maribel Benavent MD, HUMI 12 de Octubre, Madrid/Spain

Aim of study: While many thoracoscopic procedures in children such as Lung Biopsy have become common place,many advances procedures are still in question.This study evaluates the safety and efficacy of thoracoscopic Lobectomy in Infants and Children. Methods: From January 2000 to Nov.2004 ten patients underwent Video assisted thoracoscopic lobe resection.Ages ranged from 5 weeks to 13 years and weight from 3,8 to 78kg.Preoperative diagnosis included sequestration,congenital adenomatoid malformations(8)and severe bronchiectasis(2).The initial procedures were performed with a combination of standard thoracic and endoscopic instruments,through a mini thoracotomy and 2 to 3 endoscopic ports.Later procedures were performed completely through 3 to 5 valved throcars with no mini-thoracotomy. Main Results:7 of 10 procedures were completed thoracoscopically.Operative times ranged from 35 min. to 3 hours.There were 1 upper,1middle and 8 lower lobe resections.There were 1 intraoperative complication(bleeding).Chesttubes were left in 9 of 10 procedures for 1 to 3 days.Hospital state ranged from 1 to 5 days(avg.2.4).1 Patient developed pneumothorax and postoperative day 5, but this resolved with tube thoracostomy alone.No patient required blood transfusion. Conclusion:Thoracoscopic Lung resection is a save and efficacious technique.It avoids the inherent morbidity of a mayor thoracotomy incision and is associated with the same decrease in postoperative pain, recovery and hospital stay as seen in minimally invasive procedures.

P137 – Thoracoscopy

VATS AS AN ADJUNCTIVE TOOL IN THE MANAGEMENT OF CONGENITAL ARTERIOVENOUS MALFORMATION OF THE CHEST WALL, B. Haluck Guvenc MD, Deniz I CEK MD,Tonguc Isken MD, Kocaeli University, School of Medicine, Dept. of Pediatric Surgery, Dept. of Plastic & Reconstructive Surgery, Kocaeli, Turkey

Introduction: Congenital arteriovenous malformation (AVM) of the chest wall is a rarely encountered lesion. It is considered as a challenging problem because of the complexity associated with the treatment of these

rare tumors. Angiography is indicated to show the exact angioarchitecture in high-flow and combined-flow lesions. Preoperative embolization may also be recommended prior to surgical intervention, because of the increased risk of massive bleeding and/or disseminated intravascular clotting.
Methods / Procedure: An eleven year old female, suffering from congenital AVM of the left chest wall is presented. The lesion had been progressively expanding over a period of 5 years, despite a series of selective embolizations. Patient had a high-flow murmur medial to the inferior margin of the scapula. Erosion was detected in the neighboring costal margins. Angiography revealed multiple tortuous feeding vessels branching from the intercostal arteries. Initial stage of the operation consisted a thoracoscopic examination, ligation and/or cauterization of intercostals vessels. Numerous coils owing to prior embolizations were observed within the tortuous vessels outlining the margins of the lesion. The second stage was a meticulous transcutaneus resection of tumor followed by a limited thoracotomy under video assistance. The second stage was complicated with massive bleeding from a ruptured draining vein, containing an embolizing coil. The patient is free of recurrence after a follow-up period of almost 2 years.
Conclusion: The complexity associated with the treatment of AVM is well demonstrated in our case. We believe that videoasisted thoracic approach is a useful adjunctive tool along with angiography and selective embolization in treating chest wall AVM.

P138 – Thoracoscopy

CHANGING OF BREATH MECHANIC DURING THE VIDEOTORACOSKOPIC OPERATIONS IN CHILDREN WITH EMPYEMA, Vladimir Makushkin DO, Svetlana Ishkova DO, Vladimir Alyangin DO, Bashkir State Medical University

The aim of this research was to study the changing of breathing mechanics before and after videotoracoskopic operations (VTO) in children with empyema, in order to determine the correlation of breathing mechanics with gas exchanging, disease onset and to establish the indications to the second operation.
Materials and methods. Forty-seven children 1,5 ? 14 years old with empyema were included in this study. There were the following VTO: pleurolysis, decortication of lungs, pleural cavity sanitation. According to the disease onset all patients were divided into two groups. In the first group (25 children) operation performed in the period of time less than 8 days after disease onset, in the second group (22 children) ? over than 8 days. During the operations the following indexes were tested: PaO2, PaCO2, SpO2, CI, UPSS. Registration of breathing mechanics indexes: expire volume (VÔ), maximal inspiration pressure (Dpeak), mean pressure of airways (Dmean), pressure in the end of expiration (DÅÅD) were registered with respirator. Lung distensibility (C) was also calculated. One lung ventilation was used in all cases. Double-lumen intubation's tubes ?Carlens? were used in patients elder than 11 years.
Results. Examined indexes (Dpeak, Dmean, C) in the affected lung showed changing of breathing mechanics in all patients. In the first group at the end of VTO we determined increase C on 36,6% (d<0,05) and decrease Dpeak on 11,5% (d<0,05), at the post operation period DàÎ2 increased on 15,7% (d<0,05) beside initial data. In the second group at the end of VTO Dmean and C indexes did not change, Dpeak increased on 11,2 % (d<0,05). Gas exchanging indexes at the post operation period did not distinguish beside initial data. Correlation analysis showed strong correlation of lung-thoracic compliance with time of disease presentation (days) (R=0,96) and DàÎ2 index (R=0,92).
Conclusion. Children with empyema with delayed operation did not have positive dynamic of breathing mechanics at the end of VTO and improving of aeration at the early post operation period. For the correction of situation and improving quality of life, there were indications for second operations (10 children, 45%).

P139 – Thoracoscopy

THORACOSCOPIC SURGERY IN NEONATES: EXPERIENCE FROM SIBERIA, Yuri A Kozlov MD, Vladimir A Novogilov MD,Pavel S Yurkov MD,Natalja G Aleinikova, Department of Newborn Surgery, Pediatric Hospital, Irkutsk, Russia

Introduction. Thoracoscopy was used in children in 1970 as diagnostic with modified cystoscopy equipment. The endoscopic instrumentation and surgical strategies were adapted to accommodate the small size of neonatal population. We reviewed all patients in our centre who had thoracoscopy for congenital disease during the newborn period.
Methods and Procedures. From January 2002 to November 2004, 20 patients, ages 2 day to 28 days, underwent thoracoscopic surgery at our institution. There were 15 boys and 5 girls. The weight ranged between 800 - 3400 g. The technique of VATS was performed in premature infants -12 patients. The spectrum of pathology included esophageal atresia - 3, patent ductus arteriosus - 14, tracheomalacia - 1, left congenital diaphragmatic hernia - 1, atrioventricular septal defect - 1. We used three small 5-mm thoracostomy (a camera port and 2 working ports) in each case: 3 - in the right hemithorax, 17 - in the left hemithorax. All operation were performed with classical thoracoscopic approach: transpleural termino-terminal esophageal anastomosis, clipping of patent ductus arteriosus, aortopericardiosternopexy, suturing of diaphragmatic defect, pulmonary artery banding with using Gore-Tex material. A routine chest radiograph was obtained on the intensive care unit and pleural suction catheter was removed on 1 post-operative day.
Results. There were no procedure-related complications. We had no esophageal leak, hemorrhage and residual ductal patency. The operating time was 20 min. - 3 h. 50 min. There were one contralateral conversion by patient with TOF and vascular abnormality: unexpected right sided aorta and double aortic arch. The reason for this conversion was inadequate visualitation. Patients were discharged between day 7 and 64.
Conclusion. Thoracoscopy is a safe and effective alternative to open thoracotomy for treatment of wide congenital pathology in the newborn period. Potential benefits include precise dissection of intrathoracic structures, reduction of post-operative pain, hospital stay and excellent cosmetic results. It should not be attempted without training and should be carried out only in specialized medical centers and by surgeons with experience with open procedures.

P140 – Thoracoscopy

VIDEO-ASSISTED SURGERY OF THORAX IN PAEDIATRIC ONCOLOGY., Przemyslaw Mankowski MD, Andrzej Jankowski MD,Pawel Juszczak MD, Dept. of Paediatric Surgery, Traumatology and Urology,

Purpose: The aim of the work is to estimate the usefulness of mini ? invasive surgery assisted with videoscopy technique in diagnosing and treatment of oncological diseases of thorax in children.
Material and methods: There were 79 thoracoscopic procedures performed in 56 children treated with oncological diseases in Dept. of Paediatric Surgery in Poznan between March 1998 and July 2004. The average age of patient was 10.8 years and the Body Mass Index (BMI) was 18.1.
In 49 cases the diagnostic biopsies were only performed and in 30, the videoscopy technique was used in order to remove the selected chest tumors. The thoracoscopic method was useful in operating of 46 patients and the open mini ? invasive surgery with help of video technique (VATS) was performed in 33 children. The invasive propensity (CRP, IL-6, time of hospitalization, etc.) and usefulness of videoscopy in paediatric oncology were analysed.
Results: According to our experience, we can ascertain that the videothoracoscopic method allows to perform many kinds of diagnostic and threrapeutic procedures in children as well as wide inspection of pleural cavity and mediastinum with minimal operative trauma. There were no post-operative significant complications observed in any patient. The operation results and the post-operative courses were satisfactory and did not negatively caused the treatment of main diseases.

P141 – Thoracoscopy

THORACOSCOPIC GUIDED PLEURAL BIOPSY AS AN AID TO DIAGNOSIS OF PAEDIATRIC TB, Elizabeth J McLeod MD, David Armstrong MD,Christine Pesti, Departments of Surgery and Respiratory Medicine, Monash University, Melbourne, Australia

Tuberculosis (TB) has an incidence of 5:100 000 new cases in Australia, and approximately 20%of children with pulmonary TB develop tuberculous pleuritis. Pleural biopsy performed by either needle or thoracoscopically guided methods has been the mainstay of diagnosis in adults and has a sensitivity of 87% provided that at least two pleural specimens are obtained. However, confirming the diagnosis of TB prior to treatment with multi-agent therapy is difficult to achieve in the paediatric population, as children have a much lower burden of tubercle bacilli compared to adults, and seldom produce sputum. Commencement of multi-agent therapy in children is not recommended on the basis of positive Mantoux alone. Minimal data exist regarding the use of pleural biopsy in children.

We present three cases of tuberculosis with pleural involvement in which thoracoscopic pleural biopsy was pivotal in establishing a diagnosis. In all three cases the Mantoux skin test was positive (>5mm induration), however there was no recent history of contact with TB in any case. Moreover, previous culure and AFB staining of pleural fluid had been negative. At thoracoscopy, large specimens of affected pleura were obtained and drainage of effusion and placement of thoracostomy tubes under vision was undertaken. Histology of pleural specimens was consistent wth TB in 2 cases, and culture and drug sensitivities were confirmed for all three cases. All three children had an excellent clinical and radiological response to anti-tuberculous treatment.
For children with large tuberculous pleural effusions, who require general anaesthesia for invasive procedures, we suggest that thoracoscopy with direct visualization and targeted biopsy of tuberculous nodules is the investigation of choice.

P142 – Thoracoscopy

TREATMENT OF WOUND SEROMA, A RARE COMPLICATION OF NUSS PROCEDURE, Antonio Messineo MD, Enrico Ciardini MD,Alessandra Martin MD, Childrens Hospital "A. Meyer", Florence

In many institutions, the NUSS operation (NO) has rapidly become the procedure of choice for correction of pectus excavatum (PE) because it is associated with small and lateral skin incision, shorter operation time, minimal blood loss, and early return to full activity. At the same time, an increasing surgeons? number have reported complications with NO. The aim of this study was to present a particular complication we observed with such technique.
The original NO describes the routine use of lateral stabilizers (device's dimension 60 by 16 mm, maximum thickness of 5mm) to minimize the risk of bar displacement after operation. Recently Nuss has recommended the use of only one stabilizer in children with PE; such device, however, could create problems in slender subjects as the ones with PE. Only a previous study indicated that the use of a lateral stabilizer increases the incidence of seroma with dermatitis due to pressure damage.
In our first 15 cases we experienced, a month after a uneventful NO, a case of bilateral seroma in a slender adolescent in which 2 stabilizer were used. We treated the infections with simple drainage and parenteral antibiotics, followed by oral antibiotics given at low dosage for six months. We obtained the complete wound's healing; at difference from other reports removal of the stabilizer was no necessary.
From this single experience we recommend to use one lateral stabilizer only in severe PE in which stabilizer is necessary to impede bar displacement. Furthermore, in all slender patients, wire stabilizer should be used as first choice device to avoid bar displacement. When stabilizer is used, a long-term preventive antibiotics treatment should be utilized to avoid seroma formation. Removal of stabilizer should be reserved to cases in which infection does not recede.

P143 – Thoracoscopy

FIBRINOLYTIC SALVAGE THERAPY FOR POSTOPERATIVE RECURRENT PARAPNEUMONIC EFFUSION IN COMPLEX PEDIATRIC EMPYEMA, Jeffrey C Pence MD, Kim G Mendelson MD,Laurie A Driscoll, Brody School of Medicine at East Carolina University, Greenville, NC, USA

The effectiveness of video-assisted thoracoscopic surgery (VATS) in the treatment of complex pediatric empyema is dependent upon the adequacy of drainage of the affected pleural space. This retrospective study reviewed a multi-institutional population of 50 children undergoing VATS for the treatment of fibrinopurulent empyema during a ten year period ending in 2004. Five patients (10%) were identified as demonstrating inadequate postoperative drainage, as defined by tube thoracostomy output of less than 1 mL/Kg/d within the initial two postoperative days coupled with radiographic evidence of recurrent parapneumonic effusion. As salvage therapy, the postoperative instillation of fibrinolytic (250,000 Units urokinase or streptokinase/50 mL sterile normal saline instilled for four hours) was performed on the second to fourth postoperative days. One to three instillations resulted in an acute mean drainage volume of 13.6 mL/Kg/d. Concomitant radiographs documented complete and durable resolution of all recurrent effusions. Postoperative outcomes, including ventilator requirements, resolution of pyrexia, and length of hospital stay, were not significantly altered by this intervention when compared to the general study population. Complications, including bronchopleural fistula and acute hemorrhagic complications, were not observed. In summary, salvage fibrinolytic therapy following VATS may offer a safe alternative treatment for recurrent postoperative parapneumonic effusion, thereby precluding further invasive or reoperative strategies. Additionally, these data would suggest routine perioperative fibrinolytic utilization may improve the efficacy of VATS-based treatment protocols for complicated pediatric empyema.

P144 – Thoracoscopy

THORACOSCOPIC RESECTION OF ESOPHAGEAL DUPLICATION IN CHILDREN:REPORT OF TWO CASES, Lena Perger MD,Robert Weinsheimer MD, Georges Azzie MD, Libby Watch MD, Children's hospital of New Mexico,University of New Mexico

Esophageal duplication is a rare developmental abnormality.Complete excision is the treatment of choice.A thoracoscopic approach is preferred to open thoracotomy because of lower peri-operative morbidity,better patient comfort and shorter hospital stay.
We report two cases of esophageal duplication cysts resected via a thoracoscopic approach.
Both patients had succesful thoracoscopic excision.They were discharged on post-operative day 2 and 4 respectively. They have made uneventful recoveries and are completely asymptomatic at follow-up.
Thoracoscopic resection of esophageal duplications is feasible and safe. Complete excision is possible even if the cyst shares a common muscular wall with the eosphagus. To avoid esophageal injury/perforation,it is useful to perform the dissection under endoscopic supervision.

P145 – Thoracoscopy

THE "NUSS PROCEDURE". OUR EXPERIENCE OF MINIMALLY INVASIVE REPAIR OF PECTUS EXCAVATUM., Akihiro Shimotakahara PhD, Manabu Okawada MD,Tadaharu Okazaki PhD,Geoffrey J Lane PhD,Atsuyuki Yamataka PhD,Shiori Kawasaki PhD,Atsushi Amano PhD,Takeshi Miyano PhD, Department of Pediatric General and Urogenital Surgery, Department of Cardiovascular Surgery, Juntendo University School of Medicine

Purpose: To assess our experience of the Nuss procedure (minimally invasive repair of pectus excavatum, or, MIRPE).
Methods & Procedures: We retrospectively reviewed the medical records of MIRPE cases treated at our institution from 1999 - 2004. Initially, MIRPE was performed by several surgeons, but later on, by a specialized team.
Results: Twenty-six cases of MIRPE (20 male and 6 female) were treated. Preoperative Haller?fs index was 6.4 ?} 3.1. Age at bar insertion was 8.0 ?} 3.3 years old and operative time was 88.57 ?} 27.1 minutes. Follow up was 2.4 ?} 1.7 years. Bar removal was performed in 14 cases and sometimes complicated by excessive costal bone formation. Cosmetic results were excellent (21) and good (5). Postoperative complications requiring intervention were only seen initially (1 recurrence secondary to bar dispostion, 3 infections, and 1 wire snapping secondary to metal fatigue). Outcome was improved through: routine use of antibiotics, routine use of right-sided thoracoscopy, sliding the introducer parallel to the sternum, inserting the flat surface of the bar to face the sternum, 3 point bar fixation, routine use of a stabilizer connected to the bar with screws, suturing the stabilizer and fascia before connecting the bar, water seal procedure, intraoperative X-ray to confirm pneumothorax, pain control with patient-controlled anesthetic device, establishing a specialized team including a cardiothoracic surgeon, standardizing pre-/post-operative management, and shortening the duration of bar insertion.
Conclusion: Organization of a specialized team and minor technical improvements have improved outcome in MIRPE cases.

P146 – Thoracoscopy

THORACOSCOPIC THYMECTOMY IN CHILDREN, Michael Hoellwarth MD, Lutz Stroedter MD, Brigitte Messerer * MD,Juergen Schleef ** MD, Medical University Graz, Dept. of Paediatric Surgery, Auenbrugger Platz 34, A-8036 Graz *Medical University Graz, Dept. of Anaesthesiology, **Ospedale Infantile e Pie, Istituto per l'Infanzia, via dell'Istra 65/1, Trieste, Italy

Introduction:
Myasthenia gravis in children is rare. Medical treatment and thymectomie are parts of the treatment protokoll. The classical surgical approach to the thymus is through a medial sternotomy but minimal access surgery is in increasing use for this purpose. Nevertheless the experience in pediatric surgical departments is limited. We report of two cases with a left sided thoracoscopic approach.

Material and Method:
Two patients (11y and 15y) with myasthenia gravis showed up with increased ACHR-Antibody levels under Pyridostigmin (Mestinon) therapy. The indication for thymectomy was given and anaesthesia was applied without the use of muscle relaxants and with continuation of the Pyridostigmin therapy. No single lung intubation was needed. The patients were positioned 45° oblique to the right side. In one case the AESOP robotic system was used for assistance. The Thymus was mobilized from caudal to cranial. Vessels were ligated with clips. Operation time was approx. 2,5 hours in both cases.
Results:
The postoperative course was uneventful and the patients were discharged after 3 days. Medical treatment was reduced and the score for Myasthenia gravis was 0 after 2 month
Conclusion:
Thoracoscopic thymectomy is a safe alternative approach to open surgical procedures in children with Myasthenia gravis.

P147 – Thoracoscopy

NEUROGENIC MEDIASTINAL TUMOR REMOVAL BY THORACOSCOPY 7 CASES, Jean stephane VALLA MD, Michel M LECLAIR MD, Yves M HELOURY MD, Henri M STEYAERT MD, Fondation LENVAL Pediatric Surgery

Thoracoscopic surgery is an accepted technique to remove cystic mediastinal mass in children, but it could also be used to remove selected solid neurogenic tumor: the obvious bulky malignant neoplasm was a contreindication. The aim of thoracoscopic resection is to ensure the same complete resection of the neoplasm as with open thoracotomy and to reduce approach related morbidity.
TECHNIQUE: A good exposure of mediastinal structures could be achieved by using a double lumen endo tracheal tube or bronchial blockers or CO2 insufflation.
The use of ultrasonically actived devices is useful. An endobag is mandatory for avoiding tumor spillage during extraction.
MATERIALS: 7 cases, 6 months to 15 years. Four patients were asymptomatic, 3 suffered of intercostal pain. The tumoral localisation was as following: upper part 3 cases, middle part 3 cases, lower part 1 case, no true dumbbel tumor.
The tumor size was between 3 and 8 CM. on histological examination 3 cases proved to be ganglioneuromas, 2 case ganglioneuroblastomas, 2 neuroblastomas.
RESULTS: tumor resection was macroscopically complete in all case. No peroperative complication except one dura injury, no conversion. The postoperative period was short (mean 4 days). 3 patients presented a postoperative HORNER syndrom , 2 patients suffered of persistent intercostal pain and anesthesia. There were no recurrence (median follow-up 3 years).
DISCUSSION: Despite short number and short follow-up, the preleminary results are encouraging. One extra advantage of thoracoscopic approach is probably to reduce late post resectionnal disorder during growth, like thoracic asymetry, scapular mobility restriction, spinal deformities including kyphosis and scoliosis.
The presentation is illustrated with a video.

P148 – Thoracoscopy

THORACOSCOPIC APPROACH FOR CONGENITAL CYSTIC LUNG DISEASE IN PEDIATRIC PATIENTS, Ricardo Villalpando C PhD, Edgar Morales- Juvera PhD,Gabriel Reyes G. PhD, Hospital of Pediatrics, National Medical Center, XXI, IMSS

The Congenital Lung disease could be grouped in for categories, lobar emphysema, pulmonary sequestration, cystic adenomatoid malformation and bronchogenic cyst. The symptoms include, respiratory distress, cough, stridor, recurrent pulmonary infections, hemoptysis, dysphasia, pneumothorax, or life threatening event with respiratory failure.
The surgical treatments depends on the kind of lesion include enucleation of the lesion, segmental resection, lobectomy, bilobectomy or total pneumonectomy.
We report our experience in 8 patients with ages raging from 2 weeks to 4 years old. All patients did well, with out an increase of the morbidity or mortality to the patient.
We also think that thoracoscopy should be attempt in all the stable patients with congenital thoracic disease.

P149 – Thoracoscopy

THORACOSCOPY (VATS) IN PEDIATRIC CHYLOTHORAX, J Waldschmidt PhD, H Giest MD,L Meyer-Junghänel MD, St. Joseph Childrens Hospital, Berlin, Germany

Introduction: The therapeutic management of children with persistent chylothorax is one of the most challenging problems in pediatric thoracic diseases. The surgeon is an important member of the team treating these children. The therapeutic procedure depends on the etiology of the pleural effusion and the age of the child.
Patients: In a ten years period five children with chylothorax, aged 1 to 14 years, underwent VATS. The etiology of the effusion was posttraumatic in 3 cases, Gorham-Stout-disease and idiopathic in the other two infants.
Methods: Three point standard thoracoscopy in lateral position, general anesthesia, artificial Pneumothorax with 5 to 8 mm Hg. Closure of the leaks was performed by suture or clip and by laser using the NdYAG laser 1064 nm with 0.6 mm bare fiber, 30 watt, non contact technique. In two cases additional sealing by fibrin glue was used. The leaks of the thoracic duct were visualized by preoperative oral administration of cream.
Results and discussion: In all five children the leaking thoracic duct could be located and successfully sealed. In three children it was found on the left side cranially, in two children on the right. The tube for drainage of the pleural space could be removed on the following or second day. No recurrences occurred.
Keywords: chylothorax, thoracoscopy, NdYAG laser

P150

APPLICATION OF LASER TECHNOLOGIES IN LAPAROSCOPIC SURGERIES IN CHILDREN, L.M .Roshal, A.V. Bryantsev, V.A. Kapustin, V.P. Minaev, V.S. Gvozdikov, Clinical and Research Institute of Emergency Children's Surgery and Trauma (Moscow, Russia), Firm "IRE-Poljus" (Moscow, Russia)

The aim of the present work is to study a possibility to use laser energy with the wavelength 0,97 mkm in laparoscopic surgeries in children.

Laser surgical device "LS-0,97-IRE-Poljus" with powerful semiconductor diodes was used. Laser enrgy was delivered via a flexible optic fiber. The laser device has small size; it has low powers. At the same time it is highly reliable and easy to handle. Maximal output power at the distal end of the lightguide is 30 Wt. All these parameters make it possible to apply this device in many laparoscopic surgeries. Laser energy with 0,97 mkm wavelength is well absorbed by hydrophilic tissues and tissues richly saturated with blood because the local absorption maximum takes place in water and oxyhemoglobin. It gives a good hemostatic effect while the depth of damaging penetration is less.

700 laparoscopic surgeries have been performed by us with semiconductor laser energy for the last three years. The majority of them were done in destructive forms of acute appendicitis (including those with the complicated peritonitis). We also treated pathologies of female genitalia (ovarian cysts, hydatides of the uterine adnexies, etc.) as well as pathologies of the great omentum (a cyst of the great omentum, cyst torsion) and adhesive processes in the abdominal cavity of various origin.

Laser energy scalpel was used in laparoscopic appendectomy for treating the appendix mesentery, for cutting adhesions and for cutting the appendix. A principally important technical moment is an obligatory compression of the appendix mesentery before its cutting with laser scalpel because of the risk of bleeding. The same moment must be observed in other surgical interventions such as coagulation, incision of vascular lesions.

Intraoperative complications (bleeding from the mesentery artery) were seen in 7 patients at early stages of this technique development. Postoperative course in all children was smooth; recovery took place within normal limits.

Thus, laser light with the wavelength 0.97 mkm gives good hemostatic, dissective and bactericidial effects due to its specific interaction with biological tissues. It also reduces time of surgical intervention thus, opening wide possibilities for applying laser light scalpel in endoscopic surgeries in children.

P151

LAPAROSCOPIC APPENDECTOMY IN TREATING APPENDICULAR PERITONITIS IN CHILDREN, V.A. Kapustin, A.V. Bryantsev, O.V. Karaseva, Clinical and Research Institute of Emergency Children's Surgery and Trauma (Moscow, Russia)

For the last 12 years laparoscopic appendectomy has been done in 4020 children aged 2-16 admitted to our hospital. 557 (13,9%) out of these surgeries had various forms of appendicular peritonitis. We apply laparoscopic appendectomy in the majority of our children-patients (95%).

The technique of laparoscopic appendectomy in case of peritonitis consisted of five stages: 1 - diagnostic laparoscopy; 2 - primary abdominal sanation; 3 - laparoscopic appendectomy; 4 - final sanation of the abdominal cavity; 5 - drainage of the abdominal cavity.

The conventional antibactericidial, antiparetic, symptomatic and antiadhesive therapy was prescribed in the postoperative period.

Postoperative course in children operated with laparoscopic technique was more favourable: less pain syndrome and less postoperative intestinal paresis. The number of postoperative intraabdominal complications and wound complications became less from 15,6% to 5% and from 9,3% to 1,5%, correspondingly.

Our experience of using laparoscopic techniques for treating acute appendicitis complicated with peritonitis allows us to use them in practically all forms of complicated appendicitis. Contraindications for laparoscopic treatment of appendicular peritonitis are: preoperative syndrome of the intestinal insufficiency of the 3rd degree and the appendicular abscess located under the front abdominal wall and in the pelvis.

Comparative results of treating complicated forms of acute appendicitis in children obtained during many years have evidently demonstrated advantages of laparoscopic approaches comparing to conventional ones when the open approach is used. Little traumatisation of both the surgical approach and manipulations in the abdominal cavity, good visual control at all surgical stages and high level of instrumental and technical equipment evidently advocate for laparoscopic techniques being used for treating complicated acute appendicitis in children.

V001

TOTALLY STAPLED LAPAROSCOPIC ROUX-EN-Y GASTRIC BYPASS: PEARLS AND PITFALLS, John M Morton MD, Sanjeev Dutta MD, Craig T Albanese MD, Lucile Packard Children's Hospital, Stanford University

A worldwide epidemic of morbid obesity exists among adolescents. An effective and enduring therapy for this condition exists with Roux-en-Y gastric bypass (RNYGB). Several operative approaches exist for RNYGB. Our technique of totally stapled laparoscopic RNYGB is comprised of the following six key steps: 1) appropriate port placement, 2) ample jejunal mesenteric division, 3) wide jejunojejunal anastomosis, 4) antecolic omental split, 5) gastric pouch formation utilizing the 25mm EEA anvil as a sizer, and 6) gastrojejunal anastomosis using transabdominally placed 25 mm EEA stapler. The advantages of a totally stapled approach include: 1) ease of gastrojejunal anastomosis as compared to handsewn, 2) consistent gastrojejunal stoma size, 3) reduced stricture rate using 25 mm EEA as compared to 21 mm EEA used in transoral approach, and 4) shielded transabdominal passage of EEA stapler to reduce wound infections. Potential pitfalls of this approach include: 1) staple line bleeding, 2) stapler misfire, 3) larger port to facilitate passage of 25 mm EEA, and 4) additional gastrotomy for placement of anvil.

V002

LAPAROSCOPIC ADJUSTABLE GASTRIC BANDING IN TEENAGERS: LESS IS BETTER, Atul K Madan MD,Craig A Ternovits MD,David S Tichansky MD, Thom E Lobe MD, Minimally Invasive Surgery Section, Department of Surgery, University of Tennessee, Memphis

Laparoscopic adjustable gastric banding offers a relatively low-risk surgical option for the treatment of morbid obesity in teenagers. This video demonstrates a simple technique of Lap-Band placement with minimal dissection.
As shown in the video, we first bluntly create a space left of the gastroesophageal junction. The attachments of the stomach to the diaphragm are left alone to help hold the band in place. Then, the area of pars flacida is opened up bluntly with a grasper. Minimal dissection is needed for this dissection. The reticulating dissector is placed underneath the stomach and brought up the initial space that was created.
The band with its tubing is placed into the abdomen and the tip of the tubing is placed into the dissector. Next, the dissector is brought back to the other side of the stomach. The tubing is pulled to bring the band into position and then through the buckle to tighten the band. Stitches are placed to cover the anterior aspect of the band with care not to cover the buckle. Only enough sutures to cover the anterior aspect of the band are needed (sometimes only two).
After the band is checked to be in good position, the tubing is brought out through the initial trocar site. The tip is cut off connected to the port. The port is fixated in all 4 quadrants to make avoid port flippage.
The band is not adjusted with saline until a full 6 weeks to allow for resolution of the swelling from the normal inflammatory position after surgery. The typical weight loss is 1-2 pounds per week. Laparoscopic adjustable gastric banding offers a safe and efficient option for morbidly obese teenagers.

V003

ROBOTIC KASAI, John J Meehan MD, John Lawrence MD,Laura Phearman RN,Paula Francis,Anthony Sandler MD, University of Iowa Hospitals and Clinics

Robotic technology offers a new type of minimally invasive surgery which can allow more complex movement than what is currently possible with standard laparoscopic instruments. We present a video demonstration of a Robotic Kasai Portoenterostomy in a six week old infant with biliary atresia. The procedure was accomplished using 4 ports: a 12 mm camera port at the umbilicus, 2 five mm robot instrument ports (one along the upper midline and the other along the right mid-clavicular line), and a single 5 mm accesory port along the right flank.
The procedure took just under 5 hours and the patient had no complications. His stool improved in color within 48 hours of the surgery and he was discharged home on POD #3. His bilirubin peaked at 8.4 a few days before surgery and began declining immediately following the procedure. Robotic technology can be used in small infants with complex surgical problems. The increased degrees of freedom and 3-D imaging can help the surgeon perform complex minimally invasive procedures such as a Kasai portoenterostomy.

V004

LAPAROSCOPIC PARTIAL EXTERNAL BILIARY DIVERSION PROCEDURE IN PROGRESSIVE FAMILIAL INTRAHEPATIC CHOLESTASIS, M. Bottländer (1) MD, M. L. Metzelder (1) MD,M. Melter (2) MD,C. Petersen (1) MD,B. M. Ure (1) MD, Departments of Pediatric Surgery (1) and Pediatric Gastroenterology (2), Hannover Medical School, Hannover, Germany

Background: Progressive intrahepatic familial cholestasis (PFIC) is a complex of syndromes that lead to cholestasis, progressing to biliary cirrhosis and chronic liver failure. Medical treatment has a poor outcome. Surgical partial external biliary diversion is suggested to be the firstline surgical treatment of PFIC. This is the first series of 4 children, in whom partial external biliary diversion has been performed using a laparoscopic approach.
Methods: A three-trocar technique was used. First the ligament of Treitz was identified laparoscopically. From this point 25 cm distally a small bowel loop was exteriorized via the infraumbilical trocar incision. A 10 cm long jejunal loop was excised outside of the abdomen and a small bowel anastomosis was performed. After repositioning the bowel in the abdominal cavity an isoperistaltic cholecystojejunostomy was performed laparoscopically using 4.0 vicryl sutures. The distal end of the excised jejunal loop was placed as a stoma through the right trocar incision in the abdominal wall.
Results: In 4 children, no intraoperative events occurred. Mean duration of the laparoscopic procedure was 156 minutes. On the second postoperative day, bile fluid drained out of the stoma. The recovery of the patients was excellent and the bile acid and liver enzyme levels declined postoperatively in all patients.
Conclusion: Laparoscopic partial biliary diversion procedure is feasible and may be a further treatment option in children with PFIC. Long-term outcome needs to be evaluated.

V005

LAPAROSCOPIC ROUX-EN-Y PANCREATICOJEJUNOSTOMY, Nam X Nguyen MD, Barry Steinmetz MD,John Lee MD,Sherif Emil MD, UCI School of Medicine

The purpose of this video is to demonstrate the technical aspects of laparoscopic pancreaticojejunostomy procedure as a treatment for recurrent pancreatitis due to pancreatic duct stricture.
The patient is a fifteen-year-old female who presented with multiple episodes of pancreatitis. An ERCP demonstrated a tight pancreatic duct stricture that was not amenable to stenting. She underwent a laparoscopic Roux-en-Y pancreaticojejunostomy. There was no intraoperative complication. She was discharged home on postoperative day five. She remains symptom free from pancreatitis and has not been readmitted to the hospital in eleven months since the operation. She is, however, developing exocrine deficiency which is well-controlled with pancreatic enzyme replacement.

V006

THORACOSCOPIC REPAIR OF LEFT- AND RIGHT-SIDED CDH, Philipp O Szavay MD, Hans Joachim Kirschner MD,Joerg Fuchs MD, Dept. of Pediatric Surgery, Children's Hospital, University of Tuebingen, Tuebingen, Germany

Background:Management of children with CDH has been modified over the last decade. Primary to any surgical therapy the goal is to maintain or to re-establish ideal patient parameters including the use of High Frequency Ventilation (HFO) and Extracorporal Membrane Oxygenation (ECMO). For surgical repair of CDH minimal invasive techniques have been increasingly used in the last years.
Methods:Between 2002 and 2004 21 children underwent surgery for CDH at our institution. 6 children were operated on thoracoscopically. These were 3 newborns (2 left-sided, 1 right-sided hernia) and 3 infants, with a mean age of 11 months (2 right-sided and 1 left-sided hernia).
Results:The presented video shows both the repair of a right-sided CDH in an 8 months old female infant as well as the closure of a left-sided CDH in a newborn boy. The girl presented with a pneumonia, chest x-ray and ultrasound revealed the CDH. The boy was readmitted to the hospital due to vomiting 8 days postnatally. Preoperative diagnostics showed the CDH. Both operations were delayed surgical procedures while patients were stable concerning all relevant cardiorespiratory parameters. Primary repair was successful in both cases.
Conclusion:Children with a CDH undergoing elective surgery have a

good survival also when using a thoracoscopic approach. Thoracoscopic repair is feasible also in newborns and offers reduced morbidity avoiding large incisions for laparotomy or thoracotomy. Reposition of abdominal organs may be performed gently with moderate intrathoracic pressure of CO2. Long-term results are pending.

V007

ROBOTIC ASSISTED REPAIR OF UPJ OBSTRUCTION 2' TO CROSSING GONADAL VESSEL IN A 6 YEAR OLD BOY, Allan M Shanberg MD, David Yee MD,Esequial Rodriguez MD,Deepak Rajpoot MD, Antoci Center for Pediatric Urology and Nephrology, University of California, Irvine

Patient is a 6 year old boy who presented with a congenital UPJ obstruction of the right kidney 2' to a crossing Gonadal Vessel. The technique of a dismembered Pyeloplasty with Robotic assist for the Reconstruction of the kidney is demonstrated. The ease of this reconstruction is demonstrated, as well as the endoscopic placement of a Ureteral catheter. This child was able to be discharged from the hospital the next day following surgery.

V008

RETROPERITONEOSCOPIC SURGERY FOR THE TREATMENT OF UPPER URINARY TRACT STONES IN CHILDREN., Wieslaw Urbanowicz BS, Janusz Sulislawski MD, Michal Wolnicki PhD,Radoslaw Mycek MD, Department of Pediatric Urology, Jagiellonian University, Cracow, Poland.

Introduction.Urolithiasis is fairly common condition in children. In some cases contact or extracorporeal lithotrypsy find a limited use in pediatric patients. Additionally, one should verify whether concrement formation does not result from obstacles hindering the urine outflow.
Goal. The assessment of the validity of the retroperitoneoscopic surgery in removing concrements from the renal pelvis and ureter.
Material and methods. In the years 2000 ? 2002, retroperitoneoscopic concrement removal from the upper urinary tract was performed in 13 children aged 6 to 15 years. Eight patients had nephrolithiasis and five ? ureterolithiasis. In procedures involving the kidneys and the ureters, the abdominal approach was employed with three ports inserted and the patient placed in the prone position. Following procedures involving the upper urinary tract, healing was achieved employing a JJ stent left in situ and removed 6 weeks later.
Results. The procedure were very well tolerated. On the day of surgery the patients recived fluids and oral feeding was introduced on the following day. Analgesics were administrated for 48 hours only. The patients were allowed to walk on day 2 postoperatively. The wounds in the abdominal integument healed by first intention. The patients were discharged on day 5 ? 6 postoperatively. No complications or recurrent urolithiasis were detected on follow up.
Conclusions. Retroperitoneoscopic surgery techniques may be successfully employed in children with upper urinary tract lithiasis. The procedures meet all requirements of low ? invasiveness procedures.

V009

LAPAROSCOPIC PARTIAL NEPHRECTOMY IN A 6 MONTH OLD GIRL WITH 5 MM. LIGASURE DEVICE—NO SUTURING, Allan Shanberg MD, David Yee MD, Antoci Center for Pediatric Urology & Nephrology, University of California, Irvinie

The 5 mm. Ligasure Device is an excellent new addition to the Pediatric Urologist and Surgeons ability to perform surgery on small children with minimal morbidity. The Ligasure is a device that causes bipolar coagulation and sealing of vessels in the jaws of the device with an audio feedback telling the surgeon when the vessel has been adequately secured. It will coagulate artery's up to 5 mm in diameter and veins up to 7 mm. in diameter. It is available in both 5 mm. and 10mm instruments. There is a cutting blade attached to the instrument that allows the surgeon to cut the tissue or vessel after it is adequately coagulated.
We will demonstrate the usefullness of this instrument in performing a Laparoscopic Partial Nephrectomy in a 6 month old child for an ectopic Ureter into the vagina. No suturing or clipping of vessels is necessary, and the procedure is performed through 5 mm and 3 mm ports.

V010

LAPAROSCOPIC RESECTION OF A PROSTATIC UTRICLE, Michael V Tirabassi MD, Kevin P Moriarty MD,Richard A Courtney MD, Baystate Medical Center Children's Hospital, Tufts University School of Medicine

This video demonstrated a laparoscopic approach towards resection of a utricle in an eleven month old male born with a multi-cystic right kidney, peniloscrotal hypospadias, and a large utricle arising from the prostate. This video starts with highlighting pertinent pre-operative information including a voidance urethrogram, gross appearance of the hypospadius, and cystoscopy. During cystoscopy the utricle was cannulated with a six french catheter and filled with methylene blue to aid in surgical dissection. The utricle resection was performed via a laparoscopic trans-peritoneal approach after a trans-peritoneal laparoscopic right nephroureteroectomy. Four ports were utilized, three five millimeter ports and one three millimeter port. The camera was employed via a supra-umbilical five-millimeter port. The two working five millimeter ports were placed in the left and right hypochondriums. The three-millimeter port in the left lower quadrant was primarily used for retraction. The dissection of the utricle was begun with the harmonic scalpel. Once the correct plane was delineated the remainder of the dissection was performed bluntly. The neck of the utricle was ligated with a vicryl endo-loop and then divided with endo-shears. The entire operative time, including cystoscopy, laparoscopic nephrectomy, and resection of the prostatic utricle was 270 minutes. Pathology revealed a fibro-muscular sac lined by transitional epithelium.

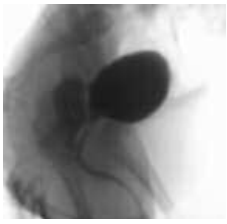

V011

ROBOTIC-ASSISTED RESECTION OF RECURRENT BRONCHOGENIC CYST, Michael S Irish MD, Thom E Lobe MD, Blank Children?s Hospital, Des Moines, Iowa

A one year-old male, having previously undergone robotically-assisted, primary resection of a bronchogenic cyst as a newborn through a right-sided approach, was diagnosed with recurrence of this lesion upon evaluation of symptoms of new onset asthma. Re-resection of this lesion was performed via a left-sided approach at one year of age. The da Vinci? Surgical system and 5 mm instruments were used for both procedures. During the procedure, the ductus arteriosus was divided and the cyst was bluntly dissected from its bed beneath the aortic arch and anterior to the trachea. There were no intraoperative complications and blood loss was negligible. The articulating robotic instruments enabled more precise, intracorporeal tissue manipulation and suturing, and 3-dimensional vision.

V012

THORACOSCOPIC TREATMENT OF CONGENITAL ESOPHAGEAL STENOSIS Marcelo Martinez-Ferro MD, Martin Rubio MD, Lisandro Piaggio MD, Pablo Laje MD, National Children's Hospital J.P.Garrahan. Buenos Aires

Purpose: Congenital esophageal stenosis (CES) is defined as an intrinsec stenosis of the esophagus , which is caused by a congenital malformation of the esophageal wall architecture. CES is a rare condition of childhood with an estimated incidence of 1:25,000 to 50,000 live births. Our purpose is to present the technical aspects for the thoracoscopic approach of a CES in a neonate. To our knowledge there are no further reports of thoracoscopic resolution of this entity.
Case Report: A neonate with bilateral anophtalmia, micropenis and distal congenital esophageal stenosis was referred to our institution for surgical treatment. After unsuccessful balloon dilatations, a thoracoscopic approach was decided. Complete resection of the stenotic esophageal segment was facilitated by using a balloon catheter. An end to end esophageal anastomosis was performed as we currently do in the esophageal atresia cases. No intraoperative or postoperative complications were observed. Cosmetic and functional results were excellent. A laparoscopic Nissen fundoplication was indicated two months later, due to persistent gastroesophageal reflux.
Conclusions: This case report supports the concept that all the congenital malformations of the esophagus can be treated with minimally invasive techniques. The authors want to share in the present video, all the technical aspects that resulted extremely useful for achieving a thoracoscopic esophageal resection and reconstruction.

Venue

Venice Convention Center
Palazzo Del Cinema & Palazzo Del Casino
Lido Lungomare G. Marconi 30, 30127 Venice, Italy
Phone: +39 041 24 20 330 Fax: +39 041 52 62 233
E-mail: info@veniceconvention.com
Website: www.veniceconvention.com

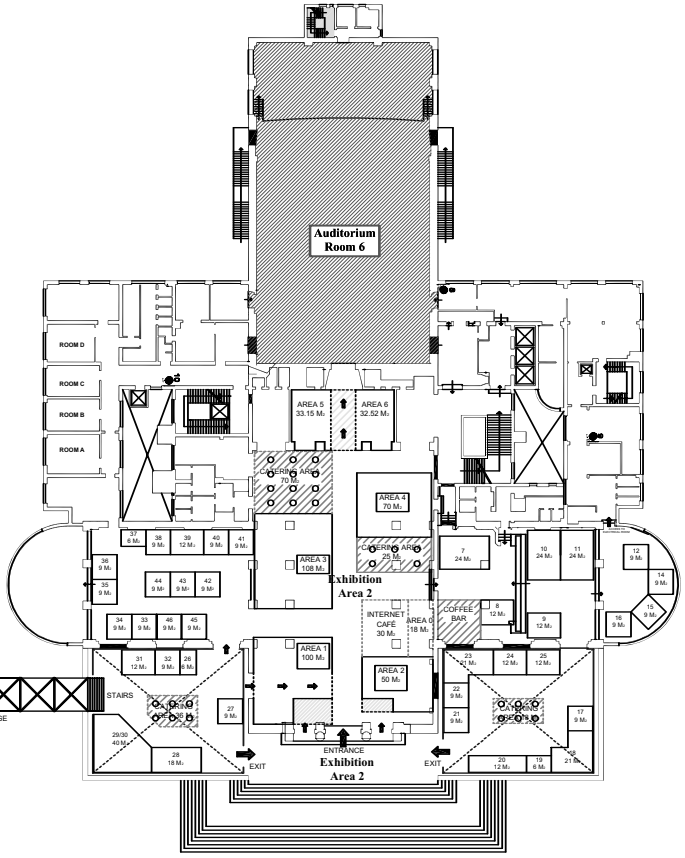

Palazzo del Casinò
Level 1

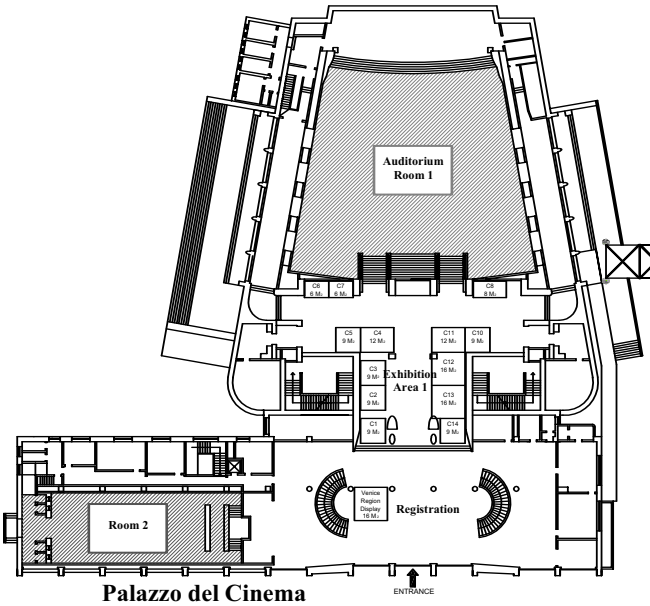

Palazzo del Cinema
Level 1

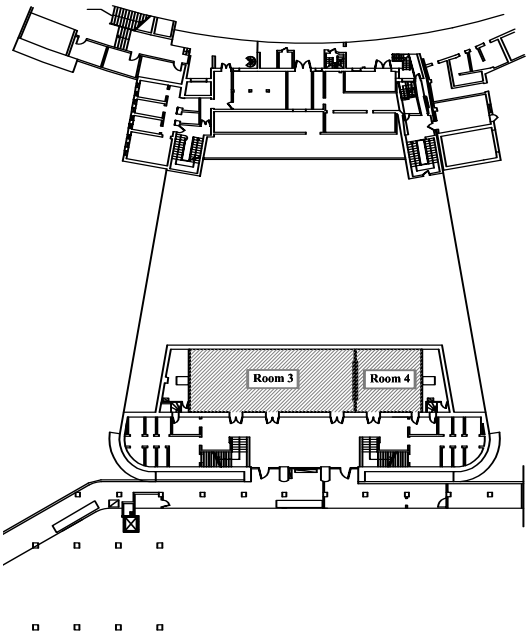

Palazzo del Cinema
Level -1

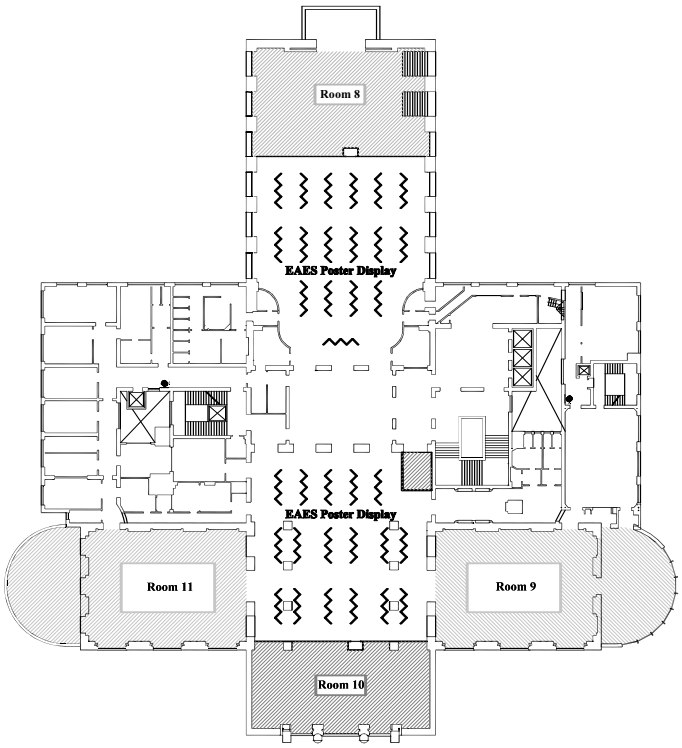

Palazzo del Casinò
Level 3

Exhibition Build-up/Break-down Period

Build Period

Monday, May 30, 2005	08:00 - 20:00
Tuesday, May 31, 2005	08:00 - 20:00
Wednesday, June 1, 2005	08:00 - 16:00

Break down Period

Saturday, June 4, 2005	13:00 - 12:00 midnight

Exhibit badge pick-up

Wednesday, June 1, 2005	08:00 - 16:00
Thursday, June 2, 2005	09:00 - 17:00
Friday, June 3, 2005	09:00 - 17:00
Saturday, June 4, 2005	09:00 - 13:00

Exhibition Opening Hours

Wednesday June 1, 2005 (Welcome Reception)	19:00 - 21:00
Thursday June 2, 2005	09:30 - 17:00

2005 Exhibitors

Taut Inc.	**0**
Olympus Medical Systems Europa GmbH	**1**
B. Braun Aesculap	**2**
Tyco Healthcare	**3**
Ethicon Endo-Surgery	**4**
Karl Storz GmbH & Co. KG	**5+6**
Richard Wolf GmbH	**7**
Pajunk GmbH	**8**
Stryker Europe, Middle East & Africa	**9+10+11**
Simulab Corporation	**12**
Hitachi Medical Systems	**14**
Intuitive Surgical, Inc.	**15**
Fleet Pharmaceuticals	**16**
Tuebingen Scientific Surgical Products GmbH	**17**
Power Medical Interventions Inc.	**18**
Genzyme GmbH	**19**
Hospimedical - HumanMed	**20**
Mentice Medical Simulation	**21**
FEG Textiltechnik GmbH	**22**
ConMed Corporation	**24**
Inamed Health	**25**
SurgRx Inc.	**26**
Atrium Medical	**27**
VIMS	**28**
Sony Healthcare Solutions	**29/30**
Simbionix Corp.	**31**
Erbe Elektromedizin GmbH	**32**
Snowden Pencer	**33**
MTP - Medical Technical Promotion	**34**
Sofradim	**35**
Viking Systems Inc.	**36**
Aus systems/LaproSurge	**37**
Cook	**38**
Gimmi GmbH	**39**
Surgical Science AB	**40+41**
Applied Medical	**42+43**
Innovamedica srl	**44**
Vernon-Carus Ltd	**45**
IRCAD-EITS-WEBSURG	**46**
World Congress 2006	**C1**
Springer Verlag	**C2**
SAGES	**C3**
W.L. Gore & Associati GmbH	**C4**
WISAP mbH	**C5**
Lina Medical CML APS	**C6**
Dellta Tech	**C7**
Microline PENTAX, Inc	**C8**
LOTUS - SRA Developments Ltd	**C10**
Simsurgery AS	**C11**
EAES	**C14**

EDITORIALS

Applied Medical — *Booth 42 + 43*

As a new generation medical company with a history of responding to evolving clinical needs, Applied is well recognized for its advancements in laparoscopic surgery. Applied's innovations include the Separator® abdominal access system, Direct Drive™ atraumatic graspers and the new GelPort® XE hand access device.

22872 Avenida Empresa, Rancho Santa Margarita, California 92688, USA, Ph: +19497138000, Fx: +19497138200.

Atrium Medical — *Booth 27*

Atrium with over two decades of experience providing solutions from science with our first to market Lightweight surgical mesh continues the commitment by introducing our novel APD™ design allowing easier implantation of our lightweight ProLite™ and ProLite Ultra™ meshes as the shapes follow the Anatomical Plane of Dissection. Atrium: From Science to Solutions!

Rendementsweg 24 L, 3641SL Mijdrecht, The Netherlands, Ph: +31 297 230 420, Fax: +31 297 230 422,

Email: internationalsales@atriummed.com

Aus Systems/LaproSurg — *Booth 37*

Aus systems rbi2. The new suction rectal biopsy system designed to retrieve a controlled specimen for pathological examination for the diagnosis of Hirschprung's Disease.

LaproSurge. High quality single-use devices for laproscopic applications including tissue retrieval systems, trocar and cannula sets, smoke filters, scissors, insufflation needles and many laproscopic accessories.

Heriots Wood, The Common Stanmore, HA7 3HT, England, UK, Ph: + 442089509501, Fx:+442089509199.

B. Braun Aesculap — *Area 2*

Aesculap, founded 1867 in Tuttlingen/Germany, is the undisputed leader in the manufacturing of surgical instruments worldwide. Decades of experience, competence and expertise in surgery made Aesculap a system supplier for the entire core process in the operating theatre. Including surgical instruments for open and minimally invasive surgery, sutures, power units, navigation and container systems as well as a complete range of implants for orthopaedics, neuro, spinal and cardiovascular surgery. For nearly 140 years the name Aesculap is a synonym for quality, innovation and reliability.

Am Aesculap-Platz, 78532 Tuttlingen, Germany, Ph: +497461952929, Fx: +497461952072.

Conmed Corporation — *Booth 24*

525 French Road, Utica, New York 13502, USA, Ph: +131562433, Fx: +13157327991.

Cook — *Booth 38*

SURGISIS™ is a surgical biomaterial used instead of a mesh. While SURGISIS reinforces and supports, the body's natural healing process repairs the weakened tissue. Eventually SURGISIS is replaced with new organised host tissue. SURGISIS is strong enough to be sutured or stapled and becomes even stronger over time. It reduces pain after inguinal hernia repair and can be used in an infected or potentially contaminated ventral hernia.

O'Halloran Road, National Technology Park, Limerick, Ireland, Ph: +35361334440, Fx: + 35361334441.

Dynamesh — *Booth 22*

Advanced technology of textile implants designed and engineered by FEG Textiltechnik GmbH. DynaMesh® hernia implants, applicable in all open and laparoscopic operation techniques, are characterised by high porosity, excellent biocompatibility and improved handling properties. Presentation of DynaMesh®-IPOM, the worldwide unique non-coated and non-adhesive mesh made from the high-tech polymer PVDF.

Juelicher Strasse 338A, 52070 Aachen, Germany, Ph: +49241162008, Fx: + 49241962126, WWW.dynamesh.com.

ERBE Elektromedizin GmbH — *Booth 32*

Waldhörnlestr. 17, D-72072 Tübingen, Ggermany, Ph: +49 7071 755 111, Fx: +49 7071 755 5111.

Ethicon Endo-Surgery — *Area 4*

Ethicon Endo-Surgery develops and markets a broad portfolio of advanced surgical instruments and medical devices for minimally invasive and traditional surgery. We focus on designing innovative, procedure-enabling solutions for the diagnosis and treatment of diseases in most surgical areas. Our vision is "Transforming Patient Care Through Innovation".

Hummelbuetteler Steindamm 71, 22851 Norderstedt, Germany, Ph: +494052973200, Fx: +494052973119.

Fleet Pharmaceuticals — *Booth 16*

Fleet Pharmaceuticals offers the most complete line of laxative products and is the number one brand of laxatives sold in the U.S. Fleet has three unique products specifically designed for children – Fleet® enema for children, Fleet® Child Glycerin Suppositories and Fleet® Babylax®.

4615 Murray Place, Lynchburg VA 24502, USA, Ph:+4345284000, Fx:+ 434 5228490.

Genzyme GmbH — *Booth 19*

Siemensstrasse 5b, 63262 Nue-Isenburg, Germany, Ph:+4961023674721, Fx:+4961023674701.

Gimmi GmbH — *Booth 39*

GIMMI GmbH founded in Tuttlingen 1932, manufacturing and distributing medical products. Professional customer service, product training by our capable GIMMI team. Our program: Endoscopic Technology, Advanced Imaging, HF Units, Accessoires, Insufflation, Suction, Irrigation Units, Urology.

Carl-Zeiss-Str.6, D-78532 Tuttlingen, Germany, Phone: +49746196590-0, Fax: +4996590-33.

Hitachi Medical Systems GmbH — *Booth 14*

HITACHI Medical Systems offers a wide variety of fully digital Ultrasound-Systems including a selection of specific transducers for Endoscopic Surgery, such as radial and longitudinal electronic Echoendoscopes, Rectal-Probes, Biopsy-Probes and Laparoscopic-Probes with integrated working channel for Biopsy and Therapy. HITACHI Medical Systems presents also

the SonoElastography Module for the EUB-8500 Series which allow to display the Tissue Elasticity in Real-Time.

Sumpfstrasse 24, Zug 6300, Switzerland, Phone: +41417486333, Fax: +41417486332, E-mail:info@hitachi-medical-systems.com.

Hospimedical Gastric Banding — *Booth 20*

Hospimedical GmbH is a manufacture of innovative gastric banding solutions, like the MiniMizer gastric band and accessories. The MiniMizer is the only band on the market that does not require a placation and can directly be attached to the stomach by which it dramatically reduces the slipping rate.

Gewerbegebiet Egelsee, CH-8259 Kaltenbach, Switzerland, Ph:+41527416500, Fx:+41527416501,E-mail:mail@hospimedical.com.

Inamed Health — *Booth 25*

INAMED Health is a world leader in delivering minimally invasive surgical devices and services to achieve and support sustained weight-loss, reduce the health risks associated with obesity and enhance patients' quality of life. The LAP-BAND® System is an adjustable band that reduces gastric capacity and creates an earlier feeling of satiety. The BioEnterics® Intragastric Balloon (BIB®) System is a non-surgical, non-pharmaceutical alternative for the treatment of obesity. Endoscopically placed within the stomach and inflated with saline, the BIB® System balloon partially fills the stomach to induce a feeling of satiety to support patients in reducing food intake and adopting new dietary habits.

Prof. Zeemanweg 2C, 5144 NN Waalwijk, The Netherlands, Ph: + 31416392246, Fx: + 31416363015.

Innovamedica srl — *Booth 44*

INNOVAMEDICA develops and markets innovative product ranges (single use, multi use and reusable) in various select medical fields in Italy, through its own sales organization.

In the Minimally Invasive Surgery INNOVAMEDICA is exclusively representing several brands, including Applied Medical – USA, leading brand in the world market.

Our premises are located in Cusago in the west area of Milan, very close to the ring-road motorway.

There we enjoy new offices and warehouse, which guaranties proper stock and prompt deliveries for every product line.

Viale Europa, 7820090 Cusago (MI), Italy, Ph:+ :+39 02 9039201, Fx :++39 02 90394211.

Intuitive Surgical, Inc. — *Booth 15*

Intuitive Surgical is the world's leading provider of operative solutions for the robotically assisted Minimally Invasive Surgery market. From core technology- robotics, voice control and telecollaborative systems – to proven protocols for clinical success, Intuitive's solutions make routine procedures easier, complex procedures routine and new procedures possible.

5 place Royale, 78100 Saint-Germain en Laye, France, Ph: +33.1.39.04.26.60, Fx: 33.1.39.04.26.61, E-mail: eurosales@intusurg.com

IRCAD-EITS-Websurg — *Booth 46*

Training center in minimally invasive surgery (colorectal, digestive, morbid obesity, endocrine, aortoiliac, urological and gynaecological surgery). Web site specialized in laparoscopic surgery and e-learning.

1 Place de l' Hôpital, BP 426, F-67091, Strasbourg, France, Ph: +33388119154, Fx: +33388119199.

Karl Storz GmbH & Co. KG — *Area 5 + 6*

KARL STORZ is a renowned manufacturer that is well established in all fields of endoscopy. The still family held company has grown to one with a world wide presence and more than 3000 employees. KARL STORZ offers a range of both rigid and flexible endoscopes for a broad variety of applications.

Mittelstrasse 8, 78532 Tuttlingen, Germany, Ph: +4974611708378, Fax: +4974611708377, E-mail:s.maj@karlstorz.de.

Lina Medical CML Aps — *Booth C6*

LINA Medical offers products for laparoscopic surgery: LiNA PowerBlade, which cuts with bipolar current, plus the transportable Laparo Trainer, which enables surgeons to train laparoscopic surgery with an affordable trainer. Endo-bags, Endo-Hooks, Trocars, Lap-Chole Kits, Suction & Irrigation, Bipolar Blunt Coagulator, Lina-Loop a monopolar loop for sectioning of the uterus.

Formervangen 5, DK-2600 Glostrup, Denmark, Ph: +4543296666, Fx: +4543296699.

LOTUS - SRA Developments ltd — *Booth C10*

LOTUS technology realises the early ambitions of Ultracision and Ethicon for their Harmonic Scalpel products. The ultrasonic alternative to diathermy need not be slow and costly: LOTUS offers secure fast affordable tissue welding, with minimal trauma. Visit stand C10 Palazzo del Cinema to see the best ultrasonic scalpel on the market.

Bremridge House, Bremridge , Ashburton, Devon TQ13 7JX, UK, Ph: +441364652426, Fx: +441364653589, E-mail: heather@sra-developments.co.uk.

Mentice Medical Simulation — *Booth 21*

Mentice has a vision of increasing the patient safety through being the leading developer and supplier of virtual reality applications within the field of medicine, with special attention to the area of endovascular intervention and minimally invasive surgery. Mentice works closely together with the leading medical and healthcare professionals in order to develop long-term solutions that are of immediate use to the medical profession.

Kaserntorget 6, 41118 Gothenburg, Sweden, Ph: +46317438783, Fx: +46317438099.

Microline-PENTAX — *Booth C8*

Microline-Pentax manufactures and sells a "reposable" modular laparoscopic instrument system consisting of a laparoscopic multifire clip applier and several reusable handpieces, accommodating a broad assortment of disposable and limited-use tips. This concept generates surgical efficiency and cost effectiveness by reusing durable components and only replacing critical components, like scissor tips.

800 Cummings Center, Suite 157-X, Beverly, MA 01915 USA, Ph: +19789229810, Fx: +19789229209, www.microlineinc.com.

Mtp Medical Technical Promotion GmbH — *Booth 34*

mtp is manufacturer of medical disposables especially for the minimal invasive surgery. Besides tubing sets and filters – exclusively accessories to KARL STORZ products – mtp offers extraction bags and sterile covers as well as disposable HF-Instruments. All orders received are immediately processed via our 24-hour delivery service.

Dr. Karl-Storz-Str. 13, 78532 Tuttlingen, Germany, Ph: +497461966300, Fx: +4974619663025, E-mail: info@mtp-tut.de.

Olympus Medical Systems Europa GmbH — *Area 1*

Olympus represents a complete range of laparoscopic equipment which starts with integrated OR systems and ends with a variety of unique accessories: EndoEYE – chip-on-the-tip – the autoclavable all-in-one solution is a synonym for excellent image quality as well as for efficient handling. SonoSurg – 100% reusable – incorporates ultrasonic coagulation/cutting and aspiration.

Wendenstr. 14-18, 20097 Hamburg, Germany, Ph: +494023773-5744, Fx: +494023773-5731.

Pajunk GmbH — *Booth 8*

Karl-Hall-Str. 1, D-78187 Geisingen, Germany, Ph: +4977049291-0, Fx : +4977049291-610.

Power Medical Interventions Inc. — *Booth 18*

110 Union square Drive, New Hope, PA 18938, USA, Ph:+441295738440, Fx:+441295738974.

Richard Wolf GmbH — *Booth 7*

Endoscopes from Richard Wolf GmbH - for the latest operating techniques!

Richard Wolf is one of the world's leading manufacturers of medical instruments and electronic equipment for minimal invasive surgery. With the development of the extracorporeal Richard Wolf has made a further significant contribution to non-invasive stone therapy.

Pforzheimer Strasse 32, D-75438 Knittlingen, Ph : +497043350, Fx: +49704335300, E-mail: info@richard-wolf.com.

SAGES — *Booth C3*

SAGES is the American "Sister" Society of EAES. Visit our booth for international membership applications, guidelines in training and standards of practice as well as information on the SAGES '05 meeting in Florida when we are part of "Spring Surgery Week" with AHPBA and the American College of Surgeons.

11300 West Olympic Boulevard, Suite 600, Los Angeles, CA 90064, Ph: +3104370544, Fx: +13104370585

Simbionix Corp. — *Booth 31*

Simbionix is a global leader in medical simulation technology. Simbionix products provide medical experts with hands-on training in a comprehensive array of MIS procedures; GI Mentor™ for training Gastroscopic procedures, URO/PERC Mentors™ - Practice endourology and PCN procedures, LAP Mentor™ - for laparoscopic skills and procedures, and ANGIO Mentor™, provides practice in interventional endovascular procedures.

6 Hamelacha Street , Northern Industrial Zone, 71520 LOD, Israel, Ph: + 97289211177, Fx: +97289211188.

Simendo — *Booth C7*

Dellta Tech is a company that is specialized in VR-training for Laparoscopy and endoscopy. Our latest product is the SIMENDO, world most affordable VR-Trainer there is on the market nowadays. Our philosophy: every surgeon or resident surgeon should have the possibility to train his/her skills anytime, anywhere. We made it possible.

Mijnbouwplein 11 K1.06, 2628 CX Delft, The Netherlands, Ph: +31(0)152561851, Fx: +31847301117.

Simulab Corporation — *Booth 12*

1144 NW 52nd Street, WA98107 Seattle, USA, Ph:+2062971260, Fx:+2536817667.

Simsurgery AS — *Booth C11*

Sognsvn. 75B, 0855 Oslo, Norway, Ph:+4723008164, Fx:+4797535656.

Snowden Pencer — *Booth 33*

The Snowden Pencer® Products business of Cardinal Health is the manufacturer of the highest quality instrumentation and equipment for endoscopic surgery. Our product line includes Diamond-Flex®, Diamond-Touch, and Diamond-Port instruments as well as the latest technology in high flow insufflators.

5175 South Royal Atlanta Drive, Tucker, GA 30084, USA, Ph: +17704960952, Fx: +17707232798.

Sofradim — *Booth 35*

SOFRADIM offers a full range of parietal implants for the surgical reinforcement of deficient abdominal walls: PARIETEX®, PARIETENE®, PARIETEX® COMPOSITE, PARIETENE® COMPOSITE. These implants are particularly adapted to the repair of inguinal, incisional, umbilical and hiatus hernias, and surgical treatment of specific prolapses (Gynecology). SOFRADIM offers also

I-CLIP®, a new disposable instrument delivering resorbable fixation clips.

116 Avenue du Formans, 01600 Trevoux, France, Ph: + 33(0)474089015, Fx: +33(0)474089016.

Sony Healthcare Solutions — *Booth 29 + 30*

Sony will be demonstrating their complete solution for the management of visible light inventory. From the MPEG-2 capture box, to the Satellite server/HNF storage system, ultra-sharp LCD monitors and more, Sony offers a complete DICOM-compliant solution for capture and communication of the operating room's still imagery and video output.

www.sonybiz.net/healthcare

Springer –Verlag GmbH & Co KG — *booth C2*

Springer's programme contains a wide range of books, journals and electronic media covering most fields of medicine of interest to professionals and researchers in medical and biomedical sciences. Our latest highlights on surgery and its

various techniques (endoscopic, laparoscopic, keyhole minimal invasive etc) will be on display, along with our journals programme related to the topics of the congress. Please visit our exhibit, we will be pleased to show you our current titles in your field.

Tiergartenstr. no. 17, D-69121 Heidelberg, Germany, Ph: +496221487-8994, Fx: +496221487-8916.

Stryker Europe, Middle East & Africa — *Booth 9 + 10 + 11*

Stryker Corporation is a leader in the worldwide orthopaedic market and is one of the world's largest medical device companies. Stryker delivers results through a wide range of capabilities including joint replacements, trauma, spine and micro implant systems, orthobiologics, powered surgical instruments, surgical navigation systems, endoscopic products as well as patient handling and emergency medical equipment.

Cité-Centre, Grand-rue 92, 1820 Montreux, Switzerland, Ph: +41219661201, Fx: +41219661200, www.strykereurope.com.

Surgical Science AB — *Booth 40 + 41*

Surgical Science develops high-quality tools for the Assessment, Training and Certification of medical professionals. Using cutting-edge simulation technology and wide-ranging knowledge of the needs of the medical community, we are committed to developing tools that will help train safer surgeons faster.

Haraldsgatan 5, 413 14, Goteborg, Sweden, Ph: + 46317416562, Fx: +46317416579.

Surgrx Inc. — *Booth 26*

The EnSeal™ System enables thermal ligation and division of up to 7mm vessels using our RF-60 Generator. SMART ELECTRODE™ technology fuses tissues independent of their impedance characteristics. EnSeal™ fuses and divides vessels with virtually no unwanted thermal effects.

380 Portage Avenue, Palo Alto, CA 94306, USA, Ph: +13676507102, Fx: +13676507101, E-mail: CustomerService@surgrx.com.

Taut Inc — *Area 0*

2571 Kaneville Court, Geneva, IL 60134, USA, Ph: + 16302322507, Fx: +16302328005.

Tuebingen Scientific Surgical Products GmbH — *Booth 17*

Dorfackerstrasse 26, 72074 Tuebingen, Germany, Ph: +4970717704514, Fx: +497071763574.

Tyco Healthcare — *Area 3*

Tyco Healthcare is a global leader within the healthcare industry. Its extensive products portfolio includes wound closure products (sutures and surgical stapling), disposable laparoscopic instruments, cardiovascular and vascular therapies devices. Tyco's commitment to the surgical team also includes a complete line of advanced electrosurgery and ultrasonic surgery systems and accessories.

2, Rue Denis Diderot- ZA La Clef de St. Pierre, F-78990 Elancourt, France, Ph: +33130798222, Fx: +33130798213.

Vernon Carus Ltd — *Booth 45*

Vernon Carus is a manufacturer of endoscopic retrieval bags - Nubert, Albert and Hubert are impervious and the strongest bags available. We also manufacture disposable kits for Laparoscopic Surgery, either as a standard kit or to customer specification.

Penwortham Mills, Preston PR1 9SN, United Kingdom, Ph: +441772744493, Fx: +441772320438.

VIKING SYSTEMS INC. — *Booth 36*

134 Flanders Road, Westborough, MA 01581, USA, Ph:+15083663668,Fx:+15083668858.

VIMS — *Booth 28*

The Visionary all-in one digital video system.

Immeuble les Aravis – Voie occitane, ZAC Grande Borde, 31673 Labege Cedex, France, Ph:+ 33534450909, Fx :+ 33561228584.

W.L. Gore & Associates GmbH — *Booth C4*

Gore is a leading manufacturer of thousands of advanced technology products for the electronics, industrial, fabrics and medical markets. The Gore Medical Products Division provides creative healing solutions to complex medical problems. Gore Medical provides such products as synthetic vascular grafts, interventional devices, surgical meshes for hernia repair, and sutures for use in vascular, cardiac, general surgery and orthopedic procedures. With more than 12 million implants, these devices have been saving and improving the quality of lives worldwide for over 30 years.

Hermann Oberth Strasse 22, 85639 Putzbrunn, Germany, Ph:+498946120.

WISAP Gesellschaft für wissenschaftlichen Apparatebau mbH — *Booth C5*

Rudolf-Diesel-Ring 20, 82054 Sauerlach, Germany
Phone: 49-8104-89080, Fax: 49-8104-890890
Email: <mailto:info@wisap.de>info@wisap.de
www.wisap.com

WISAP is one of the most historical, leading manufacturers in Minimal Invasive Surgery and Gynaecology. WISAP provides medical practitioners with innovative devices made to Professor Kurt Semm's specifications, who invented the first

CO2-insufflator world-wide for controlled build-up of a pneumoperitoneum (1963), the Endo-Coagulator and the unique Morcellator-System.

Come to a New Kind of Texas!

IPEG's 15th Annual Congress for Endosurgery in Children

Part of Spring Surgical Week with SAGES & ACS

April 26 - 29, 2006

Dallas, Texas

at the extraordinary

Wyndham Anatole Hotel



Dallas is a newly hip city. IPEG convenes at one of its most extraordinary new hotel/convention center complexes.

Program Chair: Marc Levitt, MD

- **World Class International Faculty...as usual!**
- **State-of-the-Art Courses**
- **Scientific Sessions**
- **Learning Center**
- **Technology Pavillion**
- **Exhibits debut the newest in minimal access and endoluminal technology and equipment**
- **The traditional IPEG Social**
- **SAGES (Society of American Gastrointestinal & Endoscopic Surgeons) hosts its annual meeting once again concurrent with the IPEG meeting.**
- **The ACS Spring meeting will follow the IPEG/SAGES meeting...also at the Wyndham Anatole**
- **Once again it is possible to attend three superb surgical meetings in the space of one week.**

IPEG 2006 preliminary program information will be available this Fall. Check the IPEG website, www.ipeg.org, for updates.

IPEG
Phone: (310) 437-0553 • Fax: (310) 437-0585
11300 West Olympic Boulevard, Suite 600 • Los Angeles, CA 90064 • email: ipegweb@ipeg.org

SPONSOR:

IPEG
International Pediatric Endosurgery Group
11300 West Olympic Blvd., Suite 600
Los Angeles, CA 90064 USA
Phone: (310) 437 - 0553
Fax: (310) 437 - 0585
E-mail: admin@ipeg.org
Website: www.ipeg.org

CONGRESS:

14TH Annual Congress of the International Pediatric Endosurgery Group (IPEG)

Joint Meeting with The European Association for Endoscopic Surgery (EAES)

For EAES program information, please visit
http:www.eaes-eur.org/congress2005/index.html

ENGLISH IS THE OFFICIAL LANGUAGE OF THIS CONGRESS

LOCATION:

Venice Lido, Italy

DATE:

June 1 - 4, 2005

IPEG 2005 Corporate Supporters

AutoSuture, Valleylab and Tyco Healthcare International
Ethicon Endo-Surgery, Inc.

Fleet Pharmaceuticals
Karl Storz Endoscopy, Inc
Stryker Endoscopy
Taut, Inc.

International Pediatric Endosurgery Group
11300 West Olympic Blvd., Suite 600